



Patient's name : ANUPAMABEN KISHORBHAI MANHAR
Age/Sex : 51.Years/Female
Referred by : MEDI WHEEL
Collection Time : 11:16

Reg. ID : P-6863-23
Accession : 24706
Order Dt/time : 23/03/2024 11:16

Complete Blood Count

Sample Type: EDTA

Test Name	Result	Units	Biological Reference Interval
<u>Blood Counts</u>			
Haemoglobin :	11.3	Gms%	12.5 - 16.0
Total R.B.C. :	4.02	mill/c.mm	4.2 - 5.4
Total W. B. C. :	5850	/cu mm	4000 - 10500
Platelet Count :	245000	/cu.mm	1,50,000 - 4,50,000
<u>Differential Count</u>			
Neutrophils :	58	%	40 - 70
Lymphocytes :	37	%	20 - 40
Eosinophils :	03	%	1 - 4
Monocytes :	02	%	2 - 6
Basophils :	00	%	0 - 01
<u>Blood Indices</u>			
P. C. V :	35.6	%	37 - 47
M. C. V. :	88.5	fl	78 - 100
M.C.H :	28.1	pg	27 - 31
M. C. H. C :	31.8	%	32 - 36
R.D.W :	14.6	%	11.5 - 14.0

E.S.R.(Westergren Method)

After one hour : 06 mm/hr 3 - 12

TESTS DONE ON FULLY AUTOMATED HEMATOLOGY ANALYZER.

Dr. Gayatri M. Mehta
M. D. (Patho)

Reg. No. G-32215

DR GAYATRI MEHTA
MD(PATHOLOGY)

DR.ANAND D.PARIKH
MD(PATHOLOGY)

LAB USE ONLY (Entered by :GM Enter Date/Time:23/03/2024 7:15:00 PM) (Verify by :GM Verify Date/Time:23/03/2024 7:15:00 PM)



Vidhi Diagnostics | Pathology Department

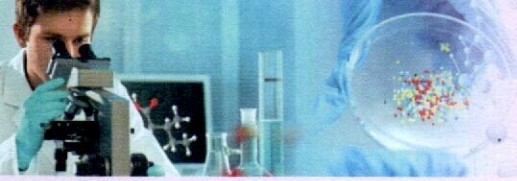L-86, Swatantra Senani Nagar, Opp. Akhbarnagar Petrol Pump, Nr. Akhbarnagar Circle, Nava-Vadaj, Ahmedabad - 380 013.

M. - Pathology : 8849893954, Ph. : 079-27621406, M. 98799 29406, 98250 09406, E-mail : vidhidiagnostics@gmail.com, Web. : www.vidhidiagnostics.com

Time (Pathology) : Mon. to Sat. 8.30 am to 8.00 pm, Sunday 9 am to 12 Noon

Pathology means science behind medicine

CT SCAN & CBCT FACILITY NOW AVAILABLE



Pathology Department

Patient's name : ANUPAMABEN KISHORBHAI MANHAR
 Age/Sex : 51 Years/Female
 Referred by : MEDI WHEEL
 Collection Time : 11:16

Reg. ID : P-6863-23
 Accession : 24706
 Order Dt/time : 23/03/2024 11:16

Blood Group

Sample Type: EDTA sample.

Test Name	Result
BG :	" O "
RH :	POSITIVE
Remarks	Done by forward grouping method.

Blood Glucose

Sample Type: Serum

Test Name	Result	Units	Biological Reference Interval
Fasting Blood Glucose :	93.2	mg/dl	70 - 110
Urine Sugar :	NIL		Absent
<i>GOD-POD Method.</i>			

Blood Glucose

Sample Type: Serum

Test Name	Result	Units	Biological Reference Interval
Post Prandial Blood Glucose After 2hr. :	136.3	mg/dl	80 - 140
Urine Sugar :	NIL		Absent
<i>GOD-POD Method.</i>			

Dr. Gayatri M. Mehta
 M. D. (Patho)

Reg. No. G-32215

DR GAYATRI MEHTA
MD(PATHOLOGY)

DR. ANAND D. PARIKH
MD(PATHOLOGY)

LAB USE ONLY (Entered by :GM Enter Date/Time:23/03/2024 7:17:00 PM) (Verify by :GM Verify Date/Time:23/03/2024 7:17:00 PM)



Vidhi Diagnostics | Pathology Department

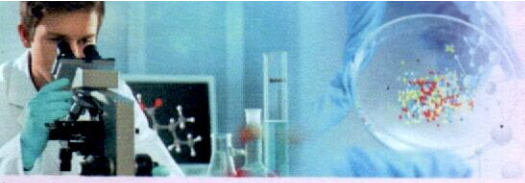L-86, Swatantra Senani Nagar, Opp. Akhbarnagar Petrol Pump, Nr. Akhbarnagar Circle, Nava-Vadaj, Ahmedabad - 380 013.

M. - Pathology : 8849893954, Ph. : 079-27621406, M. 98799 29406, 98250 09406, E-mail : vidhidiagnostics@gmail.com, Web. : www.vidhidiagnostics.com

Time (Pathology) : Mon. to Sat. 8.30 am to 8.00 pm, Sunday 9 am to 12 Noon

Pathology means science behind medicine

CT SCAN & CBCT FACILITY NOW AVAILABLE



Creating Life in Progress

Pathology Department

Patient's name : ANUPAMABEN KISHORBHAI MANHAR
Age/Sex : 51 Years/Female
Referred by : MEDI WHEEL
Collection Time : 11:16

Reg. ID : P-6863-23
Accession : 24706
Order Dt/time : 23/03/2024 11:16

HbA1C

Sample Type: EDTA

Test Name	Result	Units	Biological Reference Interval
HbA1C :	5.5	%	Non-diabetic: 4.2-6.2 Pre-diabetic : 6.3-7.2 Diabetic : 7.3-8.2
Mean Blood Glucose of Last 03 months.	111.15	mg/dl	

Comment

*As per the new 2009 update of American Diabetes Association regarding HbA1C & Mean Blood Glucose relationship.

NOTE:

This test is used to monitor diabetic patients compliance with the therapeutic regimen and logo It's level is proportional to both the average blood glucose concentration and the life span of the red blood cells (RBC) in circulation. HbA1c values are free of day to day glucose fluctuations and are unaffected by exercise or recent food intake.

Dr. Gayatri M. Mehta
M. D. (Patho)

Reg. No. G-32215

DR GAYATRI MEHTA
MD(PATHOLOGY)

DR. ANAND D. PARIKH
MD(PATHOLOGY)

LAB USE ONLY (Entered by :GM Enter Date/Time:23/03/2024 7:16:00 PM) (Verify by :GM Verify Date/Time:23/03/2024 7:16:00 PM)



Vidhi Diagnostics | Pathology Department

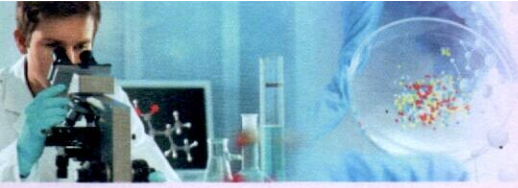L-86, Swatantra Senani Nagar, Opp. Akhbarnagar Petrol Pump, Nr. Akhbarnagar Circle, Nava-Vadaj, Ahmedabad - 380 013.

M. - Pathology : 8849893954, Ph. : 079-27621406, M. 98799 29406, 98250 09406, E-mail : vidhidiagnostics@gmail.com, Web. : www.vidhidiagnostics.com

Time (Pathology) : Mon. to Sat. 8.30 am to 8.00 pm, Sunday 9 am to 12 Noon

Pathology means science behind medicine

CT SCAN & CBCT FACILITY NOW AVAILABLE



Pathology Department



Patient's name : ANUPAMABEN KISHORBHAI MANHAR
Age/Sex : 51 Years/Female
Referred by : MEDI WHEEL
Collection Time : 11:16

Reg. ID : P-6863-23
Accession : 24706
Order Dt/time : 23/03/2024 11:16

Lipid Profile

Sample Type: Serum

Test Name	Result	Units	Biological Reference Interval
S. Cholesterol : Oxidase-esterase method.	143	mg/dl	0 - 200
S. Triglyceride : Enzymatic Colorimetry method	54.0	mg/dL	0 - 200
S. HDL - Cholesterol : Serum by Enzymatic method.	48.2	mg/dL	35 - 65
S. LDL - Cholesterol : Serum by Enzymatic method	84	mg/dL	0 - 130
S. VLDL - Cholesterol :	10.8	mg/dL	0 - 30
S. Chole/HDL.Ratio :	2.97		1 - 6
S. LDL/ HDL Cholesterol Ratio :	1.74		0 - 3.5

Dr. Gayatri M. Mehta
M. D. (Patho)

Reg. No. G-32215

DR GAYATRI MEHTA
MD(PATHOLOGY)

DR. ANAND D. PARIKH
MD(PATHOLOGY)

LAB USE ONLY (Entered by :GM Enter Date/Time:23/03/2024 7:16:00 PM) (Verify by :GM Verify Date/Time:23/03/2024 7:16:00 PM)



Vidhi Diagnostics | Pathology Department

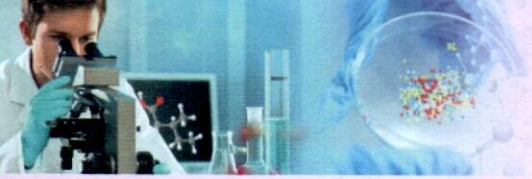L-86, Swatantra Senani Nagar, Opp. Akhbarnagar Petrol Pump, Nr. Akhbarnagar Circle, Nava-Vadaj, Ahmedabad - 380 013.

M. - Pathology : 8849893954, Ph. : 079-27621406, M. 98799 29406, 98250 09406, E-mail : vidhidiagnostics@gmail.com, Web. : www.vidhidiagnostics.com

Time (Pathology) : Mon. to Sat. 8.30 am to 8.00 pm, Sunday 9 am to 12 Noon

Pathology means science behind medicine

CT SCAN & CBCT FACILITY NOW AVAILABLE



Pathology Department

Patient's name : ANUPAMABEN KISHORBHAI MANHAR
Age/Sex : 51 Years/Female
Referred by : MEDI WHEEL
Collection Time : 11:16

Reg. ID : P-6863-23
Accession : 24706
Order Dt/time : 23/03/2024 11:16

BIOCHEMISTRY

Sample type :Serum

Test Name	Result	Units	Biological Reference Interval
Urea , (Serum by GLDH method) :	26.1	mg/dl	10 - 50
S.Uric acid , (Serum by Uricase method) :	6.7	mg/dl	2.6-6.0
Bun :	12.2	mg/dl	6-20
Creatinine , (Serum by Enzymatic reaction) :	0.52	mg/dl	0.5-1.2
S.G.P.T (ALT) : (Serum by IFCC method)	16.9	U/L	0 - 40
S.G.O.T (AST) : (Serum by IFCC method)	14.3	U/L	0 - 37
ALK.PHOSPHATASE : (Serum by PNP method)	101	U/L	35-104
G.G.T :	13.4	U/L	8 - 78
<u>BILIRUBIN</u>			
Total :	0.57	mg/dl	Up to 1.2
Direct :	0.32	mg/dl	0-0.7
Indirect :	0.25	mg/dl	0 - 0.5
<u>SERUM PROTEINS</u>			
Total Protein (Serum by Biuret method) :	6.77	gms/dl	6.4 - 8.5
Albumin (Serum by BCG method) :	4.08	gms/dl	3.97-4.94
Globulins :	2.69	gms/dl	2.3 - 3.5
A/G Ratio :	1.517		0.9 - 2.9

Dr. Gayatri M. Mehta
M. D. (Patho)

Reg. No. G-32215

DR GAYATRI MEHTA
MD(PATHOLOGY)

DR.ANAND D.PARIKH
MD(PATHOLOGY)

LAB USE ONLY (Entered by :GM Enter Date/Time:23/03/2024 7:15:00 PM) (Verify by :GM Verify Date/Time:23/03/2024 7:15:00 PM)



Vidhi Diagnostics | Pathology Department

L-86, Swatantra Senani Nagar, Opp. Akhbarnagar Petrol Pump, Nr. Akhbarnagar Circle, Nava-Vadaj, Ahmedabad - 380 013.

M. - Pathology : 8849893954, Ph. : 079-27621406, M. 98799 29406, 98250 09406, E-mail : vidhidiagnostics@gmail.com, Web. : www.vidhidiagnostics.com

Time (Pathology) : Mon. to Sat. 8.30 am to 8.00 pm, Sunday 9 am to 12 Noon

Pathology means science behind medicine

CT SCAN & CBCT FACILITY NOW AVAILABLE



Creating Life in Progress

Pathology Department

Patient's name : ANUPAMABEN KISHORBHAI MANHAR
Age/Sex : 51 Years/Female
Referred by : MEDI WHEEL
Collection Time : 11:16

Reg. ID : P-6863-23
Accession : 24706
Order Dt/time : 23/03/2024 11:16

Urine Analysis

Sample Type: Urine

Test Name	Result	Units	Biological Reference Interval
<u>Physical Examination</u>			
Quantity :	30	ml	0 - 500 ml
Colour :	Pale Yellow		Pale Yellow
Transparency :	Slight Turbid.		Clear
Reaction :	Acidic		4.6 - 8.0
Specific Gravity :	1.025		1.016 - 1.022
Sediment :	Present		
<u>Chemical Examination</u>			
Albumin :	Present (Faint Trace)		Absent
Sugar :	NIL		Absent
Acetone :	Absent		Absent
Bile Salts :	Absent		Absent
Bile Pigments :	Absent		Absent
Urobilogen :	Absent		Absent
Nitrites :	Absent		Absent
<u>Microscopic Examination</u>			
Red blood Cells :	2-3	/h.p.f	Absent
Pus Cells :	2-3	/h.p.f	Absent
Epithelial Cells :	1-2	/h.p.f	< 10.0
Amorphous :	Absent	/h.p.f	Absent
Bacteria :	Absent	/h.p.f	Absent
Crystals :	Absent	/h.p.f	Absent
Casts :	Absent	/h.p.f	Absent
Fungus :	Not seen	/h.p.f	Absent

Dr. Gayatri M. Mehta
M. D. (Patho)

Reg. No. G-32215

DR GAYATRI MEHTA
MD(PATHOLOGY)



DR. ANAND D. PARIKH
MD(PATHOLOGY)

AB ONLY (Entered by :GM Enter Date/Time:23/03/2024 7:18:00 PM) (Verify by :GM Verify Date/Time:23/03/2024 7:18:00 PM)

Vidhi Diagnostics | Pathology Department

L-86, Swatantra Senani Nagar, Opp. Akhbarnagar Petrol Pump, Nr. Akhbarnagar Circle, Nava-Vadaj, Ahmedabad - 380 013.

M. - Pathology : 8849893954, Ph. : 079-27621406, M. 98799 29406, 98250 09406, E-mail : vidhidiagnostics@gmail.com, Web. : www.vidhidiagnostics.com

Time (Pathology) : Mon. to Sat. 8.30 am to 8.00 pm, Sunday 9 am to 12 Noon

Pathology means science behind medicine

CT SCAN & CBCT FACILITY NOW AVAILABLE



Creating Life in Changes



Pathology Department

Patient's name : ANUPAMABEN KISHORBHAI MANHAR
Age/Sex : 51 Years/Female
Referred by : MEDI WHEEL
Collection Time : 11:16

Reg. ID : P-6863-23
Accession : 24706
Order Dt/time : 23/03/2024 11:16

Thyroid Function Test

Sample Type: Serum

Test Name	Result	Units	Biological Reference Interval
TOTAL T3 :	1.20	ng/ml	1.07 - 1.86
TOTAL T4 :	<u>4.95</u>	µg/dL	6.09 - 12.23
TSH(Ultra sensitive) :	<u>16.35</u>	µIU/mL	0.4001 - 4.049

Dr. Gayatri M. Mehta
M. D. (Patho)

Reg. No. G-32215

DR GAYATRI MEHTA
MD(PATHOLOGY)

DR. ANAND D. PARIKH
MD(PATHOLOGY)

LAB USE ONLY (Entered by : AP Enter Date/Time: 23/03/2024 5:41:00 PM) (Verify by : GM Verify Date/Time: 23/03/2024 6:09:00 PM)



Vidhi Diagnostics | Pathology Department

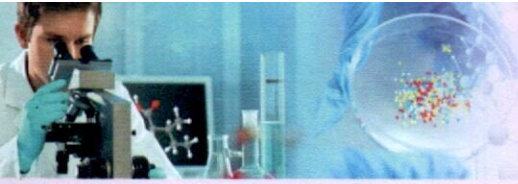L-86, Swatantra Senani Nagar, Opp. Akhbarnagar Petrol Pump, Nr. Akhbarnagar Circle, Nava-Vadaj, Ahmedabad - 380 013.

M. - Pathology : 8849893954, Ph. : 079-27621406, M. 98799 29406, 98250 09406, E-mail : vidhidiagnostics@gmail.com, Web. : www.vidhidiagnostics.com

Time (Pathology) : Mon. to Sat. 8.30 am to 8.00 pm, Sunday 9 am to 12 Noon

Pathology means science behind medicine

CT SCAN & CBCT FACILITY NOW AVAILABLE



Pathology Department



Patient's name : ANUPAMABEN KISHORBHAI MANHAR
Age/Sex : 51 Years/Female
Referred by : MEDI WHEEL
Collection Time : 11:16

Reg. ID : P-6863-23
Accession : 24706
Order Dt/time : 23/03/2024 11:16

Stool Examination

SAMPLE NOT RECEIVED

Dr. Gayatri M. Mehta
M. D. (Patho)

DR GAYATRI MEHTA. G-32215
MD(PATHOLOGY)

DR. ANAND D. PARIKH
MD(PATHOLOGY)

LAB USE ONLY (Entered by :GM Enter Date/Time:23/03/2024 7:19:00 PM) (Verify by :GM Verify Date/Time:23/03/2024 7:19:00 PM)



Vidhi Diagnostics | Pathology Department

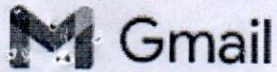L-86, Swatantra Senani Nagar, Opp. Akhbarnagar Petrol Pump, Nr. Akhbarnagar Circle, Nava-Vadaj, Ahmedabad - 380 013.

M. - Pathology : 8849893954, Ph. : 079-27621406, M. 98799 29406, 98250 09406, E-mail : vidhidiagnostics@gmail.com, Web. : www.vidhidiagnostics.com

Time (Pathology) : Mon. to Sat. 8.30 am to 8.00 pm, Sunday 9 am to 12 Noon

Pathology means science behind medicine

CT SCAN & CBCT FACILITY NOW AVAILABLE



vidhi diagnostics <vidhidiagnostics@gmail.com>

Health Check up Booking Confirmed Request(bobS13381),Package Code-PKG10000477, Beneficiary Code-285597

Mediwheel <wellness@mediwheel.in>
 To: vidhidiagnostics@gmail.com
 Cc: customercare@mediwheel.in

20 March 2024 at 17:18



Mediwheel
 ...Your wellness partner

011-41195959

Hi **VIDHI DIAGNOSTICS**,

The following booking has been confirmed. It is requested to honor the said booking & provide priority services to our client

Hospital Package Name : Mediwheel Full Body Health Checkup Female Above 40

Patient Package Name : Mediwheel Full Body Health Checkup Female Above 40

Hospital Address : L-86 Swatantra - Senani Nagar , Opp- Akhbarnagar Bus Terminals, New Wadaj , Ahmedabad -13

Contact Details : 9898973197

Appointment Date : 23-03-2024

Confirmation Status : Booking Confirmed

Preferred Time : 8:00am

Member Information		
Booked Member Name	Age	Gender
Anupama	51 year	Female

We request you to facilitate the employee on priority.

Thanks,
 Mediwheel Team
 Please Download Mediwheel App



You have received this mail because your e-mail ID is registered with **Arcofemi Healthcare Limited** This is a system-generated e-mail please don't reply to this message.



Dr. Dinesh S. Modh

M.D., D.M.R.E. (Radiodiagnosis)
Consultant Radiologist & Sonologist
Ex. Junior Lecturer, B.J. Medical College, Civil Hospital, A'bad.

VIDHI[®] DIAGNOSTICS

Creating Life in Images

<u>DATE:</u> 23/03/2024		
<u>NAME:</u> Anu Purnaban Kishorabhai' munhar		
<u>AGE:</u> 52 yr / female		
<u>MEDICAL EXAMINATION:-</u>		
<u>HEIGHT:</u> 159 cm	<u>WEIGHT:</u> 52 kg	
<u>BP:</u> 108 / 72 mmHg	<u>PULSE:</u> 72 Per min	
<u>SPO2:</u> 98	<u>TEMPERATURE:</u> $\text{\textcircled{N}}$	
<u>RS:</u> $\text{\textcircled{N}}$	<u>CVS:</u> $\text{\textcircled{N}}$	
ASYMTOMATIC		
<u>HISTORY:</u> NO H/O DM, HTN, Thyroid or TB		
<u>EYE CHECK-UP:-</u>	<u>RIGHT</u>	<u>LEFT</u>
<u>DISTANCE:</u>	Normal 6/6 with spectacles	Normal 6/6 with spectacles
<u>NEAR:</u>	N/6 with spectacles	N/6 with spectacles
<u>COLOR VISION:</u>	Normal	Normal
<u>DENTAL CHECK-UP:</u>	Normal	
<u>ADVISE/SHE IS MEDICALLY FIT</u>		

Dr. Vidhi D. Modh
MBBS
Reg. No. G-74540

Vidhi Diagnostics
L-86, Swatantra-Senani Nagar,
Nr. Akhbarnagar Bus Terminals
Nr. Akhbarnagar Circle,
New Wadaj, Ahmedabad-13.

ISO 9001:2015 Certified Diagnostics Center
Vidhi Imaging Center

L-86, Swatantra Senani Nagar, Opp. Indian Oil Petrol Pump, Akhbarnagar Circle, Nava Vadaj, Ahmedabad - 380 013.

Phone : (Radiology) 079-2762 1406 | M. 98799 29406, 98250 09406 | Time (Radiology) : Mon. to Sat. 9 am to 2 pm, 5 to 9 pm, Sunday 9 am to 12 Noon
E-mail : vidhidiagnostics@gmail.com, Website : www.vidhidiagnostics.com

Multislice CT Scan | CBCT-Dental Scan | Live 3D-4D Sonography | Colour Doppler | Echo Cardiography | Interventional Radiology | Maxillofacial Radiology | Fetal Medicine
Digital X-Ray | Digital Mammography | Digital OPG/TMJ | ECG/TMT/PFT/EEG/EMG | Audiometry | Pathology Laboratory | Health Check Up Plans | Pre Employment Check Up

CT SCAN & CBCT FACILITY NOW AVAILABLE

23-03-2024 09:26:09

<< Analysis Result >>

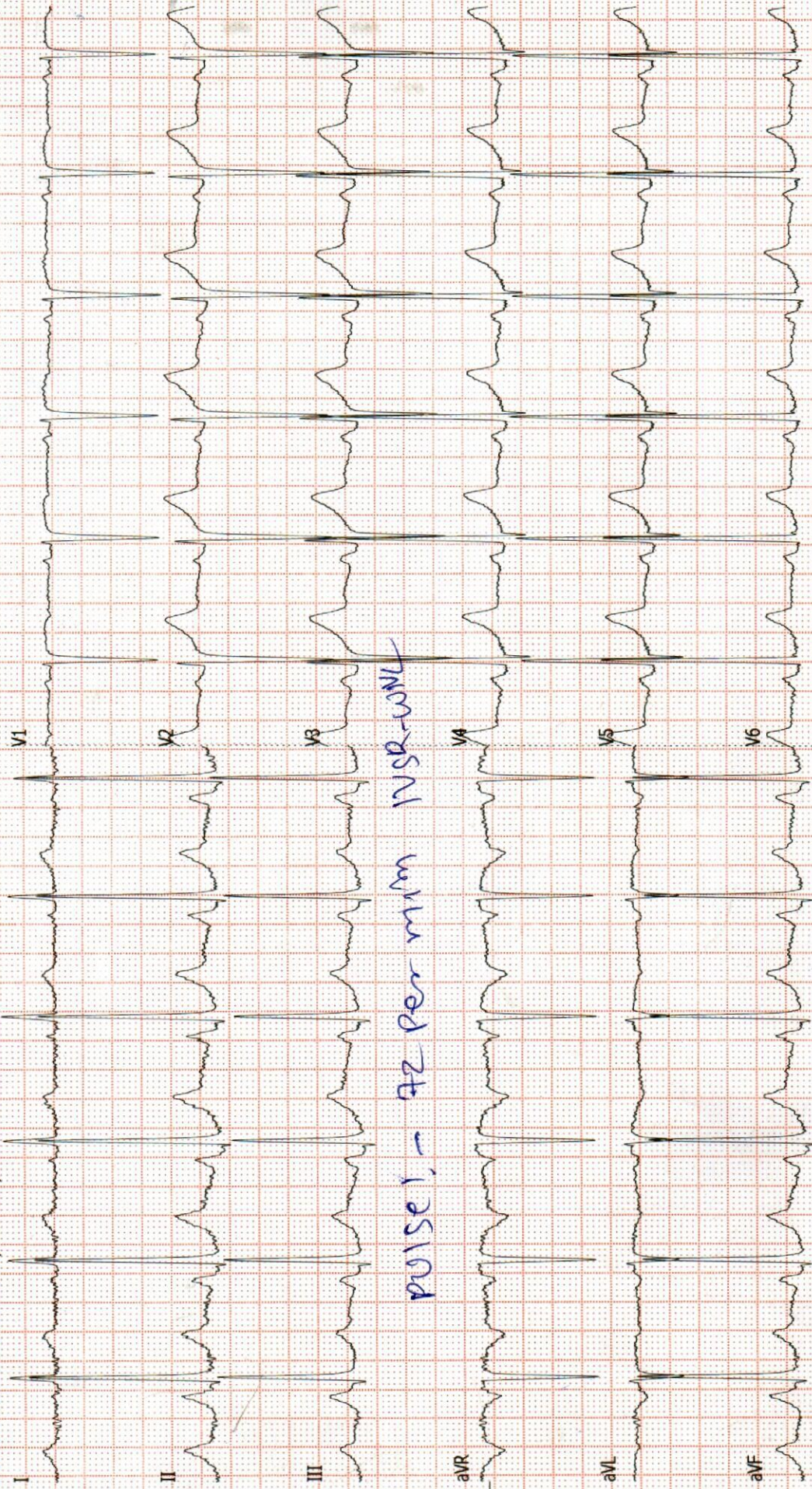
Wahi Diagnostics
 Sinus rhythm, Swatantra-Senani Nagar,
 Opp. Akhbarnagar Bus Terminal,
 Nr. Aulibemagar Circle,
 New Wadaj, Ahmedabad-13.

HR : 73 bpm
 PR : 148 ms
 QRS : 82 ms
 QT/QTc : 402/442 ms
 P/QRS/T : 80/74/71 deg.
 RV5/SV1 : 1.174/-0.911 mv
 RV5+SV1 : 2.085 mv

Dr. Animesh Anand
 MBBS, D Cardiol
 Reg. No.: G-45946

Need to be confirmed by doctor. Doctor Name: _____

0.67Hz 35Hz AC 50Hz 25 mm/s 20 mm/mv



Dr. Dinesh S. Modh

M.D., D.M.R.E. (Radiodiagnosis)

Consultant Radiologist & Sonologist

Ex. Junior Lecturer, B.J. Medical College, Civil Hospital, A'bad.



Patient's name: ANUPAMA K MANHAR
Reg. ID : R-14833-23
Referred by : Dr. MEDIWHEEL

Age/Sex : 51 Years/Female
Accession : 24668
Date : 23/03/2024

2D- ECHO REPORT

FINAL CONCLUSION:

LV IS NORMAL SIZE. GOOD LV SYSTOLIC FUNCTION NO RWMA.
LVEF - 60%. NO CONCENTRIC LVH.
NORMAL LV COMPLIANCE.
LA IS NORMAL SIZE. NO LA CLOT.
RV IS NORMAL SIZE. GOOD RV SYSTOLIC FUNCTION.
RA IS NORMAL SIZE.
MITRAL VALVE IS NORMAL. NO MS. TRIVIAL MR . NO MVP.
AORTIC VALVE IS NORMAL. NO AS. NO AR.
TRICUSPID VALVE IS NORMAL. NO TR. RVSP-22 mmHg. NO PAH.

NO CLOT, NO VEGETATION, NO PERICARDIAL EFFUSION.

DIMENSIONS:

AORTA	2.5 C.M
LEFT ATRIUM	2.7 C.M
LVDD	4.6 C.M.
IVSD	1.0 C.M
PWD	1.0 C.M
LVDS	2.6 C.M..

COLOUR DOPPLER FINDING:

STRUCTURE	VELOCITY m/sec
	Max
PULMONARY VALVE	0.8
MITRAL VALVE	E : 0.8 A: 0.5
AORTIC VALVE	1.2

Dr. Avinash Bhaskar
M.D.S. in Cardio
Reg. No.: G-45946

DR AVINASH BHASKAR
CLINICAL CARDIOLOGIST
9924836431

Vidhi Diagnostics
L-86, Swatantra-Senani Nagar,
Nr. Akhbarnagar Bus Terminals
New Wadaj, Ahmedabad-13.

ISO 9001:2015 Certified Diagnostics Center

Vidhi Imaging Center

L-86, Swatantra Senani Nagar, Opp. Indian Oil Petrol Pump, Akhbarnagar Circle, Nava Vadaj, Ahmedabad - 380 013.

Phone : (Radiology) 079-2762 1406 | M. 98799 29406, 98250 09406 | Time (Radiology) : Mon. to Sat. 9 am to 2 pm, 5 to 9 pm, Sunday 9 am to 12 Noon
E-mail : vidhidiagnostics@gmail.com, Website : www.vidhidiagnostics.com

Multislice CT Scan | CBCT-Dental Scan | Live 3D-4D Sonography | Colour Doppler | Echo Cardiography | Interventional Radiology | Maxillofacial Radiology | Fetal Medicine
Digital X-Ray | Digital Mammography | Digital OPG/TMJ | ECG/TMT/PFT/EEG/EMG | Audiometry | Pathology Laboratory | Health Check Up Plans | Pre Employment Check Up

CT SCAN & CBCT FACILITY NOW AVAILABLE

Dr. Dinesh S. Modh

M.D., D.M.R.E. (Radiodiagnosis)

Consultant Radiologist & Sonologist

Ex. Junior Lecturer, B.J. Medical College, Civil Hospital, A'bad.



Patient's name : ANUPAMA K MANHAR
Reg. ID : R-14833-23
Referred by : Dr. MEDIWHEEL

Age/Sex : 51 Years/Female
Accession : 24668
Date : 23/03/2024

DIGITAL MAMMOGRAPHY

Digital mammography was done on Siemens mammomat-3000.

Reason for exam: - Screening.

Bilateral digital cranio-caudal and medio-lateral oblique views were taken.
The breast tissue is homogeneously dense with fibro-fatty tissue on both sides.
No masses, no architectural distortion, no suspicious calcifications, no asymmetries or other abnormalities are seen.
No e/o radio-opaque or radiolucent mass lesion is seen.
No e/o skin thickening is seen.
Nipple and sub-areolar tissue appear normal.
Axillary tail appears normal.

USG:-Normal.

Assessment:-Negative (BI-RADS category-1)

BI-RADS category

- 0- incomplete
- 1- Negative
- 2- Benign
- 3- Probably benign
- 4- Suspicious abnormality.
- 5- Highly suggestive of malignancy
- 6- Known biopsy-proven malignancy.

The false negative mammography is approximately 10%. Management of palpable abnormality must be based upon clinical grounds.

Thanks for reference.

Dr. Dinesh S. Modh
M.D. DMRE (Radiodiagnosis)
G-2695

DR DINESH S. MODH

M.D. DMRE(RADIODIAGNOSIS)

Vidhi Diagnostics
L-86, Swatantra-Senani Nagar,
Nr. Akhbarnagar Bus Terminals
Nr. Akhbarnagar Circle,
New Wadaj, Ahmedabad-13.

ISO 9001:2015 Certified Diagnostics Center

Vidhi Imaging Center

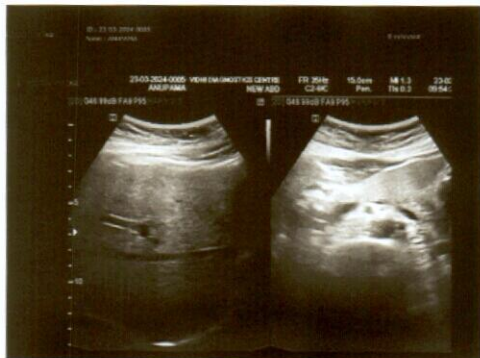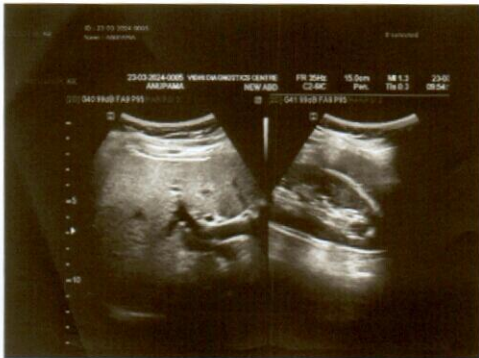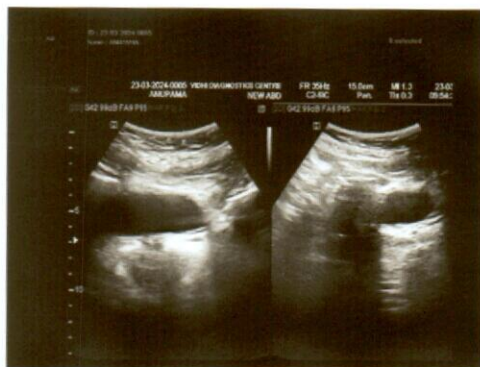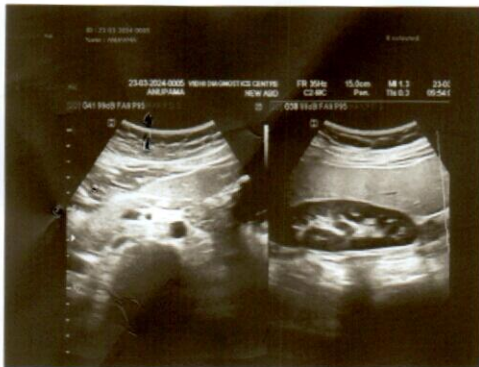L-86, Swatantra Senani Nagar, Opp. Indian Oil Petrol Pump, Akhbarnagar Circle, Nava Vadaj, Ahmedabad - 380 013.

Phone : (Radiology) 079-2762 1406 | M. 98799 29406, 98250 09406 | Time (Radiology) : Mon. to Sat. 9 am to 2 pm, 5 to 9 pm, Sunday 9 am to 12 Noon

E-mail : vidhidiagnostics@gmail.com, Website : www.vidhidiagnostics.com

Multislice CT Scan | CBCT-Dental Scan | Live 3D-4D Sonography | Colour Doppler | Echo Cardiography | Interventional Radiology | Maxillofacial Radiology | Fetal Medicine
Digital X-Ray | Digital Mammography | Digital OPG / TMJ | ECG / TMT / PFT / EEG / EMG | Audiometry | Pathology Laboratory | Health Check Up Plans | Pre Employment Check Up

CT SCAN & CBCT FACILITY NOW AVAILABLE



Dr. Dinesh S. Modh

M.D., D.M.R.E. (Radiodiagnosis)

Consultant Radiologist & Sonologist

Ex. Junior Lecturer, B.J. Medical College, Civil Hospital, A'bad.



Patient's name : ANUPAMA K MANHAR
Reg. ID : R-14833-23
Referred by : Dr. MEDIWHEEL

Age/Sex : 51 Years/Female
Accession : 24668
Date : 23/03/2024

X-RAY CHEST (PA VIEW)

Both lung fields appear normal.
No e/o consolidation or cavitations is seen.
Both costo-phrenic angles appear clear.
Cardiac size is within normal limits.
Both domes of diaphragm appear normal.
Bony thoracic cage appears normal.

Thanks for reference.

Dr. Dinesh S. Modh
MD DMRE (Radiodiagnosis)
R-14833-23
[Signature]
DR DINESH S. MODH
M.D. DMRE(RADIODIAGNOSIS)

Vidhi Diagnostics
L-86, Swatantra-Senani Nagar,
Nr. Akhbarnagar Bus Terminal
Nr. Akhbarnagar Circle,
New Wadaj, Ahmedabad-13.

ISO 9001:2015 Certified Diagnostics Center

Vidhi Imaging Center

L-86, Swatantra Senani Nagar, Opp. Indian Oil Petrol Pump, Akhbarnagar Circle, Nava Vadaj, Ahmedabad - 380 013.

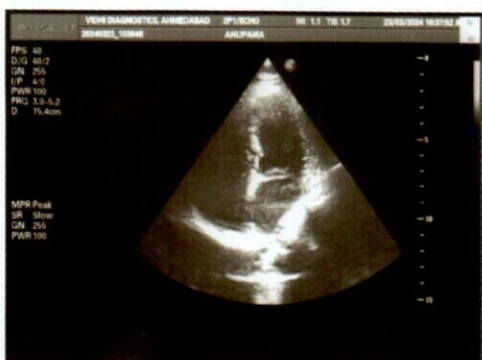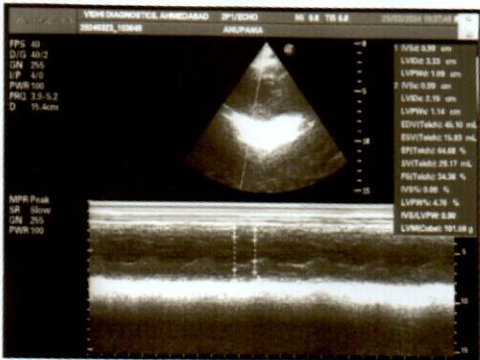
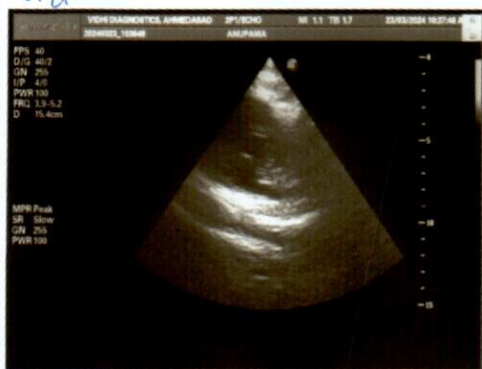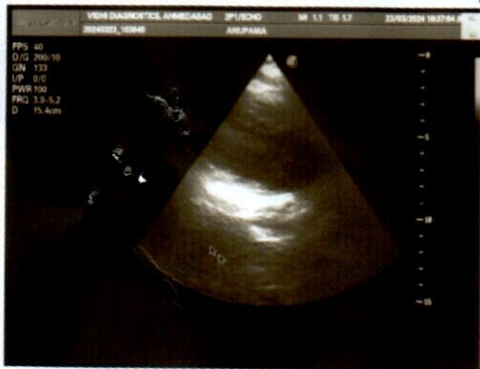Phone : (Radiology) 079-2762 1406 | M. 98799 29406, 98250 09406 | Time (Radiology) : Mon. to Sat. 9 am to 2 pm, 5 to 9 pm, Sunday 9 am to 12 Noon

E-mail : vidhidiagnostics@gmail.com, Website : www.vidhidiagnostics.com

Multislice CT Scan | CBCT-Dental Scan | Live 3D-4D Sonography | Colour Doppler | Echo Cardiography | Interventional Radiology | Maxillofacial Radiology | Fetal Medicine
Digital X-Ray | Digital Mammography | Digital OPG / TMJ | ECG / TMT / PFT / EEG / EMG | Audiometry | Pathology Laboratory | Health Check Up Plans | Pre Employment Check Up

CT SCAN & CBCT FACILITY NOW AVAILABLE

AmUpd mel



Dr. Dinesh S. Modh

M.D., D.M.R.E. (Radiodiagnosis)

Consultant Radiologist & Sonologist

Ex. Junior Lecturer, B.J. Medical College, Civil Hospital, A'bad.



Patient's name : ANUPAMA K MANHAR
Reg. ID : R-14833-23
Referred by : Dr. MEDIWHEEL

Age/Sex : 51 Years/Female
Accession : 24668
Date : 23/03/2024

USG ABDOMEN

LIVER: - Liver appears normal in size & show normal echotexture. No evidence of diffuse or focal lesion is seen. Intrahepatic biliary radicals appear normal. Portal vein and CBD appear normal. No e/o calculus is seen in bile duct.

GALL BLADDER: - Gall bladder is not seen(h/o operation).

SPLEEN: - Spleen appears normal in size & shows normal echotexture. No evidence of diffuse or focal lesion is seen.

PANCREAS: - Pancreas appears normal size and echopattern. No e/o diffuse or focal lesion is seen. Main pancreatic duct appears normal.

KIDNEY: - Both Kidneys appear normal in size & echotexture.

No e/o calculus or hydronephrosis or hydroureter is seen in either side.

Cortico-medullary differentiation is maintained on either side.

Both suprarenal regions appear normal.

RIF & BOWEL LOOPS (By high frequency probe):-Normal.

No evidence of pre & para aortic lymphadenopathy is seen.

No evidence of free fluid is seen in abdomen.

No evidence of dilated or thickened bowel loops is seen.

Urinary bladder: - appears normal. No e/o calculus or mass lesion is seen in bladder.

Uterus is post-menopausal state.

Both adnexal regions appear normal.

No e/o free fluid is seen in pouch of Douglas.

Thanks for reference.

Dr. Dinesh S. Modh

M.D. DMRE (Radiodiagnosis)

DR DINESH S. MODH
M.D. DMRE (RADIO DIAGNOSIS)

Vidhi Diagnostics
L-86, Swatantra-Senani Nagar,
Nr. Akhbarnagar Bus Terminals
Nr. Akhbarnagar Circle,
New Wadaj, Ahmedabad-13.

ISO 9001:2015 Certified Diagnostics Center

Vidhi Imaging Center

L-86, Swatantra Senani Nagar, Opp. Indian Oil Petrol Pump, Akhbarnagar Circle, Nava Vadaj, Ahmedabad - 380 013.

Phone : (Radiology) 079-2762 1406 | M. 98799 29406, 98250 09406 | Time (Radiology) : Mon. to Sat. 9 am to 2 pm, 5 to 9 pm, Sunday 9 am to 12 Noon
E-mail : vidhidiagnostics@gmail.com, Website : www.vidhidiagnostics.com

Multislice CT Scan | CBCT-Dental Scan | Live 3D-4D Sonography | Colour Doppler | Echo Cardiography | Interventional Radiology | Maxillofacial Radiology | Fetal Medicine
Digital X-Ray | Digital Mammography | Digital OPG/TMJ | ECG/TMT/PFT/EEG/EMG | Audiometry | Pathology Laboratory | Health Check Up Plans | Pre Employment Check Up

CT SCAN & CBCT FACILITY NOW AVAILABLE