

DAKSH HOSPITAL

396 - 397, Gandhi Nagar, Scheme No. 8, ALWAR -301001

Ref. No.

Date.....

MEDICAL EXAMINATION REPORT

Mediwheel (BOB)

Name: Mrs. Sangeeta Bansal

Age: 30 yrs

Sex: Female

Date: 22/03/2024

General Physical Examination

Height : 161cm
Pulse : 80/mt
Respiration : 18/mt

Weight : 49.60 Kg
BP : 97/60 mm/hg
BMI : 19.1 kg/m²

Systemic Exam:-

NORMAL

Dental Check up :-

NORMAL

Eye check-up :-

NORMAL

Skin Check up:-

NORMAL

ENT Check up:-

NORMAL

Gynae Check up:-

MN-3/30/2024 on - P, FchND
LMP 1 month LD-10mth.

Pap
Pap smear refused

Impression:-

NORMAL

Recommendation:-

ND

Dr. Mukesh Kumar Gupta
MD Gen. Medicine
Reg. No 5423/16262

डॉ० मुकेश गुप्ता
M.D.F.C.C.S.
फिजिशियन एवं मधुमेह रोग विशेषज्ञ
दक्ष हॉस्पिटल, अलवर
रजि० नं०-5423/16262

Results

Run Date 22/03/2024 10:58:25 AM

Operator DAKSH

Last Name

Sample ID 4

First Name MRS SANGEETA

Department

Gender Female

Age

Physician DR. MUKESH GUPTA M.D

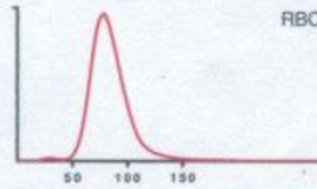
Patient ID AUTO_PID20413

Type Woman

Date of birth

Sample comments

			Range
RBC	3.92	10 ⁶ /μL	3.80 - 5.50
HGB	10.8	g/dL	11.5 - 15.2
HCT	33.0	%	35.0 - 46.0
MCV	84.1	μm ³	77.0 - 97.0
MCH	27.7	pg	26.0 - 34.0
MCHC	32.9	g/dL	32.0 - 35.0
RDW-CV	17.4	%	11.0 - 17.0
RDW-SD	56.2	μm ³	37.0 - 49.0



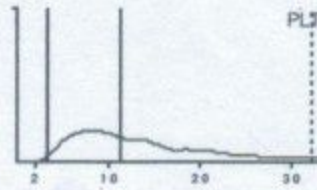
Recommended actions

Slide review

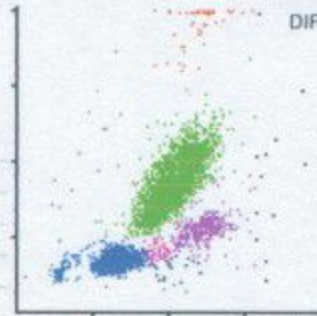
Susp. Pathologies

Anisocytosis
Macroplatelets

			Range
PLT	154	* 10 ³ /μL	150 - 450
PCT	0.20	%	0.15 - 0.40
MPV	12.8	H* μm ³	8.0 - 11.0
PDW	25.3	H* μm ³	11.0 - 22.0
P-LCC	79	10 ³ /μL	44 - 140
P-LCR	51.0	h %	18.0 - 50.0



			Range
WBC	8.97	10 ³ /μL	3.50 - 10.00
	#	Range	%
NEU	5.09	1.60 - 7.00	57.0
LYM	3.52	1.00 - 3.00	39.3
MON	0.15	0.20 - 0.80	1.7
EOS	0.09	0.00 - 0.50	1.0
BAS	0.09	0.00 - 0.15	1.0
LIC	0.03	0.00 - 0.10	0.3



[Signature]

Dr. R.S. GUPTA
MD (Pathology) (MAHE)
RMC No. 7924/19778

Date :- 22/03/2024

Name :- MRS. SANGEETA BANSAL

Age & Sex :- 30 Yrs/Female

Refd. :- Dr Mukesh Gupta M.D.

	TEST NAME	RESULT	REFERENCE RANGE
	ESR	10	00 -20 mm/hrs
	Blood Group & Rh Factor	A* POSITIVE	
	HbA1C	4.83	4 - 5.6%
	Blood Sugar (R)	84.3	< 150 mg/dl
	Blood Sugar (PP)	-	< 140 mg/dl
	Urine Sugar (F)	NIL	-
	Urine Sugar (PP)	NIL	-
LIVER	S.Bilirubin Total	1.00	0.30 - 1.20 mg/dl
	S.Bilirubin Direct	0.30	0.10 - 0.30 mg/dl
	S.Bilirubin Indirect	0.70	0.30 - 0.90 mg/dl
	S.G.O.T.	19	u/l
	S.G.P.T.	25	u/l
	S.Alk. Phosp.	197	u/l
	G.G.T.	32	5 -10 u/l
	Total Protein	6.8	6.5 - 8.5 gm/dl
	Albumin	3.6	3.8 - 5.4 gm/dl
	Globulin	3.2	2.3 - 3.5 gm/dl
	AVG Ratio	1.1	-
	AST/ALT Ratio	0.7	-
KIDNEY	Blood Urea	25.1	15 -45 mg/dl
	S.Creatinine	0.8	0.60 - 1.30 mg/dl
	BUN	21.1	6 -24 mg/dl
	S.Uric Acid	5.3	M 3.1 - 7.0, F 2.5 - 5.6 mg/dl
	BUN/Creatinine Ratio	23.1	-
LIPID PROFILE	Total Cholesterol	125.1	Up to 200 mg/dl
	S.HDL	40.1	30 - 70 mg/dl
	S.LDL	59.1	Up to 170 mg/dl
	S.VLDL	26.1	5.0 - 40 mg/dl
	S. Triglycerides	130.1	Up to 170 mg/dl
	LDL/HDL Ratio	1.4	-
THYROID	Total Cholesterol/ HDL Ratio	3.1	-
	T3	94.1	1.2 - 2.8 nmol/L
	T4	4.5	77 -155 nmol/L
	TSH	1.7	0.30 - 5.0 mU/L

URINE EXAMINATION

Microscopic Examination :

General/Chemical Examination:	Colour	Pale Yellow	RBC	Absent
	Reaction	Acidic	WBC	2 - 3
	Specific Gravity	QNS	Epithelial Cells	1-2
	Appearance	Clear	Cast	Absent
	Albumin	Nil	Crystal	Absent
	Sugar	Nil	Spermatozoa	Absent
			Amorphous Sediments	Absent
			Other	Absent

X-RAY CHEST

NORMAL STUDY

STOOL EXAMINATION

Microscopic Examination :

General/ Chemical Examination:	Colour	-	RBC	-
	Consistency	-	WBC	-
	PH	-	Ova & Parasites	-
	Reducing Substances	-		

Dr. R.S. GUPTA
MD (Pathology) (MAHE)
Doctor
RMC No. 7924/19778

TECHNOLOGIST

All investigation have their own limitations regarding the sensitivity & specificity of individual assay procedures, Isolated laboratory investigations never confirm the final diagnosis of the disease. They only help in arriving at a diagnosis in conjunction with clinical presentation and other related investigations. Report is not valid for medico-legal purpose subject to ALWAR jurisdiction only.



दक्ष हॉस्पिटल

396, गाँधी नगर स्कीम नं.8, अलवर (राज०) ☎ 0144-2703340

Sonography / 2D Echo Cardiography / Doppler Report

2D/ ECHO REPORT

Name: - Mrs Sangeeta Bansal

Age: - 30 Yrs

Date: - 22-Mar-24

Reg. No.: - Alw/2009/04
BOB health checkup

PROCEDURES:

M-MODE/2D/DOPPLER/COLOR/CONTRAST B.A.S. M²

MEASUREMENT:		DOPPLER:					
AOD	14	NORMAL (20- 37mm)	MV	0.7	NORMAL (cm/sec.) (0.8- 1.3)	MR	No
LA	22	(19- 40mm)	AV	1.4	(1.2- 1.8)	AR	No
AVO	21	(12- 25mm)	TV	0.6	(0.3- 0.8)	TR	No
RVDd.	9	(03- 09mm)	PV	0.8	(0.7- 1.1)	PR	No
LVDd	44.6	(37- 56mm)	MITRAL VALVE-				
LVDs	28.5	(22- 40mm)	AML				Normal
IVS d	7	(06- 12mm)	PML				Normal
IVS s	9.7		AORTIC VALVE				Normal
PWd	3.9	(05- 10mm)	TV & PV are normal.				
LV FUNCTION							
M- E- S Separation		<0.9cm					
Minor		24.42%					
LV Ejection Fraction	66%	65 +/- 12%					

LV WALL MOTION: NO RWMA
ALL CARDIAC CHAMBERS ARE NORMAL
ALL VALVES ARE NORMAL
NO CLOT, VEGETATION, PERICARDIAL EFFUSION

FINAL DIAGNOSIS: NORMAL STUDY

Adv: - Follow up/ review at higher center for confirmation

Note:- Please Correlate clinically. Due to technical limitations as well as inaccuracies inherent in the laboratory and statistical analysis of biological process. Diagnostic accuracy of ECHO is up to 95% only.
Report is not valid for medico-legal purpose.


DR. MUKESH GUPTA
Dr. Mukesh Kumar Gupta
Physician & Sonologist
RM 5423/16262



भ्रूण लिंग परीक्षण की शिकायत
104 टोल फ्री सेवा पर भी की
जा सकती है।

भ्रूण लिंग परीक्षण की शिकायत 104 टोल फ्री सेवा पर भी की जा सकती है।



दक्ष हॉस्पिटल

396, गाँधी नगर स्कीम नं.8, अलवर (राज०) ☎ 0144-2703340

Sonography / 2D Echo Cardiography / Doppler Report

NAME :- MRS SANGEETA BANSAL/F/30 YRS

22-Mar-24

BOB HEALTH CHECKUP

U.S.G. OF ABDOMEN & PELVIS

LIVER

Liver is normal in size shape with normal echo-texture. Intra hepatic biliary radicals Are not dilated. No evidence of focal or diffuse lesion.

GALL BLADDER

Gall bladder is normal.

PANCREAS

Pancreas is normal in size, shape & echo-texture. No evidence of focal or diffuse lesion. MPD not dilated.

SPLEEN

8.4 cm in size with normal shape & echo- texture. Spleen vein is normal. No evidence of focal or diffuse lesion

KIDNEY

Both kidneys are normal.

URINARY BLADDER

UB is normal.

UTERUS:

Uterus is normal in size (7.5x3.7x5.1cm) with homogenous echo-texture. Endometrial 7.7 mm in thickness & echo genicity

OVARIES:

Both ovaries are normal.

Minimum fluid in POD.

Advice- follow up/ hormonal study review at higher center for confirmation

Please correlate clinically. USG accuracy is 95 % due to technical limitations as well as inaccuracies inherent in the laboratory and statistical analysis biological process.
This report is not valid for medico-legal cases


DR. MUKESH GUPTA
Dr. Mukesh Kumar Gupta
Physician & Sonologist
RM 5423/16262



"भ्रूण लिंग परीक्षण की शिकायत 104 टोल फ्री सेवा पर भी की जा सकती है"

भ्रूण लिंग परीक्षण की शिकायत 104 टोल फ्री सेवा पर भी की जा सकती है।

11-02-2024 12:32:39 PM

ID: 3

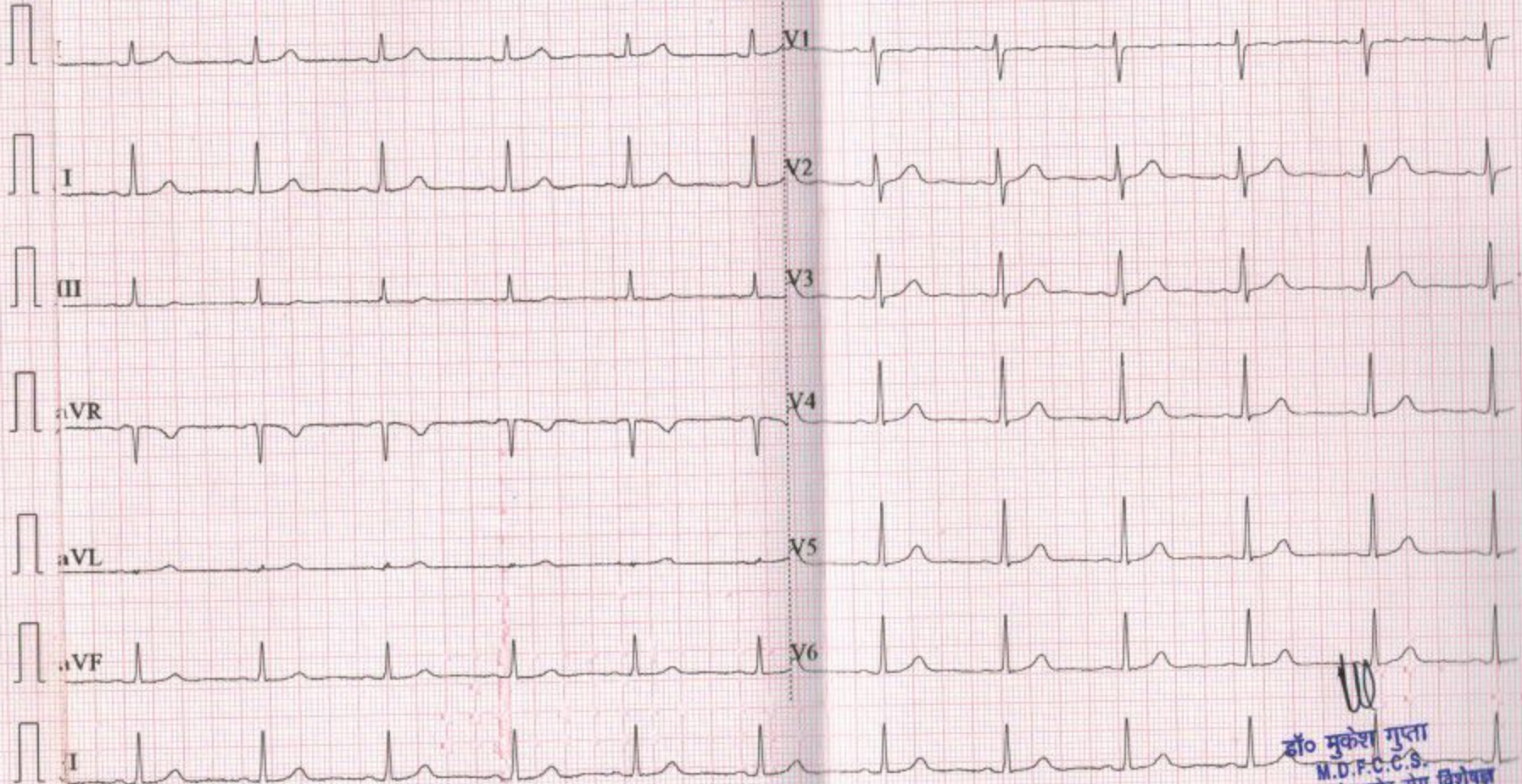
Female Years

HR : 70 bpm
 P : 97 ms
 PR : 143 ms
 QRS : 71 ms
 QT/QTc : 371/402 ms
 P/QRS/T : 36/55/33 °
 RV5/SV1 : 1.083/0.567 mV

Diagnosis Information:

Sinus Rhythm
Normal ECG

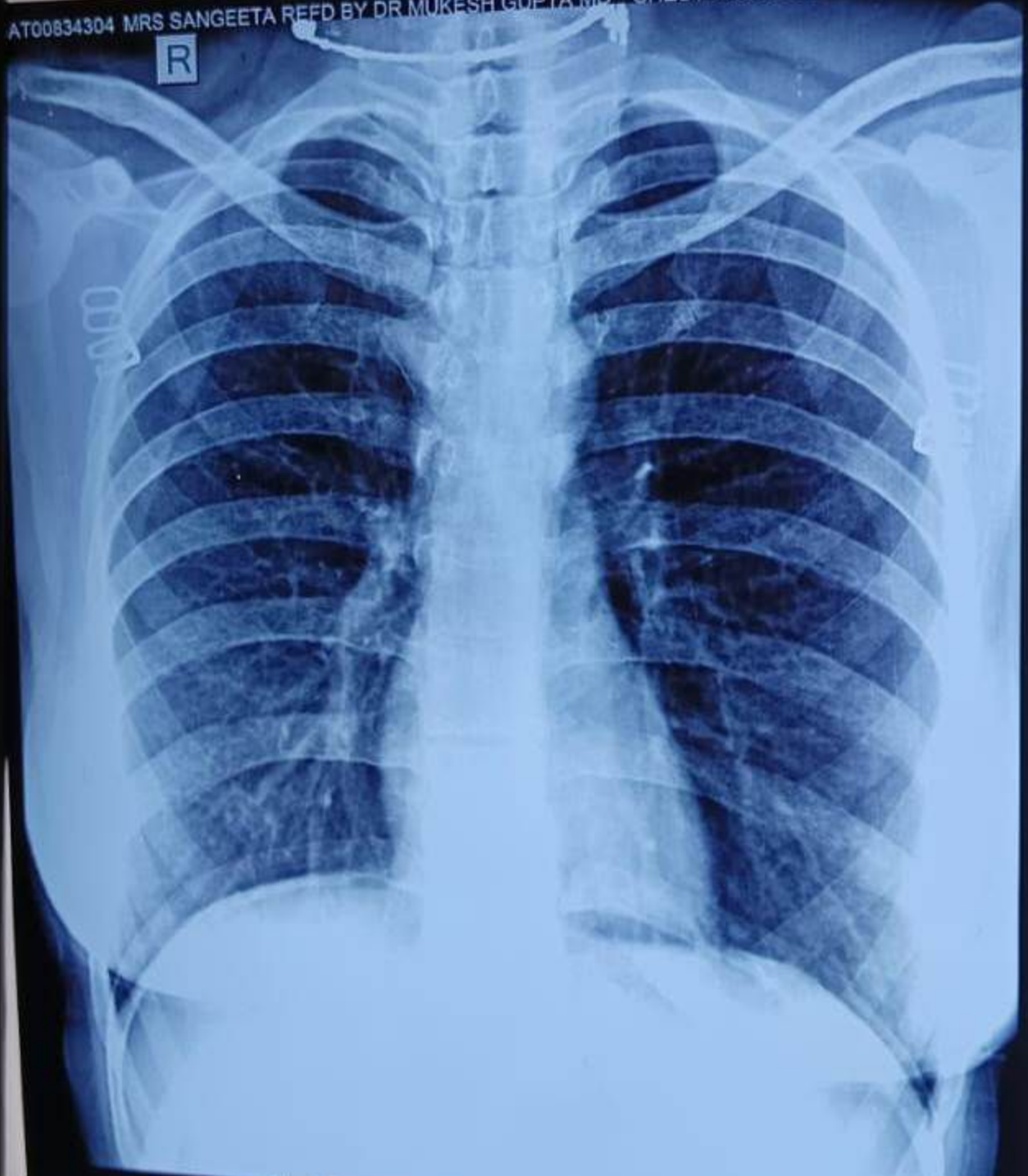
Report Confirmed by:



डॉ० मुकेश गुप्ता
 M.D.F.C.C.S.
 फिजिशियन एवं मधुमेह रोग विशेषज्ञ
 दक्ष हॉस्पिटल, अलवर
 रजि० नं०-5423/16282

AT00834304 MRS SANGEETA REED BY DR MUKESH GUPTA MD CHEST 22.03.2024

R



VIJAY DIAGNOSTIC CENTRE 1/16 KALA KUAN .ALWAR

208