

PUROHIT, PRAJITA
Female

29-Mar-24 10:43:35 AM

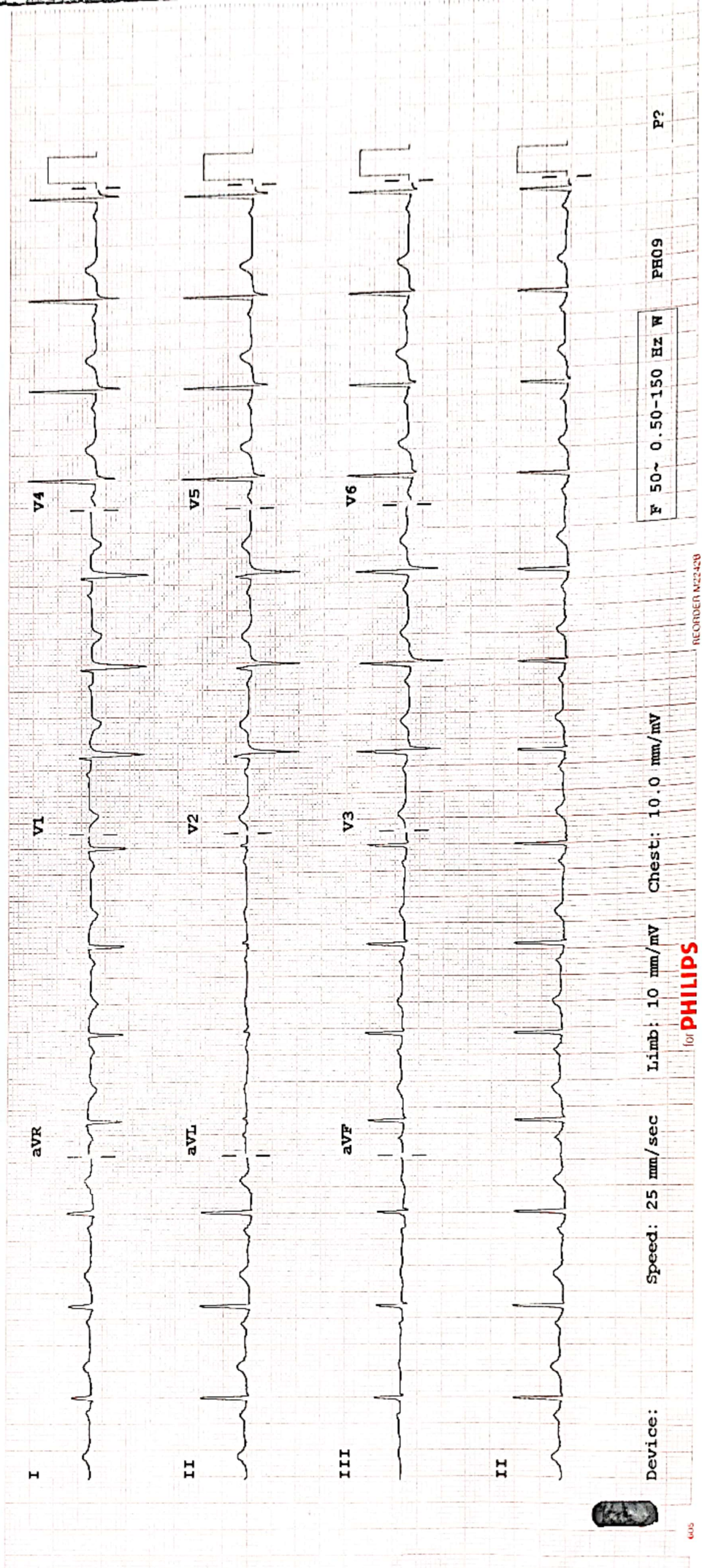
Rate 85

PR 148
QRSD 82
QT 360
QTc 428

--AXIS--

P 35
QR 58
T 31

12 Lead; Standard Placement





Savita
Superspecialty Hospital
(A Unit of Solace Healthcare Pvt. Ltd.)

Parivar Char Rasta, Waghodia-Dabhoi Ring Road, Vadodara-390019
0265-2578844 / 2578849 63596 88442
mh@savitahospital.com savitahospital.com



2D-ECHOCARDIOGRAPHY AND COLOR DOPPLER REPORT

NAME: PRAJITA PUROHIT

DATE: 29/03/2024

AGE/SEX: 28 YRS/FEMALE

REF BY: DIRECT

OBSERVATION:

- NORMAL LV SIZE AND NORMAL LV SYSTOLIC FUNCTION. LVEF = 60% (VISUAL).
- NO RWMA AT REST.
- NORMAL LV DIASTOLIC DYSFUNCTION.
- TRIVIAL MR. NO MS.
- NO AR. NO AS.
- MILD TR. NO PAH. RVSP : 26 MMHG.
- NORMAL SIZED LA, RA & RV WITH NORMAL RV SYSTOLIC FUNCTION.
- NORMAL SIZED MPA, RPA & LPA.
- INTACT IAS & IVS.
- NO E/O INTRACARDIAC CLOT/VEGETATION/PE.
- NORMAL IVC.
- NORMAL PERICARDIUM.

LA: 30MM

AO: 28MM


IVS: 10/12MM

LVPW: 10/13MM

LVID: 43/22MM

CONCLUSION:

- NORMAL LV/RV SIZE AND SYSTOLIC FUNCTION.
- NO RWMA AT REST.
- LVEF = 60% (VISUAL).


DR. NIRAV BHALANI
[CARDIOLOGIST]

DR. ARVIND SHARMA
[CARDIOLOGIST]





PATIENT NAME: PRAJITA PUROHIT	
AGE/SEX: 28 YRS/F	DATE: Friday, 29 March 2024

CHEST X-RAY (PA)

Both lung fields appear normal.

Both hila appear normal

Bilateral costo-phrenic angles appear grossly clear

Mediastinum and cardiac shadow appear normal

Bony thorax appears unremarkable

No evidence of free gas under domes of diaphragm

IMPRESSION:

- NO SIGNIFICANT ABNORMALITY NOTED IN LUNG FIELDS
- NORMAL CARDIAC SHADOW


DR SHARAD RUNGTA (MD & DNB)
CONSULTANT RADIOLOGIST

Not all pathologies can be detected on ultrasound in each scan. Further radiographic evaluation is suggested if required.



Savita
Superspeciality Hospital
(A Unit of Solace Healthcare Pvt. Ltd.)

Parivar Char Rasta, Waghodia Dabhoi Ring Road, Vadodara-390019
0265-2578844 / 2578849 63596 88442
mh@savitahospital.com savitahospital.com



PATIENT NAME: PRAJITA PUROHIT

AGE/SEX: 28 YRS/F

DATE: Friday, 29 March 2024

ULTRASOUND OF ABDOMEN & PELVIS

LIVER appears normal in size and shows normal parenchymal echogenicity. No evidence of focal lesion. No evidence of dilated IHBR or portal vein. CBD appears normal.

GALL BLADDER is distended. No evidence of abnormal wall thickening or any significant calculus within.

PANCREAS appears normal. MPD is WNL.

SPLEEN appears normal in size and shows normal parenchymal echogenicity. No evidence of focal lesion.

BOTH KIDNEYS appear normal in size, shape and position.

Show normal cortical echogenicity. Corticomedullary differentiation is maintained. No evidence of calculus or hydronephrosis on either side.

URINARY BLADDER is partially full. No evidence of abnormal wall thickening or any significant calculus within.

UTERUS appears normal in size and position. CET is 5.6 mm WNL. No evidence of focal lesion noted. Bilateral ovaries appear normal in size. No evidence of focal or obvious mass lesion noted.


BOWEL LOOPS appear normal and show normal peristalsis.

No evidence of LYMPHADENOPATHY noted.

No evidence of ASCITES noted.

IMPRESSION:

- NO SIGNIFICANT ABNORMALITY AT PRESENT SCAN.


DR SHARAD RUNGTA (MD & DNB)
CONSULTANT RADIOLOGIST

Not all pathologies can be detected on ultrasound in each scan. Further radiographic evaluation is suggested if required.





Savita

Superspeciality Hospital
(A Unit of Solace Healthcare Pvt. Ltd.)

Parivar Char Rasta, Waghodia Dabhoi Ring Road, Vadodara-390019
0265-2578844 / 2578849 | mh@savitahospital.com | savitahospital.com

Patient Name : Prajita Vivekkumar Purohit	Sample No. : 20240314836
Patient ID : 20240309240	Visit No. : OPD20240329432
Age / Sex : 28y/Female	Call. Date : 29/03/2024 09:20
Consultant : DR SAURABH JAIN	S. Call. Date : 29/03/2024 13:24
Ward :	Report Date : 29/03/2024 17:02

CBC, ESR

Investigation	Result	Normal Value
Hemoglobin :	12.5 gm/dl	12.5 to 16.0 gm/dl
P.C.V. :	39.2 %	37.0 to 47.0 %
M.C.V. :	80.7 fL	78 to 100 fL
M.C.H. :	25.7 pg [L]	27 to 31 pg
M.C.H.C. :	31.9 g/dl [L]	32 to 36 g/dl
RDW :	11.8 %	11.5 to 14.0 %
RBC Count :	4.86 X 10 ⁶ / cumm	4.2 to 5.4 X 10 ⁶ / cumm
Polymorphs :	66 %	38 to 70 %
Lymphocytes :	30 %	15 to 48 %
Eosinophils :	2 %	0 to 6 %
Monocytes :	2 % [L]	3 to 11 %
Basophils :	0 %	0.0 to 1.0 %
Total :	100	< 100 > 100
WBC Count :	6700 /cmm	4000 to 10000 /cmm
Platelets Count :	434000 /cmm	1,50,000 to 4,50,000 /cmm
ESR - After One Hour :	20 mm/hr	1 to 20 mm/hr


Dr. Mehul Desai
M.B.D.C.P
Reg.No.G-9521



Savita


Superspeciality Hospital
(A Unit of Solace Healthcare Pvt. Ltd.)

Parivar Char Rasta, Waghodia-Dabhoi Ring Road, Vadodara-390019
0265-2578844 / 2578849 | mh@savitahospital.com | savitahospital.com

Patient Name :	Prajita Vivekkumar Purohit	Sample No. :	20240314836 
Patient ID :	20240309240	Visit No. :	OPD20240329432
Age / Sex :	28y/Female	Call. Date :	29/03/2024 09:20
Consultant :	DR SAURABH JAIN	S. Coll. Date :	29/03/2024 13:25
Ward :	-	Report Date :	29/03/2024 17:02

Blood Group Investigation	Result	Normal Value
BLOOD GROUP :		
ABO	O	
Rh	Positive	

RENAL FUNCTION TEST Investigation	Result	Normal Value
Creatinine :	0.6 mg/dl	0.6 - 1.4 mg/dl
Urea :	18 mg/ dl	13 - 45 mg/dl
Uric Acid :	4.1 mg/dl	3.5 - 7.2 mg/dl
Calcium :	9 mg/dl	8.5 - 10.5



Dr. Mehul Desai
M.B.D.C.P
Reg.No.G-9521



Patient Name : Prajita Vivekkumar Purohit	Sample No. : 20240314836
Patient ID : 20240309240	Visit No. : OPD20240329432
Age / Sex : 28y/Female	Call. Date : 29/03/2024 09:20
Consultant : DR SAURABH JAIN	S. Coll. Date : 29/03/2024 13:25
Ward : -	Report Date : 29/03/2024 17:02

Lipid Profile

Investigation	Result	Normal Value
Sample :	Fasting	
Sample Type :	Normal	
Cholesterol (Chol) :	180 mg/dl	Low risk : < 200 Moderate risk : 200 - 239 High risk : > or = 240
Triglyceride :	60 mg/dl	Normal : < 200.0 High : 200 - 499 Very High : > or = 500
HDL Cholesterol :	58 mg/dl	Low risk : >or = 60 mg/dL High risk : Up to 35 mg/dL
LDL :	110 mg/dl [L]	131.0 to 159.0(N) < 130.0(L) > 159.0(H)
VLDL :	12 mg/dl	Up to 0 to 34 mg/dl
LDL/HDL Ratio :	1.9	Low risk : 0.5 to 3.0 Moderate risk : 3.0 to 6.0 Elevted level high > 6.0
Total Chol / HDL Ratio :	3.1	Low Risk : 3.3 to 4.4 Average Risk : 4.4 to 7.1 Moderate Risk : 7.1 to 11.0 High Risk : > 11.0
Total Lipids :	598 mg/dl	400 to 700 mg/dl

Note :- Lipemic samples give high triglyceride value and falsely low LDL value.

Dr.Mehul Desai
M.B.D.C.P
Reg.No.G-9521






Savita

Superspeciality Hospital
(A Unit of Solace Healthcare Pvt. Ltd.)

Parivar Char Rasta, Waghodia Dabhoi Ring Road, Vadodara-390019

0265-2578844 / 2578849 ✉ mh@savitahospital.com 🌐 savitahospital.com

Patient Name :	Prajita Vivekkumar Purohit	Sample No. :	20240314836 
Patient ID :	20240309240	Visit No. :	OPD20240329432
Age / Sex :	28y/Female	Call. Date :	29/03/2024 09:20
Consultant :	DR SAURABH JAIN	S. Coll. Date :	29/03/2024 13:25
Ward :	-	Report Date :	29/03/2024 17:02

LFT (Liver Function Test)

Investigation	Result	Normal Value
Total Bilirubin :	0.4 mg/dl	0.2 to 1.0 mg/dl
Direct Bilirubin :	0.2 mg/dl	0.0 to 0.2 mg/dl
Indirect Bilirubin :	0.2 mg/dl	0.0 to 0.8 mg/dl
AST (SGOT) :	27 U/L	5 to 34 U/L
ALT (SGPT) :	14 U/L	0 to 55 U/L
Total Protein (TP) :	6.2 g/dL [L]	6.4 to 8.3, g/dl
Albumin (ALB) :	4.2 g/dl	3.5 to 5.2 g/dl
Globulin :	2 g/dl	2.3 to 3.5 g/dl
A/G Ratio :	2.1	
Alkaline Phosphatase (ALP) :	90 U/L	40 to 150 U/L
GAMMA GT. :	12 U/L	7 to 35 U/L



Dr. Mehul Desai
M.B.D.C.P
Reg.No.G-9521





Unipath Speciality Laboratory (Baroda) LLP, Plotting Complex, Opp. HDIC Bank, Nr. Sadha Krishna chaurasta, Akota, Vadodra - 390020
Unipath Speciality Laboratory (Baroda) LLP, Plotting Complex, Opp. HDIC Bank, Nr. Sadha Krishna chaurasta, Akota, Vadodra - 390020
Mobile: 7228800500 / 8155028222 | Email: info.baroda@unipathllp.in
Home Visit / OPD Reception : 9998724579



TEST REPORT

Reg. No. : 40301017425 Reg. Date : 29-Mar-2024 12:25 Collected On : 29-Mar-2024 12:25
Name : Ms. PRAJITA PUROHIT Approved On : 29-Mar-2024 14:25
Age : 28 Years Gender : Female Ref. No. : Dispatch At :
Ref. By : Tele No. :
Location : SAVITA SUPERSPECIALTY HOSPITAL @ WAGHODIYA ROAD

Test Name	Results	Units	Bio. Ref. Interval
THYROID FUNCTION TEST			
T3 (triiodothyronine) <i>Method:CLIA</i>	0.97	ng/mL	0.6 - 1.81
T4 (Thyroxine) <i>Method:CLIA</i>	9.30	µg/dL	4.5 - 12.6
TSH (ultra sensitive) <i>Method:CLIA</i>	1.228	µIU/mL	0.55 - 4.78
Sample Type:Serum			

Comments:
Thyroid stimulating hormone (TSH) is synthesized and secreted by the anterior pituitary in response to a negative feedback mechanism involving concentrations of FT3 (free T3) and FT4 (free T4). Additionally, the hypothalamic tripeptide, thyrotropin-releasing hormone (TRH), directly stimulates TSH production. TSH stimulates thyroid cell production and hypertrophy, also stimulate the thyroid gland to synthesize and secrete T3 and T4. Quantification of TSH is significant to differentiate primary (thyroid) from secondary (pituitary) and tertiary (hypothalamus) hypothyroidism. In primary hypothyroidism, TSH levels are significantly elevated, while in secondary and tertiary hypothyroidism, TSH levels are low.

- TSH levels During Pregnancy :**
- First Trimester : 0.1 to 2.5 µIU/mL
 - Second Trimester : 0.2 to 3.0 µIU/mL
 - Third trimester : 0.3 to 3.0 µIU/mL

Reference : Carl A.Burtis,Edward R.Ashwood,David E.Bruns. Tietz Textbook of Clinical Chemistry and Molecular Diagnostics. 5th Edition. Philadelphia: WB Saunders.2012:2170

..... End Of Report

This is an electronically authenticated report. Test done from collected sample.

Dr. Vishal Jhaveri
M.B.B.S, D.C.P

Printed On: 29-Mar-2024 14:26

We are open 24 x 7 & 365 days

Reg. G-13041 LLP Identification Number: AAN-8932
Page 1 of 1



Savita
Superspecialty Hospital
(A Unit of Solace Healthcare Pvt. Ltd.)

Parivar Char Rasta, Waghodia Dabhoi Ring Road, Vadodara-390019
0265 2578844 / 2578849 | mh@savitalhospital.com | savitalhospital.com

Patient Name : Prajila Vivekkumar Purohit

Patient ID : 20240309240

Age / Sex : 28y/Female

Consultant : DR SAURABH JAIN

Ward :

Sample No. : 20240314836



Visit No. : OPD20240329432

Call. Date : 29/03/2024 09:20

S. Coll. Date : 29/03/2024 13:25

Report Date : 29/03/2024 17:02

Urine R/M

Investigation	Result	Normal Value
Quantity - :	20 ml	
Colour - :	Pale Yellow	
Reaction (pH) :	5.0	4.6-8.0
Turbidity :	Clear	
Deposit :	Absent	Absent
Sp.Gravity :	1.020	1.005-1.010
Protein :	Absent	Absent
Glucose :	Absent	Absent
Bile Salts :	Absent	Absent
Bile pigments :	Absent	Absent
Ketones :	Absent	Absent
Urobilinogen :	Absent	
Blood :	Absent	Absent
Pus Cells :	1-2 /hpf	0-5/hpf
Red Blood Cells :	0-1 /hpf	Absent
Epithelial Cells :	3-5 /hpf	

Dr. Mehul Desai
M.B.D.C.P
Reg.No.G-9521





Savita
Superspecialty Hospital
(A Unit of Solace Healthcare Pvt. Ltd.)

Parivar Char Rasta, Waghodia-Dabhoi Ring Road, Vadodara-390019
0265-2578844 / 2578849 | mh@savitahospital.com | savitahospital.com

Patient Name : Prajita Vivekkumar Purohit
Patient ID : 20240309240
Age / Sex : 28y/Female
Consultant : DR SAURABH JAIN
Ward :

Sample No. : 20240314836



Visit No. : OPD20240329432
Call. Date : 29/03/2024 09:20
S. Coll. Date : 29/03/2024 13:25
Report Date : 29/03/2024 17:28

FBS & PPBS

Investigation

Investigation	Result	Normal Value
Blood Sugar (FBS) :	93 mg/dl	74 - 100 mg/dl
Urine Sugar (FUS) :	Nil	
Blood Sugar (PP2BS) :	82 mg/dl	70 to 120 mg/dl
Urine Sugar (PP2US) :	Nil	

HBA1C

Investigation

Investigation	Result	Normal Value
Glycosylated Hb :	6.1 % [H]	Near Normal Glycemia : 6 to 7 Excellent Control : 7 to 8 Good Control : 8 to 9 Fair Control : 9 to 10 Poor Control : > 10

Average Plasma Glucose of Last 3 Months : 128.37

Dr. Mehul Desai
M.B.D.C.P
Reg.No.G-9521





Savita
Superspecialty Hospital
(A Unit of Solace Healthcare Pvt. Ltd.)

Parivar Char Rasta, Waghodia-Dabhoi Ring Road, Vadodara-390019
0265-2578844 / 2578849 ☎ 63596 88442
mh@savitahospital.com savitahospital.com



Examination by Ophthalmologist

Name: PRAJITA PUROHIT

Reg. No: 20230309240

Age/ Sex: 28/FEMALE

DOE: 29/03/2024

Nil

Medical History:

Nil

Examination of Eye:

Right LEFT

External Examination: WNL

Anti seg Examination: WNL

Schiot Tonometry IOP:

Fundus:

Without Glass Distant Vision: 6/6 6/6

Near Vision: N6 N6

With Glass Distant Vision: 2 2

Near Vision: 2 2

Colour Vision (With Ishihara Chart): WNL

Impression: WNL

Advice:



Signature:





Savita
Superspecialty Hospital
(A Unit of Solace Healthcare Pvt. Ltd.)

Parivar Char Rasta, Waghodia-Dabhoi Ring Road, Vadodara-390019
0265-2578844 / 2578849 ☎ 63596 88442
✉ mh@savitahospital.com 🌐 savitahospital.com



Examination by Physicia

Name: PRAJITA PUROHIT

Reg. No: 20230309240

Age/ Sex: 28/FEMALE

DOE: 29/03/2024

Physical Examination

Height: 152cm Weight: 79 kg BMI: 34.19

Temperature: N Pulse: 90 BP: 144/82 SpO2: 99

Chief Complaints:

Since epistaxis reg. sebaceous cyst,

do. oco pem +

Past History:

CA PLG AO

Examination:

General Examination:

NAD

Systemic Examination:

NAD

Investigation:

RBS

ECG

Others

NAD

Advice:

✓

Signature



NIDNIA

0915 81

भारत आधार, भारी ओज्ज



भारत सरकार

Government of India



Issue Date: 06/05/2012



पुरोहित प्रजिता वीवेककुमार

PUROHIT PRAJITA VIVEKKUMAR

जन्म तारीख / DOB: 07/11/1996

स्त्री / Female

7923 0981 2610