

ID: 910063343  
Name: MR UDHAYA KUMAR  
Age: 31 Years  
Gender: Male  
Race:

2024-04-09 09:35:08 AM

Vital Signs™ 226 166 05

CE 0537 LOT D 790

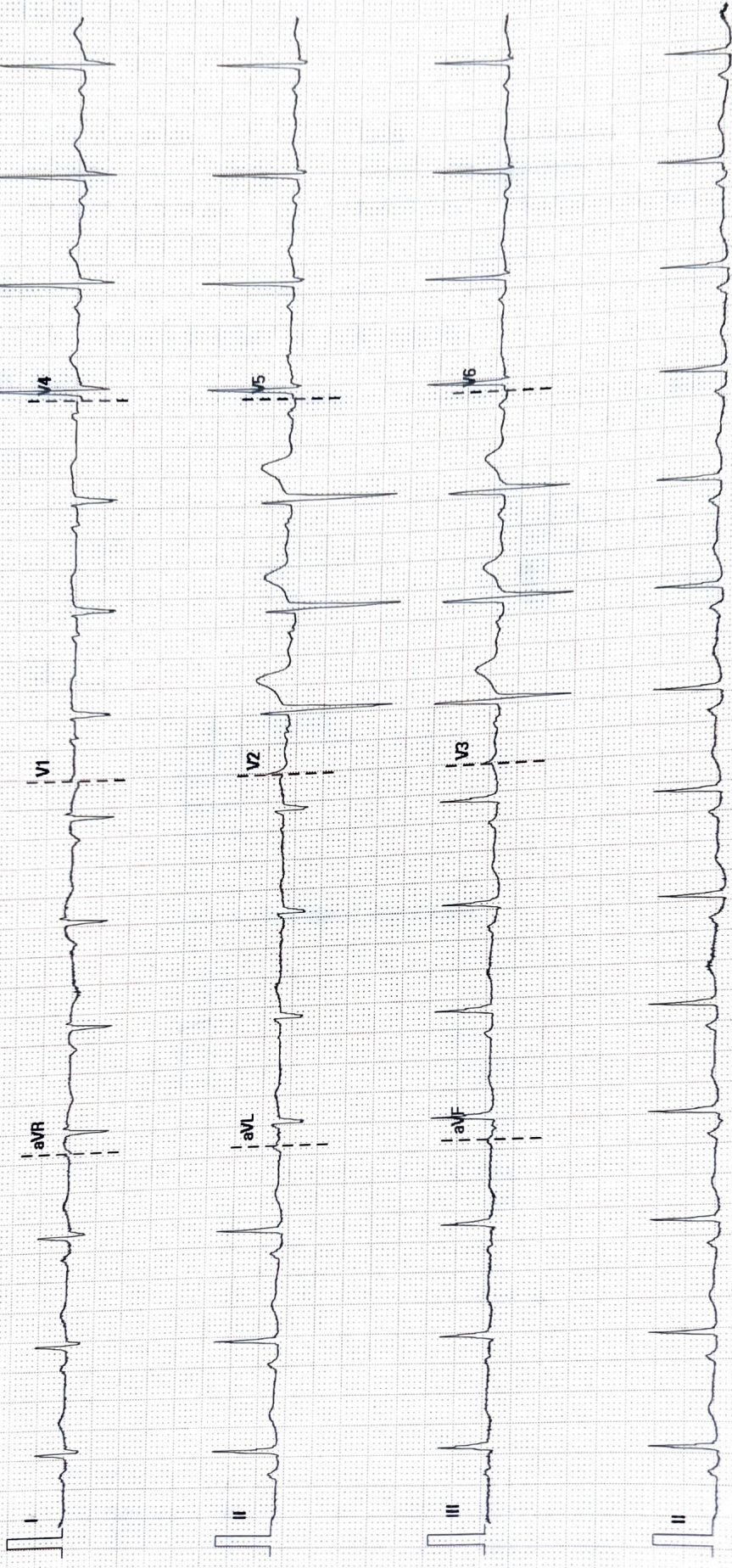
Vent. Rate  
PR Interval  
QRS Duration  
QT/QTc Interval  
P/ORS/T Axes  
QTc:Hodgess

84 bpm  
162 ms  
82 ms  
342/384 ms  
58/74/24 deg

Sinus rhythm  
Normal ECG

Unconfirmed Diagnosis

*Signature*  
*D*



25 mm/s

10 mm/mV

50 Hz

BDR 150 Hz

PRASHANTH SUPERSPECIALITY HOSPITAL

02.06.00V28.A.1

SN:FN-72006888





# PRASHANTH HOSPITALS

Name	: J UDHAYA KUMAR	UHID	: 910063343
Sex / Age	: M / 31Y	Accession NO	: 9121185173
Study Date	: 9/4/2024, 11:08:58 am	Report Date	: 9/4/2024, 10:46:58 am
Ref Dr.	: DR. GOPALASWAMY G		

## DEPARTMENT OF CARDIOLOGY

### INVESTIGATION: ECHO

#### LV MEASUREMENTS

AO	24 mm	IVS d/s	08/13 mm
LA	31 mm	LVPW d/s	07/09 mm
LVID (ED)	48 mm	EF	66 %
LVID (ES)	30 mm	FS	36 %

#### MORPHOLOGICAL DATA

MITRAL VALVE:	
AML	: GRADE I PROLAPSE
PML	: NORMAL
CHORDAE	: NORMAL
AORTIC VALVE	: NORMAL
TRICUSPID VALVE	: NORMAL
PULMONARY VALVE	: NORMAL
ATRIA	: NORMAL
RIGHT VENTRICLE	: NORMAL FUNCTION (TAPSE:2.2 cm)
THROMBOSIS	: NIL
INTER ATRIAL SEPTUM	: INTACT
INTER VENTRICULAR SEPTUM	: INTACT
AORTA	: NORMAL
PULMONARY ARTERY	: NORMAL
PERICARDIUM	: NORMAL

#### DOPPLER DATA :

MITRAL VALVE	: NORMAL E/A RATIO AT MITRAL INFLOW TRIVIAL MR E : 97 cm/s, A : 48 cm/s E/E' :10.2, S' :6.3 cm/s
AORTIC VALVE	: NO AR, NO AS, VEL : 133 cm/s
PULMONARY VALVE	: NO PR NO PS, VEI: 100 cm/s
TRICUSPID VALVE	: TRIVIAL TR / NO PAH ,TRPG 19 mmHg

A Unit of PRASHANTH FERTILITY RESEARCH CENTRE PVT. LTD.

No. 36 & 36A, Velachery Main Road, Velachery, Chennai - 600 042. ☎ +91 93 8099 8099

☎ +91 44 4680 5544 / 2243 9494 ✉ info@prashanthhospitals.org 🌐 www.prashanthhospitals.org



# PRASHANTH HOSPITALS

Name	: J UDHAYA KUMAR	UHID	: 910063343
Sex / Age	: M / 31Y	Accession NO	: 9121185173
Study Date	: 9/4/2024, 11:08:58 am	Report Date	: 9/4/2024, 10:46:58 am
Ref Dr.	: DR. GOPALASWAMY G		

## IMPRESSION

- GRADE I MITRAL VALVE PROLAPSE (AML)
- MITRAL REGURGITATION (TRIVIAL)
- NO REGIONAL WALL MOTION ABNORMALITY
- NORMAL LV SYSTOLIC & DIASTOLICFUNCTION (LVEF: 66 %)
- NORMAL RIGHT VENTRICLE FUNCTION (TAPSE: 2.2 cm )
- NO PERICARDIAL EFFUSION
- NO EVIDENCE OF CLOT OR VEGETATION

**DONE BY :KARTHIKA. V**  
**SR.ECHO TECHNOLOGIST**

**Dr. Sivakumar**  
**MBBS.MD.,DNB.,FNB**  
**Sr. Consultant Interventional Cardiologist**  
**Reg. No: 68984**

**A Unit of PRASHANTH FERTILITY RESEARCH CENTRE PVT. LTD.**

No. 36 & 36A, Velachery Main Road, Velachery, Chennai - 600 042. ☎ +91 93 8099 8099

☎ +91 44 4680 5544 / 2243 9494 ✉ info@prashanthhospitals.org 🌐 www.prashanthhospitals.org



# PRASHANTH HOSPITALS

Name	: J UDHAYA KUMAR 31 YRS	UHID	: 910063343
Sex / Age	: M / ---	Accession NO	: 180053776
Study Date	: 9/4/2024, 11:14:57 am	Report Date	: 9/4/2024, 3:39:20 pm
Ref Dr.	: DR. G . GOPALASWAMY		

## CHEST X-RAY

Trachea and both main bronchi are normal.

Cardiac silhouette and cardiothoracic ratio are normal

Bilateral lung fields are clear. No focal lesion seen.

The cardiophrenic and costophrenic angles are free.

Both hemi diaphragms appear normal.

Bony thorax appears normal.

### IMPRESSION:

No significant abnormality detected.

  
Dr. NARMADHA, MBBS., DMRD  
CONSULTANT RADIOLOGIST  
REG NO: 93293

A Unit of PRASHANTH FERTILITY RESEARCH CENTRE PVT. LTD.

No.36 & 36 A, Velachery Main Road, Velachery, Chennai - 600 042. ☎ +91 93 8099 8099

☎ +91 44 4680 5544 / 2243 9494

✉ info@prashanthhospitals.org

🌐 www.prashanthhospitals.org





# PRASHANTH HOSPITALS

Patient Name	Mr. J Udhaya Kumar	Age / Sex	31 Y/ M
Patient ID	910063343	Visit No.	1
Ref. By	Dr. G.Gopalaswamy	Visit Date	09.04.2024

## USG Complete Abdomen

### Upper Abdomen:

Liver normal in size measures 13.3 cm and filled with homogeneous parenchymal echoes. No abscess or mass lesion in the liver. No dilatation of intrahepatic biliary radicals seen. Gall bladder walls and lumen appeared normal. No calculi seen. Common duct appeared normal. No calculi seen. Portal vein and Pancreas appeared normal. **Spleen appeared enlarged in size 13.2 cm.** No free fluid seen in the hepatorenal pouch.

### KUB

RT. Kidney measures 10.9 x 3.9 cm. Cortex appears normal. Cortico medullary differentiation is maintained. Pelvicalyceal system is not dilated. No calculus is seen. Right ureter is not dilated.

LT. Kidney measures 11.7 x 4.3 cm. Cortex appears normal. Cortico medullary differentiation is maintained. Pelvicalyceal system is not dilated. No calculus is seen. Left ureter is not dilated.


Urinary Bladder is normal in contour. No intra luminal echoes are seen. No calculus or diverticulum is seen.

Prostate: Appears normal in size and measures 2.7 x 2.9 x 1.8 cm ( Vol = 7.8 cc ). It shows homogenous echogenicity. No intravesical extension.

Retroperitoneum: Aorta and IVC appears normal. No obvious para aortic lymphadenopathy. No free fluid in peritoneal cavity. Pleural spaces appeared normal.

### Impression:

- Splenomegaly

  
Dr. Narmadha, DMRD  
Consultant Radiologist  
Reg no : 93293

**Note:** This investigation has its own limitation. Hence sonographic findings should be correlated with clinical features and with further investigations. Not for medico legal purpose.

**A Unit of PRASHANTH FERTILITY RESEARCH CENTRE PVT. LTD.**

No. 36 & 36A, Velachery Main Road, Velachery, Chennai - 600 042. ☎ +91 93 8099 8099

☎ +91 44 4680 5544 / 2243 9494 ✉ info@prashanthhospitals.org 🌐 www.prashanthhospitals.org



# PRASHANTH HOSPITALS

## EYE CHECK-UP REPORT

NAME : Mrs. J. Udhayakumar

DATE : 09/11/24

AGE / SEX : 31/m

UHID NUM : 910068343

Chief complaints : Regular eye check up | Eye Pain, Headache

Past history : —

Systemic Diseases : —

### DISTANCE VISION :

WITH OUT GLASS : 6/18<sup>st</sup>, N6      6/36, N6

WITH GLASS : —      —

COLOR VISION :  NORMAL /  ABNORMAL

### GLASS PRESCRIPTION :

EYE	SPH	CYL	AXIS	V/A	SPH	CYL	AXIS	V/A
DISTANCE	±	1.50	120°	6/6 <sup>st</sup>	±	1.50	70°	6/9
ADD	—	—	—	N6	—	—	—	N6

ANTERIOR SEGMENT :

CORNEA & LENS : BF Wnt

REMARK : CONTINUE WITH SAME GLASSE

ROUTINE CHECK UP AFTER 6/12 MONTH

FUNDUSCOPY ONCE A YEAR

Advice:

Dilate, IAR, Pmt

OPTOMETRIST

A Unit of PRASHANTH FERTILITY RESEARCH CENTRE PVT. LTD.

No. 36 & 36A, Velachery Main Road, Velachery, Chennai - 600 042. ☎ +91 93 8099 8099

☎ +91 44 4680 5544 / 2243 9494    ✉ info@prashanthhospitals.org    🌐 www.prashanthhospitals.org