

MER- MEDICAL EXAMINATION REPORT

Date of Examination	29/3/24		
NAME	VISAYA CHANDRAY		
AGE	39	Gender	F.
HEIGHT(cm)	159	WEIGHT (kg)	65 Bmi- 25.7
B.P.	110/70		
ECG	normal		
X Ray	normal		
Vision Checkup	—		
Present Ailments	None		
Details of Past ailments (If Any)	None		
Comments / Advice : She /He is Physically Fit	Medicines Rx		



Dr. Smita Pastogi
 MBBS, DCP
 S. Pastogi

Signature with Stamp of Medical Examiner



Vijaya Chaudhary



भारत सरकार
Government of India



विजया चौधरी
Vijaya Chaudhary
जन्म तिथि/ DOB: 09/07/1984
महिला / FEMALE



5522 0399 0929

मेरा आधार, मेरी पहचान

You have been informed that ent ,diet, opthal consultation facility is not available at our centre. If you are ready then your test can be start

2D echo test facility is not available at our center, instead we do TMT test.

Vijaya Chaudhary





MODERN PATHOLOGY & DIAGNOSTIC CENTRE

Dr. R. P. Rastogi
M.B.B.S., M.D. (Path & Bact)



CLINIC :
1/4A, Vineet Khand, (Opp Jaipuria Management)
Gomti Nagar, Lucknow - 226 010
Ph.: 0522-4008184, 4308184 • 8112323230
Mob.: 7618884441, 9450389932, 8177063877

Date	: 29-Mar-2024		
Name	: Mr. VIJAYA CHAUDHARY	Age	: 39 Yrs.
Ref.By	: APOLLO HEALTH	Sex	: Male

Haemoglobin	12.6	gm%	14 - 17
-------------	-------------	-----	---------

Total Leucocyte Count	8100	Cells/cumm.	4000-11000
-----------------------	-------------	-------------	------------

Differential Leucocyte Count			
Polymorphs	72	%	45 - 70
Lymphocytes	21	%	20 - 45
Eosinophils	02	%	0 - 6
Monocytes	05	%	0 - 8
Basophils	00	%	0 - 1

Erythrocyte Sedimentation Rate (Wintrobe)			
ESR	12	mm in 1st Hr.	0 - 9
PCV	39.0	cc%	40 - 52
Corrected ESR	04	mm in 1st Hr.	0 - 9

Platelet Count	2.57	lakh/cumm.	1.5 - 4.0
----------------	-------------	------------	-----------

Red Cells Count	4.53	million/cmm	3.90 to 5.80
-----------------	-------------	-------------	--------------

Absolute values			
MCV	86.1	fL	77 - 97
MCH	27.9	pg	27 - 31
MCHC	32.4	gm /dl	31 - 34

Page 1 of 2 (End of Report)
Dr. Sanjay Rastogi
M.B.B.S., DCP, CRIAT (BARC)

Dr. Smita Rastogi
M.B.B.S., DCP

Results, adhering to W.H.O. and International Federation of Clinical Chemists Quality Control Standards.

SAMPLE COLLECTION FACILITY AVAILABLE

Report needs clinicopathological correlation ♦ Not for Medico Legal Purpose

e-mail : mpdcgn@gmail.com ♦ For online reports - www.modernpath.in

♦ Please ask for your computerized bill ♦ Pay only the printed collection charges



MODERN PATHOLOGY & DIAGNOSTIC CENTRE

Dr. R. P. Rastogi
M.B.B.S., M.D. (Path & Bact)



CLINIC :
1/4A, Vineet Khand, (Opp Jaipuria Management)
Gomti Nagar, Lucknow - 226 010
Ph.: 0522-4008184, 4308184 • 8112323230
Mob.: 7618884441, 9450389932, 8177063877

Date : 29-Mar-2024
Name : **Mr. VIJAYA CHAUDHARY**
Ref.By : APOLLO HEALTH
Age : 39 Yrs.
Sex : Male

Plasma Glucose - F
GOD-POD Method 98 mg/dl 70 - 110

Plasma Glucose - PP
GOD POD Method 118 mg/dl 110 - 170

KFT
UREA 19.4 mg % 15 - 50
CREATININE 0.72 mg % 0.5 - 1.5
URIC ACID 5.4 mg % 2 - 7
CALCIUM 9.5 mg % 8.8 - 10.0

Blood Group & Rh "AB" Positive

LFT T&D
Total Bilirubin 0.49 mg% 0.2 - 1.0
Direct Bilirubin 0.16 mg% 0.0 to 0.40
Indirect Bilirubin 0.33 mg% 0.10 to 0.90
S.G.P.T 19 IU/L 5 - 40
S.G.O.T 12 IU/L 5 - 50
ALP 86 IU/L 40 to 129

Serum Gamma G.T. 28 IU/L 11 - 50

Urine Sugar (Fasting) NIL

Urine Sugar (PP) NIL

Page **Dr. Sanjay Rastogi**
M.B.B.S., DCP, CRIAT (BARC)

Dr. Smita Rastogi
M.B.B.S., DCP

Contd...

Results, adhering to W.H.O. and International Federation of Clinical Chemists Quality Control Standards.

SAMPLE COLLECTION FACILITY AVAILABLE

Report needs clinicopathological correlation ♦ Not for Medico Legal Purpose

e-mail : mpdcgn@gmail.com ♦ For online reports - www.modernpath.in

♦ Please ask for your computerized bill ♦ Pay only the printed collection charges



MODERN PATHOLOGY & DIAGNOSTIC CENTRE

Dr. R. P. Rastogi
M.B.B.S., M.D. (Path & Bact)



CLINIC :
1/4A, Vineet Khand, (Opp Jaipuria Management)
Gomti Nagar, Lucknow - 226 010
Ph.: 0522-4008184, 4308184 • 8112323230
Mob.: 7618884441, 9450389932, 8177063877

Date : 29-Mar-2024
Name : **Mr. VIJAYA CHAUDHARY**
Ref.By : APOLLO HEALTH
Age : 39 Yrs.
Sex : Male

LIPID PROFILE

Triglycerids	72	mg%	70 - 190
S. Cholestrol S.	206	mg%	130 - 230
S. HDL Cholestrol	41.4	mg%	35 - 75
S. LDL Cholestrol	150.2	mg%	75 - 150
VLDL	14.4	mg%	0 - 34
Chol / HDL factor	4.98		
LDL / HDL Factor	3.63		

COMMENTS

- * Triglycerides (TG) are the main dietary lipids. Cholesterol constitutes a small part of the dietary lipids, it is mostly synthesised in the liver. Both TG and Chol. are transported through the plasma by lipoproteins (Chylomicrons, VLDL, LDL, IDL, HDL).
- * LDL is the major cholesterol particle in plasma and high levels are strongly implicated in the formation of atheroma. An increase in the LDL leads to hypercholesterolemia, and therefore a risk factor for IHD. LDL increases with age particularly in females. Oestrogen lower LDL and raise HDL. Raised chol. in females is mostly due to disturbed thyroid function.
- * Increase in VLDL leads to hyperglyceridaemia. Raised TGs are associated with increased risk of CHD. Very high TGs increase the risk of Pancreatitis. Cholesterol is often raised due to Diabetes, Renal disease, Diuretic or Betablocker therapy.

TYPES OF HYPERLIPOPROTEINEMIAS

- | | |
|---|--|
| TYPE 1: Normal cholesterol
TG greatly raised | TYPE 3: Cholesterol increased
TG increased |
| TYPE 2a: Cholesterol increased
LDL increased
TG normal | TYPE 4: Cholesterol normal /increased
VLDL increased
TG increased |
| TYPE 2b Chol. increased
VLDL raised
TG increased
LDL increased | TYPE 5: Cholesterol increased
LDL reduced
VLDL increased
TG greatly increased |

Dr. Sanjay Rastogi
M.B.B.S., DCP, CRIAT (BARC)

Dr. Smita Rastogi
M.B.B.S., DCP

Contd...

Results, adhering to W.H.O. and International Federation of Clinical Chemists Quality Control Standards.

SAMPLE COLLECTION FACILITY AVAILABLE

Report needs clinicopathological correlation ♦ Not for Medico Legal Purpose

e-mail : mpdcgn@gmail.com ♦ For online reports - www.modernpath.in

♦ Please ask for your computerized bill ♦ Pay only the printed collection charges

Dr. R. P. Rastogi
M.B.B.S., M.D. (Path & Bact)



CLINIC :
1/4A, Vineet Khand, (Opp Jaipuria Management)
Gomti Nagar, Lucknow - 226 010
Ph.: 0522-4008184, 4308184 • 8112323230
Mob.: 7618884441, 9450389932, 8177063877

Date : 29-Mar-2024
Name : **Mr. VIJAYA CHAUDHARY**
Ref.By : APOLLO HEALTH
Age : 39 Yrs.
Sex : Male

THYROID TEST

Tri-iodothyronine (T3)	1.94	nmol/L	0.50 to 2.50
Thyroxine (T4)	7.18	mcg/dL	5.0 to 12.5
Thyroid Stimulating Hormone (TSH)	1.43	mIU/ ml	0.3 to 6.0

COMMENTS

- 1) Primary hyperthyroidism is accompanied by elevated Serum T3 and T4 values along with depressed TSH levels.
- 2) Primary Hypothyroidism is accompanied by depressed serum T3 and T4 values and elevated serum TSH levels.
- 3) Normal T4 levels accompanied by high T3 levels are seen in patients with T3 thyrotoxicosis.
- 4) Slightly elevated T3 levels may be found in pregnancy and estrogen therapy, while depressed levels may be encountered in severe illness, malnutrition, renal failure and during therapy with drugs like propranolol and propylthiouracil.
- 5) Elevated TSH levels may also be indicative of TSH secreting Pituitary Tumour.

Dr. Sanjay Rastogi
M.B.B.S., DCP, CRIAT (BARC)

Dr. Smita Rastogi
M.B.B.S., DCP

Contd...

Results, adhering to W.H.O. and International Federation of Clinical Chemists Quality Control Standards.

SAMPLE COLLECTION FACILITY AVAILABLE

Report needs clinicopathological correlation ♦ Not for Medico Legal Purpose

e-mail : mpdcgn@gmail.com ♦ For online reports - www.modernpath.in

♦ Please ask for your computerized bill ♦ Pay only the printed collection charges



MODERN PATHOLOGY & DIAGNOSTIC CENTRE

Dr. R. P. Rastogi
M.B.B.S., M.D. (Path & Bact)



CLINIC :

1/4A, Vineet Khand, (Opp Jaipuria Management)
Gomti Nagar, Lucknow - 226 010
Ph.: 0522-4008184, 4308184 ● 8112323230
Mob.: 7618884441, 9450389932, 8177063877

Date	: 29-Mar-2024	Age	: 39 Yrs.
Name	: Mr. VIJAYA CHAUDHARY	Sex	: Male
Ref.By	: APOLLO HEALTH		

Glycosylated Haemoglobin

Glycosylated Haemoglobin	5.5	%	4.5 TO 6.0
--------------------------	-----	---	------------

=====

INTERPRETATION AND COMMENTS

=====

- NON DIABETIC : 4.5 to 6.0 %
- GOOD CONTROL: 6.0 to 7.0
- FAIR CONTROLLED 7.0 AND 8.0
- UNCONTROLLED 8.0 AND ABOVE

Glycosylated haemoglobin is the adducted glucose in the haemoglobin of the red blood cells, this adduction is stable for the life time of the RBC (i.e 120 days). There fore the measure of glycosylated haemoglobin reflects the average blood glucose concentration over the preseding several weeks. The sudden change in blood glucose level would not effect the glycosylated haemoglobin level ,which serves as a better marker of long term metabolic control and the efficacy of therapy.



Page **Dr. Sanjay Rastogi**
M.B.B.S., DCP, CRIAT (BARC)

Dr. Smita Rastogi
M.B.B.S., DCP
Contd



MODERN PATHOLOGY & DIAGNOSTIC CENTRE

DIAGNOSTIC CENTRE

Dr. R. P. Rastogi
M.B.B.S., M.D. (Path & Bact)



CLINIC :

1/4A, Vineet Khand, (Opp Jaipuria Management)
Gomti Nagar, Lucknow - 226 010
Ph.: 0522-4008184, 4308184 • 8112323230
Mob.: 7618884441, 9450389932, 8177063877

Date	: 29-Mar-2024	Age	: 39 Yrs.
Name	: Mr. VIJAYA CHAUDHARY	Sex	: Male
Ref.By	: APOLLO HEALTH		

Urine Examination

PHYSICAL		
Colour	Straw	
Turbidity	Nil	
Deposit	Nil	
Reaction	Acidic	
*Specific Gravity	1.020	
CHEMICAL		
Protein	Nil	
Sugar	Nil	
*Bile Salts	Nil	
*Bile Pigments	Nil	
Phosphate	Nil	
MICROSCOPIC		
Pus Cells	Nil	/hpf
Epithelial Cells	0-1	/hpf
Red Blood Cells	Nil	/hpf
Casts	Nil	
Crystals	Nil	
Others	Nil	

Dr. Sanjay Rastogi
M.B.B.S., DCP, CRIAT (BARC)

Dr. Smita Rastogi
M.B.B.S., DCP

Results, adhering to W.H.O. and International Federation of Clinical Chemists Quality Control Standards.

SAMPLE COLLECTION FACILITY AVAILABLE

Report needs clinicopathological correlation ♦ Not for Medico Legal Purpose

e-mail : mpdcgn@gmail.com ♦ For online reports - www.modernpath.in

♦ Please ask for your computerized bill ♦ Pay only the printed collection charges



MODERN PATHOLOGY & DIAGNOSTIC CENTRE

Dr. R. P. Rastogi
M.B.B.S., M.D. (Path & Bact)



CLINIC :
1/4A, Vineet Khand, (Opp Jaipuria Management)
Gomti Nagar, Lucknow - 226 010
Ph.: 0522-4008184, 4308184 • 8112323230
Mob.: 7618884441, 9450389932, 8177063877



TEST REQUEST ID :012403290045	SAMPLE DATE	:29/Mar/2024 09:50AM
NAME :Mrs. VIJAYA CHAUDHARY	SAMPLE REC. DATE	:29/Mar/2024 09:50AM
AGE/SEX :32 YRS/FEMALE	REPORTED DATE	:29/Mar/2024 01:37PM
REFERRED BY : Apollo Health and Lifestyle Limited,	BARCODE NO	:01290045

XRAY CHEST PA

- Trachea is central in position.
- Bilateral lung fields are normally aerated.
- Both hilar shadows are normal.
- Both C.P. angles are clear.
- Cardiac shadow is within normal limits.
- Bony cage appears normal.

OPINION: NORMAL STUDY.

Please correlate clinically.

*** End Of Report ***

Dr. Sanjay Rastogi
M.B.B.S., DCP, CRIAT (BARC)

DR. PANKAJ UPADHYAYA

Dr. Smita Rastogi
M.B.B.S., DCP

Results, adhering to W.H.O. and International Federation of Clinical Chemists Quality Control Standards.

DMRD
Consultant Radiologist
SPECIALTY FACILITY AVAILABLE

Report needs clinicopathological correlation ♦ Not for Medico Legal Purpose

Print DateTime: 29/03/2024 1:50 PM e-mail : mpdcgn@gmail.com ♦ For online reports - www.modernpath.in

♦ Please ask for your computerized bill ♦ Pay only the printed collection charges



MODERN PATHOLOGY & DIAGNOSTIC CENTRE

Dr. R. P. Rastogi
M.B.B.S., M.D. (Path & Bact)



CLINIC :
1/4A, Vineet Khand, (Opp Jaipuria Management)
Gomti Nagar, Lucknow - 226 010
Ph.: 0522-4008184, 4308184 • 8112323230
Mob.: 7618884441, 9450389932, 8177068871



TEST REQUEST ID :012403290045	SAMPLE DATE	:29/Mar/2024 09:50AM
NAME :Mrs. VIJAYA CHAUDHARY	SAMPLE REC. DATE	:29/Mar/2024 09:50AM
AGE/SEX :32 YRS FEMALE	REPORTED DATE	:29/Mar/2024 12:05PM
REFERRED BY :Apollo Health and Lifestyle Limited,	BARCODE NO	:01290045

USG WHOLE ABDOMEN-FEMALE

Liver: is normal in size (135 mm). Parenchymal echogenicity is normal. No focal echovariant lesion is seen. Intrahepatic biliary radicles are not dilated.

Gall Bladder: is well distended. Lumen is anechoic. Wall is of normal thickness.

CBD: is normal in diameter. Portal vein is normal in diameter.

Pancreas: is normal in size, shape and echotexture. No focal echovariant lesion is seen. Pancreatic duct is not dilated.

Spleen: is normal in size (89 mm), shape and echotexture. No focal echovariant lesion is seen. Splenic vein is normal.

Both Kidneys: are normal in size (RK- 76 x 45 mm & LK -97 x 46 mm), shape, position and excursion. Parenchymal echogenicity and echotexture is normal with maintained corticomedullary differentiation. No mass, cyst is seen. **A small calculus of 4.8 mm in size is seen in left lower uretric region at UV junction.** Pelvicalyceal systems are not dilated. Ureters are not dilated.

Urinary bladder: is well distended. Lumen is anechoic. Wall is of normal thickness. No mass or calculus is seen.

Uterus is normal in size (85 x 67 x 51 mms), shape and echotexture. It is anteverted.

Dr. Sanjay Rastogi
M.B.B.S., DCP, CRIAT (BARC)

Dr. Smita Rastogi
M.B.B.S., DCP

Results, adhering to W.H.O. and International Federation of Clinical Chemists Quality Control Standards.
SAMPLE COLLECTION FACILITY AVAILABLE

Report needs clinicopathological correlation ♦ Not for Medico Legal Purpose

e-mail : mpdcgn@gmail.com ♦ For online reports - www.modernpath.in

♦ Please ask for your computerized bill ♦ Pay only the printed collection charges



MODERN PATHOLOGY & DIAGNOSTIC CENTRE

Dr. R. P. Rastogi
M.B.B.S., M.D. (Path & Bact)



CLINIC :

1/4A, Vineet Khand, (Opp Jaipuria Management)
Gomti Nagar, Lucknow - 226 010
Ph.: 0522-4008184, 4308184 • 8112323230
Mob.: 7618884441, 9450389932, 8177068877



TEST REQUEST ID :012403290045	SAMPLE DATE	:29/Mar/2024 09:50AM
NAME :Mrs. VIJAYA CHAUDHARY	SAMPLE REC. DATE	:29/Mar/2024 09:50AM
AGE/SEX :32 YRS/FEMALE	REPORTED DATE	:29/Mar/2024 12:05PM
REFERRED BY : Apollo Health and Lifestyle Limited,	BARCODE NO	:01290045

Myometrium is homogenous. No focal mass is seen. Endometrial thickness is normal 6.6 mm. Cervix appears normal in size, shape and echotexture. No evidence of collection in cervical canal.

Bilateral Ovaries and adnexae Both ovaries are normal in size, shape and echotexture. No adnexal solid or cystic mass lesion is seen.

Both iliac fossae are clear. No obvious bowel pathology is noted. There is no free fluid in peritoneal cavity.

OPINION:

- LEFT LOWER URETRIC CALCULUS

*** End Of Report ***

Dr. Sanjay Rastogi
M.B.B.S., DCP, CRIAT (BARC)

Dr. Smita Rastogi
M.B.B.S., DCP

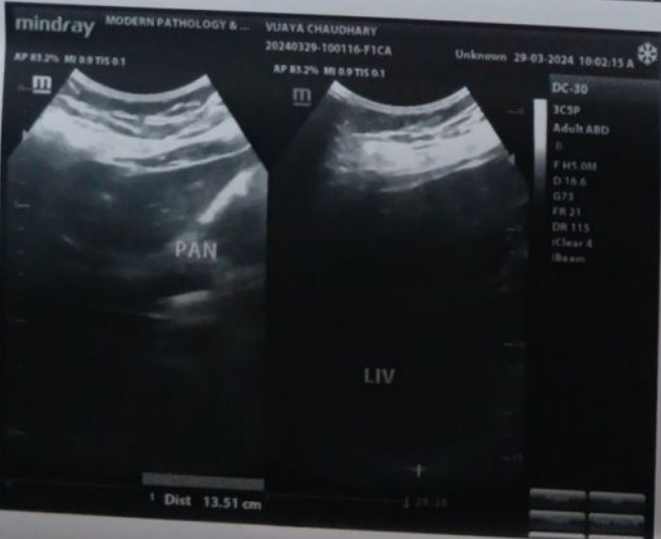
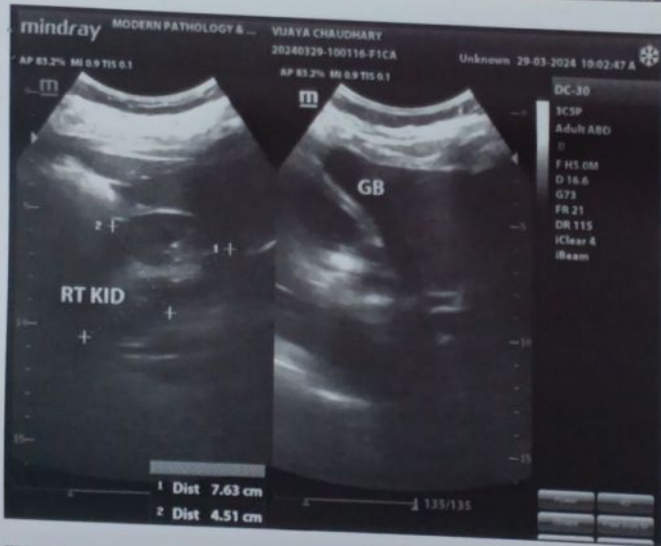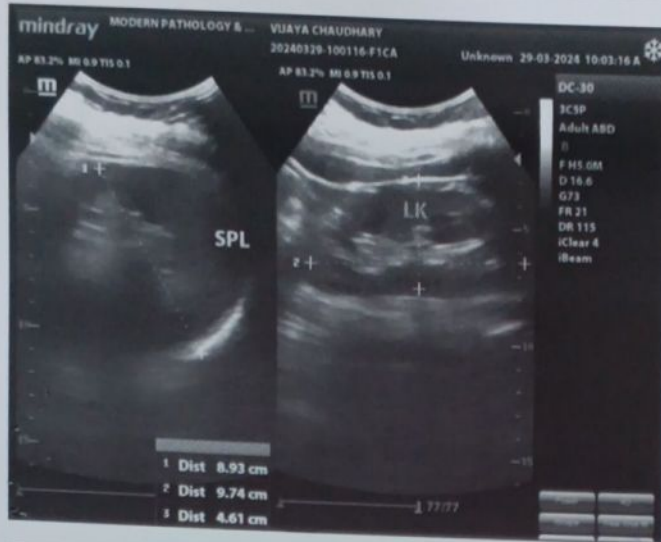
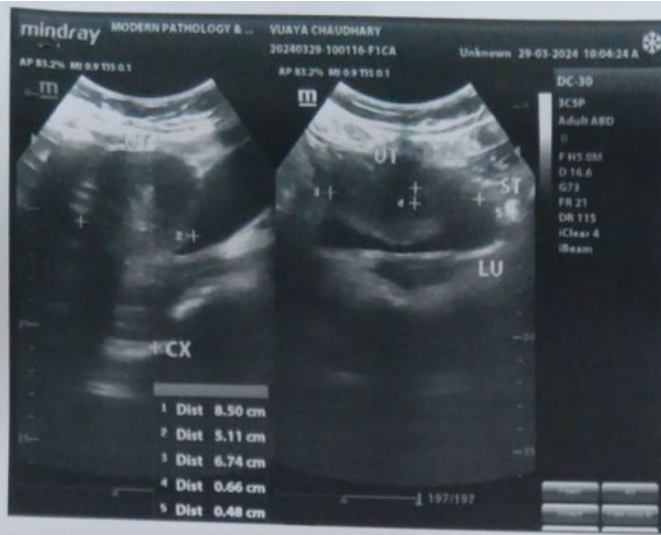Results, adhering to W.H.O. and International Federation of Clinical Chemists Quality Control Standards.

SAMPLE COLLECTION FACILITY AVAILABLE

Report needs clinicopathological correlation ♦ Not for Medico Legal Purpose

e-mail : mpdcgn@gmail.com ♦ For online reports - www.modernpath.in

♦ Please ask for your computerized bill ♦ Pay only the printed collection charges





MODERN PATHOLOGY & DIAGNOSTIC CENTRE

Dr. R. P. Rastogi
M.B.B.S., M.D. (Path & Bact)



CLINIC :

1/4A, Vineet Khand, (Opp Jaipuria Management)
Gomti Nagar, Lucknow - 226 010
Ph.: 0522-4008184, 4308184 • 8112323230
Mob.: 7618884441, 9450389932, 8177063877

Patient name: Mrs Vijaya Chaudhary
Ref By. Apollo Health care

Age/Sex 39/F
29/03/2024

E.C.G. REPORT

1. Rhythm	:	Sinus, Regular
2. Atrial Rate	:	80/mt
3. Ventricular Rate	:	80/mt
4. P – Wave	:	Normal
5. P R Interval	:	Normal
6. Q R S	:	
Axis	:	Normal
R/S Ratio	:	Normal
Configuration	:	Normal
7. Q T c Interval	:	Normal
8. S-T Segment	:	Normal
9. T-Wave	:	Normal

FINAL IMPRESSION

E.C.G. is within normal limits.

Signature of Doctor

Dr. AMIT MOHAN MD
Reg. No. 44559

Dr. Sanjay Rastogi
M.B.B.S., DCP, CRIAT (BARC)

Dr. Smita Rastogi
M.B.B.S., DCP

Results, adhering to W.H.O. and International Federation of Clinical Chemists Quality Control Standards.

SAMPLE COLLECTION FACILITY AVAILABLE

Report needs clinicopathological correlation ♦ Not for Medico Legal Purpose

e-mail : mpdcgn@gmail.com ♦ For online reports - www.modernpath.in

♦ Please ask for your computerized bill ♦ Pay only the printed collection charges

Name Vijaya Chandhary

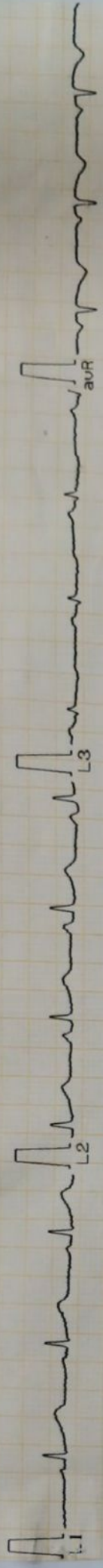
Age 45 Yrs M/F

10mm/mV

25mm/s

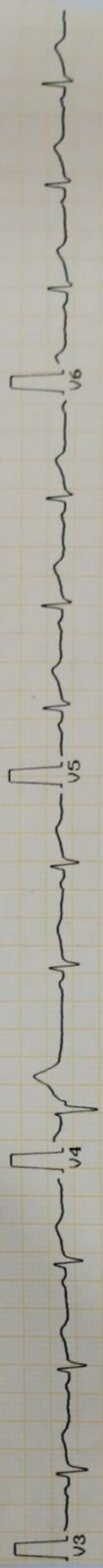
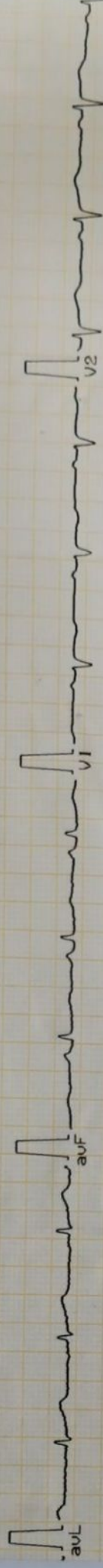
0.1-35 Hz

BLC



Vijay

LarityMed ECG50-1CH Dr.:



Dr. AMIT MOHAN
MD
Reg. No. 44559

MODERN PATHOLOGY AND DIAGNOSTIC CENTER

Gomti Nagar Lucknow

Report



VIJAYA CHAUDHARY / 39 Yrs / F / 159 Cms / 65 Kg
 Date: 29 - 03 - 2024 Refd By : APOLLO HEALTH Examined By:

Stage	Time	Duration	Speed(Kmph)	Elevation	METs	Rate	% THR	BP	RPP	PVC	Comments
Supine	00:04	0:04	00.0	00.0	01.0	089	49 %	110/70	097	00	
Standing	00:10	0:06	00.0	00.0	01.0	089	49 %	110/70	097	00	
HV	00:14	0:04	00.0	00.0	01.0	089	49 %	110/70	097	00	
ExStart	00:18	0:04	02.7	10.0	01.1	089	49 %	110/70	097	00	
PeakEx	02:27	2:09	02.7	10.0	03.7	116	64 %	138/88	160	00	
Recovery	03:27	1:00	00.0	00.0	03.7	099	55 %	136/86	134	00	
Recovery	04:27	2:00	00.0	00.0	03.7	091	50 %	132/82	120	00	
Recovery	05:27	3:00	00.0	00.0	03.7	090	50 %	126/80	113	00	
Recovery	05:39	3:11	00.0	00.0	03.7	089	49 %	126/80	112	00	

FINDINGS :

Exercise Time : 02:09
 Max HR Attained : 116 bpm 64% of Target 181
 Max BP Attained : 138/88 (mm/Hg)
 Max WorkLoad Attained : 3.7 Poor response to induced stress
 Test End Reasons : Test Complete *Stopped by client.*

REPORT :

CONCLUSIONS:

1. STRESS TEST IS NEGATIVE FOR EXERCISE INDUCED ISCHAEMIC HEART DISEASE.

[Signature]
 Dr. ANIL MOHAN MD
 Reg. No. 44559

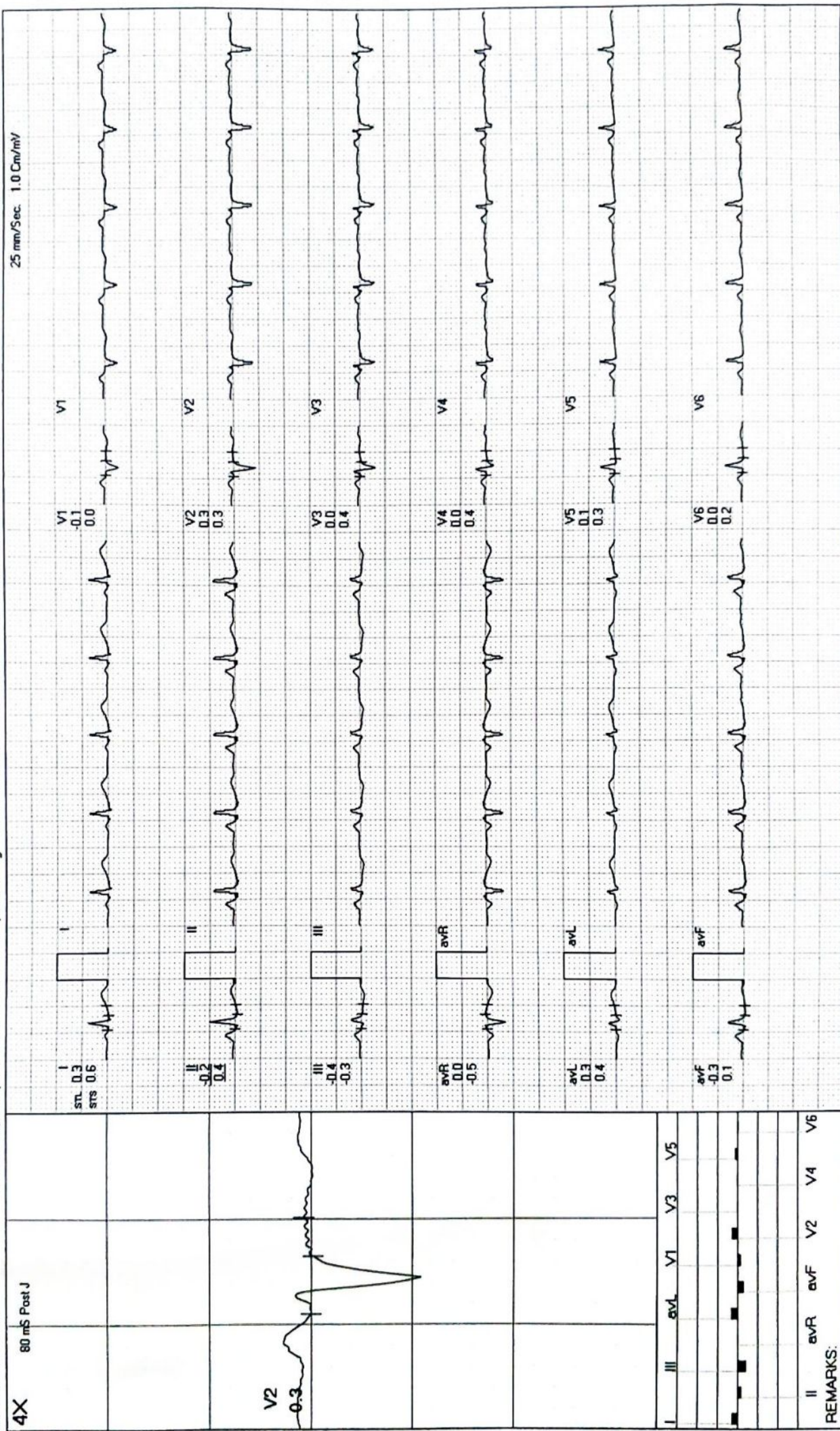
MODERN PATHOLOGY AND DIAGNOSTIC CENTER

VIJAYA CHAUDHARY / 39 Yrs / F / 159 Cms / 65 Kg / HR : 89

BRUCE:Supine(0:07)



Date: 29 - 03 - 2024 METS: 1.0/ 89 bpm 49% of THR BP: 110/70 mmHg Combined Medians/BLC On/ Notch On/ HF 0.05 Hz/LF 35 Hz ExTime 00:00 0.0 Kmph, 0.0%

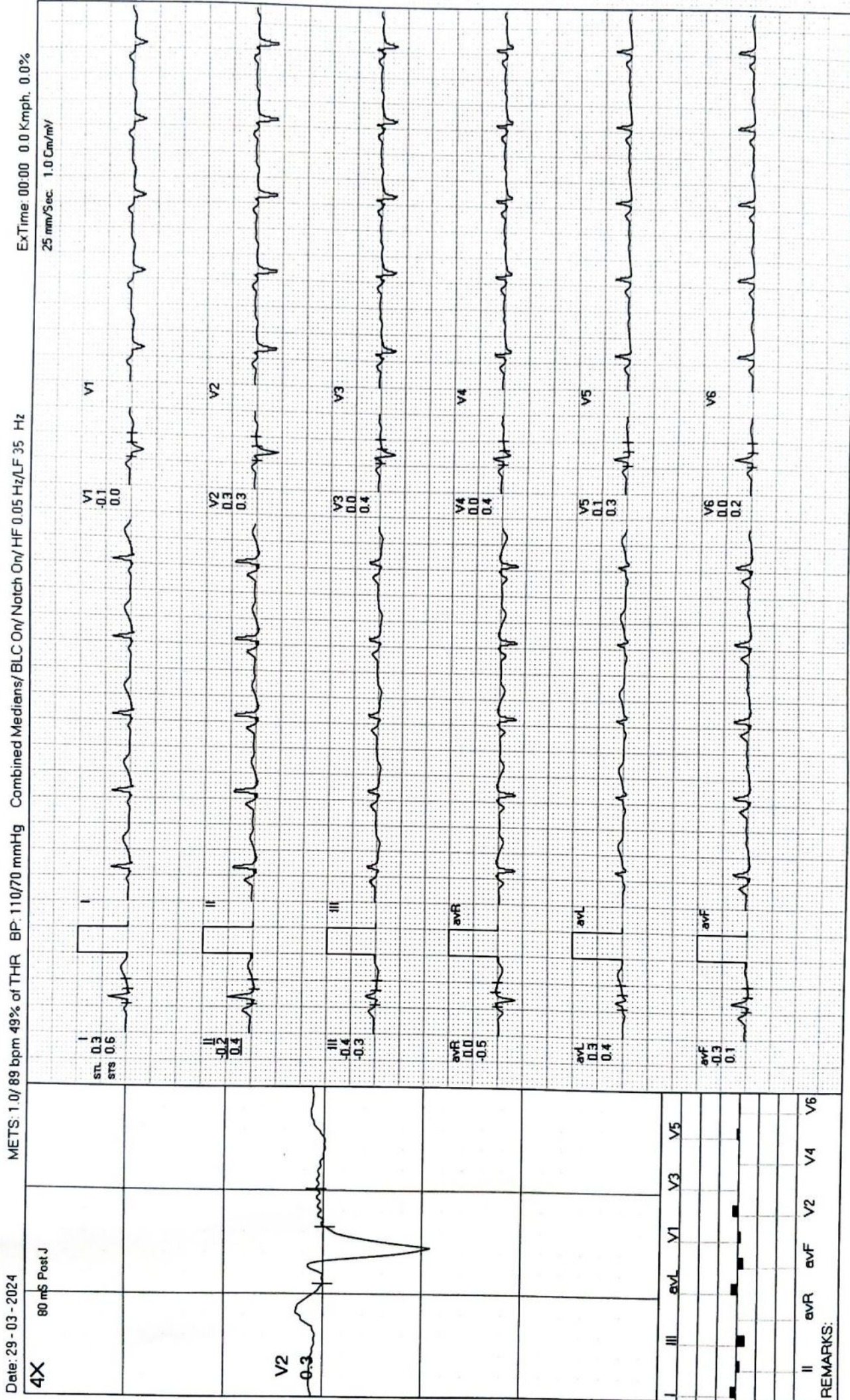

REMARKS:

MODERN PATHOLOGY AND DIAGNOSTIC CENTER

VIA YA CHAUDHARY / 39 Yrs / F / 159 Cms / 65 Kg / HR : 89

BRUCE: Standing (0:06)



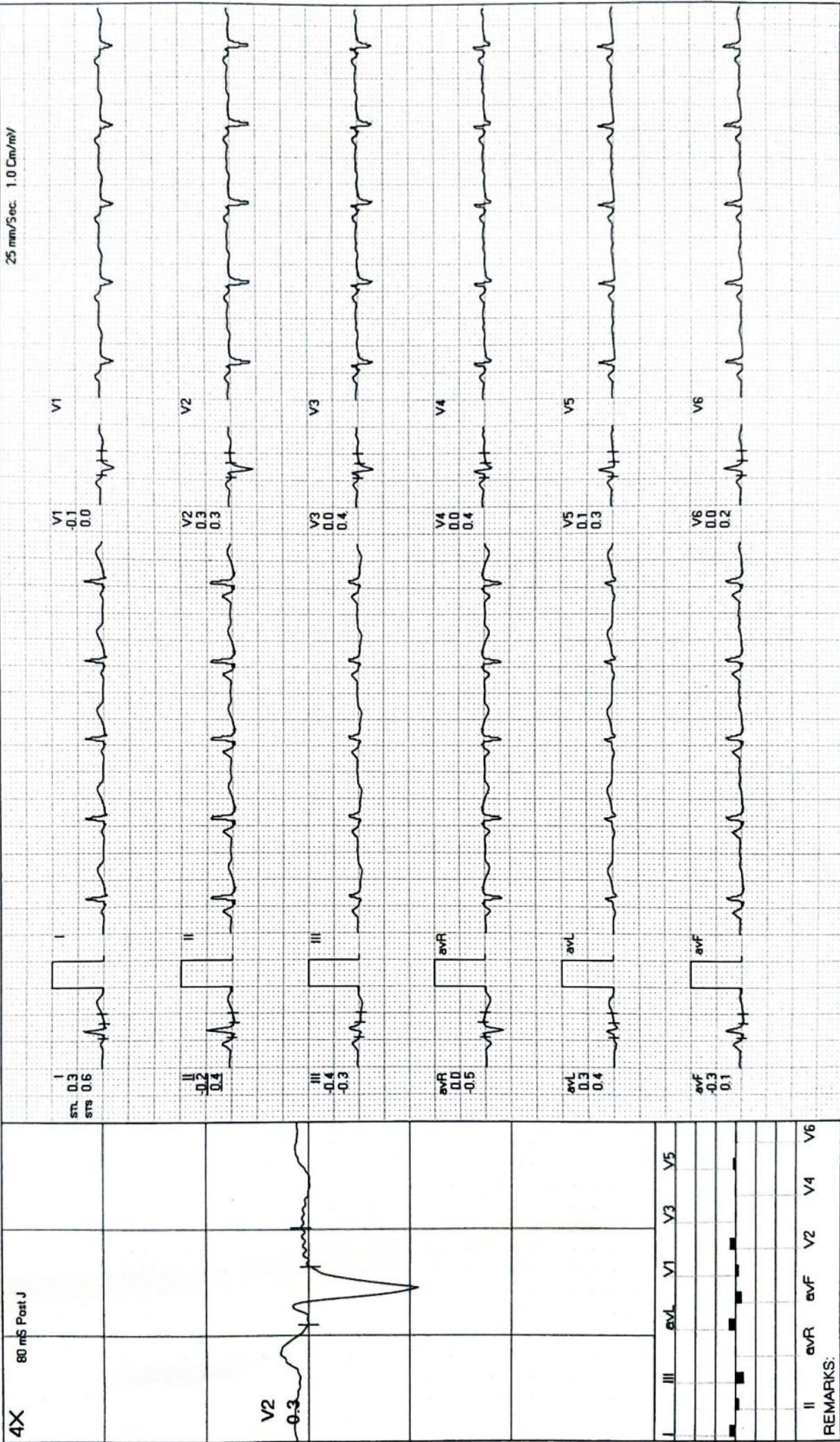


BRUCE:HV(0:04)

MODERN PATHOLOGY AND DIAGNOSTIC CENTER

VIJAYA CHAUDHARY / 39 Yrs / F / 159 Cms / 65 Kg / HR : 89

Date: 29 - 03 - 2024 METS: 1.0/89 bpm 49% of THR BP: 110/70 mmHg Combined Medions/BLC Ony/Watch Ony/HF 0.05 Hz/LF 35 Hz ExTime 00:00 0.0 Kmph, 0.0%



REMARKS:


MODERN PATHOLOGY AND DIAGNOSTIC CENTER

VIJAYA CHAUDHARY / 39 Yrs / F / 159 Cms / 65 Kg / HR : 89

ExStart



Date: 29-03-2024 METS: 1.1/89 bpm 49% of THR BP: 110/70 mmHg Combined Medians/BLC On/ HF 0.05 Hz/LF 35 Hz

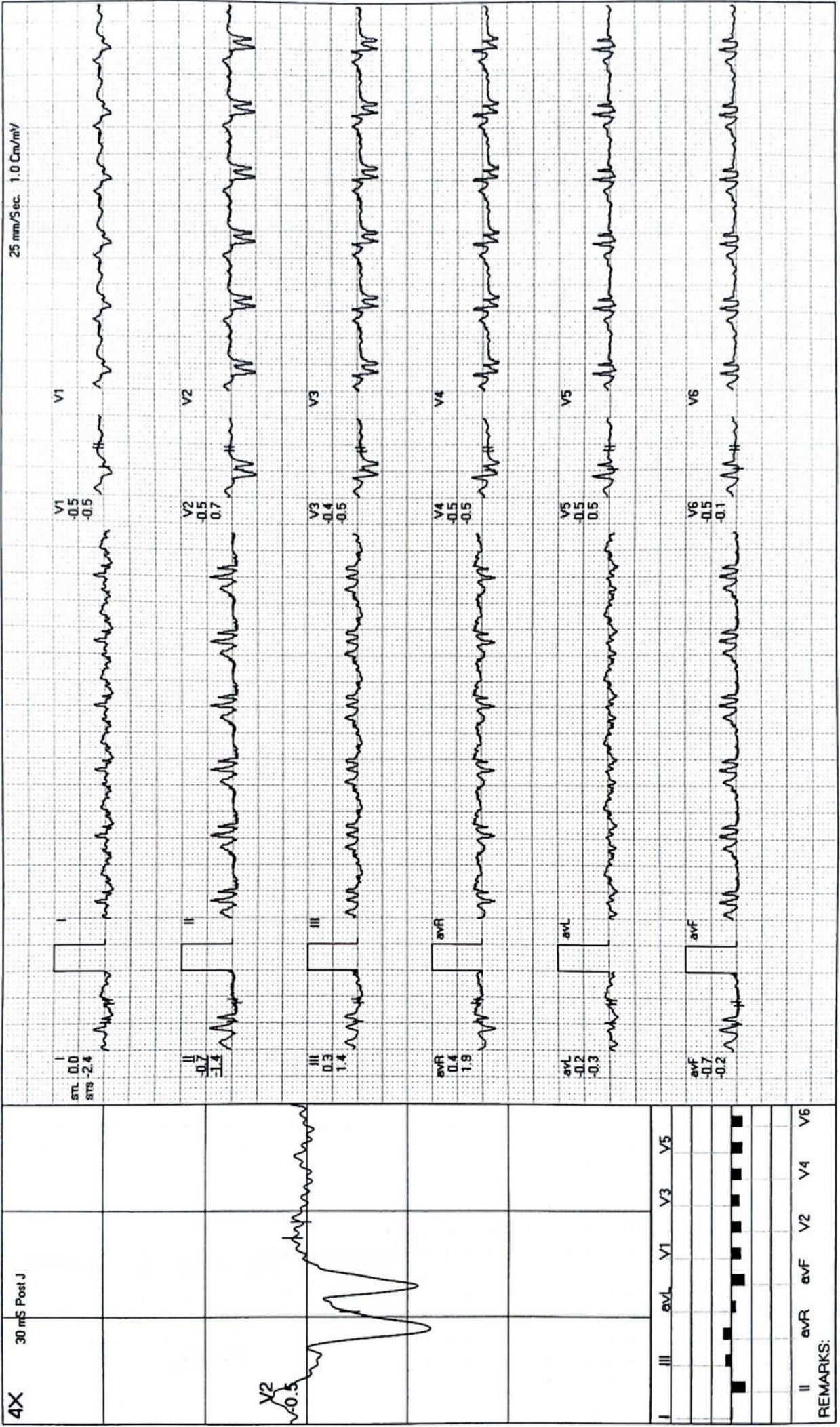


MODERN PATHOLOGY AND DIAGNOSTIC CENTER

VIJAYA CHAUDHARY / 39 Yrs / F / 159 Cms / 65 Kg / HR : 116



Date: 29-03-2024 METS: 3.7/116 bpm 64% of THR BP: 138/88 mmHg Combined Medians/BLC On/ Natch On/ HF 0.05 Hz/LF 35 Hz ExTime: 02:10 2.7 Kmph. 10.0%

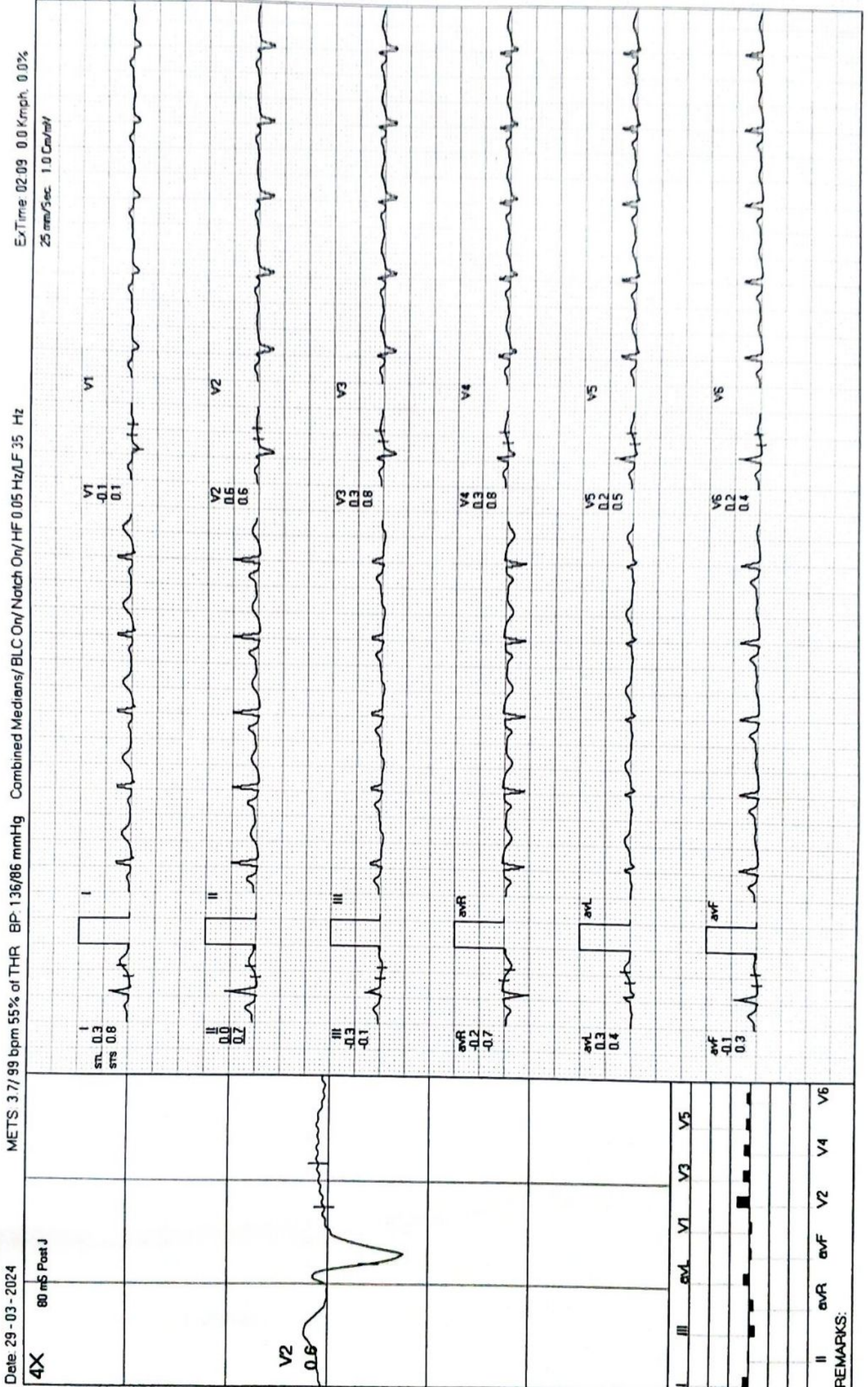


REMARKS:

MODERN PATHOLOGY AND DIAGNOSTIC CENTER

VIJAYA CHAUDHARY / 39 Yrs / F / 159 Cms / 65 Kg / HR : 99

Recovery(1:00)



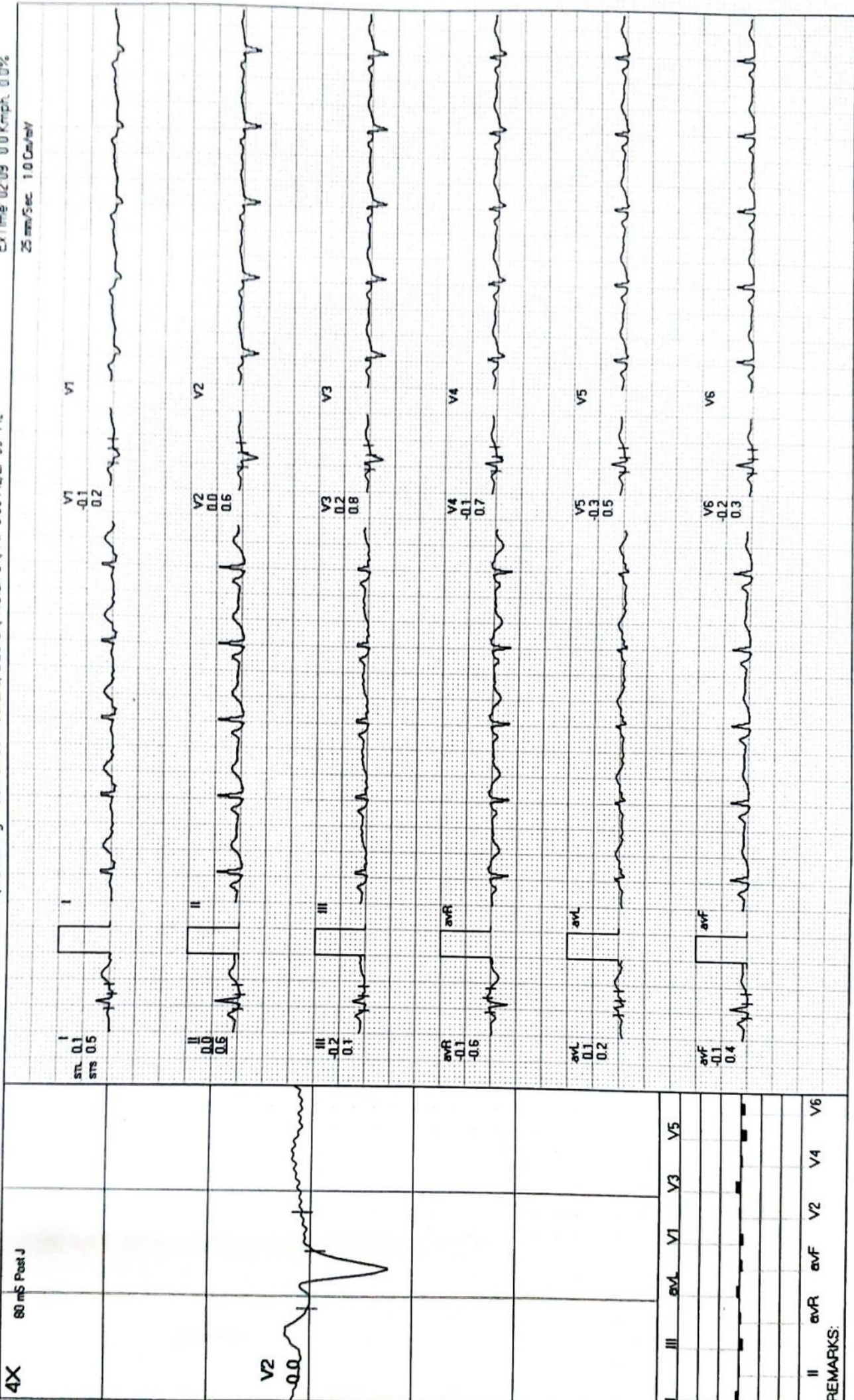
MODERN PATHOLOGY AND DIAGNOSTIC CENTER

VAJAYA CHAUDHARY / 39 Yrs / F / 159 Cms / 65 Kg / HR : 91

Recovery(2:00)



Date: 29-03-2024 METS 3.7/91 bpm 50% of THR BP: 132/82 mmHg Combined Medians/BLC Or/ HF 0.05 Hz/LF 35 Hz ExTime 02:09 0.0 Km/Ph. 0.0%
 4X 80 mS Post J 25 mm/Sec 1.0 Cm/Chy

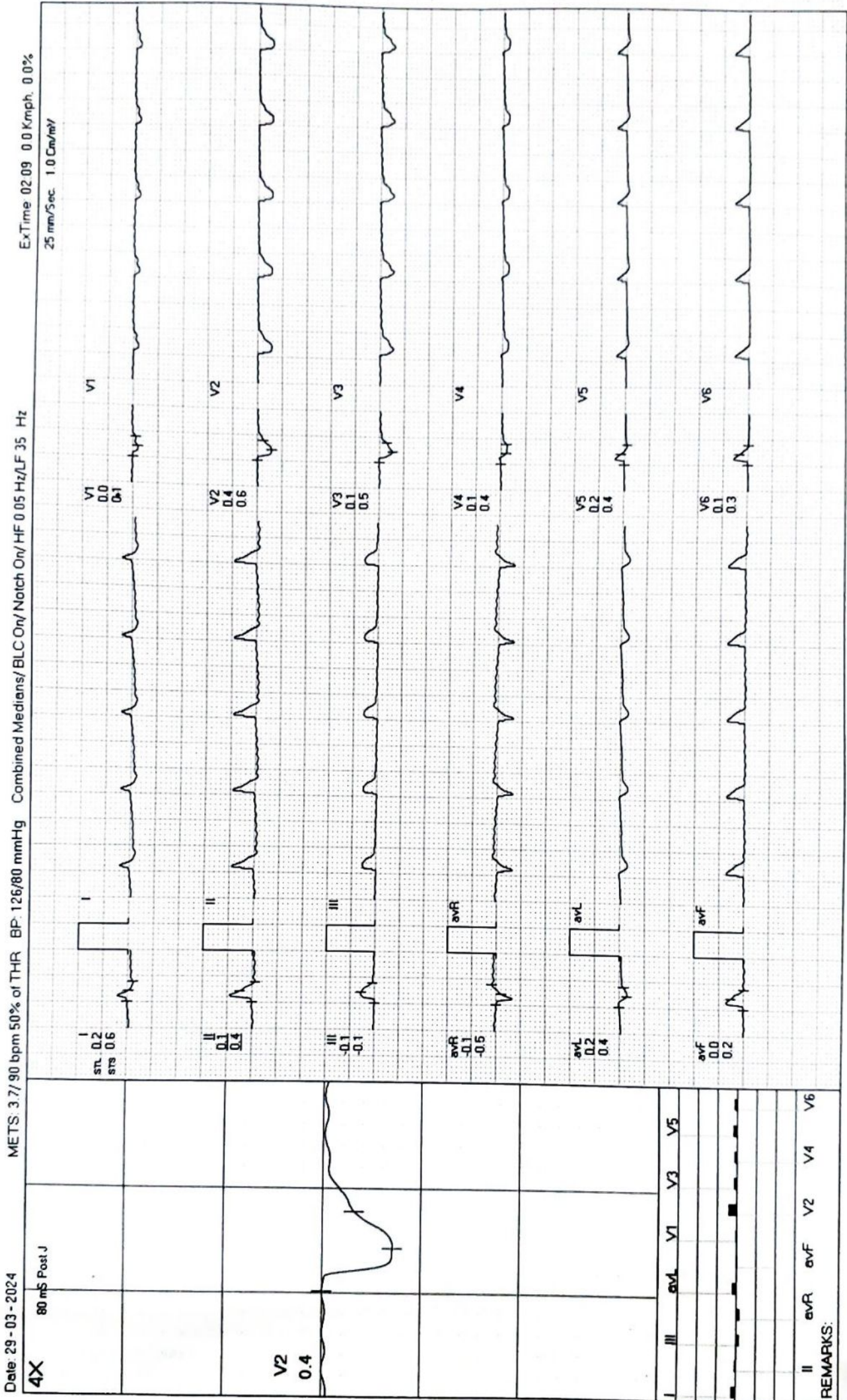
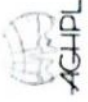

REMARKS:
 I II III aVR aVL aVF V1 V2 V3 V4 V5 V6

MODERN PATHOLOGY AND DIAGNOSTIC CENTER

VIJAYA CHAUDHARY / 39 Yrs / F / 159 Cms / 65 Kg / HR : 90

Recovery(3:00)





MODERN PATHOLOGY & DIAGNOSTIC CENTRE

CLINIC :

1/4A, Vineet Khand, (Opp Jaipuria Management)
Gomti Nagar, Lucknow - 226 010
Ph.: 0522-4008184, 4308184 • 8112323230
Mob.: 7618884441, 9450389932, 8177063877

Dr. R. P. Rastogi
M.B.B.S., M.D. (Path & Bact)



SAMPLE DATE : 29/03/2024
NAME : **Mr. Vijaya Chaudhary**
AGE/SEX : 39/YRS/FEMALE
REFERRED BY : Apollo Health

Test Name	Result	Bio. Ref. Range	Unit
-----------	--------	-----------------	------

CLINICAL PATHOLOGY TEST REPORT

PAP

GROSS:

Smears collected from the ecto and the endo cervix. Slides prepared and stained with PAP stain.

MICROSCOPIC:

- Smears studied show adequate representing material, comprising mainly of squamous epithelial cells. These cells have abundant pale pink eosinophilic cytoplasm and normal appearing round to oval nuclei. Smears from the endocervix show fair number of "stripped nuclei" of the endometrial cells. Occasional small cluster of the endometrial cells are seen. These cells have indistinct cellular borders, scanty basophilic cytoplasm and oval nuclei with clumped chromatin. Smears from both the sites are mildly infiltrated with inflammatory cells, mostly polymorphs

IMPRESSION: SMEARS SUGGESTIVE OF NORMAL PAP SMEAR WITH MODERATE INFLAMMATION

*** End Of Report ***

Dr. Sanjay Rastogi
M.B.B.S., DCP, CRIAT (BARC)

Dr. Smitha Rastogi
M.B.B.S., DCP

Results, adhering to W.H.O. and International Federation of Clinical Chemists Quality Control Standards.

SAMPLE COLLECTION FACILITY AVAILABLE

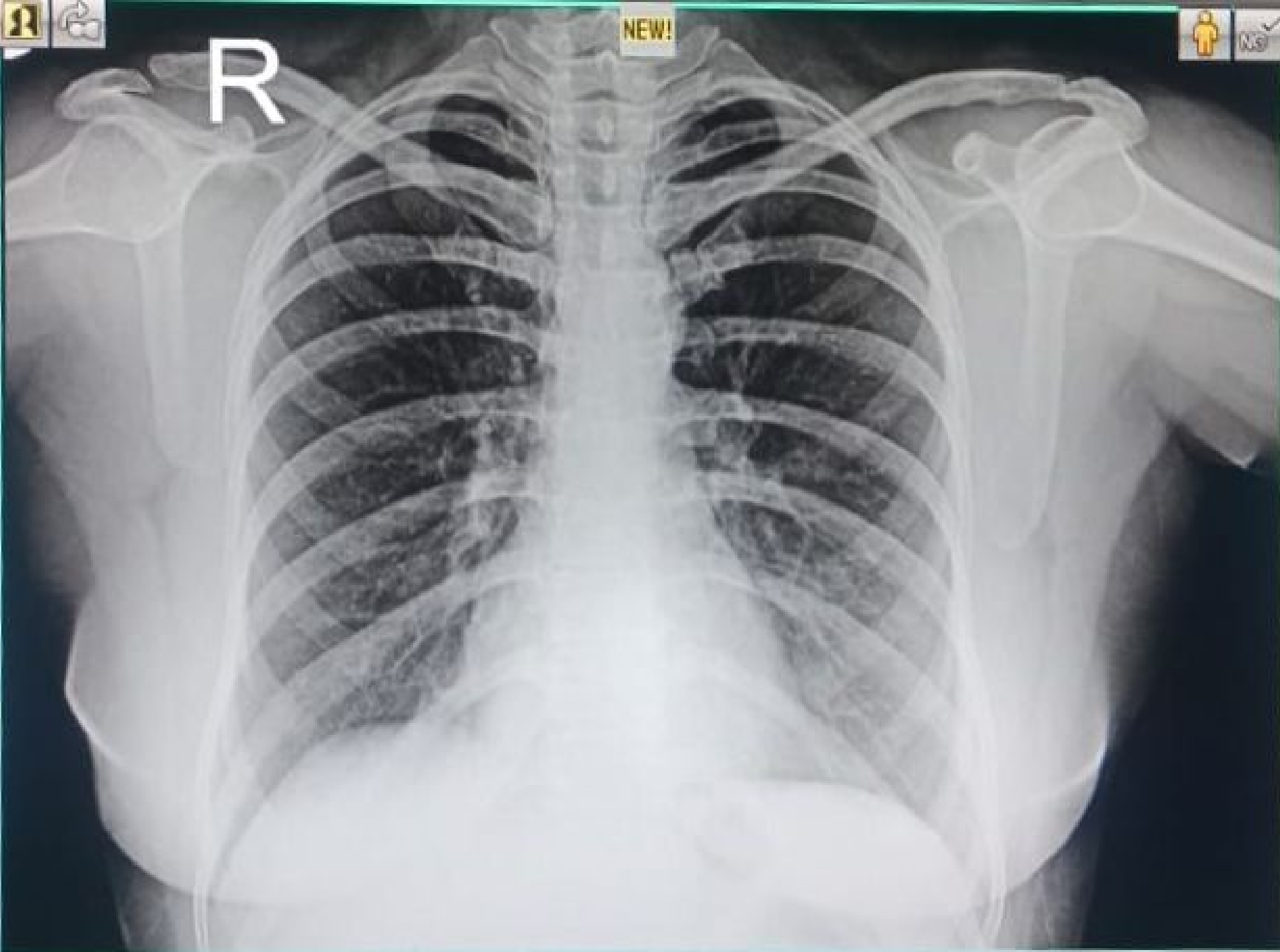
Report needs clinicopathological correlation ♦ Not for Medico Legal Purpose

e-mail : mpdcgn@gmail.com ♦ For online reports - www.modernpath.in

♦ Please ask for your computerized bill ♦ Pay only the printed collection charges



NEW!



24032903989 MRS VIJAYA CHAUDHARY 32 YRS F DR SELF CHEST PA
03/29/2024 MODERN PATHOLOGY & DIAGNOSTIC CENTRE GOMTI NAGAR LUCKNOW