

8, 9,

Name : Mrs. M LABANYA

Age: 33 Y

UHID:CMYS.0000060191

Sex: F



OP Number:CMYSOPV123779

Address : MYSORE

Bill No :CMYS-OCR-22795

Plan : ARCOFEMI MEDIWHEEL FEMALE AHC CREDIT PAN
INDIA OP AGREEMENT

Date : 23.03.2024 09:12

Sno	Service Type/ServiceName	Department
1	ARCOFEMI - MEDIWHEEL - FULL BODY HEALTH ANNUAL PLUS CHECK - FEMALE - 2D ECHO - PAN INDIA - FY2324	
1	GAMMA GLUTAMYL TRANSFERASE (GGT)	
2	2 D ECHO → P	
3	LIVER FUNCTION TEST (LFT)	
4	GLUCOSE, FASTING	
5	HEMOGRAM + PERIPHERAL SMEAR	
6	GYNAECOLOGY CONSULTATION → P	
7	DIET CONSULTATION → P	
8	COMPLETE URINE EXAMINATION	
9	URINE GLUCOSE (POST PRANDIAL)	wt - 75.5
10	PERIPHERAL SMEAR	64
11	ECG	110/80
12	LBC PAP TEST - PAPSURE skip	
13	RENAL PROFILE/RENAL FUNCTION TEST (RFT/KFT)	
14	DENTAL CONSULTATION	
15	GLUCOSE, POST PRANDIAL (PP), 2 HOURS (POST MEAL)	
16	URINE GLUCOSE (FASTING)	
17	HbA1c, GLYCATED HEMOGLOBIN	
18	X-RAY CHEST PA	
19	ENT CONSULTATION → P	
20	FITNESS BY GENERAL PHYSICIAN → P	
21	BLOOD GROUP ABO AND RH FACTOR	
22	LIPID PROFILE	
23	BODY MASS INDEX (BMI)	
24	OPHTHAL BY GENERAL PHYSICIAN	
25	ULTRASOUND - WHOLE ABDOMEN → P	
26	THYROID PROFILE (TOTAL T3, TOTAL T4, TSH)	

Alimmar done

Date : 23-03-2024
 MR NO : CMYS.0000060191
 Name : Mrs. M LABANYA
 Age/ Gender : 33 Y / Female

Department : GENERAL
 Doctor :
 Registration No :
 Qualification :

Consultation Timing: 09:12

Height : 164	Weight : 75.5	BMI :	Waist Circum :
Temp :	Pulse :	Resp :	B.P : 110/80

General Examination /
 Allergies History

B- (n)
 Th (n)
 TSH - 0.290 ↓

Clinical Diagnosis & Management Plan

clinical Hypothyroidism on Tab Thyroxin
 on 25mcg on 12yr 11/2

8/5/22
 up
 1/1
 0/1
 1/1

A
 Sep TPT alt
 3 mo

8/2
 Dr. Ravi Chethan Kumar A.M
 M.B.B.S., MD (General Med)
 KMC Reg. No. 82207
 Apollo Clinic, K.D. Road, Mysore

Follow up date :

Doctor Signature

Apollo Clinic
 # 23, 1st Floor,
 Kalidasa Road, Mysore - 02
 Ph : 0821-4005040/41

Date : 23-03-2024
MR NO : CMYS.000060191
Name : Mrs. M LABANYA
Age/ Gender : 33 Y / Female

Department : GENERAL
Doctor : RNT
Registration No :
Qualification :


Consultation Timing: 09:12

Height : 164	Weight : 75.5	BMI :	Waist Circum :
Temp :	Pulse :	Resp :	B.P : 110/80

General Examination /
Allergies History

Clinical Diagnosis & Management Plan

Docs to @
See - sh ans - slow.



Follow up date :

Doctor Signature

Apollo Clinic
23, 1st Floor,
Kalidasa Road, Mysore - 02
Ph : 0821-4006040/41

Date : 23-03-2024
MR NO : CMYS.0000060191
Name : Mrs. M LABANYA
Age/ Gender : 33 Y / Female

Department : GENERAL [dental]
Doctor :
Registration No :
Qualification :

Consultation Timing: 09:12

Height : 164	Weight : 78.5	BMI :	Waist Circum :
Temp :	Pulse :	Resp :	B.P : 110/80

General Examination /
Allergies History

Clinical Diagnosis & Management Plan

Ca+, S6+

Adv. OP

21 | 123

PPM Bridge Present
Asymptomatic

Follow up date :


Doctor Signature
Apollo Clinic
23, 1st Floor,
Kalldasa Road, Mysore - 02
Ph : 0821-4006040/41

Date : 23-03-2024
 MR NO : CMYS.0000060191
 Name : Mrs. M LABANYA
 Age/ Gender : 33 Y / Female

Department : GENERAL (Ophthal)
 Doctor :
 Registration No :
 Qualification :

Consultation Timing: 09:12

Height : 164	Weight : 75.5	BMI :	Waist Circum :
Temp :	Pulse :	Resp :	B.P : 110/80

General Examination /
 Allergies History

- Nil -


Clinical Diagnosis & Management Plan

Wearing corrected Spectacles.
 on regular wear > 25 yrs.

No H₂O Ty II DM / HTN. - on R

vision .	(R)	(L)
Far	6/6	6/6
Near	Wearing corrected Spectacles..	
colour	Not affected	

Follow up date :

Doctor Signature 

Regular check
 - laser correction

Apollo Clinic
 # 23, 1st Floor,
 Kalidasa Road, Mysore - 02
 Ph : 0821-4006040/41

Date : 23-03-2024
 MR NO : CMYS.0000060191
 Name : Mrs. M LABANYA
 Age/ Gender : 33 Y / Female

Department : GENERAL
 Doctor :
 Registration No :
 Qualification :

Consultation Timing: 09:12

Height : 164	Weight : 75.5	BMI :	Waist Circum :
Temp :	Pulse :	Resp :	B.P : 110/80

ml → 5 yrs I - US -
 Boy AWH
2 yrs 3m

General Examination /
 Allergies History
 hypothyroid m Rk
 on 6 yrs
 some OD (HOLD)
 ↓
 s. TSH →
 25/4/24
 imp in stomach.
 8.3/2m

Clinical Diagnosis & Management Plan
 ush - normal study
 sTSH ↓ 0.29

Adv: normal walk
 avoid sunbaths.

Follow up date :

Dr.

Doctor Signature

Apollo Clinic
 # 23, 1st Floor,
 Kalidasa Road, Mysore - 02
 Ph : 0821-4005040/41

Date : 23-03-2024
MR NO : CMYS.0000060191

Department : GENERAL Dietetics
Doctor : Madhura. B. P

Name : Mrs. M LABANYA
Age/ Gender : 33 Y / Female

Registration No :
Qualification : M.Sc Nutrition & Dietetics
PhD*

Consultation Timing: 09:12

FBW - 60kg

Height : 164	Weight : 75.5	BMI : 28 kg/m ²	Waist Circum : 110/80
Temp :	Pulse :	Resp :	B.P : 110/80


General Examination /
Allergies History

Clinical Diagnosis & Management Plan

ESR - 60
LDL - 106.47
TSH - 0.290

relato - Thyroid
→ Advised low calorie, high protein diet with fiber rich foods.
→ Avoid cruciferous vegetables like cabbage, cauliflower, Broccoli, soy & its products.

Follow up date :

Doctor Signature :  - B. P
23/3/2024

Apollo Clinic
23, 1st Floor,
Kalidasa Road, Mysore - 02
Ph : 0821-4006040/41

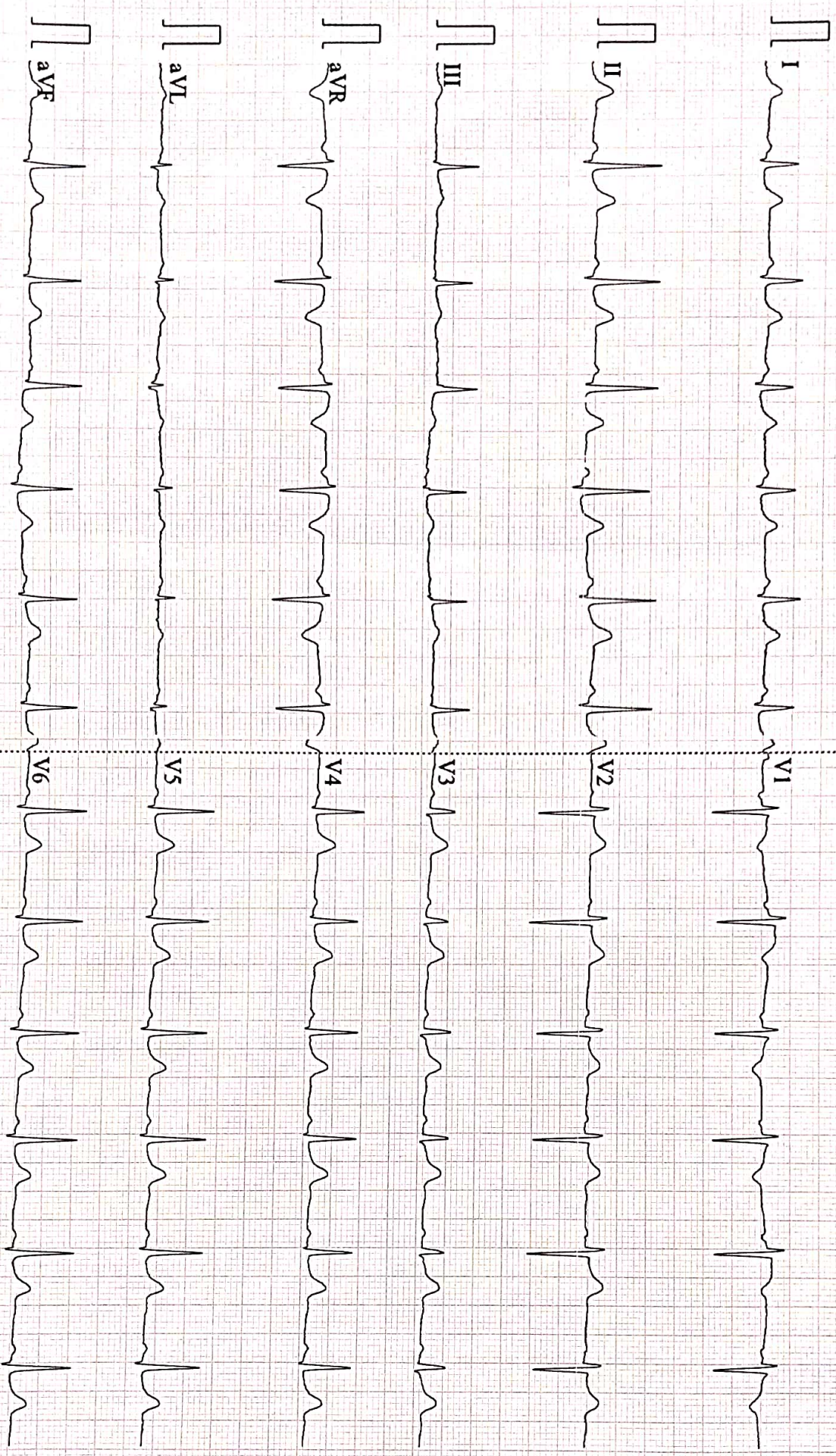
ID: 60191
MRS M LABANYA
Female 33Years
164cm 75kg 110/80 mmHg

23-03-2024 12:22:46 PM

Diagnosis Information:

Unconfirmed Report.

Apollo Clinic
23, 1st Floor,
Kalladasa Road, Mysore - 02
Ph : 0821-4006040/41



0.5~45Hz AC50 25mm/s 10mm/mV 2*5.0s 75 CARDIART 8 D V1.43 Glasgow V28.6.0 APOLLO CLINIC MYSURU

Patient Name: Mrs. M LABANYA	Date : 23.03.2024	Referring Doctor: DR Self
Age / Sex: 33Yrs/Female	UHID No :60191	Location : OP
ULTRASONOGRAPHY- ABDOMEN & PELVIS		

LIVER: It is normal in size and echotexture. No focal lesions seen. IHBR are not dilated. CBD and Portal vein are normal.

GALL BLADDER: It is well distended and normal. No calculi seen.

SPLEEN: It is normal in size, outline and echopattern. No e/o focal lesions.

PANCREAS: It is normal.

RIGHT KIDNEY: It measures 10.2x4.1 cm with parenchymal thickness of 1.1 cm. It is normal in size, outline and echotexture. No e/o calculus or hydronephrosis seen.

LEFT KIDNEY: It measures 11.0x4.4 cm with parenchymal thickness of 1.3 cm. It is normal in size, outline and echotexture. No e/o calculus or hydronephrosis seen.

URINARY BLADDER: It is well distended. The UB wall is normal. No calculi seen.

UTERUS: It is anteverted and measures 9x4.6x5.2 cm with ET= 13.5mm. It is normal in size, outline and echotexture. No mass lesion.

Rt. OVARY: It measures 3.2x1.9cm. It is normal. No mass lesion seen.

Lt. OVARY: It measures 3.1x1.4cm. It is normal. No mass lesion seen.

OTHERS: No e/o free fluid in the abdomen. No e/o lymphadenopathy. No e/o gut wall thickening. No mass lesion seen in the abdomen.

IMPRESSION: NORMAL STUDY.

Dr. Chetan H, DNB
Consultant Radiologist.

Apollo Health and Lifestyle Limited

(CIN: URS1107G20XKPLC115819)

Regd Office: 11D 6/0 6/2, Ashoka Raghupathi Chambers, 5th Floor, Begumpet, Hyderabad, Telangana - 500 016

Ph. No: (040) 4904 7777 Fax No: 4904 7744 | E-mail ID: enquiry@apollohl.com | www.apollohl.com

APOLLO CLINICS NETWORK KARNATAKA

Bangalore: Basavanagudi | Bellandur | Electronic City | Fraser Town | MSR Layout | Indira Nagar | JP Nagar | Kundalahalli |
Koramangala | Sarjapur Road | Mysore (VV Mohalla)

Online appointments: www.apolloclinic.com

TO BOOK AN APPOINTMENT

1860 500 7788

Patient's Name : Mrs. M LABANYA	Age & Sex; 33Yrs /Female
Date : 23.03.2024	UHID No:0060191

2D ECHOCARDIOGRAPHY STUDY

Impression:

- Normal chambers and valves
- No regional wall motion abnormality
- Normal left ventricular systolic function. EF 62 %
- No clots. No pericardial effusion

Findings

Left Ventricle:	No RWMA
Right Ventricle	Normal
Left Atrium	Normal
Right Atrium	Normal
Aorta	Normal
Pulmonary Artery	Normal
IAS	Intact
IVS	Intact
Valves	Normal
Pericardium	Normal
Doppler	Normal

Apollo Health and Lifestyle Limited

(CIN: URS110TG200KPLC115R19)

Regd Office: 11D RD G2, Ashoka Raghupathi Chambers, 5th Floor, Begumpet, Hyderabad, Telangana - 500 016

Ph: No: (040) 4934 7777 Fax No: 4934 7744 | Email ID: enquiry@apollohl.com | www.apollohl.com

APOLLO CLINICS NETWORK KARNATAKA

Bangalore | Basavaneswari | Bellandur | Electronic City | Fraser Town | HSR Layout | Indira Nagar | JP Nagar | Kundalahalli |
Kumaraswami | Sarjapur Road | Mysore (VV Mohalla)

Online appointments: www.apolloclinic.com

TO BOOK AN APPOINTMENT

 **1860 500 7788**

Patient's Name : Mrs. M LABANYA	Age & Sex; 33Yrs /Female
Date : 23.03.2024	UHID No:0060191

Measurements

AO : 2.4 cm
LA : 2.8 cm

RV : 2.3 cm
LVIDd 4.41 cm
LVIDs : 2.92 cm
IVSd : 0.89 cm
IVSs : 1.40 cm
PWd : 1.14 cm
PWs : 1.30 cm
EF : 62.0 %
FS : 33.0 %

Doppler
MV TV
E 1.06 m/s E --- m/s V max AV 1.69 m/s V max PV 1.46 m/s
:
A: 0.60 m/s A --- m/s

Dr. GURU PRASAD. B. V, MBBS, PGDCC
CONSULTANT – NON-INVASIVE CARDIOLOGY

Apollo Health and Lifestyle Limited

ICPN: URS110TG2000PLC1158191
Regd. Office: 1, 10, 6D, 62, Ashoka Raghupathi Chambers, 5th Floor, Begumpet, Hyderabad, Telangana - 500 016
Ph. No: (040) 4904 7777 Fax No: 4904 7744 | Email ID: enquiry@apollohl.com | www.apollohl.com

APOLLO CLINICS NETWORK KARNATAKA

Bangalore (Basavanagudi) | Bellandur | Electronic City | Fraser Town | HSR Layout | Indira Nagar | JP Nagar | Kundalahalli |
Kumarajale | Sarjapur Road | Mysore (VV Mohalla)

Online appointments: www.apolloclinic.com

TO BOOK AN APPOINTMENT

1860 500 7788

Informed Consent/Declaration For Test Exclusion

Patient Name: NOV M. Labanya Age: 33y 12

UHID Number: 60191

Please tick and sign the relevant part

I certify that I will skip LBC Papstare Test from my own.

No refund is provided for the above excluded test and i have been informed about the same.

Patient signature V Labanya Date 23/3/2024

Witness signature: A Date: 23/3/2024