



ENT - routine health check up.
Ear
Nose & Throat

Vitals :

BR 90/60 mmHg
wt. 56.1 kg
Ht. 5.1 ft

Chief Complaints :

H/O Present Illness :

Past History :

Investigation :

Drug Allergies : (if any)

Treatment :

[Signature]
23/03/20
PARK HOSPITAL
GURGAON



Park Hospital

GROUP SUPER SPECIALITY HOSPITAL



Mrs. Moni Kumari
Age 32y / F

Dr. Pradyumn
Dermatologist
23/3/2024

LAD
IFM
IACD
Vitals:

Chief Complaints:

Adv:

T. ZINCOVIT

H/O Present Illness:

Once daily
x 15 days

Past History:

nil

EXCELA MAX
LOTION

Investigation:

Drug Allergies: (if any)

Nil

(YA) ✓ ✓ ✓

Treatment:

TOPICAL 3%

ointment

gundri cream

XERINA Cream

(YA) ——— (N)
x 2 weeks

(YA) ——— (N)
x 5 day
- 7 day
- candid cream
x 2 week

R/v 20/2 weeks

Gurgaon

Q Block South City 11, Sohna Road, Main Sector-47, Gurgaon, Haryana Ph.: 0124-4900000 Fax : 0124-2218733
E-mail : parkmedicenters@gmail.com

● West Delhi ● South Delhi ● Faridabad ● Panipat ● Karnal



DENTAL

Vitals :

Chief Complaints :

H/O Present Illness :

Past History :


Stains and Calculus.

Investigation :

Drug Allergies : (if any)

Amu Sealing and Polishing

Treatment :





Park Hospital

GROUP SUPER SPECIALITY HOSPITAL

23/3/24



Meer Mohan Kumar
32y/f

Vitals :

Chief Complaints :

Routin eye checkup

H/O Present Illness :

uvv } 6/6 unaided
- 6/6

met } 11.4
- 11.6

Past History :

Investigation :

Drug Allergies : (if any)

uvv } mb
- mb

Treatment :

Colour vision - normal (B.E)

Pupils - Normal



Gurgaon

Q Block South City 11, Sohna Road, Main Sector-47, Gurgaon, Haryana Ph.: 0124-4900000 Fax : 0124-2218733
E-mail : parkmedicenters@gmail.com

● West Delhi ● South Delhi ● Faridabad ● Panipat ● Karnal



DEPARTMENT OF MICROBIOLOGY

Patient Name : Mrs. MONI KUMARI
MR No : 662275
Age/Sex : 33 Years 5 Months 28 Days / Female
Type : OPD
TPA/Corporate : MEDIWHEEL PVT LTD

Bill Date : 23/03/2024
Reporting Date : 26/03/2024
Sample ID : 263752
Bill/Req. No. : 25269825
Ref Doctor : Dr.RMO

Test	Result	Bio. Ref. Interval	Units	Method
------	--------	--------------------	-------	--------

URINE C/S

NAME OF SPECIMEN	Urine (Uncentrifuged)			
ORGANISM IDENTIFIED	NO ORGANISM GROWN IN CULTURE AFTER 48HRS OF INCUBATION AT 37 C DEGREE.			Aerobic culture

Method : .

Note : URINE CULTURE :

Presence of >105 cfu/ml (100000) in midstream urine sample is considered clinically significant. However in symptomatic, immunocompromised or diabetic patients & patients with indwelling catheters, even a smaller count of bacteria may signify infection (100000cfu/ml). Kindly correlate clinically.

***** END OF THE REPORT *****



Sample no.

Dr. JAY PRAKASH SINGH
MBBS, MD (PATHOLOGY)

Dr. ISHA RASTOGI
MD, MBBS MICROBIOLOGY
CONSULTANT CLINICAL MICROBIOLOGIST

USER NM ADITYA



MC - 4830

(This is only professional opinion and not the diagnosis, please correlate clinically)

Q Block, South City -II, Sohna Road, Sector-47, Gurgaon, Haryana Page 1 of 1

Ph.: 0124-4900000 (100 Lines), Toll Free No. : 1800-102-6767, Mob.: 62 62 82 82 35, Email: customercare@parkhospital.in

PARK GROUP OF HOSPITALS : West Delhi - Gurugram - Faridabad - Sonipat - Panipat - Karnal - Ambala - Patiala - Behror - Jaipur



DEPARTMENT OF BIOCHEMISTRY

Patient Name : Mrs. MONI KUMARI
MR No : 662275
Age/Sex : 33 Years 5 Months 28 Days / Female
Type : OPD
TPA/Corporate : MEDIWHEEL PVT LTD

Bill Date : 23/03/2024
Reporting Date : 23/03/2024
Sample ID : 263752
Bill/Req. No. : 25269825
Ref Doctor : Dr.RMO

Test	Result	Bio. Ref. Interval	Units	Method
LIPID PROFILE				
LIPID PROFILE				
TOTAL CHOLESTEROL	154	0 - 250	mg/dL	CHOD -Trinder
SERUM TRIGLYCERIDES	96	60 - 165	mg/dl	GPO-TRINDER
HDL-CHOLESTEROL	45	30 - 70	mg/dl	DIRECT
VLDL CHOLESTEROL	19.2	6 - 32	mg/dL	calculated
LDL	89.8	50 - 135	mg/dl	calculated
LDL CHOLESTEROL/HDL RATIO	2.0	1.0 - 3.0	mg/dL	calculated
TOTAL CHOLESTEROL/HDL RATIO	3.42	2.0 - 5.0	mg/dl	calculated

SAMPLE TYPE: SERUM

Note : ATP III Guidelines At-A-Glance Quick Desk Reference

Step 1 - Determine lipoprotein levels obtain complete lipoprotein profile after 9- to 12-hour fast.

ATP III Classification of LDL, Total, and HDL Cholesterol (mg/dL):-

LDL Cholesterol Primary Target of Therapy
<100 Optimal
130-159 Borderline high
>190 Very high.


Total Cholesterol
<200 Desirable
200-239 Borderline high
>240 High

HDL Cholesterol
<40 Low
>60 High

***** END OF THE REPORT *****



Sample no.



Dr. JAY PRAKASH SINGH
MBBS, MD (PATHOLOGY)

Dr. ISHA RASTOGI
MD, MBBS MICROBIOLOGY
CONSULTANT CLINICAL MICROBIOLOGIST

USER NM RAMKISHAN



MC - 4830

(This is only professional opinion and not the diagnosis, please correlate clinically) Page 1 of 1

Q Block, South City -II, Sohna Road, Sector-47, Gurgaon, Haryana

Ph.: 0124-4900000 (100 Lines), Toll Free No. : 1800-102-6767, Mob.: 62 62 82 82 35, Email: customercare@parkhospital.in

PARK GROUP OF HOSPITALS : West Delhi - Gurugram - Faridabad - Sonipat - Panipat - Karnal - Ambala - Patiala - Behror - Jaipur



DEPARTMENT OF BIOCHEMISTRY

Patient Name : Mrs. MONI KUMARI
MR No : 662275
Age/Sex : 33 Years 5 Months 28 Days / Female
Type : OPD
TPA/Corporate : MEDIWHEEL PVT LTD

Bill Date : 23/03/2024
Reporting Date : 23/03/2024
Sample ID : 263752
Bill/Req. No. : 25269825
Ref Doctor : Dr.RMO

Test	Result	Blo. Ref. Interval	Units	Method
BLOOD SUGAR FASTING				
PLASMA GLUCOSE FASTING	79	60 - 110	mg/dl	GOD TRINDERS

***** END OF THE REPORT *****



Dr. JAY PRAKASH SINGH
MBBS, MD (PATHOLOGY)

Dr. ISHA RASTOGI
MD, MBBS MICROBIOLOGY
CONSULTANT CLINICAL MICROBIOLOGIST

USER NM RAMKISHAN



MC - 4830

(This is only professional opinion and not the diagnosis, please correlate clinically) Page 1 of 1

Q Block, South City -II, Sohna Road, Sector-47, Gurgaon, Haryana

Ph.: 0124-4900000 (100 Lines), Toll Free No. : 1800-102-6767, Mob.: 62 62 82 82 35, Email: customercare@parkhospital.in

PARK GROUP OF HOSPITALS : West Delhi - Gurugram - Faridabad - Sonapat - Panipat - Karnal - Ambala - Patiala - Behror - Jaipur



DEPARTMENT OF BIOCHEMISTRY

Patient Name : Mrs. MONI KUMARI

MR No : 662275

Age/Sex : 33 Years 5 Months 28 Days / Female

Type : OPD

TPA/Corporate : MEDIWHEEL PVT LTD

Bill Date : 23/03/2024

Reporting Date : 23/03/2024

Sample ID : 263752

Bill/Req. No. : 25269825

Ref Doctor : Dr.RMO

Test	Result	Bio. Ref. Interval	Units	Method
BLOOD SUGAR 2 HR. PP				
BLOOD SUGAR P.P.	94.2	80 - 150	mg/dl	

***** END OF THE REPORT *****



Sample no.



Dr. JAY PRAKASH SINGH
MBBS, MD (PATHOLOGY)

Dr. ISHA RASTOGI
MD, MBBS MICROBIOLOGY
CONSULTANT CLINICAL MICROBIOLOGIST

USER NM AMIT1



MC - 4830

(This is only professional opinion and not the diagnosis, please correlate clinically) Page 1 of 1

Q Block, South City -II, Sohna Road, Sector-47, Gurgaon, Haryana

Ph.: 0124-4900000 (100 Lines), Toll Free No. : 1800-102-6767, Mob.: 62 62 82 82 35, Email: customercare@parkhospital.in

PARK GROUP OF HOSPITALS : West Delhi - Gurugram - Faridabad - Sonipat - Panipat - Karnal - Ambala - Patiala - Behror - Jaipur



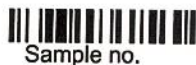DEPARTMENT OF PATHOLOGY

Patient Name : Mrs. MONI KUMARI
MR No : 662275
Age/Sex : 33 Years 5 Months 28 Days / Female
Type : OPD
TPA/Corporate : MEDIWHEEL PVT LTD

Bill Date : 23/03/2024
Reporting Date : 23/03/2024
Sample ID : 263752
Bill/Req. No. : 25269825
Ref Doctor : Dr.RMO

Test	Result	Bio. Ref. Interval	Units	Method
URINE ROUTINE AND MICROSCOPY				
PHYSICAL CHARACTERSTICS				
QUANTITY	40ml	5 - 100	ml	
COLOUR	Pale Yellow	Pale Yellow		Manual Method
TURBIDITY	Clear	clear		
SPECIFIC GRAVITY	1.020	1.000-1.030		urinometer
PH - URINE	6.0	5.0 - 9.0		PH PAPER
CHEMICAL EXAMINATION-1				
UROBILINOGEN	Negative	NIL		Ehrlich
URINE PROTEIN	Absent	NIL	mg/dl	Protein error indicator
BLOOD	NIL	NIL		
URINE BILIRUBIN	NIL	NIL		
GLUCOSE	NIL	NIL	mg/dL	GOD-POD/Benedicts
URINE KETONE	NIL	NIL		SOD.
MICRO.EXAMINATION				
PUS CELL	2-4	0-5	cells/hpf	Microscopic
RED BLOOD CELLS	Nil	0-2	cells/hpf	
EPITHELIAL CELLS	1-3	0-5	cells/hpf	
CASTS	NIL	NIL	/lpf	
CRYSTALS	NIL	NIL	/Lpf	
OTHER	NIL			
AMORPHOUS URINE	Absent			MicroScopy

***** END OF THE REPORT *****



Sample no.

Dr. JAY PRAKASH SINGH
MBBS, MD (PATHOLOGY)



Dr. ISHA RASTOGI
MD, MBBS MICROBIOLOGY
CONSULTANT CLINICAL MICROBIOLOGIST

USER NM RAVINDRA



MC - 4830

(This is only professional opinion and not the diagnosis, please correlate clinically) Page 1 of 1

Q Block, South City -II, Sohna Road, Sector-47, Gurgaon, Haryana

Ph.: 0124-4900000 (100 Lines), Toll Free No. : 1800-102-6767, Mob.: 62 62 82 82 35, Email: customercare@parkhospital.in

PARK GROUP OF HOSPITALS : West Delhi - Gurugram - Faridabad - Sonipat - Panipat - Karnal - Ambala - Patiala - Behror - Jaipur

the health care providers

the health care providers



DEPARTMENT OF HAEMATOLOGY

Patient Name : Mrs. MONI KUMARI

MR No : 662275

Age/Sex : 33 Years 5 Months 28 Days / Female

Type : OPD

TPA/Corporate : MEDIWHEEL PVT LTD

Bill Date : 23/03/2024

Reporting Date : 23/03/2024

Sample ID : 263752

Bill/Req. No. : 25269825


Ref Doctor : Dr.RMO

Test	Result	Bio. Ref. Interval	Units	Method
BLOOD GROUPING AND RH FACTOR				
BLOOD GROUP	"AB" RH POSITIVE			ABO/Rh (D) SLIDE

***** END OF THE REPORT *****



Sample no.



Dr. JAY PRAKASH SINGH
MBBS, MD (PATHOLOGY)

Dr. ISHA RASTOGI
MD, MBBS MICROBIOLOGY
CONSULTANT CLINICAL MICROBIOLOGIST

USER NM RAVINDRA



MC - 4830

(This is only professional opinion and not the diagnosis, please correlate clinically) Page 1 of 1

Q Block, South City -II, Sohna Road, Sector-47, Gurgaon, Haryana

Ph.: 0124-4900000 (100 Lines), Toll Free No. : 1800-102-6767, Mob.: 62 62 82 82 35, Email: customer@parkhospital.in

PARK GROUP OF HOSPITALS : West Delhi - Gurugram - Faridabad - Sonapat - Panipat - Karnal - Ambala - Patiala - Behror - Jaipur

the **health** care providers

the **health** care providers



DEPARTMENT OF HAEMATOLOGY

Patient Name : Mrs. MONI KUMARI
 MR No : 662275
 Age/Sex : 33 Years 5 Months 28 Days / Female
 Type : OPD
 TPA/Corporate : MEDIWHEEL PVT LTD


Bill Date : 23/03/2024
 Reporting Date : 23/03/2024
 Sample ID : 263752
 Bill/Req. No. : 25269825
 Ref Doctor : Dr.RMO

Test	Result	Bio. Ref. Interval	Units	Method
CBC				
HAEMOGLOBIN	10.8	L 12 - 15	gm/dL	COLORIMETRY
TOTAL LEUCOCYTE COUNT	4800	4000-11000	/μL	LASER FLOW
DIFFERENTIAL COUNT				
NEUTROPHILS	50	40.0 - 70.0	%	FLOW CYTOMETRY
LYMPHOCYTES	40	20.0 - 40.0	%	FLOW CYTOMETRY
MONOCYTES	06	3.0 - 8.0	%	FLOW CYTOMETRY
EOSINOPHILS	04	0.5 - 5.0	%	FLOW CYTOMETRY
BASOPHILS	00	0.0 - 2.0	%	FLOW CYTOMETRY
RED BLOOD CELL COUNT	4.02	3.5 - 5.5	millions/μL	ELECTRICAL
PACKED CELL VOLUME	34.8	L 35.0 - 50.0	%	ELECTRICAL
MEAN CORPUSCULAR VOLUME	86.6	83 - 101	fL	ELECTRICAL
MEAN CORPUSCULAR HAEMOGLOBIN	26.9	L 27 - 31	Picogrames	CALCULATED
MEAN CORPUSCULAR HB CONC	31.0	L 33 - 37	g/dl	CALCULATED
PLATELET COUNT	202	150 - 450	thou/μL	ELECTRICAL
RDW	15.9	H 11.6 - 14.5	%	CALCULATED
SAMPLE TYPE FOR C.B.C	Whole Blood EDTA			

***** END OF THE REPORT *****



Sample no.



Dr. ISHA RASTOGI
 MD, MBBS MICROBIOLOGY
 CONSULTANT CLINICAL MICROBIOLOGIST

USER NM : RAMKISHAN



MC - 4830

(This is only professional opinion and not the diagnosis, please correlate clinically)
 Q Block, South City -II, Sohna Road, Sector-47, Gurgaon, Haryana
 Ph.: 0124-4900000 (100 Lines), Toll Free No. : 1800-102-6767, Mob.: 62 62 82 82 35, Email: customercare@parkhospital.in
 PARK GROUP OF HOSPITALS : West Delhi - Gurugram - Faridabad - Sonapat - Panipat - Karnal - Ambala - Patiala - Behror - Jaipur



DEPARTMENT OF HAEMATOLOGY

Patient Name : Mrs. MONI KUMARI
MR No : 662275
Age/Sex : 33 Years 5 Months 28 Days / Female
Type : OPD
TPA/Corporate : MEDIWHEEL PVT LTD

Bill Date : 23/03/2024
Reporting Date : 23/03/2024
Sample ID : 263752
Bill/Req. No. : 25269825
Ref Doctor : Dr.RMO

Test	Result	Bio. Ref. Interval	Units	Method
------	--------	--------------------	-------	--------

ESR (WESTERGREN)

E.S.R .1ST HRS.	15	0 - 20	mm/Hr.	Westergren
SPECIMEN TYPE	WHOLE BLOOD-EDTA			


Method : (Capillary photometry)

- Note** :
1. C-Reactive Protein (CRP) is the recommended test in acute inflammatory conditions.
 2. Test conducted on EDTA whole blood at 37C.
 3. ESR readings are auto- corrected with respect to Hematocrit (PCV) values.

***** END OF THE REPORT *****



Sample no.



Dr.ISHA RASTOGI
MD, MBBS MICROBIOLOGY
CONSULTANT CLINICAL MICROBIOLOGIST

USER NM RAMKISHAN



MC - 4830

(This is only professional opinion and not the diagnosis, please correlate clinically)
Q Block, South City -II, Sohna Road, Sector-47, Gurgaon, Haryana
Ph.: 0124-4900000 (100 Lines), Toll Free No. : 1800-102-6767, Mob.: 62 62 82 82 35, Email: customercare@parkhospital.in

PARK GROUP OF HOSPITALS : West Delhi - Gurugram - Faridabad - Sonipat - Panipat - Karnal - Ambala - Patiala - Behror - Jaipur

the **health** care providers

the **health** care providers



DEPARTMENT OF IMMUNOLOGY

Patient Name : Mrs. MONI KUMARI
MR No : 662275
Age/Sex : 33 Years 5 Months 28 Days / Female
Type : OPD
TPA/Corporate : MEDIWHEEL PVT LTD

Bill Date : 23/03/2024
Reporting Date : 24/03/2024
Sample ID : 263752
Bill/Req. No. : 25269825
Ref Doctor : Dr.RMO

Test	Result	Blo. Ref. Interval	Units	Method
THYROID PROFILE				
TRI-IODOTHYRONINE (T3)	1.07	0.60 - 1.81	ng/ml	Chemiluminescence
THYROXINE (T4)	8.5	5.01 - 12.45	µg/dL	Chemiluminescence
THYROID STIMULATING HORMONE	1.70	0.5-5.50 ,	µIU/ml	Chemiluminescence

Method : chemiluminescent immunoassay

Note : Clinical Significance:

Thyroid function tests (TFTs) is a collective term for blood tests used to check the function of the thyroid. TFTs may be requested if a patient is thought to suffer from hyperthyroidism (overactive thyroid) or hypothyroidism (underactive thyroid), or to monitor the effectiveness of either thyroid-suppression or hormone replacement therapy. It is also requested routinely in conditions linked to thyroid disease, such as atrial fibrillation and anxiety disorder. A TFT panel typically includes thyroid hormones such as thyroid-stimulating hormone (TSH, thyrotropin) and thyroxine (T4), and triiodothyronine (T3) depending on local laboratory policy.

Note: Please correlate with clinical condition

***** END OF THE REPORT *****



Sample no.

Dr. JAY PRAKASH SINGH
 MBBS, MD (PATHOLOGY)



Dr. ISHA RASTOGI
 MD, MBBS MICROBIOLOGY
 CONSULTANT CLINICAL MICROBIOLOGIST

USER NM NIKHIL



MC - 4830

(This is only professional opinion and not the diagnosis, please correlate clinically)
 Q Block, South City -II, Sohna Road, Sector-47, Gurgaon, Haryana
 Ph.: 0124-4900000 (100 Lines), Toll Free No. : 1800-102-6767, Mob.: 62 62 82 82 35, Email: customercare@parkhospital.in

PARK GROUP OF HOSPITALS : West Delhi - Gurugram - Faridabad - Sonipat - Panipat - Karnal - Ambala - Patiala - Behror - Jaipur



DEPARTMENT OF BIOCHEMISTRY

Patient Name : Mrs. MONI KUMARI
MR No : 662275
Age/Sex : 33 Years 5 Months 28 Days / Female
Type : OPD
TPA/Corporate : MEDIWHEEL PVT LTD

Bill Date : 23/03/2024
Reporting Date : 23/03/2024
Sample ID : 263752
Bill/Req. No. : 25269825
Ref Doctor : Dr.RMO

Test	Result	Bio. Ref. Interval	Units	Method
LFT (LIVER FUNCTION TEST)				
LFT				
TOTAL BILIRUBIN	0.3	0 - 1.2	mg/dL	DIAZO
DIRECT BILIRUBIN	0.2	0 - 0.4	mg/dL	DIAZO
INDIRECT BILIRUBIN	0.1	0.10 - 0.6	mg/dL	CALCULATED
SGOT (AST)	26	0 - 45	U/L	IFCC WITHOUT
SGPT (ALT)	15	0 - 45	U/L	IFCC WITHOUT
ALKALINE PHOSPHATASE	59	30 - 170	IU/L	MODIFIED IFCC
TOTAL PROTEINS	7.6	6.4 - 8.0	g/dL	BIURET
ALBUMIN	4.1	3.3 - 5.5	g/dL	BCG DYE
GLOBULIN	3.5	2.3 - 4.5	g/dL	CALCULATED
A/G RATIO	1.17	1.1 - 2.2		CALCULATED
SAMPLE TYPE:	SERUM			

***** END OF THE REPORT *****

Sample no. 

PARK HOSPITAL
Par
Dr. JAY PRAKASH SINGH
MBBS, MD (PATHOLOGY)
GURGAON

Dr. ISHA RASTOGI
MD, MBBS MICROBIOLOGY
CONSULTANT CLINICAL MICROBIOLOGIST

USER NM RAMKISHAN



MC - 4830

(This is only professional opinion and not the diagnosis, please correlate clinically) Page 1 of 1

Q Block, South City -II, Sohna Road, Sector-47, Gurgaon, Haryana
Ph.: 0124-4900000 (100 Lines), Toll Free No. : 1800-102-6767, Mob.: 62 62 82 82 35, Email: customercare@parkhospital.in

PARK GROUP OF HOSPITALS : West Delhi - Gurugram - Faridabad - Sonipat - Panipat - Karnal - Ambala - Patiala - Behror - Jaipur

the health care providers

the health care providers



DEPARTMENT OF BIOCHEMISTRY

Patient Name : Mrs. MONI KUMARI
MR No : 662275
Age/Sex : 33 Years 5 Months 28 Days / Female
Type : OPD
TPA/Corporate : MEDIWHEEL PVT LTD

Bill Date : 23/03/2024
Reporting Date : 23/03/2024
Sample ID : 263752
Bill/Req. No. : 25269825
Ref Doctor : Dr.RMO

Test	Result	Bio. Ref. Interval	Units	Method
KFT (RENAL PROFILE)				
KFT				
SERUM UREA	21	10 - 45	mg/dL	
SERUM CREATININE	0.8	0.4 - 1.4	mg/dL	MODIFIED JAFFES
SERUM URIC ACID	4.2	2.5 - 7.0	mg/dL	URICASE
SERUM SODIUM	139	135 - 150	mmol/L	ISE
SERUM POTASSIUM	4.0	3.5 - 5.5	mmol/L	ISE
SERUM CALCIUM	8.7	8.5 - 10.5	mg/dL	ARSENazo III
SERUM PHOSPHORUS	3.3	2.5 - 4.5	mg/dL	AMMONIUM
SAMPLE TYPE:	SERUM			

***** END OF THE REPORT *****



Sample no.



Dr. JAY PRAKASH SINGH
MBBS, MD (PATHOLOGY)

Dr. ISHA RASTOGI
MD, MBBS MICROBIOLOGY
CONSULTANT CLINICAL MICROBIOLOGIST

USER NM RAMKISHAN



MC - 4830

(This is only professional opinion and not the diagnosis, please correlate clinically)

Q Block, South City -II, Sohna Road, Sector-47, Gurgaon, Haryana

Ph.: 0124-4900000 (100 Lines), Toll Free No. : 1800-102-6767, Mob.: 62 62 82 82 35, Email: customercare@parkhospital.in

PARK GROUP OF HOSPITALS : West Delhi - Gurugram - Faridabad - Sonapat - Panipat - Karnal - Ambala - Patiala - Behror - Jaipur



DEPARTMENT OF RADIOLOGY

Patient Name	Mrs. MONI KUMARI	Billed Date	: 23/03/2024
Reg No	662275	Reported Date	: 23/03/2024
Age/Sex	33 Years 5 Months 28Days / Female	Req. No.	: 25269825
Type	OPD	Consultant Doctor	: Dr. RMO

X-RAY CHEST AP/PA

Bilateral lungs appears normal.

No focal lung lesion seen.

No evidence of free fluid is seen.

Both hila are normal in size, have equal density and bear normal relationship.

The heart and trachea are central in position and no mediastinal abnormality is visible.

The cardiac size is normal for patient age and view.

The domes of the diaphragms are normal in position, and show smooth outline.

To be correlated clinically



Dr. ANSHU K. SHARMA
MBBS, MD
CONSULTANT RADIOLOGIST

Dr. MANJEET SEHRAWAT
MBBS, MD, PDCC
CONSULTANT RADIOLOGIST

ALISHA KHAN
MEDICAL TRANSCRIPTIONIST

Dr. NEENA SIKKA
MBBS, DNB
CONSULTANT RADIOLOGIST

RAJNISH SHARMA
MEDICAL
TRANSCRIPTIONIST

Q Block, South City -II, Sohna Road, Sector-47, Gurgaon, Haryana

Ph.: 0124-4900000 (100 Lines), Toll Free No. : 1800-102-6767, Mob.: 62 62 82 82 35, Email: customercare@parkhospital.in

PARK GROUP OF HOSPITALS : West Delhi - Gurugram - Faridabad - Sonapat - Panipat - Karnal - Ambala - Patiala - Behror - Jaipur



DEPARTMENT OF RADIOLOGY

Patient Name	Mrs. MONI KUMARI	Billed Date	: 23/03/2024
Reg No	662275	Reported Date	: 23/03/2024
Age/Sex	33 Years 5 Months 28Days / Female	Req. No.	: 25269825
Type	OPD	Consultant Doctor	: Dr. RMO

USG WHOLE ABDOMEN

The real time, B mode, gray scale sonography of the abdominal organs was performed.

LIVER : The liver is normal in size (13.8cm), shape and echotexture. No evidence of any focal lesion. IHBR is not dilated.

GALL BLADDER : The gall bladder is well distended. No evidence any calculus or mass seen. GB wall thickness with in normal limits. No evidence of pericholecystic fluid is seen.

BILE DUCT :The common bile duct is normal in caliber. No evidence of calculus is noted in common bile duct.

SPLEEN :The spleen is normal in size (9.3cm) and shape.Its echotexture is homogeneous.No evidence of focal lesion is noted.

PANCREAS :The pancreas is normal in size, shape, contours and echotexture.No evidence of solid or cystic mass lesion is noted.MPD is not dilated. No evidence of peripancreatic collection.

KIDNEYS : Right kidney measures 9.3 x 4.5 cm. Left kidney measures 9.4 x 5.2 cm. The bilateral kidneys are normal in size and echotexture. Cortico-medullary differentiation is maintained.There is no evidence of obvious calculus or hydronephrosis.

URINARY BLADDER :The urinary bladder is partially distended.

UTERUS: The uterus is anteverted. It measures 6.8 x 4.3 x 4.1 cms. in the longitudinal, anteroposterior and transverse dimensions respectively.



Cert. No. H-2016-0369

(This is only professional opinion and not the diagnosis, please correlate clinically)

Q Block, South City -II, Sohna Road, Sector-47, Gurgaon, Haryana

Ph.: 0124-4900000 (100 Lines), Toll Free No. : 1800-102-6767, Mob.: 62 62 82 82 35, Email: customercare@parkhospital.in

PARK GROUP OF HOSPITALS : West Delhi - Gurugram - Faridabad - Sonipat - Panipat - Karnal - Ambala - Patiala - Behror - Jaipur



There is evidence of well defined hypochoic lesion of size 25 x 19 mm noted in the posterior myometrium s/o uterine fibroid.

The endometrial echo is in the midline and measures 6.1 mm.

Right ovary is normal.

Left ovary shows a simple cyst of size 50 x 48 mm.

No evidence of ascites or interbowel free fluid is seen.

No evidence of obvious retroperitoneal or mesentric lymphadenopathy is seen.

Bowel loop distended with gas.

IMPRESSION-

-Uterine fibroid.

-Left ovarian simple cyst.

To be correlated clinically.



Dr. ANSHU K. SHARMA
MBBS, MD
CONSULTANT RADIOLOGIST
Cert. No. H-2016-0369

Dr. MANJEET SEHRAWAT
MBBS, MD, PDCC
CONSULTANT RADIOLOGIST

ALISHA KHAN
MEDICAL TRANSCRIPTIONIST

Dr. NEENA SIKKA
MBBS, DNB
CONSULTANT RADIOLOGIST

RAJNISH SHARMA
MEDICAL
TRANSCRIPTIONIST

Q Block, South City -II, Sohna Road, Sector-47, Gurgaon, Haryana

Ph.: 0124-4900000 (100 Lines), Toll Free No. : 1800-102-6767, Mob.: 62 62 82 82 35, Email: customercare@parkhospital.in

PARK GROUP OF HOSPITALS : West Delhi - Gurugram - Faridabad - Sonapat - Panipat - Karnal - Ambala - Patiala - Behror - Jaipur



NAME	: MRS. MONI KUMARI	DATE	: 23 / 3 / 2024
Age Sex	: 32 Years / Female	Inpatient No	: 662275
PERFORMED BY	: Dr. SWATI SINGH	BILL NO.	: 25269825

TRANS THORACIC ECHO CARDIOGRAPHY REPORT

MITRAL VALVE

Morphology AML: Normal / Thickening / Calcification / Flutter / Vegetation / Non significant Prolapse / SAM
PML: Normal / Thickening / Calcification / Prolapse / Paradoxical Motion / Fixed.
Subvalvular deformity: Present / Absent

Doppler Normal / Abnormal
Mitral Stenosis Present / Absent
Mitral Regurgitation; Absent / Normal / Mild / Trace / Moderate / Severe

TRICUSPID VALVE

Morphology Normal / Atresia / Thickening / Calcification / Prolapse / Vegetation / Doming.
Doppler Normal / Abnormal
Tricuspid Stenosis: Present / Absent.
Tricuspid Regurgitation: Absent / Mild / Trace / Moderate

PULMONARY VALVE

Morphology Normal / Atresia / Thickening / Calcified / Doming / Vegetation.
Doppler Normal / Abnormal.
Pulmonary Stenosis: Present / Absent
Pulmonary regurgitation: Present / Absent

AORTIC VALVE

Morphology Normal / Thickened / Mildly / Calcified / Flutter / Vegetation / Restricted / Opening
No. of Cusps 1 / 2 / 3 / 4
Doppler Normal / Abnormal
Aortic Stenosis : Present / Absent
Aortic regurgitation : Present / Absent / Mild / Trace / Moderate / Severe



Cert. No. H-2016-0369

(This is only professional opinion and not the diagnosis, please correlate clinically)
Q Block, South City -II, Sohna Road, Sector-47, Gurgaon, Haryana

Ph.: 0124-4900000 (100 Lines), Toll Free No. : 1800-102-6767, Mob.: 62 62 82 82 35, Email: customercare@parkhospital.in

PARK GROUP OF HOSPITALS : West Delhi - Gurugram - Faridabad - Sonapat - Panipat - Karnal - Ambala - Patiala - Behror - Jaipur



<u>Measurements</u>	<u>Normal Values</u>	<u>Measurements</u>	<u>Normal Value</u>
IVSD : 0.9cm	(0.6-1.1cm)	LA : 2.4cm	(1.9-4.0cm)
LVIDd : 4.1cm	(3.7-5.6cm)	AORTA : 1.8cm	(2.0-3.7cm)
LVIDs : 2.6cm	(0.6-1.1cm)	IVSmotion :	Normal / Flat / Paradoxical
EF : 55-60%	(55% - 80%)		
Any Other			

CHAMBERS:-

LV **Normal** / Enlarged / **Clear** / Thrombus /
Contraction Normal LV shows concentric LVH, no gradient across LVOT / Inetic / Intra capillary
Regional wall motion abnormality: **Absent**/ Present

LA **Normal** / Enlarged / Clear / Thrombus / Myxoma; **LAA: Clear** / Thrombus

RA **Normal** / **Clear** / Thrombus, Dilated.

RV **Normal** / Mildly Dilated / Enlarged / **Clear** / Thrombus / Hypertrophied

PERICARDIUM **Normal** / Thickening / Calcification / Effusion.

SUMMARY:-

- All Cardiac Chambers dimensions are within normal limits.
- NO RWMA
- LVEF -55-60%
- NORMAL LV FUNCTION
- NO MR / NO AR / NO TR
- GOOD RV FUNCTION
- IAS/IVS. No Flow seen across IAS/IVS.
- No Thrombus/Mass in any chamber.
- No Pericardial Effusion.


COMMENTS:- Normal LV Function.

Please correlate clinically

Dr. SWATI SINGH

M.D. (Medicine)

D.M. (Cardiology)



Cert. No. H-2016-0369

(This is only professional opinion and not the diagnosis, please correlate clinically)

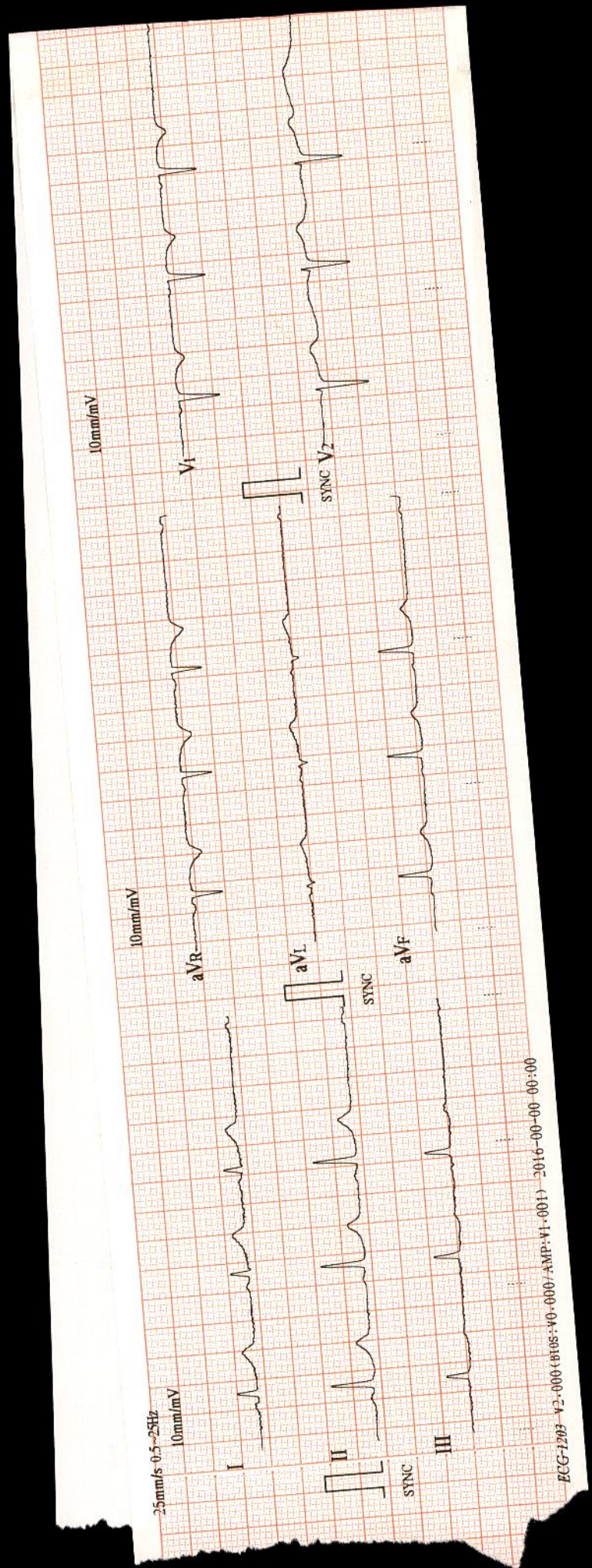
Q Block, South City -II, Sohna Road, Sector-47, Gurgaon, Haryana

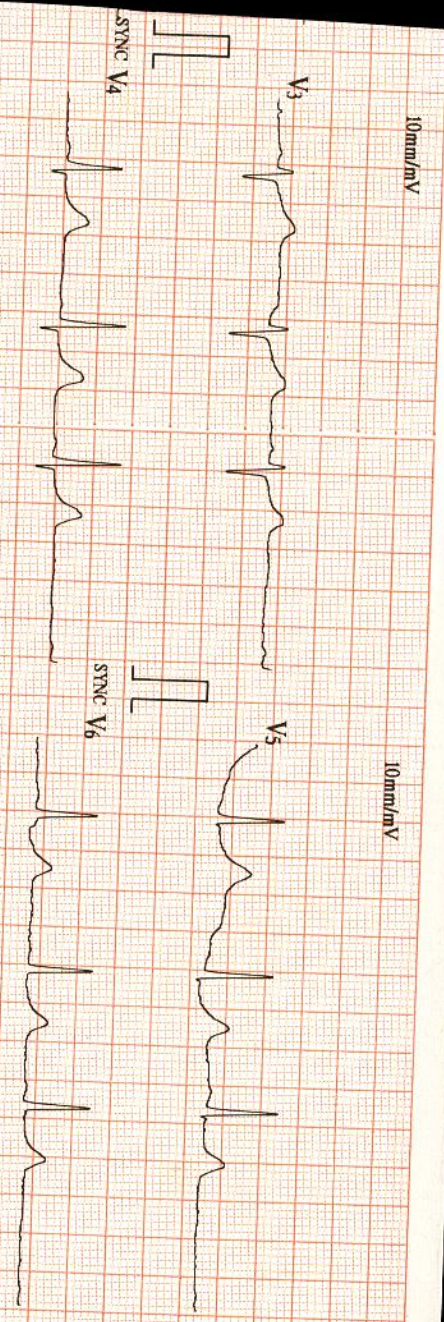
Ph.: 0124-4900000 (100 Lines), Toll Free No. : 1800-102-6767, Mob.: 62 62 82 82 35, Email: customercare@parkhospital.in

PARK GROUP OF HOSPITALS : West Delhi - Gurugram - Faridabad - Sonipat - Panipat - Karnal - Ambala - Patiala - Behror - Jaipur

the **health** care providers

the **health** care providers





ID : 0003

Name: MONI KUMARI

Sex: female

Age: 32 years

23/5/24

9:25 am

Unconfirmed report verified by:



HR	bpm
R-R	ms
P-R	ms
QRS	ms
QT/QTc	ms
P/QRS/T	ms
RV5/SVI	mV
RV6/SVI	mV