

# YASHFEEN IMAGING & RADIOLOGY DEPARTMENT

MANAGED BY :- YASHFEEN FOUNDATION

VIRAVAL, NAVSARI. 396 445. PHONE : (H) (02637) 235725

Website : [www.yashfeenhospital.in](http://www.yashfeenhospital.in) E-mail : [info@yashfeenhospital.in](mailto:info@yashfeenhospital.in)

Patient's Name:	PRATIXAKUMARI S. PATEL	Age & Sex:	37Yrs/F
Ref. by Dr.	SELF	Date:	09-04-2024

## X RAY CHEST (PA VIEW)

Both lung fields appear normal.  
Both hila appear normal.  
Both CP angles appear clear.  
Cardiac size appears within normal limit.  
Both domes of diaphragm appear normal.  
Bony thoracic cage appears normal.

### IMPRESSION:

- Normal X-ray chest (PA view).

  
**Dr. DHARMESH DESAI**  
(M.D. Radiology)  
Reg.No. G - 45284  
YASHFEEN GROUP OF HOSPITAL



Please contact immediately for any typographical error.

This report is for professional opinion, not a final diagnosis. Kindly correlate clinically. Not valid for medicolegal purpose.



# YASHFEEN CARDIAC HOSPITAL™

MANAGED BY :- YASHFEEN FOUNDATION

VIRAVAL, NAVSARI. 396 445. PHONE : (H) (02637) 235725

Website : www.yashfeenhospital.in E-mail : info@yashfeenhospital.in

(Regd. No. E / 1390 / Navsari)

(Stationary For Report Only)

## 2D ECHO CARDIOGRAPHY COLOUR DOPPLER REPORT

Patient Name & No	: PRATIXAKUMARI SHANKARBHAI PATEL CH24C	Age/Sex	UHID :	: 137
Doctor	: Mohil Nagad	37/ F	No :	: 144
Referred By	:		Date :	: 09/04/2024

### M-Mode findings

LVIDd : 39mm  
 LVIDs : 25mm  
 IVSd : 10mm  
 PWd : 09mm  
 EF : 60%  
 Aorta : 20mm  
 LA : 32mm

### 2D Imaging

Aortic Valve : Trileaflet, Normal  
 Mitral Valve : Thin, Pliable, Normal Mobility, Normal function  
 Tricuspid Valve : Normal,  
 Pulmonary Valve : Normal

=> : All cardiac chambers are normal sized.  
 => : All cardiac valves are normal.  
 => : No regional wall motion abnormality.  
 => : Normal LV systolic function.  
 => : Normal LV diastolic function.  
 => : IAS/IVS intact.  
 => : No obvious clots/ vegetations/ or effusion.  
 => : IVC Normal size.

### Doppler Findings

=> : No MS/MR, No TS/TR, No AS/AR & No PS/PR  
 Mitral inflow Pattern : E > A  
 Tissue Doppler Findings : E' > A'

Impression : Normal LVEF:60%, No RWMA.



Report Prepared By

Report Checked By  
**DR. MOHIL NAGAD**  
 M.D. Medicine, D.M. Cardiology  
 Senior Consultant, Interventional Cardiology  
 Non-Invasive Cardiology  
 Reg. No. G-22893  
 YASHFEEN HOSPITAL, NAVSARI

Designed By : Sarita Infotech Pvt. Ltd., Navsari






# YASHFEEN CARDIAC HOSPITAL™

At. & Po. Viraval, Navsari. 396 445. Phone (H) (02637) 235725

Website : [www.yashfeenhospital.in](http://www.yashfeenhospital.in) E-mail : [info@yashfeenhospital.in](mailto:info@yashfeenhospital.in)  
(For Laboratory Reports Only)



Patient Name : PRATIXAKUMARI SHANKARBHAI PATEL Age : 37 Years Sex : F  
Ref By Dr. : - Area : Valsad Date : 09/04/2024  
Sample Time : 09/04/2024 08:58 No : 6 Time : 11:28AM

## HAEMOGRAM

Test	Findings	UOM	Normal Range
HAEMOGLOBIN	11.2	gm/dl	M-13.5-17.0 gm/dl F-11.5-15.5 gm/dl
<b>HAEMOGRAM</b>			
RED BLOOD CELL	5.44	10 <sup>6</sup> /μL	3.76-5.70
TOTAL LEUCOCYTE COUNT	7100	cells/cumm	4,000-11,000cells/cumm
<b>Differential Count</b>			
Neutrophil	62	%	40-75 %
Lymphocytes	33	%	20-40 %
Eosinophil	2	%	01-06 %
Monocytes	3	%	02-10 %
Basophils	0	%	00-00 %
PLATELET COUNT	510000	lacs/cumm	1.5-5.5 Lacs/cumm
<b>RBC INDICES</b>			
P.C.V.	<b>33.7</b>	%	Male-40-56%, Female-37-47%
M.C.V.	<b>61.9</b>	cu/microns	76.0-94.0
M.C.H.	<b>20.5</b>	pg	27.0-30.0
M.C.H.C.	33.1	-	30.0-35.0
BLOOD GROUP	" A "	-	-
RH FACTOR	POSITIVE	-	-
E.S.R.(1 hour)	18	mm/hr.	Male-5-10 mm/hr, Female-5-20 mm/hr

Remarks

Designed By Sarita Infotech Pvt, Ltd., Navsari

*P. Desai*  
Dr. PIYUSH B. CHAUDHARI

M.D. Medicine

Reg. No. G-21518

Yashfeen Cardiac Hospital

*Desai*  
Signature  
Technician

Thanks for Reference



# YASHFEEN CARDIAC HOSPITAL™

At. & Po. Viraval, Navsari. 396 445. Phone (H) (02637) 235725

Website : www.yashfeenhospital.in E-mail : info@yashfeenhospital.in  
(For Laboratory Reports Only)



Patient Name : PRATIXAKUMARI SHANKARBHAI PATEL Age : 37 Years Sex : F  
Ref By Dr. : - Area : Valsad Date : 09/04/2024  
Sample Time : 09/04/2024 08:58 No : 6 Time : 11:28AM

## HAEMOGLOBIN A1 C ESTIMATION

Test	Findings	UOM	Normal Range
Hb A1C	6.2	%	>8 :Action Suggested, 7-8 :Good Control, <7 :Goal, 6-7 :Near Normal Glycemia, <6 :Non-diabetic Level
<b>Technique</b> METHOD - HPLC		-	
Mean Blood Glucose	130.0	mg/dL	

Remarks

Designed By : Sarita Infotech Pvt. Ltd., Navsari

*P. Chaudh*  
Dr. PIYUSH B. CHAUDHARI  
M.D. Medicine  
Reg. No. G-21518

Yashfeen Cardiac Hospital

Signature

Technician

*Thanks for Reference*





# YASHFEEN CARDIAC HOSPITAL™

At. & Po. Viraval, Navsari. 396 445. Phone (H) (02637) 235725

Website : www.yashfeenhospital.in E-mail : info@yashfeenhospital.in  
(For Laboratory Reports Only)



Patient Name : PRATIXAKUMARI SHANKARBHAI PATEL Age : 37 Years Sex : F  
Ref By Dr. : - Area : Valsad Date : 09/04/2024  
Sample Time : 09/04/2024 08:58 No : 6 Time : 11:28AM

## BIOCHEMICAL TEST REPORT

Test	Findings	UOM	Normal Range
S.CREATININE	<b>0.7</b>	mg/dL	Male-0.9-1.4 mg/dL, Female-0.8-1.2 mg/dL
BLOOD UREA NITROGEN	9.3	mg/dL	4.7-23.0 mg/dL
S.URIC ACID	5.7	mg/dL	Male:3.5-7.2 mg/dL, Female:2.6-6.0 mg/dL



*P. Chaudhary*  
Dr. PIYUSH B. CHAUDHARI  
M.D. Medicine  
Reg. No. G-21518

Remarks

Designed By : Sarita Infotech Pvt. Ltd., Navsari

Yashfeen Cardiac Hospital

*[Signature]*  
Signature  
Technician

*Thanks for Reference*



# YASHFEEN CARDIAC HOSPITAL™

At. & Po. Viraval, Navsari. 396 445. Phone (H) (02637) 235725

Website : [www.yashfeenhospital.in](http://www.yashfeenhospital.in) E-mail : [info@yashfeenhospital.in](mailto:info@yashfeenhospital.in)

(For Laboratory Reports Only)



Patient Name : PRATIXAKUMARI SHANKARBHAI PATEL Age : 37 Years Sex : F  
Ref By Dr. : - Area : Valsad Date : 09/04/2024  
Sample Time : 09/04/2024 08:59 No : 6 Time : 11:28AM

## LIPID PROFILE TEST REPORT

Test	Findings	UOM	Normal Range
S.CHOLESTEROL	122.9	mg/dL	<200:Desirable, 200-239:Borderline High, >=240:High
HDL CHOLESTEROL	45.2	mg/dL	<40:Low(High Risk), >=60:High(Low Risk)
LDL CHOLESTEROL	86.2	mg/dL	<100.0: Optimal, 100.0-129.0: Nearoptimal/ Aboveoptimal, 130.0-159.0:Borderline High, 160.0-189.0:High, >=190.0:Very High
VLDL CHOLESTEROL	13.1	mg/dL	Upto 40.0 mg/dL
S.TRIGLYCERIDES	65.6	mg/dL	<150.0:Normal, 150.0-199.0:Borderline high, 200.0-499.0:High, >=500.0:Very High
CHOL/ HDL RATIO	2.7	mg/dL	LESS THAN 5.0
LDL/ HDL RATIO	1.9	mg/dL	LESS THAN 5.0
REMARK	-	-	-



*P. Chaudhari*  
Dr. PIYUSH B. CHAUDHARI  
M.D. Medicine  
Reg. No. G-21518

### Remarks

Designed By : Sarita Infotech Pvt. Ltd., Navsari

Yashfeen Cardiac Hospital

*[Signature]*  
Signature  
Technician

*Thanks for Reference*





# YASHFEEN CARDIAC HOSPITAL™

At. & Po. Viraval, Navsari. 396 445. Phone (H) (02637) 235725

Website : [www.yashfeenhospital.in](http://www.yashfeenhospital.in) E-mail : [info@yashfeenhospital.in](mailto:info@yashfeenhospital.in)

(For Laboratory Reports Only)



Patient Name : PRATIXAKUMARI SHANKARBHAI PATEL Age : 37 Years Sex : F  
Ref By Dr. : - Area : Valsad Date : 09/04/2024  
Sample Time : 09/04/2024 08:59 No : 6 Time : 11:28AM

## LIVER FUNCTION TEST REPORT

Test	Findings	UOM	Normal Range
TOTAL BILIRUBIN	0.2	mg/dL	0-1.0 mg/dL
DIRECT BILIRUBIN	0.1	mg/dL	0-0.8 mg/dL
INDIRECT BILIRUBIN	0.1	mg/dL	0-0.2 mg/dL
SGPT	10.0	U/L	Below 40.0 U/L
S.ALKALINE PHOSPHATASE	97.4	U/L	Child-170.0-515.0 U/L, Adults-37.0-147.0 U/L
TOTAL PROTEIN	7.3	g/dl	6.0-8.0 g/dl
ALBUMIN	4.6	g/dl	3.0-5.0 g/dl
GLOBULIN	2.7	g/dl	3.0-3.5 g/dl
A/G	1.7	g/dl	
SGOT	13.5	U/L	Below 40.0 U/L



*P. Chaudhari*  
Dr. PIYUSH B. CHAUDHARI  
M.D. Medicine  
Reg. No. G-21518

### Remarks

Designed By : Sarita Infotech Pvt. Ltd., Navsari

Yashfeen Cardiac Hospital

*S. Desai*  
Signature

Technician

*Thanks for Reference*





# YASHFEEN CARDIAC HOSPITAL™

At. & Po. Viraval, Navsari. 396 445. Phone (H) (02637) 235725

Website : www.yashfeenhospital.in E-mail : info@yashfeenhospital.in

(For Laboratory Reports Only)



Patient Name : PRATIXAKUMARI SHANKARBHAI PATEL Age : 37 Years Sex : F  
Ref By Dr. : - Area : Valsad Date : 09/04/2024  
Sample Time : 09/04/2024 08:59 No : 6 Time : 11:28AM

## THYROID FUNCTION TEST REPORT

Test	Findings	UOM	Normal Range
T3 (TRIODOTHYRONINE)	1.82	ng/ml	Newborns:0.73-2.88, 6 Days-3 Months:0.80-2.75, 4-12Months:0.86-2.65, 1-6 Years:0.92-2.48, 7-11 Years:0.93-2.31, 12-20Years:0.91-2.18, Adults:0.80-2.00
T4(THYROXINE)	7.89	µg/dl	Newborns:5.04-18.5, 6 Days-3 Months:5.41-17.0, 4-12 Months:5.67-16.0, 1-6 Years:5.95-14.7, 7-11 Years:5.99-13.8, 12-20 Years:5.91-13.2, Adults:5.10-14.1
TSH	<b>4.40</b>	µIU/ml	Newborns:0.70-15.2, 6 Days-3 Months:0.72-11.0, 4-12 Months:0.73-8.35, 1-6 Years:0.70-5.97, 7-11 Years:0.60-4.84, 12-20 Years:0.51-4.30, Adults:0.27-4.20

**TECHNIQUE**  
ELECTROCHEMILUMINESCEN  
CE



*P. Chaudh.*  
**Dr. PIYUSH B. CHAUDHARI**  
M.D. Medicine  
Reg. No. G-21518

Remarks

Designed By : Sarita Infotech Pvt. Ltd., Navsari

Yashfeen Cardiac Hospital

*[Signature]*  
**Signature**  
Technician

*Thanks for Reference*





# YASHFEEN CARDIAC HOSPITAL™

At. & Po. Viraval, Navsari. 396 445. Phone (H) (02637) 235725

Website : www.yashfeenhospital.in E-mail : info@yashfeenhospital.in

(For Laboratory Reports Only)



Patient Name : PRATIXAKUMARI SHANKARBHAI PATEL Age : 37 Years Sex : F  
 Ref By Dr. : - Area : Valsad Date : 09/04/2024  
 Sample Time : 09/04/2024 08:59 No : 6 Time : 11:29AM

## ROUTINE URINE ANALYSIS

Test	Findings	UOM	Normal Range
<b>PHYSICAL EXAMINATION</b>			
Quantity	-	-	
Colour	YELLOW	-	
Appearance	CLEAR	-	
Reaction	ACIDIC	-	
Sp. Gravity	1.008	-	
<b>CHEMICAL EXAMINATION</b>			
U.Albumin	NIL	-	
Sugar	NIL	-	
Acetone	NIL	-	
Bile Salt	NIL	-	
Bile Pigment	NIL	-	
Occult Blood	NIL	-	
<b>MICROSCOPIC EXAMINATION</b>			
Pus Cells	<b>2-4</b>	/hpf	
Epithelial cells	<b>2-4</b>	/hpf	
Red cells	ABSENT	/hpf	
Casts	-	/hpf	
Crystals	-	/hpf	
Others	-	/hpf	



*P. Chaudh.*  
 Dr. PIYUSH B. CHAUDHARI  
 M.D. Medicine  
 Reg. No. G-21518

### Remarks

Designed By : Sarita Infotech Pvt. Ltd., Navsari

Yashfeen Cardiac Hospital

*S. Hartejee*  
 Signature

Technician

*Thanks for Reference*



# YASHFEEN CARDIAC HOSPITAL™

At. & Po. Viraval, Navsari. 396 445. Phone (H) (02637) 235725

Website : www.yashfeenhospital.in E-mail : info@yashfeenhospital.in

(For Laboratory Reports Only)



Patient Name : PRATIXAKUMARI SHANKARBHAI PATEL Age : 37 Years Sex : F  
 Ref By Dr. : - Area : Valsad Date : 09/04/2024  
 Sample Time : 09/04/2024 08:59 No : 6 Time : 11:29AM

## GGT TEST REPORT

Test	Findings	UOM	Normal Range
SERUM GGT	30.0	U/L	10.0-71.0 U/L



P. Chaudh.

Dr. PIYUSH B. CHAUDHARI

M.D. Medicine

Reg. No. G-21518

Remarks

Designed By : Sarita Infotech Pvt. Ltd., Navsari

Yashfeen Cardiac Hospital

*Signature*

signature

*Thanks for Reference*

Technician





# YASHFEEN CARDIAC HOSPITAL™

At. & Po. Viraval, Navsari. 396 445. Phone (H) (02637) 235725

Website : [www.yashfeenhospital.in](http://www.yashfeenhospital.in) E-mail : [info@yashfeenhospital.in](mailto:info@yashfeenhospital.in)  
(For Laboratory Reports Only)



Patient Name : PRATIXAKUMARI SHANKARBHAI PATEL Age : 37 Years Sex : F  
Ref By Dr. : - Area : Valsad Date : 09/04/2024  
Sample Time : 09/04/2024 08:59 No : 6 Time : 11:29AM

## BLOOD SUGAR TEST REPORT

Test	Findings	UOM	Normal Range
FASTING BLOOD SUGAR	<b>119.6</b>	mg/dL	70-110 mg/dL
FASTING URINE SUGAR	NIL	-	NIL
POSTPANDRIAL BLOOD SUGAR	<b>153.0</b>	mg/dL	70-140 mg/dL
POSTPANDRIAL URINE SUGAR	NIL	-	NIL



Remarks

Designed By : Sarita Infotech Pvt. Ltd., Navsari

*f. Chaudh.*  
Dr. PIYUSH B. CHAUDHARI  
M.D. Medicine  
Reg. No. G-21518

Yashfeen Cardiac Hospital

*Dr. Harbejee*  
signature  
Technician

*Thanks for Reference*



FRATIYAKUMARI,  
ID:  
DOB: 37 Years  
Female, Unknown  
Med.:  
Location:  
Referring Physician:  
Notes:

09-04-2024 11:34:52

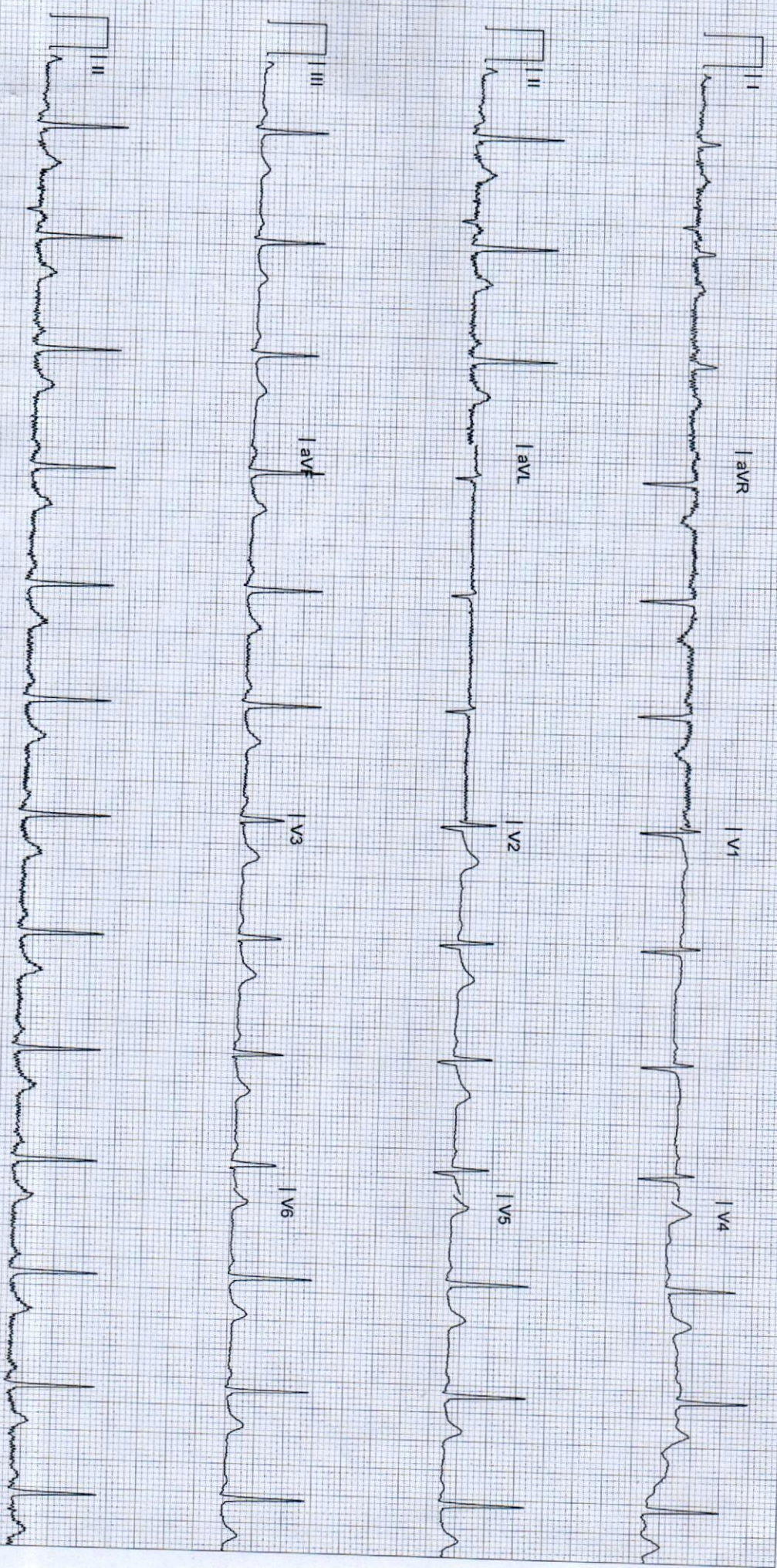
Vent. Rate: 78 bpm  
PR Int: 138 ms  
QRS dur: 74 ms  
QT/QTc: 351/384 ms  
P-R-T axes: 60 77 70  
Avg. RR: 764 ms  
QTcB: 401 ms  
QTcF: 383 ms

SINUS RHYTHM  
NORMAL ECG

UNCONFIRMED REPORT  
Reviewed by:

*P. Chaudhary*  
**Dr. PIYUSH B. CHAUDHARI**  
M.D. Medicine  
Reg. No. G-21518

Signed by:  
Date:







# YASHFEEN CARDIAC HOSPITAL

## EYE DEPARTMENT

Chief Complaint :

*Blur*

Medical History : DM / HT / Asthama / Allergy / Heart / Thyroid / TB / Anticoagulants

Family History :

Past Ocular History :

Ocular Trauma :

Visual Acuity :

*6/9  
6/4*

IOP :

NAME

09\_APR\_2024 AM 11:57  
NO. 0361  
SN: 4771998

REF. DATA

VD: 12.00 CYL: MIX  
<R> S C A  
- 0.25 - 0.25 172  
- 0.25 - 0.25 172  
- 0.25 - 0.25 172  
- 0.25 - 0.25 172  
S. E. - 0.50  
<L> S C A  
- 0.00 - 0.25 118  
- 0.00 - 0.25 118  
- 0.00  
- 0.00 - 0.25 118  
S. E. - 0.25

PD: 65.5


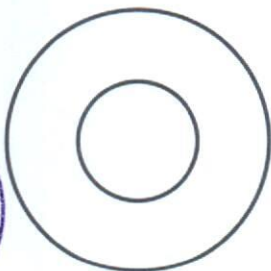
KRT. DATA

<R> D MM A

	RIGHT EYE (PH.....)				LEFT EYE (PH..)			
	Sph.	Cyl.	Axis	V/A	Sph.	Cyl.		
Distance	<i>R</i>			<i>6/9</i>	<i>R</i>		<i>6/4</i>	
Near				<i>6/9</i>			<i>6/4</i>	

Constant/Distance/Reading/Bi-Focal/Progressive/Separate Glasses

SLE :



*Dr. Reg. Meera  
A. De. Green*

*Meera*

*[Signature]*

# YASHFEEN IMAGING & RADIOLOGY DEPARTMENT

MANAGED BY :- YASHFEEN FOUNDATION

VIRAVAL, NAVSARI. 396 445. PHONE : (H) (02637) 235725

Website : [www.yashfeenhospital.in](http://www.yashfeenhospital.in) E-mail : [info@yashfeenhospital.in](mailto:info@yashfeenhospital.in)

Name	PRATIXAKUMARI S. PATEL	Age	37Y/F
Ref by Dr	SELF	Date	09/04/2024

## USG ABDOMEN & PELVIS (SCREENING)(TVS)

**Liver** appears normal in size & shape with normal echopattern.  
No e/o focal or diffuse lesion. IHBR appear normal.  
PV and CBD appear normal.

**Gall bladder** appears contracted. Adv: fasting scan.

**Pancreas** appears normal in size and echogenicity. No e/o focal or diffuse lesion.

**Spleen** appears normal in size and shows normal echopattern. No e/o focal lesion.

**Both Kidneys** appear normal in size and echopattern. CM Differentiation is preserved.  
No e/o calculus or hydronephrosis on either side.  
Perirenal spaces appear normal on either side.  
Suprarenal regions appear normal on either side. No e/o mass lesion.

**Bladder** is physiologically distended. No e/o calculus or mass. Walls appear normal.

**Uterus** appears anteverted, normal in size & shows normal echopattern.  
Endometrial cavity is empty. ET- 5 mm. No e/o focal or diffuse mass lesion.  
**Both ovaries** appear normal in size & echopattern.  
No e/o adnexal mass on either side.

RIF region appears normal.

No e/o ascites.

### IMPRESSION:

**No significant abnormality detected.**

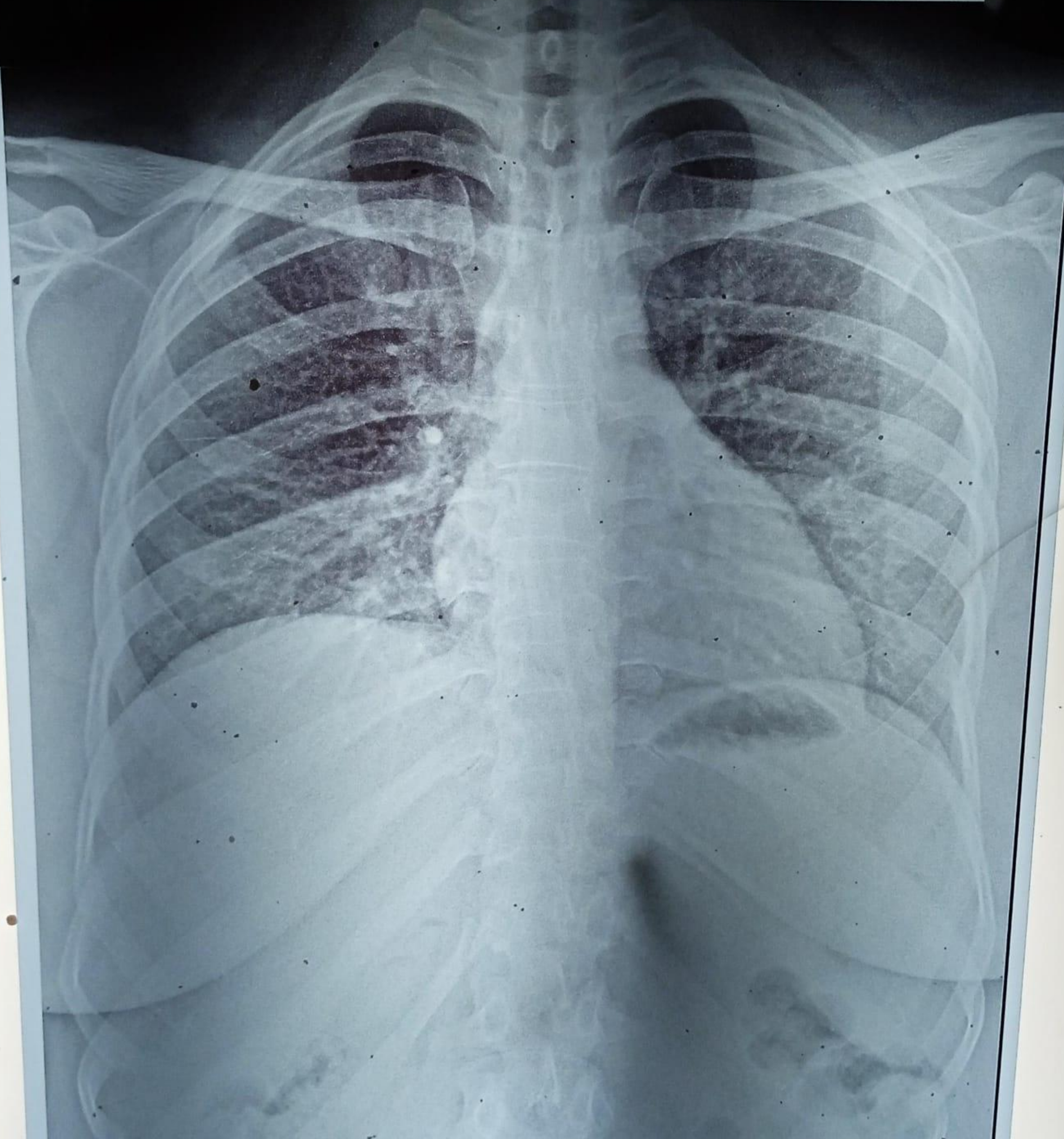


Dr. DHARMESH DESAI  
(M.D. Radiology)  
Reg. No. G - 45284  
Dr. Dharmesh Desai  
YASHFEEN GROUP OF HOSPITAL  
MD

Please contact immediately for any typographical error.

This is only professional opinion, not a final diagnosis. Kindly correlate clinically. Not valid for medical/legal purposes.





4001151 PRATIXAKUMARI S PATEL 37/Y 090424166 Chest Erect PA 09/04/2024  
YASHFEEN GROUP OF HOSPITALS NAVSARI PH:9924047789