

Dr. Goyal's

Path Lab & Imaging Centre

B-51, Ganesh Nagar, Near Metro Pillar No. 109-110, New Sanganeer Road,
Sodala, Jaipur-302019

Tele : 0141-2293346, 4049787, 9887049787

General Physical Examination

Website: www.drgoyalpathlab.com | E-mail: drgoyalpiyush@gmail.com

Date of Examination: 24/03/2024

Name: RAJNI BUNKER Age: 47 Sex: 47f

DOB: 04/09/1976

Referred By: BOB

Photo ID: Agdhar ID #: Attached

Ht: 161 (cm)

Wt: 79 (Kg)

Chest (Expiration): 105 (cm)

Abdomen Circumference: 103 (cm)

Blood Pressure: 107/62 mm Hg PR: 63 / min

BMI 29.0

Eye Examination: Dis. Vision L.E. 6/12 R.E. 6/12 (With Specs)

Near vision L.E. M/18 R.E. M/9 (With Specs) Normal Color Vision

Other: not significant

On examination he/she appears physically and mentally fit: Yes / No

Signature Of Examinee : Rajni Bunker Name of Examinee: _____

Signature Medical Examiner: Dr. Piyush Goyal Name Medical Examiner: _____
M.B.B.S., D.M.R.D.
RMC Reg. No.-017996

भारत सरकार
Government of India

आधार

Issue Date: 21/07/2015



रजनी बुन्कर
Rajni Bunker
जन्म तिथि/DOB: 04/09/1976
महिला/ FEMALE

8662 0349 6600
VID : 9141 3599 1159 9172

मेरा आधार, मेरी पहचान

Rajni Bunker

भारतीय विशिष्ट पहचान प्राधिकरण
Unique Identification Authority of India

आधार

पता:
सूच: सुरेश कुमार बुन्कर, 43, ग्रीन कुंज, नागल जैसा
बोहरा, झोटावाड़ा, झोटावाड़ा, जयपुर,
राजस्थान - 302012

Address:
C/O: Suresh Kumar Bunker, 43, Green Kunj,
Nagal Jaisa Bohara, Jhotwara, Jhotwara,
Jaipur,
Rajasthan - 302012



8662 0349 6600
VID : 9141 3599 1159 9172

1947 | help@uidai.gov.in | www.uidai.gov.in

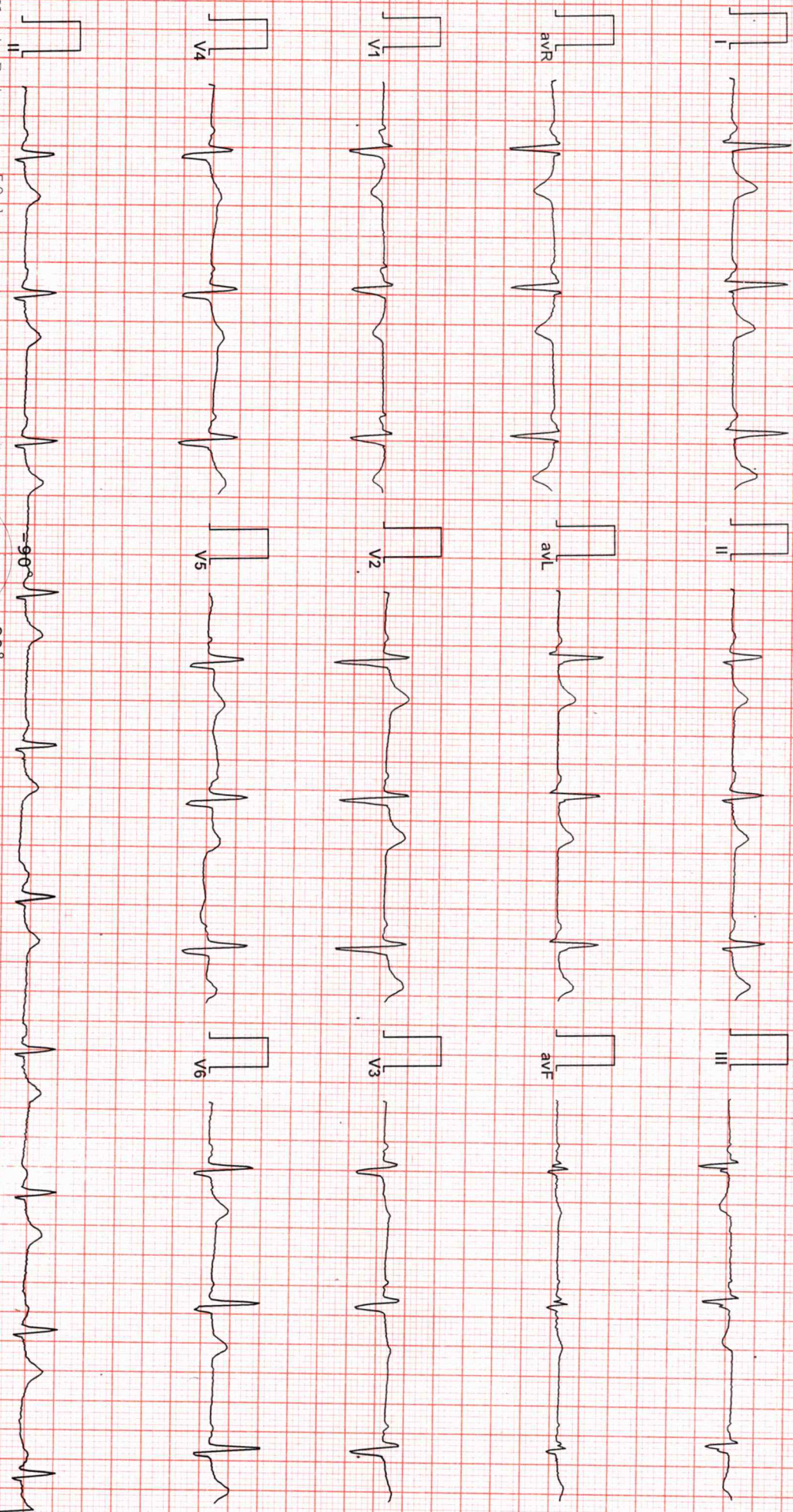
Dr. Piyush Goyal
M.B.B.S., D.M.R.D.
RMC Reg. No.-017993

DR. GOYALS PATH LAB & IMAGING CENTER

102337578 / MRS .RAJNI BUNKAR / 47 Yrs / F/ Non Smoker

Heart Rate : 59 bpm / Tested On : 24-Mar-24 10:47:18 / HF 0.05 Hz - LF 100 Hz / Notch 50 Hz / Sn 1.00 Cm/mV / Sw 25 mm/s
/ Refd By: BOB

ECG



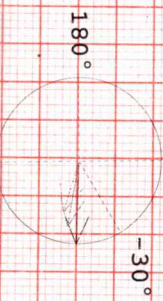
Vent Rate : 59 bpm

PR Interval : 136 ms

QRS Duration : 100 ms

QT/QTc Int : 436/434 ms

P-QRS-T axis: 171.00 • 2.00 • 10.00 •



90° R 2.00° T 10.00° P 171.00°

Allengers ECG (Piscas)(PIS218210312)

Dr. Naresh Xumar Mohanka

RMC No: 38703

Reported by: **Dr. Naresh Xumar Mohanka**
MBBS, DIP, CARDIO (ESCORTS),
D.E.M (RCGP-UK)

Dr. Goyal's

Path Lab & Imaging Centre

B-51, Ganesh Nagar, Near Metro Pillar No. 109-110, New Sanganer Road, Jaipur
Tele : 0141-2293346, 4049787, 9887049787
Website : www.drgoyalspathlab.com E-mail : drgoyalpiyush@gmail.com



Date :- 24/03/2024 09:53:22
NAME :- Mrs. RAJNI BUNKER
Sex / Age :- Female 47 Yrs 6 Mon 20 Days
Company :- MediWheel

Patient ID :-12236584
Ref. By Doctor:-BOB
Lab/Hosp :-

Final Authentication : 24/03/2024 13:45:03

BOB PACKAGEFEMALE ABOVE 40

X RAY CHEST PA VIEW:

Both lung fields appears clear.

Bronchovascular markings appear normal.

Trachea is in midline.

Both the hilar shadows are normal.

Both the C.P.angles is clear.

Both the domes of diaphragm are normally placed.


Bony cage and soft tissue shadows are normal.

Heart shadows appear normal.

Impression :- Normal Study

(Please correlate clinically and with relevant further investigations)

*** End of Report ***


Dr. NAVNEET AGARWAL (MD, DNB RADIO-DIAGNOSIS, MNAMS)
EX-SR NEURO-RADIOLOGY AIIMS NEW DELHI
(RMC No. 33613 / 14911)

Page No: 1 of 1

NIKITAPATWA
Transcript by.

Dr. Piyush Goyal
M.B.B.S., D.M.R.D.
RMC Reg No. 017996

Dr. Ashish Choudhary
MBBS, MD (R) (Radio-Diagnosis)
Fetal Medicine
FMF ID - 260517

Dr. Abhishek Jain
MBBS, DNB, (Radio-Diagnosis)
RMC No. 21687

Dr. Navneet Agarwal
MD, DNB (Radio Diagnosis)
RMC No. 33613/14911

Dr. Poorvi Malik
MBBS, MD, DNB (Radio Diagnosis)
RMC No. 21505



Date :- 24/03/2024 09:53:22
NAME :- Mrs. RAJNI BUNKER
Sex / Age :- Female 47 Yrs 6 Mon 20 Days
Company :- MediWheel

Patient ID :- 12236584
Ref. By Doctor:-BOB
Lab/Hosp :-

Final Authentication : 24/03/2024 11:51:28

BOB PACKAGEFEMALE ABOVE 40

ULTRA SOUND SCAN OF ABDOMEN

Liver is of normal size. Echo-texture is normal. No focal space occupying lesion is seen within liver parenchyma. Intra hepatic biliary channels are not dilated. Portal vein diameter is normal.

Gall bladder is of normal size. Wall is not thickened. No calculus or mass lesion is seen in gall bladder. Common bile duct is not dilated.

Pancreas is of normal size and contour. Echo-pattern is normal. No focal lesion is seen within pancreas. **Spleen** is of normal size and shape. Echotexture is normal. No focal lesion is seen.

Kidneys are normally sited and are of normal size and shape. Cortico-medullary echoes are normal. No focal lesion is seen. Collecting system does not show any dilatation or calculus.

Urinary Bladder: is well distended and showing smooth wall with normal thickness. Urinary bladder does not show any calculus or mass lesion.

Uterus is anteverted and mildly bulky in size ~ 95x67x52 mm.

Myometrium shows normal echo - pattern. No focal space occupying lesion is seen. Endometrial echo is normal.

Cervix appears bulky in size with multiple 7 to 8 cystic areas in cervical region measuring from. 8 mm to 10 mm.

Both ovaries are visualised and are normal. No adnexal mass is seen. No significant free fluid is seen in pouch of douglas.

IMPRESSION:

- * Bulky uterus.
- * Bulky cervix with cystic areas in cervical region - likely chronic cervicitis.

Needs clinical correlation

DR. PIYUSH GOYAL
CONSULTANT RADIOLOGIST
RMC REG NO. 017996

Page No. 1 of 2

AHSAN
Transcript by.

Dr. Piyush Goyal
M.B.B.S., D.M.R.D.
RMC Reg No. 017996

Dr. Ashish Choudhary
MBBS, MD (Radio Diagnosis)
Fetal Medicine Consultant
FMF ID - 260517 | RMC No 22430

Dr. Abhishek Jain
MBBS, DNB, (Radio-Diagnosis)
RMC No. 21687

Dr. Navneet Agarwal
MD, DNB (Radio Diagnosis)
RMC No. 33613/14911

Dr. Poorvi Malik
MBBS, MD, DNB (Radio Diagnosis)
RMC No. 21505



Date :- 24/03/2024 09:53:22
NAME :- Mrs. RAJNI BUNKER
Sex / Age :- Female 47 Yrs 6 Mon 20 Days
Company :- MediWheel

Patient ID :- 12236584
Ref. By Doctor:-BOB
Lab/Hosp :-

Final Authentication : 24/03/2024 11:51:28

ULTRASONOGRAPHY REPORT: BREAST AND AXILLA

RIGHT breast:-

Skin, subcutaneous tissue and retroareolar region is normal.
Fibro glandular tissue shows normal architecture and echotexture.
Pre and retro mammary regions are unremarkable.
No obvious cyst, mass or architectural distortion visualized.
Axillary lymph nodes are not significantly enlarged and their hilar shadows are preserved.

Left breast:-

Skin, subcutaneous tissue and retroareolar region is normal.
Fibro glandular tissue shows normal architecture and echotexture.
Pre and retro mammary regions are unremarkable.
No obvious cyst, mass or architectural distortion visualized.
Axillary lymph nodes are not significantly enlarged and their hilar shadows are preserved.

IMPRESSION:

* No abnormality detected.

Needs clinical correlation

DR. PIYUSH GOYAL
CONSULTANT RADIOLOGIST
RMC REG NO. 017996

*** End of Report ***

Dr. Goyal's

Path Lab & Imaging Centre

B-51, Ganesh Nagar, Near Metro Pillar No. 109-110, New Sanganer Road, Jaipur
 Tele : 0141-2293346, 4049787, 9887049787
 Website : www.drgoyalspathlab.com E-mail : drgoyalpiyush@gmail.com



Date :- 24/03/2024 09:53:22	Patient ID :-12236584
NAME :- Mrs. RAJNI BUNKER	Ref. By Doctor:-BOB
Sex / Age :- Female 47 Yrs 6 Mon 20 Days	Lab/Hosp :-
Company :- MediWheel	

Final Authentication : 24/03/2024 11:51:28

BOB PACKAGEFEMALE ABOVE 40
 2D ECHO OPTION TMT (ADULT/CHILD)

2D-ECHOCARDIOGRAPHY M.MODE WITH DOPPLER STUDY:

FAIR TRANSTHORACIC ECHOCARDIOGRAPHIC WINDOW MORPHOLOGY:

MITRAL VALVE	NORMAL	TRICUSPID VALVE	NORMAL
AORTIC VALVE	NORMAL	PULMONARY VALVE	NORMAL

M.MODE EXAMINATION:

AO	24	mm	LA	25	Mm	IVS-D	10	mm
IVS-S	14	mm	LVID	34	Mm	LVSD	22	mm
LVPW-D	11	mm	LVPW-S	15	Mm	RV		mm
RVWT		mm	EDV		MI	LVVS		ml
LVEF	67%		RWMA			ABSENT		

CHAMBERS:

LA	NORMAL	RA	NORMAL
LV	NORMAL	RV	NORMAL
PERICARDIUM		NORMAL	

COLOUR DOPPLER:

MITRAL VALVE					
E VELOCITY	1.0	m/sec	PEAK GRADIENT		Mm/hg
A VELOCITY	0.72	m/sec	MEAN GRADIENT		Mm/hg
MVA BY PHT		Cm2	MVA BY PLANIMETRY		Cm2
MITRAL REGURGITATION			ABSENT		
AORTIC VALVE					
PEAK VELOCITY	1.7	m/sec	PEAK GRADIENT		mm/hg
AR VMAX		m/sec	MEAN GRADIENT		mm/hg
AORTIC REGURGITATION			ABSENT		
TRICUSPID VALVE					
PEAK VELOCITY	0.60	m/sec	PEAK GRADIENT		mm/hg
MEAN VELOCITY		m/sec	MEAN GRADIENT		mm/hg
VMax VELOCITY					
TRICUSPID REGURGITATION			ABSENT		
PULMONARY VALVE					
PEAK VELOCITY		M/sec.	PEAK GRADIENT		Mm/hg
MEAN VELOCITY			MEAN GRADIENT		Mm/hg
PULMONARY REGURGITATION			ABSENT		

Dr. Goyal's

Path Lab & Imaging Centre

B-51, Ganesh Nagar, Near Metro Pillar No. 109-110, New Sanganer Road, Jaipur
Tele : 0141-2293346, 4049787, 9887049787
Website : www.drgoyalspathlab.com E-mail : drgoyalpiyush@gmail.com



Date :- 24/03/2024 09:53:22
NAME :- Mrs. RAJNI BUNKER
Sex / Age :- Female 47 Yrs 6 Mon 20 Days
Company :- MediWheel

Patient ID :- 12236584
Ref. By Doctor:-BOB
Lab/Hosp :-

Final Authentication : 24/03/2024 11:51:28

Impression--

1. Normal LV size & contractility
2. No RWMA, LVEF 67 %.
3. Normal cardiac chamber.
4. Normal valve
5. No clot, no vegetation, no pericardial effusion.

(Cardiologist)

*** End of Report ***

Dr. Goyal's

Path Lab & Imaging Centre



B-51, Ganesh Nagar, Near Metro Piller No. 109-110, New Sanganer Road,
Sodala, Jaipur-302019

Tele : 0141-2293346, 4049787, 9887049787

Website: www.drgoalspathlab.com | E-mail: drgoalspiyush@gmail.com

Date :- 24/03/2024 09:53:22

NAME :- Mrs. RAJNI BUNKER

Sex / Age :- Female 47 Yrs 6 Mon 20 Days

Company :- MediWheel

Patient ID :-12236584

Ref. By Dr:- BOB

Lab/Hosp :-



Sample Type :- EDTA

Sample Collected Time 24/03/2024 10:05:03

Final Authentication : 24/03/2024 12:32:17

HAEMATOLOGY

Test Name	Value	Unit	Biological Ref Interval
-----------	-------	------	-------------------------

BOB PACKAGE FEMALE ABOVE 40

GLYCOSYLATED HEMOGLOBIN (HbA1C)

Method:- HPLC

5.1

%

Non-diabetic: < 5.7
Pre-diabetics: 5.7-6.4
Diabetics: = 6.5 or higher
ADA Target: 7.0
Action suggested: > 6.5

Instrument name: ARKRAY's ADAMS Lite HA 8380V, JAPAN.

Test Interpretation:

HbA1C is formed by the condensation of glucose with n-terminal valine residue of each beta chain of HbA to form an unstable schiff base. It is the major fraction, constituting approximately 80% of HbA1c. Formation of glycated hemoglobin (GHb) is essentially irreversible and the concentration in the blood depends on both the lifespan of the red blood cells (RBC) (120 days) and the blood glucose concentration. The GHb concentration represents the integrated values for glucose over the period of 6 to 8 weeks. GHb values are free of day to day glucose fluctuations and are unaffected by recent exercise or food ingestion. Concentration of plasma glucose concentration in GHb depends on the time interval, with more recent values providing a larger contribution than earlier values. The interpretation of GHb depends on RBC having a normal life span. Patients with hemolytic disease or other conditions with shortened RBC survival exhibit a substantial reduction of GHb. High GHb have been reported in iron deficiency anemia. GHb has been firmly established as an index of long term blood glucose concentrations and as a measure of the risk for the development of complications in patients with diabetes mellitus. The absolute risk of retinopathy and nephropathy are directly proportional to the mean of HbA1C. Genetic variants (e.g. HbS trait, HbC trait), elevated HbF and chemically modified derivatives of hemoglobin can affect the accuracy of HbA1c measurements. The effects vary depending on the specific Hb variant or derivative and the specific HbA1c method.

Ref by ADA 2020

MEAN PLASMA GLUCOSE

Method:- Calculated Parameter

100

mg/dL

Non Diabetic < 100 mg/dL
Prediabetic 100- 125 mg/dL
Diabetic 126 mg/dL or Higher

MUKESH SINGH
Technologist

Page No: 1 of 11



Dr. Rashmi Bakshi
MBBS, MD (Path)
RMC No. 17975/008828

Dr. Goyal's

Path Lab & Imaging Centre



B-51, Ganesh Nagar, Near Metro Pillar No. 109-110, New Sanganer Road,
Sodala, Jaipur-302019

Tele : 0141-2293346, 4049787, 9887049787

Website: www.dr.goyalpathlab.com | E-mail: dr.goyalpiyush@gmail.com

Date : 24/03/2024 09:53:22

Patient ID :-12236584



NAME :- Mrs. RAJNI BUNKER

Ref. By Dr:- BOB

Sex / Age :- Female 47 Yrs 6 Mon 20 Days

Lab/Hosp :-

Company :- MediWheel

Sample Type :- EDTA

Sample Collected Time 24/03/2024 10:05:03

Final Authentication : 24/03/2024 12:32:17

HAEMATOLOGY

Test Name	Value	Unit	Biological Ref Interval
HAEMOGARAM			
HAEMOGLOBIN (Hb)	10.9 L	g/dL	12.0 - 15.0
TOTAL LEUCOCYTE COUNT	5.14	/cumm	4.00 - 10.00
DIFFERENTIAL LEUCOCYTE COUNT			
NEUTROPHIL	50.4	%	40.0 - 80.0
LYMPHOCYTE	34.4	%	20.0 - 40.0
EOSINOPHIL	11.7 H	%	1.0 - 6.0
MONOCYTE	3.2	%	2.0 - 10.0
BASOPHIL	0.3	%	0.0 - 2.0
NEUT#	2.60	10 ³ /uL	1.50 - 7.00
LYMPH#	1.76	10 ³ /uL	1.00 - 3.70
EO#	0.60 H	10 ³ /uL	0.00 - 0.40
MONO#	0.16	10 ³ /uL	0.00 - 0.70
BASO#	0.02	10 ³ /uL	0.00 - 0.10
TOTAL RED BLOOD CELL COUNT (RBC)	3.88	x10 ⁶ /uL	3.80 - 4.80
HEMATOCRIT (HCT)	34.80 L	%	36.00 - 46.00
MEAN CORP VOLUME (MCV)	89.5	fL	83.0 - 101.0
MEAN CORP HB (MCH)	28.1	pg	27.0 - 32.0
MEAN CORP HB CONC (MCHC)	31.4 L	g/dL	31.5 - 34.5
PLATELET COUNT			
RDW-CV	15.1 H	%	11.6 - 14.0
MENTZER INDEX	23.07		

The Mentzer index is used to differentiate iron deficiency anemia from beta thalassemia trait. If a CBC indicates microcytic anemia, these are two of the most likely causes, making it necessary to distinguish between them.

If the quotient of the mean corpuscular volume divided by the red blood cell count is less than 13, thalassemia is more likely. If the result is greater than 13, then iron-deficiency anemia is more likely.

MUKESH SINGH
Technologist

Page No: 2 of 11



Dr. Rashmi Bakshi
MBBS, MD (Path)
RMC No. 17975/008828

Dr. Goyal's

Path Lab & Imaging Centre

B-51, Ganesh Nagar, Near Metro Pillar No. 109-110, New Sanganer Road,
Sodala, Jaipur-302019

Tele : 0141-2293346, 4049787, 9887049787

Website: www.drgoalspathlab.com | E-mail: drgoalspiyush@gmail.com

Date :- 24/03/2024 09:53:22

Patient ID :-12236584



NAME :- Mrs. RAJNI BUNKER

Ref. By Dr:- BOB

Sex / Age :- Female 47 Yrs 6 Mon 20 Days

Lab/Hosp :-

Company :- MediWheel

Sample Type :- EDTA

Sample Collected Time 24/03/2024 10:05:03

Final Authentication : 24/03/2024 12:32:17

HAEMATOLOGY

Test Name	Value	Unit	Biological Ref Interval
Erythrocyte Sedimentation Rate (ESR)	43 H	mm/hr.	00 - 20

(ESR) Methodology : Measurement of ESR by cells aggregation.

Instrument Name : Independent form Hematocrit value by Automated Analyzer (Roller-20)

Interpretation : ESR test is a non-specific indicator of inflammatory disease and abnormal protein states.

The test is used to detect, follow course of a certain disease (e.g-tuberculosis, rheumatic fever, myocardial infarction

Levels are higher in pregnancy due to hyperfibrinogenaemia.

The "3-figure ESR " $\times > 100$ value nearly always indicates serious disease such as a serious infection, malignant paraproteinaemia

(CBC) Methodology: TLC, DLC, Fluorescent Flow cytometry, HB SLS-method, TRBC, PCV, PLT Hydrodynamically focused Impedance. and

of connective tissue disease. MCH, MCV, MCHC, MENTZER INDEX are calculated. Instrument Name: Sysmex 6 part fully automatic analyzer XN-L, Japan

MUKESH SINGH
Technologist

Page No: 3 of 11



Dr. Rashmi Bakshi
MBBS. MD (Path)
RMC No. 17975/008828

Dr. Goyal's

Path Lab & Imaging Centre



B-51, Ganesh Nagar, Near Metro Piller No. 109-110, New Sanganer Road,
Sodala, Jaipur-302019
Tele : 0141-2293346, 4049787, 9887049787

Website: www.drGOYALSPATHLAB.COM E-mail: drGOYALPIYUSH@GMAIL.COM

Date: 24/03/2024 09:53:22

Patient ID :-12236584



NAME :- Mrs. RAJNI BUNKER

Ref. By Dr:- BOB

Sex / Age :- Female 47 Yrs 6 Mon 20 Days

Lab/Hosp :-

Company :- MediWheel

Sample Type :- PLAIN/SERUM

Sample Collected Time 24/03/2024 10:05:03

Final Authentication : 24/03/2024 11:55:28

BIOCHEMISTRY

Test Name	Value	Unit	Biological Ref Interval
LIPID PROFILE			
TOTAL CHOLESTEROL Method:- Enzymatic Endpoint Method	210.25	mg/dl	Desirable <200 Borderline 200-239 High > 240
TRIGLYCERIDES Method:- GPO-PAP	115.10	mg/dl	Normal <150 Borderline high 150-199 High 200-499 Very high >500
DIRECT HDL CHOLESTEROL Method:- Direct clearance Method	37.76	mg/dl	Low < 40 High > 60
DIRECT LDL CHOLESTEROL Method:- Direct clearance Method	153.31 H	mg/dl	Optimal <100 Near Optimal/above optimal 100-129 Borderline High 130-159 High 160-189 Very High > 190
VLDL CHOLESTEROL Method:- Calculated	23.02	mg/dl	0.00 - 80.00
T.CHOLESTEROL/HDL CHOLESTEROL RATIO Method:- Calculated	5.57 H		0.00 - 4.90
LDL / HDL CHOLESTEROL RATIO Method:- Calculated	4.06 H		0.00 - 3.50
TOTAL LIPID Method:- CALCULATED	609.81	mg/dl	400.00 - 1000.00

TOTAL CHOLESTEROL InstrumentName:Radox Rx Imola Interpretation: Cholesterol measurements are used in the diagnosis and treatments of lipid lipoprotein metabolism disorders.

TRIGLYCERIDES InstrumentName:Radox Rx Imola Interpretation : Triglyceride measurements are used in the diagnosis and treatment of diseases involving lipid metabolism and various endocrine disorders e.g. diabetes mellitus, nephrosis and liver obstruction.

DIRECT HDLCHOLESTERO InstrumentName:Radox Rx Imola Interpretation: An inverse relationship between HDL-cholesterol (HDL-C) levels in serum and the incidence/prevalence of coronary heart disease (CHD) has been demonstrated in a number of epidemiological studies. Accurate measurement of HDL-C is of vital importance when assessing patient risk from CHD. Direct measurement gives improved accuracy and reproducibility when compared to precipitation methods.

DIRECT LDL-CHOLESTEROL InstrumentName:Radox Rx Imola Interpretation: Accurate measurement of LDL-Cholesterol is of vital importance in therapies which focus on lipid reduction to prevent atherosclerosis or reduce its progress and to avoid plaque rupture.

TOTAL LIPID AND VLDL ARE CALCULATED

SURENDRAKHANGA

Page No: 4 of 11



Dr. Rashmi Bakshi
MBBS, MD (Path)
RMC No. 17975/008828

Dr. Goyal's

Path Lab & Imaging Centre



B-51, Ganesh Nagar, Near Metro Piller No. 109-110, New Sanganer Road,
Sodala, Jaipur-302019

Tele : 0141-2293346, 4049787, 9887049787

Website: www.drgoyalpathlab.com | E-mail: drgoyalpiyush@gmail.com

Date : 24/03/2024 09:53:22

NAME :- Mrs. RAJNI BUNKER

Sex / Age :- Female 47 Yrs 6 Mon 20 Days

Company :- MediWheel

Patient ID :- 12236584

Ref. By Dr:- BOB

Lab/Hosp :-



Sample Type :- PLAIN/SERUM

Sample Collected Time 24/03/2024 10:05:03

Final Authentication : 24/03/2024 11:55:28

BIOCHEMISTRY

Test Name	Value	Unit	Biological Ref Interval
LIVER PROFILE WITH GGT			
SERUM BILIRUBIN (TOTAL) Method:- Colorimetric method	0.95	mg/dl	Up to - 1.0 Cord blood <2 Premature < 6 days <16 Full-term < 6 days= 12 1month - <12 months <2 1-19 years <1.5 Adult - Up to - 1.2 Ref-(ACCP 2020)
SERUM BILIRUBIN (DIRECT) Method:- Colorimetric Method	0.26	mg/dL	Adult - Up to 0.25 Newborn - <0.6 >- 1 month - <0.2
SERUM BILIRUBIN (INDIRECT) Method:- Calculated	0.69	mg/dl	0.30-0.70
SGOT Method:- IFCC	29.3	U/L	Men- Up to - 37.0 Women - Up to - 31.0
SGPT Method:- IFCC	38.3 H	U/L	Men- Up to - 40.0 Women - Up to - 31.0
SERUM ALKALINE PHOSPHATASE Method:- AMP Buffer	102.20	IU/L	30.00 - 120.00
SERUM GAMMA GT Method:- IFCC	36.50 H	U/L	7.00 - 32.00
SERUM TOTAL PROTEIN Method:- Biuret Reagent	7.13	g/dl	6.40 - 8.30
SERUM ALBUMIN Method:- Bromocresol Green	3.98	g/dl	3.80 - 5.00
SERUM GLOBULIN Method:- CALCULATION	3.15	gm/dl	2.20 - 3.50
A/G RATIO	1.26 L		1.30 - 2.50

Total Bilirubin Methodology: Colorimetric method InstrumentName: Randox Rx Imola Interpretation: An increase in bilirubin concentration in the serum occurs in toxic or infectious diseases of the liver e.g. hepatitis B or obstruction of the bile duct and in rhesus incompatible babies. High levels of unconjugated bilirubin indicate that too much haemoglobin is being destroyed or that the liver is not actively treating the haemoglobin it is receiving.

AST Aspartate Aminotransferase Methodology: IFCC InstrumentName: Randox Rx Imola Interpretation: Elevated levels of AST can signal myocardial infarction, hepatic disease, muscular dystrophy and organ damage. Although heart muscle is found to have the most activity of the enzyme, significant activity has also been seen in the brain, liver, gastric mucosa, adipose tissue and kidneys of humans.

ALT Alanine Aminotransferase Methodology: IFCC InstrumentName: Randox Rx Imola Interpretation: The enzyme ALT has been found to be in highest concentrations in the liver, with decreasing concentrations found in kidney, heart, skeletal muscle, pancreas, spleen and lung tissue respectively. Elevated levels of the transaminases can indicate myocardial infarction, hepatic disease, muscular dystrophy and organ damage.

Alkaline Phosphatase Methodology: AMP Buffer InstrumentName: Randox Rx Imola Interpretation: Measurements of alkaline phosphatase are of use in the diagnosis, treatment and investigation of hepatobiliary disease and in bone disease associated with increased osteoblastic activity. Alkaline phosphatase is also used in the diagnosis of parathyroid and intestinal disease.

TOTAL PROTEIN Methodology: Biuret Reagent InstrumentName: Randox Rx Imola Interpretation: Measurements obtained by this method are used in the diagnosis and treatment of a variety of diseases involving the liver, kidney and bone marrow as well as other metabolic or nutritional disorders.

ALBUMIN (ALB) Methodology: Bromocresol Green InstrumentName: Randox Rx Imola Interpretation: Albumin measurements are used in the diagnosis and treatment of numerous diseases involving primarily the liver or kidneys. Globulin & A/G ratio is calculated.

Instrument Name Randox Rx Imola Interpretation: Elevations in GGT levels are seen earlier and more pronounced than those with other liver enzymes in cases of obstructive jaundice and metastatic neoplasms. It may reach 5 to 30 times normal levels in intra- or post-hepatic biliary obstruction. Only moderate elevations in the enzyme level (2 to 5 times normal)

SURENDRAKHANGA

Page No: 5 of 11



Dr. Rashmi Bakshi
MBBS, MD (Path)
RMC No. 17975/008828

Dr. Goyal's

Path Lab & Imaging Centre



B-51, Ganesh Nagar, Near Metro Piller No. 109-110, New Sanganer Road,
Sodala, Jaipur-302019
Tele : 0141-2293346, 4049787, 9887049787

Website: www.dr.goyalspathlab.com | E-mail: dr.goyalpiyush@gmail.com Patient ID :-12236584



Date : 24/03/2024 09:53:22
NAME :- Mrs. RAJNI BUNKER
 Sex / Age :- Female 47 Yrs 6 Mon 20 Days
 Company :- MediWheel
 Ref. By Dr:- BOB
 Lab/Hosp :-

Sample Type :- PLAIN/SERUM Sample Collected Time 24/03/2024 10:05:03 Final Authentication : 24/03/2024 11:30:42

IMMUNOASSAY

Test Name	Value	Unit	Biological Ref Interval
TOTAL THYROID PROFILE			
SERUM TOTAL T3 Method:- Chemiluminescence(Competitive immunoassay)	1.490	ng/ml	0.970 - 1.690
SERUM TOTAL T4 Method:- Chemiluminescence(Competitive immunoassay)	8.490	ug/dl	5.520 - 12.970
SERUM TSH ULTRA Method:- Enhanced Chemiluminescence Immunoassay	1.514	μIU/mL	0.350 - 5.500

Interpretation: Triiodothyronine (T3) contributes to the maintenance of the euthyroid state. A decrease in T3 concentration of up to 50% occurs in a variety of clinical situations, including acute and chronic disease. Although T3 results alone cannot be used to diagnose hypothyroidism, T3 concentration may be more sensitive than thyroxine (T4) for hyperthyroidism. Consequently, the total T3 assay can be used in conjunction with other assays to aid in the differential diagnosis of thyroid disease. T3 concentrations may be altered in some conditions, such as pregnancy, that affect the capacity of the thyroid hormone-binding proteins. Under such conditions, Free T3 can provide the best estimate of the metabolically active hormone concentration. Alternatively, T3 uptake, or T4 uptake can be used with the total T3 result to calculate the free T3 index and estimate the concentration of free T3.

Interpretation : The measurement of Total T4 aids in the differential diagnosis of thyroid disease. While >99.9% of T4 is protein-bound, primarily to thyroxine-binding globulin (TBG), it is the free fraction that is biologically active. In most patients, the total T4 concentration is a good indicator of thyroid status. T4 concentrations may be altered in some conditions, such as pregnancy, that affect the capacity of the thyroid hormone-binding proteins. Under such conditions, free T4 can provide the best estimate of the metabolically active hormone concentration. Alternatively, T3 uptake may be used with the total T4 result to calculate the free T4 index (FT4I) and estimate the concentration of free T4. Some drugs and some nonthyroidal patient conditions are known to alter TT4 concentrations in vivo.

Interpretation : TSH stimulates the production of thyroxine (T4) and triiodothyronine (T3) by the thyroid gland. The diagnosis of overt hypothyroidism by the finding of a low total T4 or free T4 concentration is readily confirmed by a raised TSH concentration. Measurement of low or undetectable TSH concentrations may assist the diagnosis of hyperthyroidism, where concentrations of T4 and T3 are elevated and TSH secretion is suppressed. These have the advantage of discriminating between the concentrations of TSH observed in thyrotoxicosis, compared with the low, but detectable, concentrations that occur in subclinical hyperthyroidism. The performance of this assay has not been established for neonatal specimens. Some drugs and some nonthyroidal patient conditions are known to alter TSH concentrations in vivo.

INTERPRETATION

PREGNANCY	REFERENCE RANGE FOR TSH IN uIU/mL (As per American Thyroid Association)
1st Trimester	0.10-2.50
2nd Trimester	0.20-3.00
3rd Trimester	0.30-3.00

NARENDRAKUMAR
Technologist

Page No: 6 of 11



Dr. Rashmi Bakshi
MBBS. MD (Path)
RMC No. 17975/008828

Dr. Goyal's



Path Lab & Imaging Centre

B-51, Ganesh Nagar, Near Metro Piller No. 109-110, New Sanganer Road,
Sodala, Jaipur-302019

Tele : 0141-2293346, 4049787, 9887049787

Website: www.dr.goyalpathlab.com | E-mail: dr.goyalpiyush@gmail.com

Date :- 24/03/2024 09:53:22

NAME :- Mrs. RAJNI BUNKER

Sex / Age :- Female 47 Yrs 6 Mon 20 Days

Company :- MediWheel

Patient ID :- 12236584

Ref. By Dr:- BOB

Lab/Hosp :-



Sample Type :- URINE

Sample Collected Time 24/03/2024 10:05:03

Final Authentication : 24/03/2024 12:48:06

CLINICAL PATHOLOGY

Test Name	Value	Unit	Biological Ref Interval
Urine Routine			
PHYSICAL EXAMINATION			
COLOUR	PALE YELLOW		PALE YELLOW
APPEARANCE	Clear		Clear
CHEMICAL EXAMINATION			
REACTION(PH)	5.5		5.0 - 7.5
Method:- Reagent Strip(Double indicator blue reaction)			
SPECIFIC GRAVITY	1.010		1.010 - 1.030
Method:- Reagent Strip(bromthymol blue)			
PROTEIN	NIL		NIL
Method:- Reagent Strip (Sulphosalicylic acid test)			
GLUCOSE	NIL		NIL
Method:- Reagent Strip (Glu.Oxidase Peroxidase Benedict)			
BILIRUBIN	NEGATIVE		NEGATIVE
Method:- Reagent Strip (Azo-coupling reaction)			
UROBILINOGEN	NORMAL		NORMAL
Method:- Reagent Strip (Modified ehrlich reaction)			
KETONES	NEGATIVE		NEGATIVE
Method:- Reagent Strip (Sodium Nitropruside) Rothera's			
NITRITE	NEGATIVE		NEGATIVE
Method:- Reagent Strip (Diazotization reaction)			
RBC	NIL		NIL
Method:- Reagent Strip (Peroxidase like activity)			
MICROSCOPY EXAMINATION			
RBC/HPF	NIL	/HPF	NIL
WBC/HPF	0-1	/HPF	2-3
EPITHELIAL CELLS	2-3	/HPF	2-3
CRYSTALS/HPF	ABSENT		ABSENT
CAST/HPF	ABSENT		ABSENT
AMORPHOUS SEDIMENT	ABSENT		ABSENT
BACTERIAL FLORA	ABSENT		ABSENT
YEAST CELL	ABSENT		ABSENT
OTHER	ABSENT		ABSENT

MANOJCHOUDHARY
Technologist

Page No: 7 of 11



Dr. Rashmi Bakshi
MBBS, MD (Path)
RMC No. 17975/008828

Dr. Goyal's

Path Lab & Imaging Centre



B-51, Ganesh Nagar, Near Metro Piller No. 109-110, New Sanganer Road,
Sodala, Jaipur-302019

Tele : 0141-2293346, 4049787, 9887049787

Website: www.dr.goyalpathlab.com | E-mail: dr.goyalpiyush@gmail.com Patient ID :- 12236584

Date :- 24/03/2024 09:53:22

NAME :- Mrs. RAJNI BUNKER

Ref. By Dr:- BOB

Sex / Age :- Female 47 Yrs 6 Mon 20 Days

Lab/Hosp :-

Company :- MediWheel

Sample Type :- KOx/Na FLUORIDE-F, KOx/Na SUBPHOSPHATE-LIN/SERUM

Final Authentication : 24/03/2024 13:19:09

BIOCHEMISTRY

Test Name	Value	Unit	Biological Ref Interval
FASTING BLOOD SUGAR (Plasma) Method:- GOD PAP	89.6	mg/dl	75.0 - 115.0
Impaired glucose tolerance (IGT)	111 - 125 mg/dL		
Diabetes Mellitus (DM)	> 126 mg/dL		
BLOOD SUGAR PP (Plasma) Method:- GOD PAP	113.4	mg/dl	70.0 - 140.0
<p>Instrument Name: Randox Rx Imola Interpretation: Elevated glucose levels (hyperglycemia) may occur with diabetes, pancreatic neoplasm, hyperthyroidism and adrenal cortical hyper-function as well as other disorders. Decreased glucose levels (hypoglycemia) may result from excessive insulin therapy or various liver diseases .</p>			
SERUM CREATININE Method:- Colorimetric Method	0.74	mg/dl	Men - 0.6-1.30 Women - 0.5-1.20
SERUM URIC ACID Method:- Enzymatic colorimetric	5.24	mg/dl	Men - 3.4-7.0 Women - 2.4-5.7

SURENDRAXHANGA

Page No: 8 of 11



Dr. Rashmi Bakshi
MBBS. MD (Path)
RMC No. 17975/008828

Dr. Goyal's

Path Lab & Imaging Centre

B-51, Ganesh Nagar, Near Metro Pillar No. 109-110, New Sanganer Road,
Sodala, Jaipur-302019

Tele : 0141-2293346, 4049787, 9887049787

Website: www.dr.goyalpathlab.com | E-mail: dr.goyalpiyush@gmail.com

Date :- 24/03/2024 09:53:22

NAME :- Mrs. RAJNI BUNKER

Sex / Age :- Female 47 Yrs 6 Mon 20 Days

Company :- MediWheel

Patient ID :- 12236584

Ref. By Dr:- BOB

Lab/Hosp :-



Sample Type :- EDTA, URINE, URINE-PP

Sample Collected Time 24/03/2024 10:05:03

Final Authentication : 24/03/2024 14:13:44

HAEMATOLOGY

Test Name	Value	Unit	Biological Ref Interval
BLOOD GROUP ABO	"A" POSITIVE		
BLOOD GROUP ABO Methodology : Haemagglutination reaction Kit Name : Monoclonal agglutinating antibodies (Span clone).			
URINE SUGAR (FASTING) Collected Sample Received	Nil		Nil
URINE SUGAR PP Collected Sample Received	Nil		Nil

MANOJCHOUDHARY, MUKESH SINGH
Technologist

Page No: 10 of 11



Dr. Rashmi Bakshi
MBBS, MD (Path)
RMC No. 17975/008828

Dr. Goyal's

Path Lab & Imaging Centre

B-51, Ganesh Nagar, Near Metro Piller No. 109-110, New Sanganer Road,
Sodala, Jaipur-302019

Tele : 0141-2293346, 4049787, 9887049787

Website: www.drgoyalspathlab.com | E-mail: drgoyalpiyush@gmail.com Patient ID :- 12236584



Date :- 24/03/2024 09:53:22

NAME :- Mrs. RAJNI BUNKER

Ref. By Dr:- BOB

Sex / Age :- Female 47 Yrs 6 Mon 20 Days

Lab/Hosp :-

Company :- MediWheel

Sample Type :- PLAIN/SERUM

Sample Collected Time 24/03/2024 10:05:03

Final Authentication : 24/03/2024 11:55:28

BIOCHEMISTRY

Test Name	Value	Unit	Biological Ref Interval
BLOOD UREA NITROGEN (BUN)	8.6	mg/dl	0.0 - 23.0

*** End of Report ***

SURENDRAKHANGA

Page No: 11 of 11



Dr. Rashmi Bakshi
MBBS, MD (Path)
RMC No. 17975/008828

Dr Goyal's Path Lab, Jaipur

Name : RAJNI BUNKER / F

24 Mar 2024

