



Creating life in Science



Pathology Department

Patient's name : PATEL SAVITABEN DINESHBHAI
 Age/Sex : 46 Years/Female
 Referred by : Dr. MEDIWHEEL
 Collection Time : 09:58

Reg. ID : P-6847-23
 Accession : 24676
 Order Dt/time : 23/03/2024 09:58

Complete Blood Count

Sample Type: EDTA

Test Name	Result	Units	Biological Reference Interval
Total R.B.C. :	4.63	mill/c.mm	4.2 - 5.4
Total W. B. C. :	5380	/cu mm	4000 - 10500
Platelet Count :	305000	/cu.mm	1,50,000 - 4,50,000

Differential Count

Neutrophils :	60	%	40 - 70
Lymphocytes :	35	%	20 - 40
Eosinophils :	03	%	1 - 4
Monocytes :	02	%	2 - 6
Basophils :	00	%	0 - 01

Blood Indices

P. C. V : .	28.9	%	37 - 47
M. C. V. :	62.4	fl	78 - 100
M.C.H :	18.2	pg	27 - 31
M. C. H. C :	29.1	%	32 - 36
R.D.W :	16.2	%	11.5 - 14.0

E.S.R.(Westergren Method)

After one hour : 08 mm/hr 3 - 12

TESTS DONE ON FULLY AUTOMATED HEMATOLOGY ANALYZER.

Dr. Gayatri M. Mehta
M. D. (Patho)

Reg. No. G-32215

DR GAYATRI MEHTA
MD(PATHOLOGY)

DR. ANAND D. PARIKH
MD(PATHOLOGY)

LAB USE ONLY (Entered by :GM Enter Date/Time:23/03/2024 6:03:00 PM) (Verify by :GM Verify Date/Time:23/03/2024 6:03:00 PM)



Vidhi Diagnostics | Pathology Department

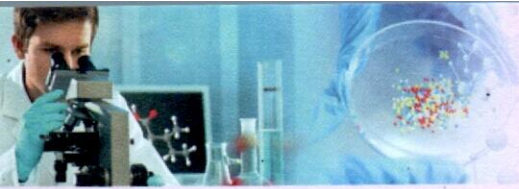L-86, Swatantra Senani Nagar, Opp. Akhbarnagar Petrol Pump, Nr. Akhbarnagar Circle, Nava-Vadaj, Ahmedabad - 380 013.

M. - Pathology : 8849893954, Ph. : 079-27621406, M. 98799 29406, 98250 09406, E-mail : vidhidiagnostics@gmail.com, Web. : www.vidhidiagnostics.com

Time (Pathology) : Mon. to Sat. 8.30 am to 8.00 pm, Sunday 9 am to 12 Noon

Pathology means science behind medicine

CT SCAN & CBCT FACILITY NOW AVAILABLE



Creating life in Gujarat



Pathology Department

Patient's name	: PATEL SAVITABEN DINESHBHAI	Reg. ID	: P-6847-23
Age/Sex	: 46 Years/Female	Accession	: 24676
Referred by	: Dr. MEDIWHEEL	Order Dt/time	: 23/03/2024 09:58
Collection Time	: 09:58		

Blood Group

Sample Type: EDTA sample.

Test Name	Result
BG :	" B "
RH :	POSITIVE
Remarks	Done by forward grouping method.

Dr. Gayatri M. Mehta
 M. D. (Patho)
 Reg. No. G-32215

DR GAYATRI MEHTA
MD(PATHOLOGY)

DR. ANAND D. PARIKH
MD(PATHOLOGY)

LAB USE ONLY (Entered by :GM Enter Date/Time:23/03/2024 6:02:00 PM) (Verify by :GM Verify Date/Time:23/03/2024 6:02:00 PM)



Vidhi Diagnostics | Pathology Department

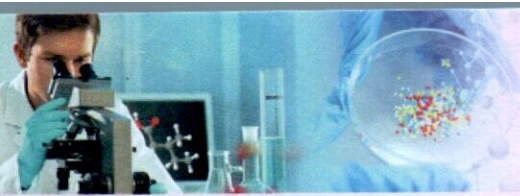L-86, Swatantra Senani Nagar, Opp. Akhbarnagar Petrol Pump, Nr. Akhbarnagar Circle, Nava-Vadaj, Ahmedabad - 380 013.

M. - Pathology : 8849893954, Ph. : 079-27621406, M. 98799 29406, 98250 09406, E-mail : vidhidiagnostics@gmail.com, Web. : www.vidhidiagnostics.com

Time (Pathology) : Mon. to Sat. 8.30 am to 8.00 pm, Sunday 9 am to 12 Noon

Pathology means science behind medicine

CT SCAN & CBCT FACILITY NOW AVAILABLE



Pathology Department

Patient's name : PATEL SAVITABEN DINESHBHAI
Age/Sex : 46 Years/Female
Referred by : Dr. MEDIWHEEL
Collection Time : 09:58

Reg. ID : P-6847-23
Accession : 24676
Order Dt/time : 23/03/2024 09:58

Blood Glucose

Sample Type: Serum

Test Name	Result	Units	Biological Reference Interval
Fasting Blood Glucose :	101.6	mg/dl	70 - 110
Urine Sugar :	NIL		Absent
<i>GOD-POD Method.</i>			

Blood Glucose

Sample Type: Serum

Test Name	Result	Units	Biological Reference Interval
Post Prandial Blood Glucose After 2hr. :	SAMPLE NOT RECEIVED	mg/dl	80 - 140
<i>GOD-POD Method.</i>			

Lipid Profile

Sample Type: Serum

Test Name	Result	Units	Biological Reference Interval
S. Cholesterol : <i>Oxidase-esterase method.</i>	130	mg/dl	0 - 200
S. Triglyceride : <i>Enzymatic Colorimetry method</i>	92.1	mg/dL	0 - 200
S. HDL - Cholesterol : <i>Serum by Enzymatic method.</i>	35.3	mg/dL	35 - 65
S. LDL - Cholesterol : <i>Serum by Enzymatic method</i>	76.28	mg/dL	0 - 130
S. VLDL - Cholesterol :	18.42	mg/dL	0 - 30
S. Chole/HDL.Ratio :	3.68		1 - 6
S. LDL / HDL Cholesterol Ratio :	2.16		0 - 3.5

Dr. Gayatri M. Mehta

M. D. (Patho)

Reg. No. G-32215

Vidhi Diagnostics | Pathology Department

L-86, Swatantra Senani Nagar, Opp. Akharnagar Petrol Pump, Nr. Akharnagar Circle, Nava-Vadaj, Ahmedabad - 380 013.

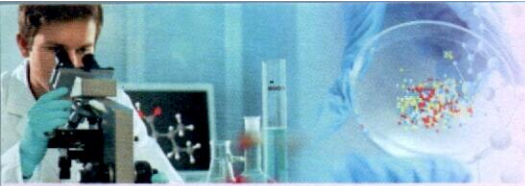M. - Pathology : 8849893954, Ph. : 079-27621406, M. 98799 29406, 98250 09406, E-mail : vidhidiagnostics@gmail.com, Web. : www.vidhidiagnostics.com

Time (Pathology) : Mon. to Sat. 8.30 am to 8:00 pm, Sunday 9 am to 12 Noon

Pathology means science behind medicine

CT SCAN & CBCT FACILITY NOW AVAILABLE





Creating Life in Progress



Pathology Department

Patient's name : PATEL SAVITABEN DINESHBHAI
 Age/Sex : 46 Years/Female
 Referred by : Dr. MEDIWHEEL
 Collection Time : 09:58

Reg. ID : P-6847-23
 Accession : 24676
 Order Dt/time : 23/03/2024 09:58

HbA1C

Sample Type: EDTA

Test Name	Result	Units	Biological Reference Interval
HbA1C :	5.3	%	Non-diabetic: 4.2-6.2 Pre-diabetic : 6.3-7.2 Diabetic : 7.3-8.2

Comment

*As per the new 2009 update of American Diabetes Association regarding HbA1C & Mean Blood Glucose relationship.

NOTE:

This test is used to monitor diabetic patients compliance with the therapeutic regimen and logo It's level is proportional to both the average blood glucose concentration and the life span of the red blood cells (RBC) in circulation. HbA1c values are free of day to day glucose fluctuations and are unaffected by exercise or recent food intake.

Dr. Gayatri M. Mehta
 M. D. (Patho)

Reg. No. G-32215

DR GAYATRI MEHTA
 MD(PATHOLOGY)

DR. ANAND D. PARIKH
 MD(PATHOLOGY)

LAB USE ONLY (Entered by :GM Enter Date/Time:23/03/2024 6:03:00 PM) (Verify by :GM Verify Date/Time:23/03/2024 6:03:00 PM)



Vidhi Diagnostics | Pathology Department

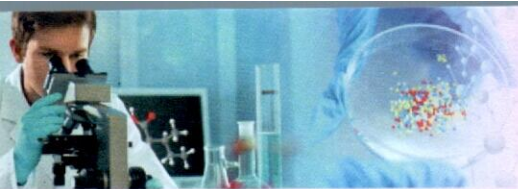L-86, Swatantra Senani Nagar, Opp. Akhbarnagar Petrol Pump, Nr. Akhbarnagar Circle, Nava-Vadaj, Ahmedabad - 380 013.

M. - Pathology : 8849893954, Ph. : 079-27621406, M. 98799 29406, 98250 09406, E-mail : vidhidiagnostics@gmail.com, Web. : www.vidhidiagnostics.com

Time (Pathology) : Mon. to Sat. 8.30 am to 8.00 pm, Sunday 9 am to 12 Noon

Pathology means science behind medicine

CT SCAN & CBCT FACILITY NOW AVAILABLE



Pathology Department



Patient's name : PATEL SAVITABEN DINESHBHAI
 Age/Sex : 46 Years/Female
 Referred by : Dr. MEDIWHEEL
 Collection Time : 09:58

Reg. ID : P-6847-23
 Accession : 24676
 Order Dt/time : 23/03/2024 09:58

BIOCHEMISTRY

Sample type :Serum

Test Name	Result	Units	Biological Reference Interval
Urea , (Serum by GLDH method) :	14.0	mg/dl	10 - 50
S.Uric acid , (Serum by Uricase method) :	4.7	mg/dl	2.6-6.0
Bun :	6.5	mg/dl	6-20
Creatinine , (Serum by Enzymatic reaction) :	0.52	mg/dl	0.5-1.2
S.G.P.T (ALT) : (Serum by IFCC method)	7.6	U/L	0 - 40
S.G.O.T (AST) : (Serum by IFCC method)	15.9	U/L	0 - 37
ALK.PHOSPHATASE : (Serum by PNP method)	82	U/L	35-104
G.G.T :	15.1	U/L	8 - 78
<u>BILIRUBIN</u>			
Total :	0.69	mg/dl	Up to 1.2
Direct :	0.32	mg/dl	0-0.7
Indirect :	0.37	mg/dl	0 - 0.5
<u>SERUM PROTEINS</u>			
Total Protein (Serum by Biuret method) :	6.84	gms/dl	6.4 - 8.5
Albumin (Serum by BCG method) :	3.98	gms/dl	3.97-4.94
Globulins :	2.86	gms/dl	2.3 - 3.5
A/G Ratio :	1.392		0.9 - 2.9

Dr. Gayatri M. Mehta
 M. D. (Patho)

Reg. No. G-32215

DR GAYATRI MEHTA
 MD(PATHOLOGY)

DR.ANAND D.PARIKH
 MD(PATHOLOGY)

LAB USE ONLY (Entered by :GM Enter Date/Time:23/03/2024 6:02:00 PM) (Verify by :GM Verify Date/Time:23/03/2024 6:02:00 PM)



Vidhi Diagnostics | Pathology Department

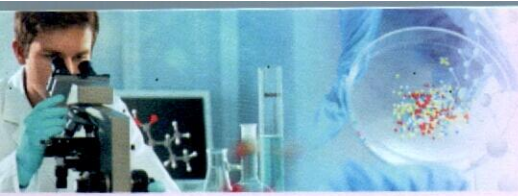L-86, Swatantra Senani Nagar, Opp. Akhbarnagar Petrol Pump, Nr. Akhbarnagar Circle, Nava-Vadaj, Ahmedabad - 380 013.

M. - Pathology : 8849893954, Ph. : 079-27621406, M. 98799 29406, 98250 09406, E-mail : vidhidiagnostics@gmail.com, Web. : www.vidhidiagnostics.com

Time (Pathology) : Mon. to Sat. 8.30 am to 8.00 pm, Sunday 9 am to 12 Noon

Pathology means science behind medicine

CT SCAN & CBCT FACILITY NOW AVAILABLE



Pathology Department



Patient's name : PATEL SAVITABEN DINESHBHAI
Age/Sex : 46 Years/Female
Referred by : Dr. MEDIWHEEL
Collection Time : 09:58

Reg. ID : P-6847-23
Accession : 24676
Order Dt/time : 23/03/2024 09:58

Thyroid Function Test

Sample Type: Serum

Test Name	Result	Units	Biological Reference Interval
TOTAL T3 :	1.48	ng/ml	1.07 - 1.86
TOTAL T4 :	7.80	µg/dL	6.09 - 12.23
TSH(Ultra sensitive) :	1.92	µIU/mL	0.4001 - 4.049

Dr. Gayatri M. Mehta
M. D. (Patho)
Reg. No. G-32215

DR GAYATRI MEHTA
MD(PATHOLOGY)

DR. ANAND D. PARIKH
MD(PATHOLOGY)

LAB USE ONLY (Entered by : GM Enter Date/Time: 23/03/2024 6:05:00 PM) (Verify by : GM Verify Date/Time: 23/03/2024 6:06:00 PM)



Vidhi Diagnostics | Pathology Department

L-86, Swatantra Senani Nagar, Opp. Akhbarnagar Petrol Pump, Nr. Akhbarnagar Circle, Nava-Vadaj, Ahmedabad - 380 013.

M. - Pathology : 8849893954, Ph. : 079-27621406, M. 98799 29406, 98250 09406, E-mail : vidhidiagnostics@gmail.com, Web. : www.vidhidiagnostics.com

Time (Pathology) : Mon. to Sat. 8.30 am to 8.00 pm, Sunday 9 am to 12 Noon

Pathology means science behind medicine

CT SCAN & CBCT FACILITY NOW AVAILABLE



Pathology Department



Patient's name : PATEL SAVITABEN DINESHBHAI
 Age/Sex : 46 Years/Female
 Referred by : Dr. MEDIWHEEL
 Collection Time : 09:58

Reg. ID : P-6847-23
 Accession : 24676
 Order Dt/time : 23/03/2024 09:58

Urine Analysis

Sample Type: Urine

Test Name	Result	Units	Biological Reference Interval
<u>Physical Examination</u>			
Quantity :	20	ml	0 - 500 ml
Colour :	Pale Yellow		Pale Yellow
Transparency :	Slight Turbid.		Clear
Reaction :	Acidic		4.6 - 8.0
Specific Gravity :	1.020		1.016 - 1.022
Sediment :	Present		
<u>Chemical Examination</u>			
Albumin :	Present (Faint Trace)		Absent
Sugar :	NIL		Absent
Acetone :	Absent		Absent
Bile Salts :	Absent		Absent
Bile Pigments :	Absent		Absent
Urobilogen :	Absent		Absent
Nitrites :	Absent		Absent
<u>Microscopic Examination</u>			
Red blood Cells :	2-3	/h.p.f	Absent
Pus Cells :	2-3	/h.p.f	Absent
Epithelial Cells :	1-2	/h.p.f	< 10.0
Amorphous :	Absent	/h.p.f	Absent
Bacteria :	Absent	/h.p.f	Absent
Crystals :	Absent	/h.p.f	Absent
Casts :	Absent	/h.p.f	Absent
Fungus :	Not seen	/h.p.f	Absent

Dr. Gayatri M. Mehta
 M. D. (Patho)

Reg. No. G-32215

DR GAYATRI MEHTA
 MD(PATHOLOGY)

DR. ANAND D. PARIKH
 MD(PATHOLOGY)



LAB ONLY (Entered by :GM Enter Date/Time:23/03/2024 6:07:00 PM) (Verify by :GM Verify Date/Time:23/03/2024 6:07:00 PM)

Vidhi Diagnostics | Pathology Department

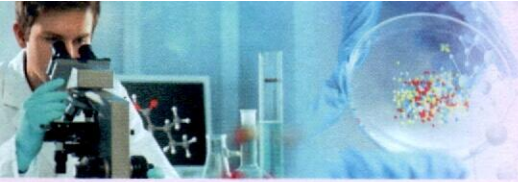L-86, Swatantra Senani Nagar, Opp. Akhbarnagar Petrol Pump, Nr. Akhbarnagar Circle, Nava-Vadaj, Ahmedabad - 380 013.

M. - Pathology : 8849893954, Ph. : 079-27621406, M. 98799 29406, 98250 09406, E-mail : vidhidiagnostics@gmail.com, Web. : www.vidhidiagnostics.com

Time (Pathology) : Mon. to Sat. 8.30 am to 8.00 pm, Sunday 9 am to 12 Noon

Pathology means science behind medicine

CT SCAN & CBCT FACILITY NOW AVAILABLE



Pathology Department



Patient's name : PATEL SAVITABEN DINESHBHAI
Age/Sex : 46 Years/Female
Referred by : Dr. MEDIWHEEL
Collection Time : 09:58

Reg. ID : P-6847-23
Accession : 24676
Order Dt/time : 23/03/2024 09:58

Stool Examination

Sample Type: Stool

Test Name	Result	Units	Biological Reference Interval
-----------	--------	-------	-------------------------------

PHYSICAL EXAMINATION

Quantity	10 gms
Colour	Brown
Consistency	Solid
Mucus	Nil
Occult Blood	Negative
Peroxidase Reaction with o-Dianisidine	
Reaction	Acidic
pH Strip Method	

MICROSCOPIC EXAMINATION

Pus Cells	2 - 3/hpf
RBCs	Nil
Vegetable Cells	Absent
Trophozoites	Nil
Cysts	Nil
Ova	Nil
Fat Globules	Nil

----- End Of Report -----

Dr. Gayatri M. Mehta

M. D. (Patho)

Reg. No. G-32215

DR GAYATRI MEHTA
MD(PATHOLOGY)

DR. ANAND D. PARIKH
MD(PATHOLOGY)

LAB USE ONLY (Entered by :GM Enter Date/Time:23/03/2024 6:05:00 PM) (Verify by :GM Verify Date/Time:23/03/2024 6:05:00 PM)



Vidhi Diagnostics | Pathology Department

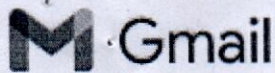
L-86, Swatantra Senani Nagar, Opp. Akhbarnagar Petrol Pump, Nr. Akhbarnagar Circle, Nava-Vadaj, Ahmedabad - 380 013.

M. - Pathology : 8849893954, Ph. : 079-27621406, M. 98799 29406, 98250 09406, E-mail : vidhidiagnostics@gmail.com, Web. : www.vidhidiagnostics.com

Time (Pathology) : Mon. to Sat. 8.30 am to 8.00 pm, Sunday 9 am to 12 Noon

Pathology means science behind medicine

CT SCAN & CBCT FACILITY NOW AVAILABLE



vidhi diagnostics <vidhidiagnostics@gmail.com>

Health Check up Booking Request(bobS18081)

1 message

Mediwheel <wellness@mediwheel.in>

22 March 2024 at 14:41

To: vidhidiagnostics@gmail.com

Cc: customercare@mediwheel.in



Mediwheel
...Your wellness partner

011-41195959

Dear VIDHI DIAGNOSTICS

We have received a booking request with the following details. Provide your confirmation by clicking on the Yes button.

You confirm this booking? Yes No

Name : MR. PATEL DINESH KANJIBHAI

Contact Details : 9265388807

Hospital Package Name : Mediwheel Full Body Health Checkup Female Above 40

Location : L-86 Swatantra - Senani Nagar , Opp- Akhbarnagar Bus Terminals, New Wadaj , Ahmedabad -13

Appointment Date : 23-03-2024

Member Information

Booked Member Name	Age	Gender
SAVITA	47 year	Female

Tests included in this Package -

- Mammography
- Stool Test
- Gynae Consultation
- Thyroid Profile
- ESR
- Blood Glucose (Fasting)
- General Physician Consultation
- TMT OR 2D ECHO
- Blood Group
- Blood Glucose (Post Prandial)
- Chest X-ray
- ECG
- USG Whole Abdomen
- Eye Check-up consultation
- Urine Sugar Fasting
- Urine Sugar PP
- Dental Consultation
- Urine analysis

ભારત સરકાર
Government of India

પટેલ સવિતાબેન દિનેશભાઈ
Patel Savitaben Dineshbhai

જન્મ તારીખ / DOB : 01/06/1977
સ્ત્રી / Female



2881 9545 7430

આધાર - સામાન્ય માણસનો અધિકાર

Vidhi Diagnostics
L-86, Swatantra-Senani Nagar,
Nr. Akhbarnagar Bus Terminals
Nr. Akhbarnagar Circle,
New Wadaj, Ahmedabad-13.

Dr. Dinesh S. Modh

M.D., D.M.R.E. (Radiodiagnosis)
Consultant Radiologist & Sonologist
Ex. Junior Lecturer, B.J. Medical College, Civil Hospital, A'bad.

VIDHI
DIAGNOSTICS



DATE: 23/03/2024		
NAME: Patel Sanitelben Dimeshbhai		
AGE: 46 yrs / female		
MEDICAL EXAMINATION:-		
HEIGHT: 149 cm	WEIGHT: 69kg	
BP: 112/78 mmHg	PULSE: 86 per min	
SPO2: 97	TEMPERATURE: (N)	
RS: (N)	CVS: (N)	
ASYMTOMATIC		
HISTORY: H/O HTN NO H/O DM, Thyroid or TB		
EYE CHECK-UP:-	RIGHT	LEFT
DISTANCE:	6/6	6/6
NEAR:	N/6	N/6
COLOR VISION:	(N)	(N)
DENTAL CHECK-UP:	(N)	
ADV: HE/SHE IS MEDICALLY FIT		

Dr. Vidhi D. Modh

Reg. No. G-74019

Vidhi Diagnostics
L-86, Swatantra-Senani Nagar,
Nr. Akhbarnagar Bus Terminals
Nr. Akhbarnagar Circle,
New Wadaj, Ahmedabad-13.

ISO 9001:2015 Certified Diagnostics Center

Vidhi Imaging Center

L-86, Swatantra Senani Nagar, Opp. Indian Oil Petrol Pump, Akhbarnagar Circle, Nava Vadaj, Ahmedabad - 380 013.

Phone : (Radiology) 079-2762 1406 | M. 98799 29406, 98250 09406 | Time (Radiology) : Mon. to Sat. 9 am to 2 pm, 5 to 9 pm, Sunday 9 am to 12 Noon

E-mail : vidhidiagnostics@gmail.com, Website : www.vidhidiagnostics.com

Multislice CT Scan | CBCT-Dental Scan | Live 3D-4D Sonography | Colour Doppler | Echo Cardiography | Interventional Radiology | Maxillofacial Radiology | Fetal Medicine
Digital X-Ray | Digital Mammography | Digital OPG / TMJ | ECG / TMT / PFT / EEG / EMG | Audiometry | Pathology Laboratory | Health Check Up Plans | Pre Employment Check Up

CT SCAN & CBCT FACILITY NOW AVAILABLE

ID: 13166
Name: savitaben

HR : 87 bpm
PR : 156 ms
QRS : 78 ms

** normal ECG **
Sinus rhythm

Age: 46yrs
Sex: Male
Hospital: **Dr. Avinash Bhaskar**
Reg. No.: **G-45946**

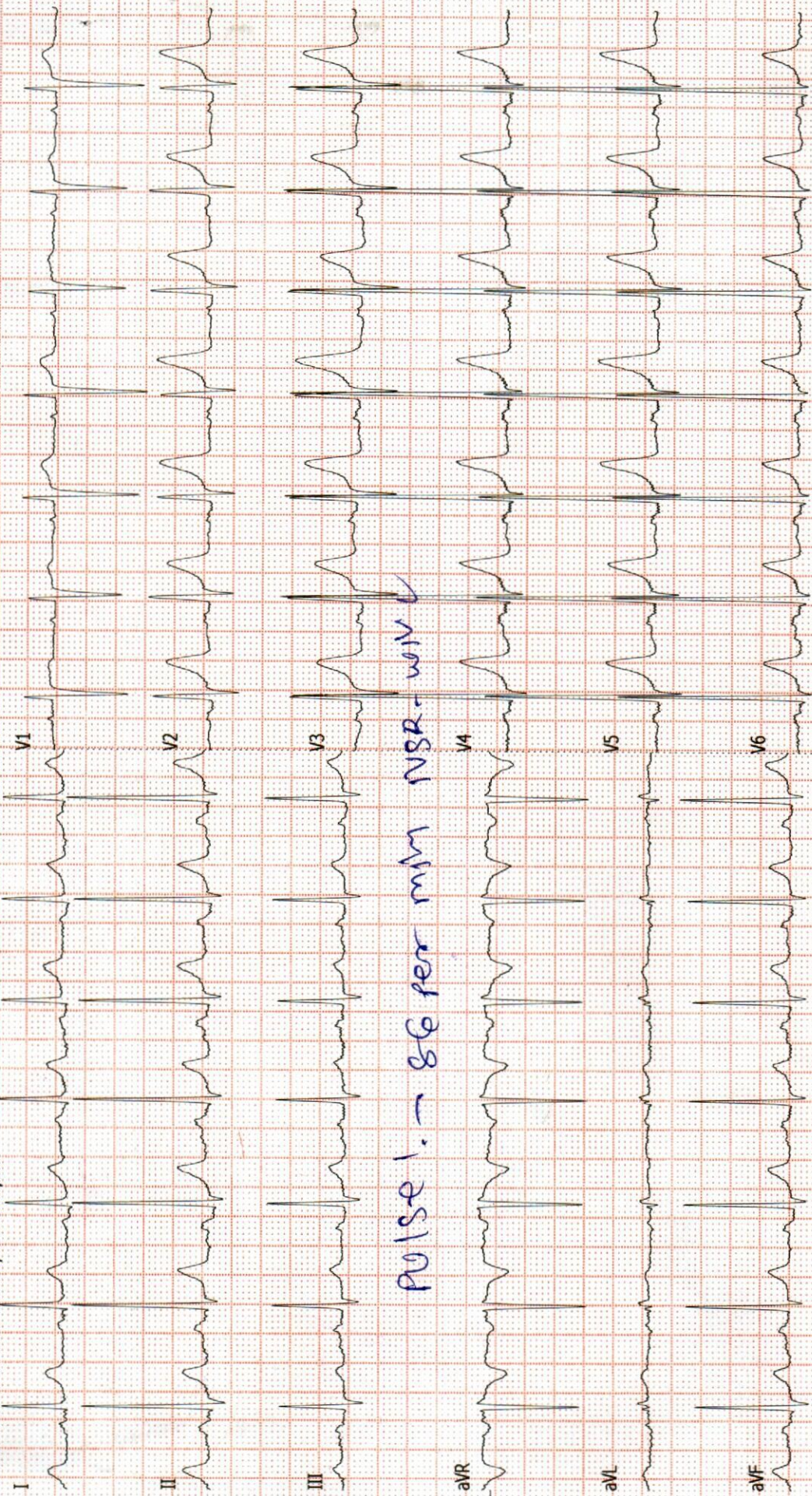
Vidhi Diagnostics
L-86, Swatantra Senani Nagar,
Opp. Akharnagar Bus Terminal,
Nr. Akharnagar Circle,
New Wadaj, Ahmedabad-13.

Department:

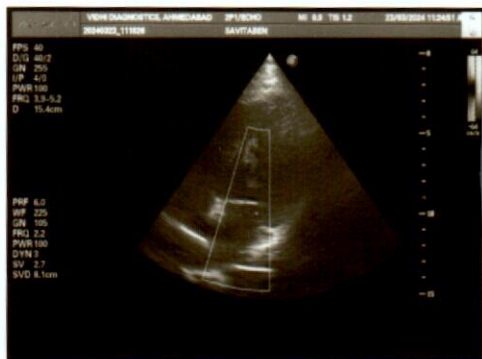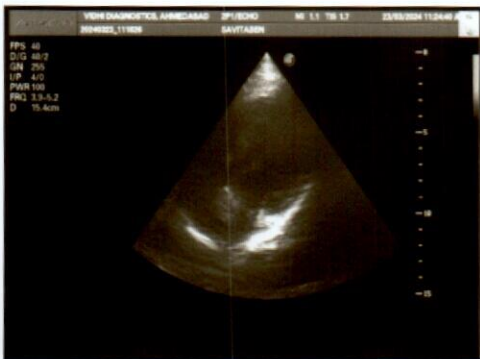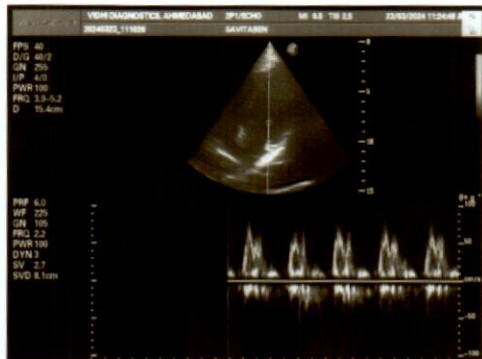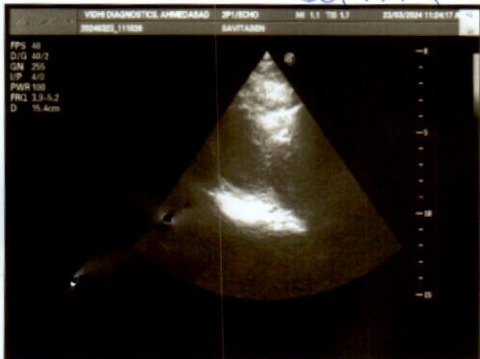RV5+SVL: 2.196 mv

Need to be confirmed by doctor. Doctor Name: _____

0.67Hz - 35Hz AC 50Hz 25 mm/s 20 mm/mv



Scvital



Dr. Dinesh S. Modh

M.D., D.M.R.E. (Radiodiagnosis)

Consultant Radiologist & Sonologist

Ex. Junior Lecturer, B.J. Medical College, Civil Hospital, A'bad.



Patient's name : PATEL SAVITABEN DINE
Reg. ID : R-14849-23
Referred by : Dr. MEDIWHEEL

Age/Sex : 46 Years/Female
Accession : 24702
Date : 23/03/2024

USG ABDOMEN

LIVER: - Liver appears normal in size & show normal echotexture. No evidence of diffuse or focal lesion is seen. Intrahepatic biliary radicals appear normal. Portal vein and CBD appear normal. No e/o calculus is seen in bile duct.

GALL BLADDER: - Gall bladder is distended & appears normal. No evidence of calculus or cholecystitis is seen. No evidence of pericholecystic fluid is seen.

SPLEEN: - Spleen appears normal in size & shows normal echotexture. No evidence of diffuse or focal lesion is seen.

PANCREAS: - Pancreas appears normal size and echopattern. No e/o diffuse or focal lesion is seen. Main pancreatic duct appears normal.

KIDNEY: - Both Kidneys appear normal in size & echotexture.

No e/o calculus or hydronephrosis or hydroureter is seen in either side.

Cortico-medullary differentiation is maintained on either side.

Both suprarenal regions appear normal.

RIF & BOWEL LOOPS (By high frequency probe): - Normal.

No evidence of pre & para aortic lymphadenopathy is seen.

No evidence of free fluid is seen in abdomen.

No evidence of dilated or thickened bowel loops is seen.

Urinary bladder: - shows changes of cystitis. No e/o calculus or mass lesion is seen in bladder.

Uterus appears normal in size and echopattern.

No evidence of diffuse or focal lesion is seen.

Cervical region appears normal.

Endometrial thickness is 6.4mm.

Both adnexal regions appear normal.

No e/o free fluid is seen in pouch of Douglas.

Thanks for reference.

Dr. Dinesh S. Modh
MD, DMRE (Radiodiagnosis)
DR DINESH S. MODH
23025
M.D. DMRE(RADIODIAGNOSIS)

Vidhi Diagnostics
L-86, Swatantra-Senani Nagar,
Nr. Akhbarnagar Bus Terminals
Nr. Akhbarnagar Circle,
New Wadaj, Ahmedabad-13.

ISO 9001:2015 Certified Diagnostics Center

Vidhi Imaging Center

L-86, Swatantra Senani Nagar, Opp. Indian Oil Petrol Pump, Akhbarnagar Circle, Nava Vadaj, Ahmedabad - 380 013.

Phone : (Radiology) 079-2762 1406 | M. 98799 29406, 98250 09406 | Time (Radiology) : Mon. to Sat. 9 am to 2 pm, 5 to 9 pm, Sunday 9 am to 12 Noon
E-mail : vidhidiagnostics@gmail.com, Website : www.vidhidiagnostics.com

Multislice CT Scan | CBCT-Dental Scan | Live 3D-4D Sonography | Colour Doppler | Echo Cardiography | Interventional Radiology | Maxillofacial Radiology | Fetal Medicine
Digital X-Ray | Digital Mammography | Digital OPG / TMJ | ECG / TMT / PFT / EEG / EMG | Audiometry | Pathology Laboratory | Health Check Up Plans | Pre Employment Check Up

CT SCAN & CBCT FACILITY NOW AVAILABLE

Dr. Dinesh S. Modh

M.D., D.M.R.E. (Radiodiagnosis)

Consultant Radiologist & Sonologist

Ex. Junior Lecturer, B.J. Medical College, Civil Hospital, A'bad.



Patient's name : PATEL SAVITABEN DINE
Reg. ID : R-14849-23
Referred by : Dr. MEDIWHEEL

Age/Sex : 46 Years/Female
Accession : 24702
Date : 23/03/2024

X-RAY CHEST (PA VIEW)

Both lung fields appear normal.
No e/o consolidation or cavitations is seen.
Both costo-phrenic angles appear clear.
Cardiac size is with in normal limits.
Both domes of diaphragm appear normal.
Bony thoracic cage appears normal.

Thanks for reference.

Dr. Dinesh S. Modh
MD DMRE (Radiodiagnosis)
DR DINESH S. MODH
M.D. DMRE(RADIODIAGNOSIS)

Vidhi Diagnostics
6, Swatantra-Senani Nagar,
Akhbarnagar Bus Terminal,
New Wadaj, Ahmedabad

ISO 9001:2015 Certified Diagnostics Center

Vidhi Imaging Center

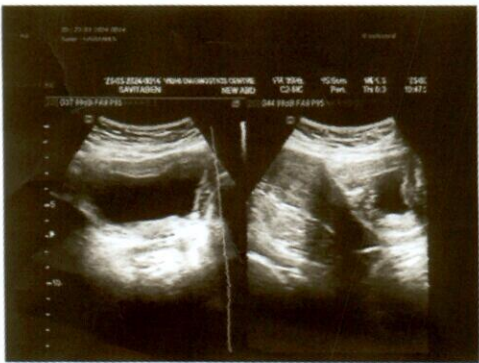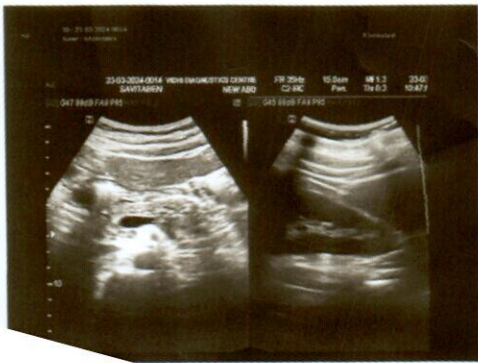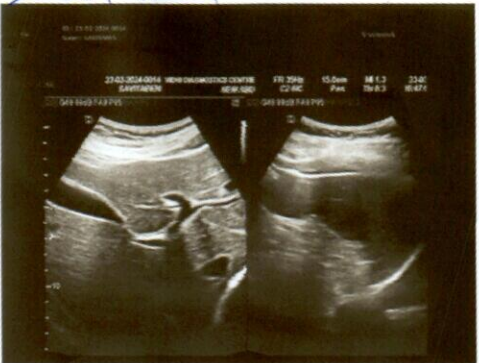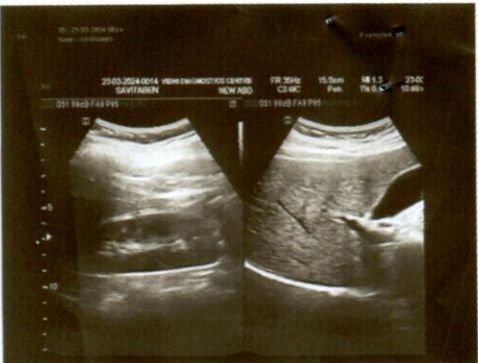L-86, Swatantra Senani Nagar, Opp. Indian Oil Petrol Pump, Akhbarnagar Circle, Nava Vadaj, Ahmedabad - 380 013.

Phone : (Radiology) 079-2762 1406 | M. 98799 29406, 98250 09406 | Time (Radiology) : Mon. to Sat. 9 am to 2 pm, 5 to 9 pm, Sunday 9 am to 12 Noon
E-mail : vidhidiagnostics@gmail.com, Website : www.vidhidiagnostics.com

Multislice CT Scan | CBCT-Dental Scan | Live 3D-4D Sonography | Colour Doppler | Echo Cardiography | Interventional Radiology | Maxillofacial Radiology | Fetal Medicine
Digital X-Ray | Digital Mammography | Digital OPG/TMJ | ECG/TMT/PFT/EEG/EMG | Audiometry | Pathology Laboratory | Health Check Up Plans | Pre Employment Check Up

CT SCAN & CBCT FACILITY NOW AVAILABLE

sum 101



Dr. Dinesh S. Modh

M.D., D.M.R.E. (Radiodiagnosis)

Consultant Radiologist & Sonologist

Ex. Junior Lecturer, B.J. Medical College, Civil Hospital, A'bad.



Patient's name : PATEL SAVITABEN DINE
Reg. ID : R-14849-23
Referred by : Dr. MEDIWHEEL

Age/Sex : 46 Years/Female
Accession : 24702
Date : 23/03/2024

2D- ECHO REPORT

FINAL CONCLUSION:

LV IS NORMAL SIZE. GOOD LV SYSTOLIC FUNCTION NO RWMA.
LVEF - 60%. MILD CONCENTRIC LVH.
NORMAL LV COMPLANCE.
LA IS NORMAL SIZE. NO LA CLOT.
RV IS NORMAL SIZE. GOOD RV SYSTOLIC FUNCTION.
RA IS NORMAL SIZE.
MITRAL VALVE IS NORMAL. NO MS. MILD MR (20%). NO MVP.
AORTIC VALVE IS NORMAL. NO AS. NO AR.
TRICUSPID VALVE IS NORMAL. NO TR. RVSP-30mmHg. NO PAH.

NO CLOT, NO VEGETATION, NO PERICARDIAL EFFUSION.

DIMENSIONS:

AORTA	2.7 C.M
LEFT ATRIUM	2.8 C.M
LVDD	4.4 C.M.
IVSD	1.1 C.M
PWD	1.1 C.M
LVDS	2.9 C.M.

COLOUR DOPPLER FINDING:

STRUCTURE	VELOCITY m/sec
	Max
PULMONARY VALVE	0.8
MITRAL VALVE	E : 0.9 A: 0.6
AORTIC VALVE	1.3

Dr. Avinash Bhaskar
MBBS, D. Cardio

DR AVINASH BHASKAR
CLINICAL CARDIOLOGIST
9924836431

Vidhi Diagnostics

3, Swatantra-Senani Nagar, Akharnagar Bus Terminal
Nr. Akharnagar Circle,
New Wadaj, Ahmedabad-13.

ISO 9001:2015 Certified Diagnostics Center

Vidhi Imaging Center

L-86, Swatantra Senani Nagar, Opp. Indian Oil Petrol Pump, Akharnagar Circle, Nava Wadaj, Ahmedabad - 380 013.

Phone : (Radiology) 079-2762 1406 | M. 98799 29406, 98250 09406 | Time (Radiology) : Mon. to Sat. 9 am to 2 pm, 5 to 9 pm, Sunday 9 am to 12 Noon

E-mail : vidhidiagnostics@gmail.com, Website : www.vidhidiagnostics.com

Multislice CT Scan | CBCT-Dental Scan | Live 3D-4D Sonography | Colour Doppler | Echo Cardiography | Interventional Radiology | Maxillofacial Radiology | Fetal Medicine
Digital X-Ray | Digital Mammography | Digital OPG/TMJ | ECG/TMT/PFT/EEG/EMG | Audiometry | Pathology Laboratory | Health Check Up Plans | Pre Employment Check Up

CT SCAN & CBCT FACILITY NOW AVAILABLE