

DR. NETRAVALKAR'S ASHWINI PATHOLOGY LABORATORY

(For all investigation in Histopathology, Cytopathology, Haematology, Clinical Pathology, Microbiology & Hormonal Chemistry)

Consultant Pathologist : **Dr. Prasad Netravalkar** MBBS, MD. (Path) BOM

(HOME COLLECTION FACILITY AVAILABLE)

Panaji : 1st, Floor, Rizvi Sadan, Above Saroj Emporium, Near Inox Theatre, Opp. Municipal Market, Panaji.

Ph.: 2229142, 8407912840, 8390242524

E-mail : ashwinilabpanaji@gmail.com, drprasadnetravalkar@gmail.com

Mapusa : F8, Ramchandra Chambers, 1st Floor, Mapusa Clinic Road, Mapusa - Bardez, Goa. Ph.: 2252320, 2250709

Sanquelim : 1st floor, Shanta Commercial Complex, Sanquelim - Goa. Ph.: 2364524, 9067292714

Pt.No. : 27 270324

Pt.Name : - Poonam Kumari

Ref. By : -

Age : 41 Yrs. Sex : F

Date : 27-03-2024

Normal Range

COMPLETE HEMOGRAM

Haemoglobin	: 12.4	g/dl	11.5 - 16.5 g/dl
W.B.C Count	: 6700	cells/ cu-mm	4000 - 11000 cells/ cu-mm
R.B.C Count	: 4.03	millions / cu-mm	3.8 - 4.5 millions / cu-mm
MCV	: 86.1	fl	80 - 99 fl
MCH	: 30.7	Pg	27 - 33 Pg
MCHC	: 35.7	%	32 - 37 %
PCV	: 34.7	%	37 - 47 %
Platelet Count	: 1.45	lakhs /cu mm	1.5 - 4.5 lakhs /cu mm
E.S.R (Westergren)	: 21	mm/hr	0 - 20 mm/hr


DIFFERENTIAL COUNT

Stab Cells	: 03	%	1-5 %
Neutrophils	: 60	%	40- 60 %
Lymphocytes	: 27	%	20 - 45 %
Eosinophils	: 04	%	1 - 6 %
Monocytes	: 06	%	0 - 10 %
Basophils	: 00	%	0 - 1 %
Abnormal Cells	: Nil		

SMEAR EXAMINATION

RBC Morphology	: Normocytic , Normochromic
W.B.C Morphology	: Within Normal Limits
Platelets on Smear	: Platelets are mildly decreased in number
Parasites	: Absent

Blood Group : 'B' Rh Positive



Dr. Prasad Netravalkar
MBBS, MD (Bom)
GMC Reg No. 1294

We Care

Diagnostic centre - Lab, ultrasound, X ray, ECG, TMT, ECHO

DR. NETRAVALKAR'S ASHWINI PATHOLOGY LABORATORY

(Consultant Pathologist in: Micro-pathology, Subspecialty: Haematology, Clinical Pathology, Microbiology & Molecular Pathology)

Consultant Pathologist: **Dr. Prasad Netravalkar** MBBS MD (Diploma)

(HOME COLLECTION FACILITY AVAILABLE)

Panel: 1st Floor, Blych Sadan, Above Saraj Emporium, Near Inox Theatre, Opp. Municipal Market, Panaji
Ph: 2220142, 9407012060, 9700242524

E-mail: ashwinilabpanaji@gmail.com, drprasadnetravalkar@gmail.com

Mapusa: 1st Floor, Bhandari Chambers, 1st Floor, Mapusa Clinic Road, Mapusa, Bardez, Goa. Ph: 2252120, 2250700

Sangolim: 1st Floor, Shanti Commercial Complex, Sangolim, Goa. Ph: 2164511, 9067207111

Ph No: 27 270324

Ph Name: Poonam Kumari

Ref By:

Age: 41 Yrs. Sex: F

Date: 27-03-2024

		<u>Normal Range</u>
Fasting Blood Sugar	: 96.0 mg/dl	70-110 mg/dl
2 Hrs Blood Sugar	: 101.0 mg/dl	110-140 mg/dl

GLYCOSYLATED HAEMOGLOBIN IN BLOOD (HPLC METHOD)

HbA1C : 5.40 %

Mean Blood Glucose : 105 mg %

INTERPRETATION:

NORMAL	HbA1c % Below 6.5 %
GOOD DIABETIC CONTROL	6.5 % - 7.5 %
FAIR CONTROL	7.5 % - 8.0 %
UNSATISFACTORY CONTROL	8.0 % - 10.0 %
POOR CONTROL	Above 10.0 %


 Dr. Prasad Netravalkar
 MBBS MD (Diploma)
 Pathologist
 U.S. No. 1284

Dr. Prasad Netravalkar
 MBBS MD (Diploma)
 Pathologist
 U.S. No. 1284

DR. NETRAVALKAR'S ASHWINI PATHOLOGY LABORATORY

(For all investigation in Histopathology, Cytopathology, Haematology, Clinical Pathology, Microbiology & Hormonal Chemistry)

Consultant Pathologist : **Dr. Prasad Netravalkar** MBBS, MD. (Path) BOM

(HOME COLLECTION FACILITY AVAILABLE)

Panaji : 1st, Floor, Rizvi Sadan, Above Saroj Emporium, Near Inox Theatre, Opp. Municipal Market, Panaji.
Ph.: 2229142, 8407912840, 8390242524

E-mail : ashwinilabpanaji@gmail.com, drprasadnetravalkar@gmail.com

Mapusa : F8, Ramchandra Chambers, 1st Floor, Mapusa Clinic Road, Mapusa - Bardez, Goa. Ph.: 2252320, 2250709

Sanquelim : 1st floor, Shanta Commercial Complex, Sanquelim - Goa. Ph.: 2364524, 9067292714

Pt.No. : 27 270324

Pt.Name : - Poonam Kumari

Ref. By : -

Age : 41 Yrs. Sex : F

Date : 27-03-2024

Normal Range

LIPID PROFILE

Total Cholesterol	: 191.0 mg/dl	130 - 220 mg/dl
S. Triglycerides	: 94.0 mg/dl	35 - 170 mg/dl
HDL Cholesterol	: 51.0 mg/dl	> 45 mg/dl
LDL Cholesterol	: 121 mg/dl	< 130 mg/dl
VLDL Cholesterol	: 19 mg/dl	Upto 35 mg/dl
TC/HDLC Ratio	: 3.7	< 4.5
LDLC/HDLC Ratio	: 2.4	2.5 - 3.5



Dr. Prasad Netravalkar
MBBS, MD (Bom)
GMC Reg. No. 1294

DR. NETRAVALKAR'S ASHWINI PATHOLOGY LABORATORY

(For all investigation in Histopathology, Cytopathology, Haematology, Clinical Pathology, Microbiology & Hormonal Chemistry)

Consultant Pathologist : **Dr. Prasad Netravalkar** MBBS, MD. (Path) BOM.

(HOME COLLECTION FACILITY AVAILABLE)

Panaji : 1st, Floor, Rizvi Sadan, Above Saroj Emporium, Near Inox Theatre, Opp. Municipal Market, Panaji.
Ph.: 2229142, 8407912840, 8390242524

E-mail : ashwinilabpanaji@gmail.com, drprasadnetravalkar@gmail.com

Mapusa : F8, Ramchandra Chambers, 1st Floor, Mapusa Clinic Road, Mapusa - Bardez, Goa. Ph.: 2252320, 2250709

Sanquelim : 1st floor, Shanta Commercial Complex, Sanquelim - Goa. Ph.: 2364524, 9067292714

Pt.No. : 27 270324

Pt.Name : - Poonam Kumari

Ref. By : -


Age : 41 Yrs. Sex : F

Date : 27-03-2024

Normal Range

LIVER FUNCTION TEST

S. Bilirubin (Total)	: 0.42	mg/dl	0 - 1 mg/dl
S. Bilirubin (Direct)	: 0.19	mg/dl	0 - 0.25 mg/dl
S. Bilirubin (Indirect)	: 0.23	mg/dl	0 - 0.75 mg/dl
S.G.O.T	: 21.0	U/L	0 - 42 U/L
S.G.P.T	: 22.0	U/L	0 - 42 U/L
S. Alkaline Phosphatase	: 55.0	IU/L	15 - 112 IU/L
GGTP	: 20.0	U/L	9-37 U/L
Total Proteins	: 6.84	g/dl	6.0 - 10.0 g/dl
S. Albumin	: 3.79	gm%	3.2 - 5.5 gm%
S. Globulin	: 3	g/dl	2.3 - 3.5 g/dl
A/G Ratio	: 1.2 : 1		



Dr. Prasad Netravalkar
MBBS, MD (Bom)
GMC Reg. No. 1294

We Care

Pathology - Lab, ultrasound, X ray, ECG, TMT, ECHO

NAME: Mr. AG
2nd Floor, Near
Tel.: 0832 2238...

DR. NETRAVALKAR'S ASHWINI PATHOLOGY LABORATORY

(For all investigation in Histopathology, Cytopathology, Haematology, Clinical Pathology, Microbiology & Hormonal Chemistry)

Consultant Pathologist **Dr. Prasad Netravalkar** MBBS, MD (Path) BOM

(HOME COLLECTION FACILITY AVAILABLE)

Panaji : 1st. Floor, Rizvi Sadan, Above Saroj Emporium, Near Inox Theatre, Opp. Municipal Market, Panaji.
Ph.: 2229142, 8407912840, 8390242524

E-mail : ashwinilabpanaji@gmail.com, drprasadnetravalkar@gmail.com

Mapusa : F8, Ramchandra Chambers, 1st Floor, Mapusa Clinic Road, Mapusa - Bardez, Goa. Ph.: 2252320, 2250709

Sanquelim : 1st floor, Shanta Commercial Complex, Sanquelim - Goa. Ph.: 2364524, 9067292714

Pt.No. : 27 270324

Pt.Name : - Poonam Kumari

Ref. By : -



Age : 41 Yrs. Sex : F

Date : 27-03-2024

Normal Range

KIDNEY FUNCTION TESTS

Blood Urea	: 23.0 mg/dl	15 - 40 mg/dl
S. Creatinine	: 0.70 mg/dl	0.5 - 1.2 mg/dl
S. Uric Acid.	: 3.70 mg/dl	1.5 - 6.0 mg/dl
S. Sodium	: 142.3 mEq/L	135 - 155 mEq/L
S. Potassium	: 4.36 mEq/L	3.5 - 5.5 mEq/L
S. Chlorides	: 101.8 mEq/L	99 - 108 mEq/L

Dr. Prasad Netravalkar
MBBS, MD (Bom)
GMC Reg No. 1294

We Care

... under one roof in Panaji centre - Lab, ultrasound, X ray, ECG, TMT, ECH

DR. NETRAVALKAR'S ASHWINI PATHOLOGY LABORATORY

(For all investigation in Histopathology, Cytopathology, Haematology, Clinical Pathology, Microbiology & Hormonal Chemistry)

Consultant Pathologist **Dr. Prasad Netravalkar** MBBS, MD (Path) BOM

(HOME COLLECTION FACILITY AVAILABLE)

Panaji : 1st, Floor, Rizvi Sadan, Above Saroj Emporium, Near Inox Theatre, Opp. Municipal Market, Panaji.
Ph.: 2229142, 8407912840, 8390242524

E-mail : ashwinilabpanaji@gmail.com, drprasadnetravalkar@gmail.com

Mapusa : F-8, Ramchandra Chambers, 1st Floor, Mapusa Clinic Road, Mapusa - Bardez, Goa. Ph : 2252320, 2250709

Sanquelim : 1st floor, Shanta Commercial Complex, Sanquelim - Goa. Ph.: 2364524, 9067292714

Pt.No. : 27 270324

Pt.Name : - Poonam Kumari

Ref. By : -

Age : 41 Yrs. Sex : F

Date : 27-03-2024

EXAMINATION OF URINE

PHYSICAL EXAMINATION


Quantity : 20 ml
Colour : Pale Yellow
Appearance : Slightly Hazy
pH : 6.5
Specific Gravity : 1.010

CHEMICAL EXAMINATION

Proteins : Present (+)
Glucose : Absent
Ketone Bodies : Absent
Bile Salts : Absent
Bile Pigments : Absent
Occult Blood : Negative
Urobilinogen : Normal

MICROSCOPIC EXAMINATION [As per hpf]

Epithelial Cells : 6 - 8 /hpf
Pus Cells : 1 - 2 /hpf
Red Blood Cells : Absent
Casts : Absent
Crystals : Absent


Dr. Prasad Netravalkar
MBBS, MD (Bom)
GMC Reg No 1294

We Care

All Diagnostic facilities under one roof in Panaji centre - Lab. ultrasound. T. mag. EEG. TMT. ECHO

DR. NETRAVALKAR'S ASHWINI PATHOLOGY LABORATORY

(For all investigation in Histopathology, Cytopathology, Haematology, Clinical Pathology, Microbiology & Hormonal Chemistry)
Consultant Pathologist : **Dr. Prasad Netravalkar** MBBS, MD. (Path) BOM.

(HOME COLLECTION FACILITY AVAILABLE)

Panaji : 1st, Floor, Rizvi Sadan, Above Saroj Emporium, Near Inox Theatre, Opp. Municipal Market, Panaji.
Ph.: 2229142, 8407912840, 8390242524

E-mail : ashwinilabpanaji@gmail.com, drprasadnetravalkar@gmail.com

Mapusa : F8, Ramchandra Chambers, 1st Floor, Mapusa Clinic Road, Mapusa - Bardez, Goa. Ph.: 2252320, 2250709

Sanquelim : 1st floor, Shanta Commercial Complex, Sanquelim - Goa. Ph.: 2364524, 9067292714

Patient Name : POONAM KUMARI

Referral : SELF

Age / Gender : 41 / Female

Reporting Time : Mar 27, 2024, 01:25 p.m.

Patient ID : 31541

Sample ID :



Source : DIRECT

Test Description	Value(s)	Reference Range	Unit
Thyroid Profile			
T3 (Total) Method : Serum ECL	1.78	1.30 - 3.10	nmol/l
T4 (Total)* Method : Serum ECL	125.5	66.0 - 181.0	nmol/l
TSH(Ultrasensitive)* Method : Serum ECL	5.20	0.270 - 4.20	uIU/ml

END OF REPORT


Dr. Prasad Netravalkar
Pathologist
GMC Reg. No. 1294
Pathology Lab

Dr. Prasad Netravalkar
MBBS, MD (Bom)
GMC Reg. No. 1294

We Care

All Diagnostic facilities under one roof in Panaji centre - Lab, ultrasound, X ray, ECG, TMT, Echo


CERTIFICATE OF MEDICAL FITNESS

This is to certify that I have conducted the clinical examination

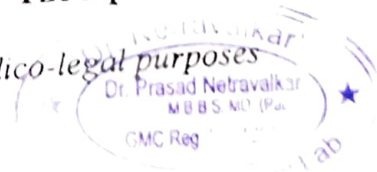
of Poornam Kumari on 27/3/24

After reviewing the medical history and on clinical examination it has been found that he/she is

<ul style="list-style-type: none">• Medically Fit	Ti <input checked="" type="checkbox"/>
<ul style="list-style-type: none">• Fit with restrictions/recommendations <p>Though following restrictions have been revealed, in my opinion, these are not impediments to the job.</p> <p>1.....</p> <p>2.....</p> <p>3.....</p> <p>However the employee should follow the advice/medication that has been communicated to him/her.</p> <p>Review after _____</p>	
<ul style="list-style-type: none">• Currently Unfit. <p>Review after _____ recommended</p>	
<ul style="list-style-type: none">• Unfit	

Dr. 
Medical Officer
The Apollo Clinic, (Location)


This certificate is not meant for medico-legal purposes



MER- MEDICAL EXAMINATION REPORT

Date of Examination	27 th March 2024	
NAME	Poonam Kumari	
AGE	41	Sex: Female
HEIGHT (cm)	152	Weight (kg): 47 kg
B.P.	100/68 mmHg	
ECG	Normal	
X Ray	Normal	
Vision Checkup	Distance Vision Ratio: 6/6 Near Vision Ratio: 6/6	
Present ailments	- NO -	
Details of Past ailments (If Any)	- NO -	
Comments / Advice : She /He is Physically Fit	She is Physically Fit	

Signature with Stamp of Medical E



Diogro

am to

Digit

Sono

100 size

INDIAN DRIVING LICENCE
GOVERNMENT OF BIHAR

DL: BR-2120160051190

Name: POONAM KUMARI

SAV/DA of: NANISH KUMAR

Address: AT-NADPUR,
 PO&PS-KHOLIAGANI,
 DIST-NALANDA

DOB: 01/01/1983 BG: B+

Valid Till (Transport):
 Valid Till (Non Transport): 31/12/2032

Badge No.:

Authorisation to drive the following vehicle:
 class B10 through 19 in India.
 Type of Vehicle: NCVA only


Signature of Holder

Issued on: 13/06/2016


State of Licencing Authority: NALANDA

Prat
 27/08/2024

() A



GPS Map Camera



Google

Panaji, Goa, India
105, 1st floor, Rizvi Sadan, next to vaidya Hospital, opp. Municipal
Market, Near Municipal Market, Panaji, Goa 403001, India
Lat 15.498457°
Long 73.822403°
27/03/24 08:37 AM GMT +05:30

Dr. Prasad Netravathi
M.B.B.S. MD. (P...)
GMC Reg. 1231
Pathology Lab

Dr. Netravalkar's Imaging Centre

Dr. Ashadevi Netravalkar
MBBS., MD, AFRC
Consultant Radiologist & Sonologist

201, 202, 203, Rizvi Sadan, 2nd Floor, Near Municipal Market, Next to Vaidya Hospital, Panaji - Goa.
Tel: 0832 2238122 | Email: drashanetravalkar@gmail.com

NAME: MRS. POONAM KUMARI
AGE: 41 YRS
REF BY: DR. SELF

DATE: 27/03/2024
SEX: F

X-RAY CHEST--- PA VIEW

Lung fields are clear.

Both costophrenic angles are clear.

Cardiac size is normal

Both domes of diaphragm are normal.

Rib cage is normal.

IMPRESSION : Normal study

With regards,



RADIOLOGIST
DR. ASHADEVI NETRAVALKAR, MD

DR. ASHADEVI NETRAVALKAR
MBBS., MD, AFRC
Consultant Radiologist
2nd Floor, Rizvi Sadan Panaji
Tel: 0832-2238122 | 9822125224

201, 202, 203, Rizvi Sadan, 2nd Floor, Near Municipal Market, Next to Valdyia Hospital, Panaji, Goa
Tel: 0832 2238122 | Email: drashadevnetravalkar@gmail.com

NAME: MRS POONAM KUMARI
AGE: 43 YRS
REF BY: DR. SELF

DATE: 27/03/2024
SEX: F

ULTRASONOGRAPHY OF ABDOMEN AND PELVIS

LIVER - It shows normal echotexture and size. No focal lesions are seen. Intrahepatic biliary and portal radicals appear normal. Length of liver is 11.6cm. PV - 9mm.

PANCREAS - It shows normal echotexture and size. No focal lesions are seen.

GALL BLADDER - It is moderately distended. No calculus is seen. Pericholecystic space is normal. CBD is normal.

SPLEEN - It shows normal echotexture and size. Length of spleen is 7.3cm.

BOTH KIDNEYS - Both kidneys show normal echotexture and size. Perirenal space is normal. Corticomedullary differentiation is seen well. No calculus or hydronephrosis is seen in both kidney.

Right kidney - measures 10.1cm x 3.2cms.

Left kidney - measures 10.5cms x 3.6cms.

Urinary Bladder is well distended. No calculus and mass is seen. Both vesicoureteric junctions are normal.

UTERUS : It is anteverted and it measures 9.1cms x 6.4cms x 4.1cms.

Myometrium show normal echotexture. No mass is seen. A seedling fibroid is seen in anterior wall. Endometrial thickness is 7mm.

Both ovaries show normal echotexture and size.

Right ovary - measures 2.8cms x 1.3 cms. Left ovary - measures 2.7cms x 1.1cms.

No adnexal mass is seen. No free fluid is seen in pelvis. Plenty of bowel gases are seen.

Impression : Normal study

With regards,


DR. ASHADEVI NETRAVALKAR, MD
RADIOLOGIST

DR. ASHADEVI NETRAVALKAR
Consultant Radiologist
2nd Floor, Rizvi Sadan, Panaji
Tel: 0832 2238122

201, 202, 203, Rizvi Sadan, 2nd Floor, Near Municipal Market, Next to Vaidya Hospital, Panaji - Goa
Tel : 0832 2238122 | Email : drashanetravalkar@gmail.com

NAME: MRS. POONAM KUMARI
AGE: 41 YRS
REF BY: DR.SELF

DATE: 27/03/2024
SEX: F

USG OF BOTH BREASTS

Normal fibroglandular and fatty tissue is seen in both breasts.

Both areolar and retroareolar and axillary areas are normal.

No mass or cystic lesion is seen.

No calcification is seen.

An oval lymphnode measuring 7mmx4mm is seen in right axillary region. It shows normal echotexture.

IMPRESSION—Normal study.

Lymph node in right axillary region.

With regards,



DR. ASHADEVI NETRAVALKAR, MD
RADIOLOGIST

DR. ASHADEVI NETRAVALKAR, MD
MBBS, MD, AFRCR
Consultant Radiologist
2nd Floor, Rizvi Sadan, Panaji
Tel: 0832-2238122 / 0832-2238123

201, 202, 203, Rizvi Sadan, 2nd Floor, Near Municipal Market, Next to Valdyia Hospital, Panaji - Goa

Tel: 0832 2238122 | Email: drashanetravalkar@gmail.com

Cardiology Report

Page 1/2

ASHWINI LABORATORY

Patient / Exam Information

Date of Exam 27.03.2024

Patient ID	VSB02280-24-03-27-1	Height
Name	POONAM KUMARI 41	Weight
DOB Age		BSA
Sex	Other	HR

Perf Phys	Ref Phys	Sonographer
Comment	Indication	

M-Mode Measurements	Value	m1	m2	m3	m4	m5	m6	Math
AV/LA								
Ao Root Diam	2.48 cm	2.48						avg.
LA Diam	1.93 cm	1.93						avg.
Left Ventricle								
IVSd	0.59 cm	0.59						avg.
LVDd	4.13 cm	4.13						avg.
LVPWd	0.59 cm	0.59						avg.
IVSs	0.98 cm	0.98						avg.
LVDs	2.76 cm	2.76						avg.
LVPWs	1.02 cm	1.02						avg.
EDV (Teich)	75.515 ml	75.515						
EDV (Cubed)	70.445 ml	70.445						
ESV (Teich)	28.522 ml	28.522						
ESV (Cubed)	21.025 ml	21.025						
SV (Teich)	46.993 ml	46.993						
SV (Cube)	49.420 ml	49.420						
EF (Teich)	62.23 %	62.23						
EF (Cube)	70.15 %	70.15						
Fract Short	33.17 %	33.17						
LV Mass	68.85 g	68.85						

2D Generic	Value	m1	m2	m3	m4	m5	m6	Math
Dist								
D	7.79 cm	10.53	3.69	7.39	10.18	3.29	11.63	avg.

Dr. Prasad Netravalkar
27.03.2024 10:56:40 AM

201.202.203, Rizvi Sadan, 2nd Floor, Near Municipal Market, Next to Vaidya Hospital, Panaji - Goa.

Tel : 0832 2238122 | Email : drashanetravalkar@gmail.com

Name

POONAM KUMARI 41

Patient ID

VS8802280-24-03-27-1

Comment

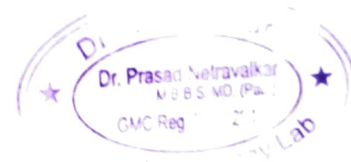
NORMAL CARDIAC CHAMBERS DIMENSIONS. NORMAL BI VENTRICLE SYSTOLIC FUNCTION. NO REGIONAL WALL MOTION ABNORMALITIES. VALVES ARE NORMAL. AORTIC ROOT IS NORMAL. PERICARDIUM IS NORMAL.

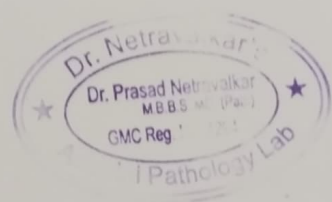
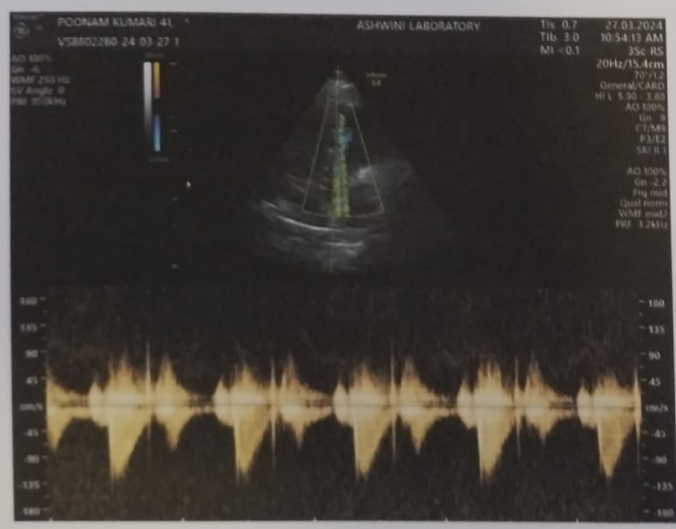
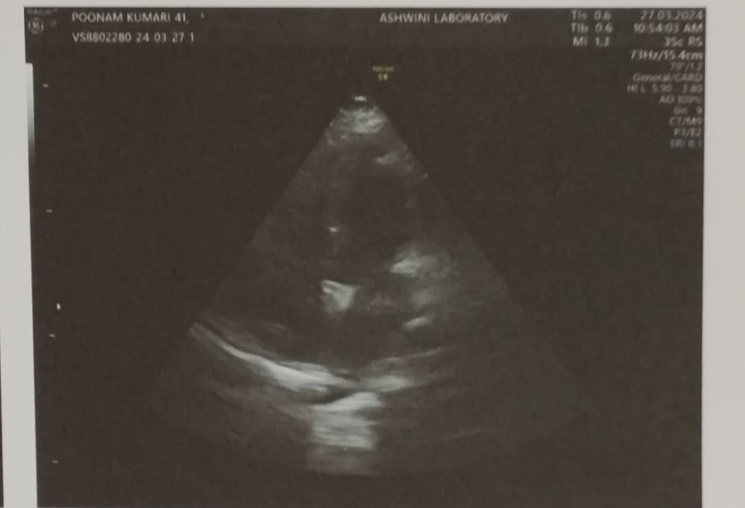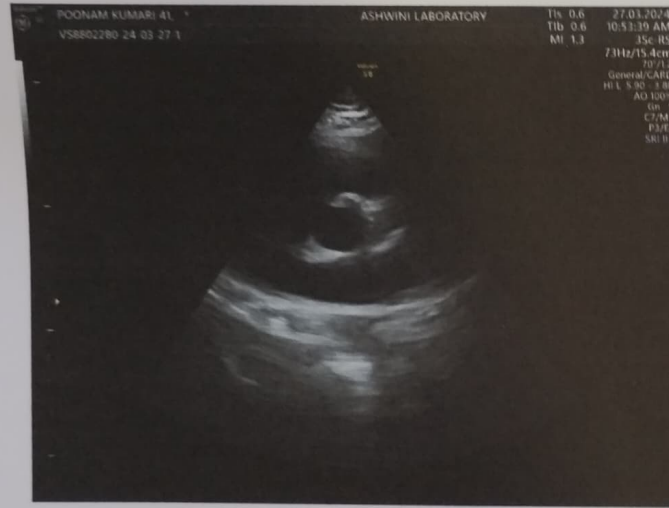
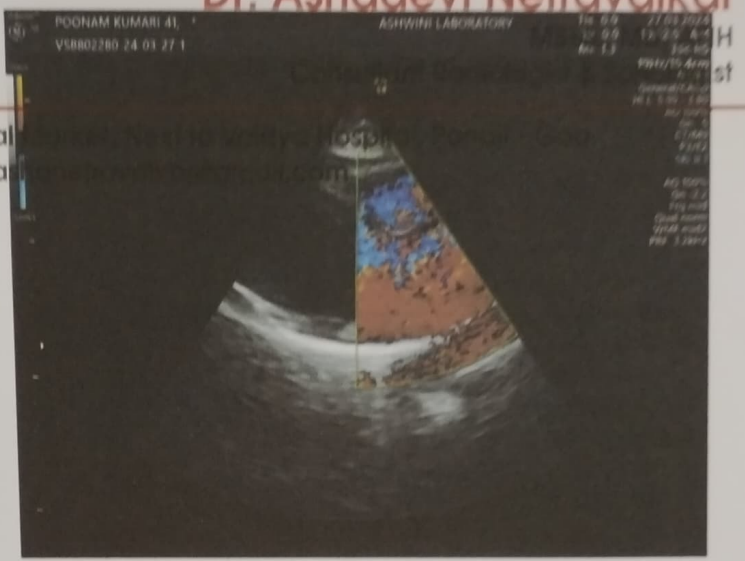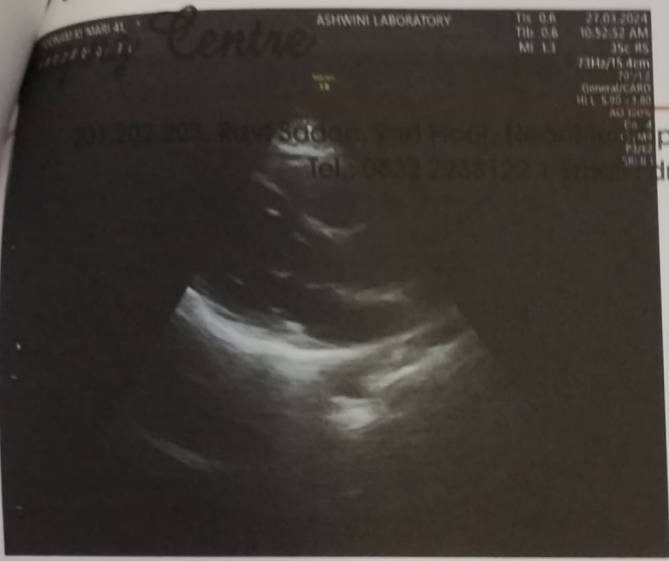
due to

Date **27.03.2024**

Perf. Physician:

Sonographer:





Dr. Netravalkar's Imaging Centre

Dr. Ashadevi Netravalkar

MBBS., MD, AFIH

Consultant Radiologist & Sonologist

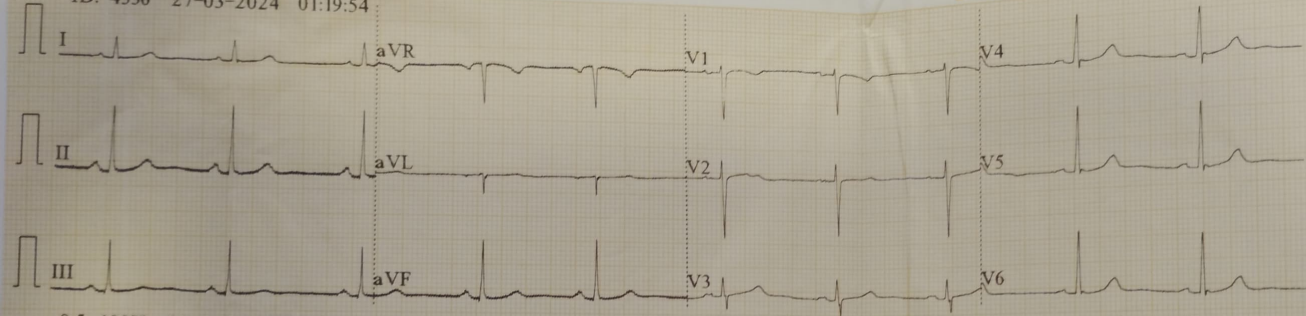
Name : POONAM KUMARI
Age : 41 M/F F Date : 27 03 24
Investigation : ECG
Ref. by Dr. : _____

201,202,203, Rizvi Sadan, 2nd Floor, Near Municipal Market,
Next to Vaidya Hospital, Panaji - Goa.

Tel.: 0832 2238122 | Email : drashanetravalkar@gmail.com

Timing : 8.00 am to 1.00 pm | 4.00 pm to 7.00 pm

ID: 4336 27-03-2024 01:19:54



0.5-100Hz 25mm/s 10mm/mV ♡62 V1.0 SEMIP V1.7

ID: 4336

Female / mmHg
41Years cm kg

HR : 61 bpm
P : 103 ms
PR : 152 ms
QRS : 71 ms
QT/QTc : 394/398 ms
P/QRS/T : 71/67/54 °
RV5/SV1 : 1.327/0.909 mV

Prasad Netravalkar
Dr. Prasad Netravalkar
MBBS, MD, (Paed)
Gen. Reg. No. 1234
Pathology Lab