

MEDICAL EXAMINATION REPORT (MER)

If the examinee is suffering from an acute life threatening situation, you may be obliged to disclose the result of the medical examination to the examinee.

1. Name of the examinee	:	Mr./Mrs./Ms. <u>Kala Santhosh</u>
2. Mark of Identification	:	(Mole/Scar/any other (specify location)):
3. Age/Date of Birth	:	<u>31.05.1979</u> Gender: <u>F/M</u>
4. Photo ID Checked	:	(Passport/Election Card/PAN Card/Driving Licence/Company ID)

PHYSICAL DETAILS:

a. Height <u>147</u> (cms)	b. Weight <u>60</u> (Kgs)	c. Girth of Abdomen <u>92</u> (cms)
d. Pulse Rate <u>70</u> (/Min)	e. Blood Pressure:	Systolic Diastolic
	1 st Reading	<u>120</u> <u>80</u>
	2 nd Reading	

FAMILY HISTORY:

Relation	Age if Living	Health Status	If deceased, age at the time and cause
Father		/NI	
Mother			
Brother(s)			
Sister(s)			

HABITS & ADDICTIONS: Does the examinee consume any of the following?

Tobacco in any form	Sedative	Alcohol
/	/	/

PERSONAL HISTORY

- | | |
|---|---|
| <p>a. Are you presently in good health and entirely free from any mental or Physical impairment or deformity. If No, please attach details. <u>Y/N</u></p> <p>b. Have you undergone/been advised any surgical procedure? <u>Varicose by Y/N</u></p> | <p>c. During the last 5 years have you been medically examined, received any advice or treatment or admitted to any hospital? <u>Y/N</u></p> <p>d. Have you lost or gained weight in past 12 months? <u>Y/N</u></p> |
|---|---|

Have you ever suffered from any of the following?

- | | |
|---|---|
| <ul style="list-style-type: none"> • Psychological Disorders or any kind of disorders of the Nervous System? <u>Y/N</u> • Any disorders of Respiratory system? <u>Y/N</u> • Any Cardiac or Circulatory Disorders? <u>Y/N</u> • Enlarged glands or any form of Cancer/Tumour? <u>Y/N</u> • Any Musculoskeletal disorder? <u>Y/N</u> | <ul style="list-style-type: none"> • Any disorder of Gastrointestinal System? <u>Y/N</u> • Unexplained recurrent or persistent fever, and/or weight loss <u>Y/N</u> • Have you been tested for HIV/HBsAg / HCV before? If yes attach reports <u>Y/N</u> • Are you presently taking medication of any kind? <u>Y/N</u> |
|---|---|

• Any disorders of Urinary System?

Y/N

• Any disorder of the Eyes, Ears, Nose, Throat or Mouth & Skin

Y/N

FOR FEMALE CANDIDATES ONLY

a. Is there any history of diseases of breast/genital organs?

Y/N

d. Do you have any history of miscarriage/abortion or MTP

Y/N

b. Is there any history of abnormal PAP Smear/Mammogram/USG of Pelvis or any other tests? (If yes attach reports)

Y/N

e. For Parous Women, were there any complication during pregnancy such as gestational diabetes, hypertension etc

Y/N

c. Do you suspect any disease of Uterus, Cervix or Ovaries?

Y/N

f. Are you now pregnant? If yes, how many months?

Y/N

CONFIDENTIAL COMMENTS FROM MEDICAL EXAMINER

➤ Was the examinee co-operative?

Y/N

➤ Is there anything about the examinee's health, lifestyle that might affect him/her in the near future with regard to his/her job?

Y/N

➤ Are there any points on which you suggest further information be obtained?

Y/N

➤ Based on your clinical impression, please provide your suggestions and recommendations below;

Adv. medical consult

➤ Do you think he/she is **MEDICALLY FIT** or **UNFIT** for employment.

MEDICAL EXAMINER'S DECLARATION

I hereby confirm that I have examined the above individual after verification of his/her identity and the findings stated above are true and correct to the best of my knowledge.

Name & Signature of the Medical Examiner :

Seal of Medical Examiner :

Dr. GEORGE THOMAS
MD, FCSI, FIAE
MEDICAL EXAMINER
Reg: 86614

Name & Seal of DDRC SRL Branch :

Date & Time :





MC-5897

PATIENT NAME : MRS. KALA SANTHOSH

REF. DOCTOR : DR. MEDIWHEEL

CODE/NAME & ADDRESS : CA00010147 - MEDIWHEEL ARCOFEMI HEALTHCARE LIMITED F701A, LADO SARAI, NEW DELHI,SOUTH DELHI, DELHI, SOUTH DELHI 110030 8800465156	ACCESSION NO : 4126XC007552	AGE/SEX : 44 Years Female
	PATIENT ID : KALAF0703794126	DRAWN :
	CLIENT PATIENT ID:	RECEIVED : 23/03/2024 13:11:02
	ABHA NO :	REPORTED : 25/03/2024 15:46:20

Test Report Status	Final	Results	Biological Reference Interval	Units
--------------------	-------	---------	-------------------------------	-------

MEDIWHEEL HEALTH CHECKUP ABOVE 40(F)2DECHO

DENTAL CHECK UP

DENTAL CHECK UP COMPLETED

DR.SMITHA PAULSON,MD
 (PATH),DPB
 (Reg No - TCMC:35960)
**LAB DIRECTOR & HEAD-
 HISTOPATHOLOGY & CYTOLOGY**

DR.NILA THERESA DAVIS,MBBS
 MD(PATH)
 (Reg No - TCMC:47450)
CONSULTANT PATHOLOGIST

DR.TEJAS PRASAD
VIDWANS ,MBBS MD(PATH)(Reg
No -MMC 2017/08/3919)
CONSULTANT PATHOLOGIST



View Details



View Report

PERFORMED AT :

DDRC AGILUS PATHLABS LIMITED
 DDRC agilus TOWER, G-131,PANAMPILLY NAGAR,
 ERNAKULAM, 682036
 KERALA, INDIA
 Tel : 93334 93334
 Email : customercare.ddrc@agilus.in



Patient Ref. No. 66600008311447

PATIENT NAME : MRS. KALA SANTHOSH

REF. DOCTOR : DR. MEDIWHEEL

CODE/NAME & ADDRESS : CA00010147 - MEDIWHEEL ARCOFEMI HEALTHCARE LIMITED F701A, LADO SARAI, NEW DELHI,SOUTH DELHI, DELHI, SOUTH DELHI 110030 8800465156	ACCESSION NO : 4126XC007552	AGE/SEX : 44 Years Female
	PATIENT ID : KALAF0703794126	DRAWN :
	CLIENT PATIENT ID:	RECEIVED : 23/03/2024 13:11:02
	ABHA NO :	REPORTED : 25/03/2024 15:46:20

Test Report Status	Final	Results	Biological Reference Interval	Units
--------------------	-------	---------	-------------------------------	-------

MEDIWHEEL HEALTH CHECKUP ABOVE 40(F)2DECHO

OPHTHAL

OPHTHAL COMPLETED

DR.SMITHA PAULSON,MD
 (PATH),DPB
 (Reg No - TCMC:35960)
**LAB DIRECTOR & HEAD-
 HISTOPATHOLOGY & CYTOLOGY**

DR.NILA THERESA DAVIS,MBBS
 MD(PATH)
 (Reg No - TCMC:47450)
CONSULTANT PATHOLOGIST

DR.TEJAS PRASAD
VIDWANS ,MBBS MD(PATH)(Reg
No -MMC 2017/08/3919)
CONSULTANT PATHOLOGIST



View Details



View Report

PERFORMED AT :

DDRC AGILUS PATHLABS LIMITED
 DDRC agilus TOWER, G-131,PANAMPILLY NAGAR,
 ERNAKULAM, 682036
 KERALA, INDIA
 Tel : 93334 93334
 Email : customercare.ddrc@agilus.in



Patient Ref. No. 66600008311447

PATIENT NAME : MRS. KALA SANTHOSH		REF. DOCTOR : DR. MEDIWHEEL	
CODE/NAME & ADDRESS : CA00010147 - MEDIWHEEL ARCOFEMI HEALTHCARE LIMITED F701A, LADO SARAI, NEW DELHI,SOUTH DELHI, DELHI, SOUTH DELHI 110030 8800465156		ACCESSION NO : 4126XC007552	AGE/SEX : 44 Years Female
		PATIENT ID : KALAF0703794126	DRAWN :
		CLIENT PATIENT ID:	RECEIVED : 23/03/2024 13:11:02
		ABHA NO :	REPORTED : 25/03/2024 15:46:20

Test Report Status	Final	Results	Units
--------------------	-------	---------	-------

MEDIWHEEL HEALTH CHECKUP ABOVE 40(F)2DECHO

ECG WITH REPORT

**REPORT
COMPLETED**

2D - ECHO WITH COLOR DOPPLER

**REPORT
COMPLETED**

USG ABDOMEN AND PELVIS

**REPORT
COMPLETED**

CHEST X-RAY WITH REPORT

**REPORT
COMPLETED**

MAMMOGRAPHY -BOTH

**REPORT
COMPLETED**

HAEMATOLOGY

MEDIWHEEL HEALTH CHECKUP ABOVE 40(F)2DECHO

GLYCOSYLATED HEMOGLOBIN(HBA1C), EDTA WHOLE BLOOD

HBA1C	5.4	Normal	: 4.0 -	%
		5.6%.		

**DR.SMITHA PAULSON,MD
(PATH),DPB
(Reg No - TCMC:35960)
LAB DIRECTOR & HEAD-
HISTOPATHOLOGY & CYTOLOGY**

**DR.NILA THERESA DAVIS,MBBS
MD(PATH)
(Reg No - TCMC:47450)
CONSULTANT PATHOLOGIST**

**DR.TEJAS PRASAD
VIDWANS ,MBBS MD(PATH)(Reg
No -MMC 2017/08/3919)
CONSULTANT PATHOLOGIST**



View Details




View Report

PERFORMED AT :

DDRC AGILUS PATHLABS LIMITED
DDRC agilus TOWER, G-131,PANAMPILLY NAGAR,
ERNAKULAM, 682036
KERALA, INDIA
Tel : 93334 93334
Email : customercare.ddrc@agilus.in



Patient Ref. No. 66600008311447



PATIENT NAME : MRS. KALA SANTHOSH

REF. DOCTOR : DR. MEDIWHEEL

CODE/NAME & ADDRESS : CA00010147 -
MEDIWHEEL ARCOFEMI HEALTHCARE LIMITED
F701A, LADO SARAI, NEW DELHI,SOUTH DELHI,
DELHI,
SOUTH DELHI 110030
8800465156

ACCESSION NO : **4126XC007552**
PATIENT ID : KALAF0703794126
CLIENT PATIENT ID:
ABHA NO :

AGE/SEX : 44 Years Female
DRAWN :
RECEIVED : 23/03/2024 13:11:02
REPORTED : 25/03/2024 15:46:20


Test Report Status	Final	Results	Units
--------------------	-------	---------	-------

Non-diabetic level : < 5.7%.
Diabetic : >6.5%

Glycemic control goal
More stringent goal : < 6.5 %.
General goal : < 7%.
Less stringent goal : < 8%.


Glycemic targets in CKD :-
If eGFR > 60 : < 7%.
If eGFR < 60 : 7 - 8.5%.


MEAN PLASMA GLUCOSE 108.3 < 116.0 mg/dL




BLOOD COUNTS,EDTA WHOLE BLOOD

HEMOGLOBIN	11.6 Low	12.0 - 15.0	g/dL
RED BLOOD CELL COUNT	3.94	3.80 - 4.80	mil/ μ L
WHITE BLOOD CELL COUNT	8.84	4.0 - 10.0	thou/ μ L
PLATELET COUNT	265	150 - 410	thou/ μ L


DR.HARI SHANKAR, MBBS MD
(Reg No - TCMC:62092)
HEAD - Biochemistry & Immunology


DR.SMITHA PAULSON,MD
(PATH),DPB
(Reg No - TCMC:35960)
LAB DIRECTOR & HEAD-HISTOPATHOLOGY & CYTOLOGY


DR.NISHA G,MBBS MD(PATH),
(Reg No - TCMC:45399)
CONSULTANT PATHOLOGIST



View Details



View Report

PERFORMED AT :

DDRC AGILUS PATHLABS LIMITED
DDRC agilus TOWER, G-131,PANAMPILLY NAGAR,
ERNAKULAM, 682036
KERALA, INDIA
Tel : 93334 93334
Email : customercare.ddrc@agilus.in



Patient Ref. No. 66600008311447



PATIENT NAME : MRS. KALA SANTHOSH

REF. DOCTOR : DR. MEDIWHEEL

CODE/NAME & ADDRESS : CA00010147 -
MEDIWHEEL ARCOFEMI HEALTHCARE LIMITED
F701A, LADO SARAI, NEW DELHI, SOUTH DELHI,
DELHI,
SOUTH DELHI 110030
8800465156

ACCESSION NO : **4126XC007552**
PATIENT ID : KALAF0703794126
CLIENT PATIENT ID:
ABHA NO :

AGE/SEX : 44 Years Female
DRAWN :
RECEIVED : 23/03/2024 13:11:02
REPORTED : 25/03/2024 15:46:20

Test Report Status	Final	Results	Units
--------------------	-------	---------	-------

RBC AND PLATELET INDICES

HEMATOCRIT	38.0	36.0 - 46.0	%
MEAN CORPUSCULAR VOL	96.4	83.0 - 101	fL
MEAN CORPUSCULAR HGB.	29.4	27.0 - 32.0	pg
MEAN CORPUSCULAR HEMOGLOBIN CONCENTRATION	30.5 Low	31.50 - 34.50	g/dL
RED CELL DISTRIBUTION WIDTH	12.7	11.60 - 14.0	%
MENTZER INDEX	24.5		
MEAN PLATELET VOLUME	9.9	6.80 - 10.90	fL

WBC DIFFERENTIAL COUNT

SEGMENTED NEUTROPHILS	65	40.0 - 80.0	%
LYMPHOCYTES	29	20.0 - 40.0	%
MONOCYTES	4	2.0 - 10.0	%
EOSINOPHILS	2	1.0 - 6.0	%
BASOPHILS	0	0.0 - 1.0	%
ABSOLUTE NEUTROPHIL COUNT	5.75	2.0 - 7.0	thou/ μ L
ABSOLUTE LYMPHOCYTE COUNT	2.56	1.0 - 3.0	thou/ μ L
ABSOLUTE MONOCYTE COUNT	0.35	0.20 - 1.0	thou/ μ L
ABSOLUTE EOSINOPHIL COUNT	0.18	0.02 - 0.50	thou/ μ L
ABSOLUTE BASOPHIL COUNT	0.00	0.00 - 0.10	thou/ μ L
NEUTROPHIL LYMPHOCYTE RATIO (NLR)	2.2		

ERYTHROCYTE SEDIMENTATION RATE (ESR), EDTA BLOOD


SEDIMENTATION RATE (ESR)	13	0 - 20	mm at 1 hr
--------------------------	----	--------	------------


METHOD : WESTERGREIN METHOD


MEDIWHEEL HEALTH CHECKUP ABOVE 40(F) 2DECHO

SUGAR URINE - POST PRANDIAL

SUGAR URINE - POST PRANDIAL	NOT DETECTED	NOT DETECTED
-----------------------------	--------------	--------------


DR. HARI SHANKAR, MBBS MD
(Reg No - TCMC:62092)
HEAD - Biochemistry & Immunology


DR. SMITHA PAULSON, MD
(PATH), DPB
(Reg No - TCMC:35960)
LAB DIRECTOR & HEAD- HISTOPATHOLOGY & CYTOLOGY


DR. NISHA G, MBBS MD(PATH),
(Reg No - TCMC:45399)
CONSULTANT PATHOLOGIST



View Details



PERFORMED AT :

DDRC AGILUS PATHLABS LIMITED
DDRC agilus TOWER, G-131, PANAMPILLY NAGAR,
ERNAKULAM, 682036
KERALA, INDIA
Tel : 93334 93334
Email : customercare.ddrc@agilus.in



PATIENT NAME : MRS. KALA SANTHOSH
REF. DOCTOR : DR. MEDIWHEEL
CODE/NAME & ADDRESS : CA00010147 -

 MEDIWHEEL ARCOFEMI HEALTHCARE LIMITED
 F701A, LADO SARAI, NEW DELHI, SOUTH DELHI,
 DELHI,
 SOUTH DELHI 110030
 8800465156

ACCESSION NO : 4126XC007552
PATIENT ID : KALAF0703794126
CLIENT PATIENT ID:
ABHA NO :
AGE/SEX : 44 Years Female
DRAWN :
RECEIVED : 23/03/2024 13:11:02
REPORTED : 25/03/2024 15:46:20
Test Report Status Final
Results
Units
SUGAR URINE - FASTING

SUGAR URINE - FASTING

NOT DETECTED

NOT DETECTED

IMMUNOHAEMATOLOGY
MEDIWHEEL HEALTH CHECKUP ABOVE 40(F)2DECHO
ABO GROUP & RH TYPE, EDTA WHOLE BLOOD

ABO GROUP

TYPE A

RH TYPE

POSITIVE

Interpretation(s)

ABO GROUP & RH TYPE, EDTA WHOLE BLOOD-Blood group is identified by antigens and antibodies present in the blood. Antigens are protein molecules found on the surface of red blood cells. Antibodies are found in plasma. To determine blood group, red cells are mixed with different antibody solutions to give A,B,O or AB.

Disclaimer: "Please note, as the results of previous ABO and Rh group (Blood Group) for pregnant women are not available, please check with the patient records for availability of the same."

The test is performed by both forward as well as reverse grouping methods.

BIO CHEMISTRY
MEDIWHEEL HEALTH CHECKUP ABOVE 40(F)2DECHO
BLOOD UREA NITROGEN (BUN), SERUM

BLOOD UREA NITROGEN

7

Adult(<60 yrs) : 6 to 20

mg/dL


DR.SMITHA PAULSON,MD
 (PATH),DPB
 (Reg No - TCMC:35960)
 LAB DIRECTOR & HEAD-
 HISTOPATHOLOGY & CYTOLOGY


DR.HARI SHANKAR, MBBS MD
 (Reg No - TCMC:62092)
 HEAD - Biochemistry &
 Immunology

Page 6 Of 14



View Details




View Report

PERFORMED AT :

 DDRC AGILUS PATHLABS LIMITED
 DDRC agilus TOWER, G-131,PANAMPILLY NAGAR,
 ERNAKULAM, 682036
 KERALA, INDIA
 Tel : 93334 93334
 Email : customercare.ddrc@agilus.in


Patient Ref. No. 66600008311447



PATIENT NAME : MRS. KALA SANTHOSH

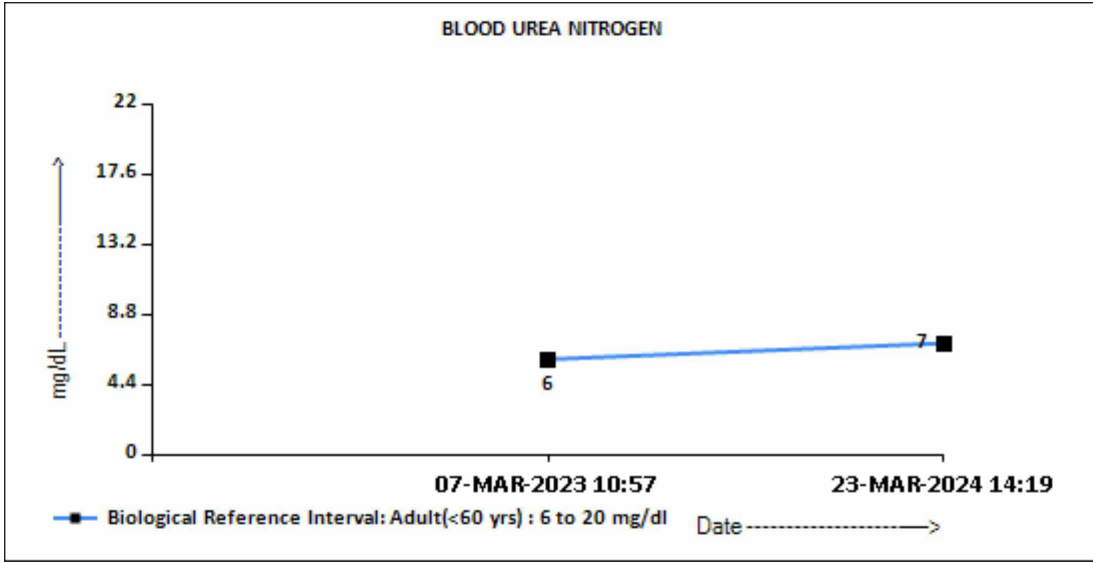
REF. DOCTOR : DR. MEDIWHEEL

CODE/NAME & ADDRESS : CA00010147 -
MEDIWHEEL ARCOFEMI HEALTHCARE LIMITED
F701A, LADO SARAI, NEW DELHI,SOUTH DELHI,
DELHI,
SOUTH DELHI 110030
8800465156

ACCESSION NO : 4126XC007552
PATIENT ID : KALAF0703794126
CLIENT PATIENT ID:
ABHA NO :

AGE/SEX : 44 Years Female
DRAWN :
RECEIVED : 23/03/2024 13:11:02
REPORTED : 25/03/2024 15:46:20

Test Report Status	Final	Results	Units
--------------------	-------	---------	-------



BUN/CREAT RATIO

BUN/CREAT RATIO 12.0

CREATININE, SERUM

CREATININE 0.58 18 - 60 yrs : 0.6 - 1.1 mg/dL

DR.SMITHA PAULSON,MD
(PATH),DPB
(Reg No - TCMC:35960)
**LAB DIRECTOR & HEAD-
HISTOPATHOLOGY & CYTOLOGY**

DR.HARI SHANKAR, MBBS MD
(Reg No - TCMC:62092)
**HEAD - Biochemistry &
Immunology**



View Details



View Report

PERFORMED AT :

DDRC AGILUS PATHLABS LIMITED
DDRC agilus TOWER, G-131,PANAMPILLY NAGAR,
ERNAKULAM, 682036
KERALA, INDIA
Tel : 93334 93334
Email : customercare.ddrc@agilus.in



Patient Ref. No. 66600008311447



PATIENT NAME : MRS. KALA SANTHOSH

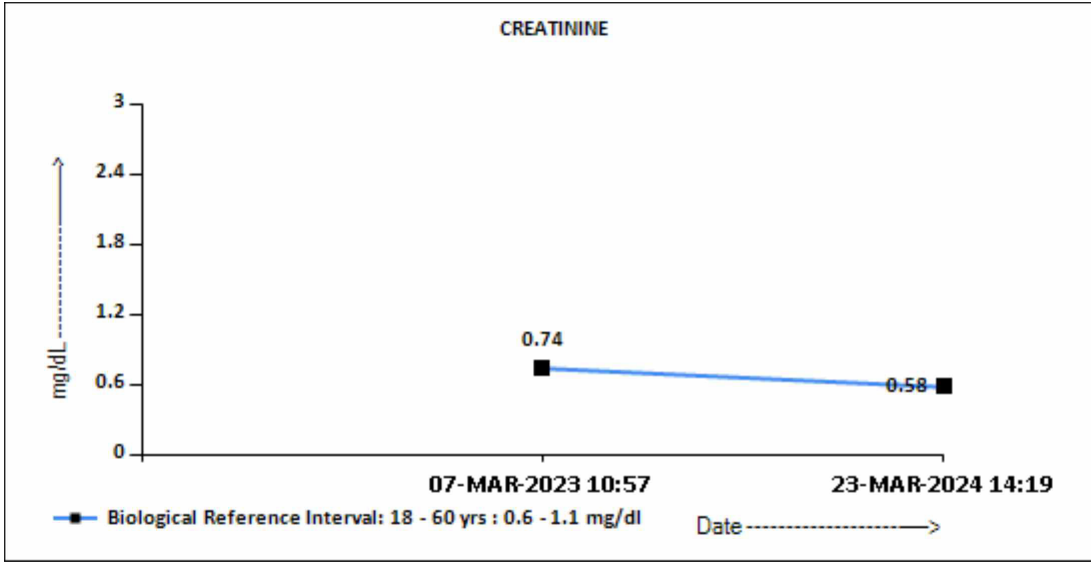
REF. DOCTOR : DR. MEDIWHEEL

CODE/NAME & ADDRESS : CA00010147 -
MEDIWHEEL ARCOFEMI HEALTHCARE LIMITED
F701A, LADO SARAI, NEW DELHI,SOUTH DELHI,
DELHI,
SOUTH DELHI 110030
8800465156

ACCESSION NO : 4126XC007552
PATIENT ID : KALAF0703794126
CLIENT PATIENT ID:
ABHA NO :

AGE/SEX : 44 Years Female
DRAWN :
RECEIVED : 23/03/2024 13:11:02
REPORTED : 25/03/2024 15:46:20

Test Report Status	Final	Results	Units
--------------------	-------	---------	-------



GLUCOSE, POST-PRANDIAL, PLASMA

GLUCOSE, POST-PRANDIAL, PLASMA 80

Diabetes Mellitus : > or = 200. mg/dL
Impaired Glucose tolerance/
Prediabetes : 140 - 199.
Hypoglycemia : < 55.

DR.SMITHA PAULSON,MD
(PATH),DPB
(Reg No - TCMC:35960)
**LAB DIRECTOR & HEAD-
HISTOPATHOLOGY & CYTOLOGY**

DR.HARI SHANKAR, MBBS MD
(Reg No - TCMC:62092)
**HEAD - Biochemistry &
Immunology**



View Details



View Report

PERFORMED AT :

DDRC AGILUS PATHLABS LIMITED
DDRC agilus TOWER, G-131,PANAMPILLY NAGAR,
ERNAKULAM, 682036
KERALA, INDIA
Tel : 93334 93334
Email : customercare.ddrc@agilus.in



Patient Ref. No. 66600008311447



PATIENT NAME : MRS. KALA SANTHOSH


REF. DOCTOR : DR. MEDIWHEEL

CODE/NAME & ADDRESS : CA00010147 -
MEDIWHEEL ARCOFEMI HEALTHCARE LIMITED
F701A, LADO SARAI, NEW DELHI,SOUTH DELHI,
DELHI,
SOUTH DELHI 110030
8800465156

ACCESSION NO : **4126XC007552**
PATIENT ID : KALAF0703794126
CLIENT PATIENT ID:
ABHA NO :

AGE/SEX : 44 Years Female
DRAWN :
RECEIVED : 23/03/2024 13:11:02
REPORTED : 25/03/2024 15:46:20

Test Report Status	Final	Results	Units
--------------------	-------	---------	-------



GLUCOSE FASTING,FLUORIDE PLASMA

FBS (FASTING BLOOD SUGAR) 90

Diabetes Mellitus : > or = 126. mg/dL
Impaired fasting Glucose/
Prediabetes : 101 - 125.
Hypoglycemia : < 55.

DR.SMITHA PAULSON,MD
(PATH),DPB
(Reg No - TCMC:35960)
**LAB DIRECTOR & HEAD-
HISTOPATHOLOGY & CYTOLOGY**

DR.HARI SHANKAR, MBBS MD
(Reg No - TCMC:62092)
**HEAD - Biochemistry &
Immunology**



View Details



View Report

PERFORMED AT :

DDRC AGILUS PATHLABS LIMITED
DDRC agilus TOWER, G-131,PANAMPILLY NAGAR,
ERNAKULAM, 682036
KERALA, INDIA
Tel : 93334 93334
Email : customercare.ddrc@agilus.in



Patient Ref. No. 66600008311447



PATIENT NAME : MRS. KALA SANTHOSH

REF. DOCTOR : DR. MEDIWHEEL

CODE/NAME & ADDRESS : CA00010147 -
MEDIWHEEL ARCOFEMI HEALTHCARE LIMITED
F701A, LADO SARAI, NEW DELHI,SOUTH DELHI,
DELHI,
SOUTH DELHI 110030
8800465156

ACCESSION NO : **4126XC007552**
PATIENT ID : KALAF0703794126
CLIENT PATIENT ID:
ABHA NO :

AGE/SEX : 44 Years Female
DRAWN :
RECEIVED : 23/03/2024 13:11:02
REPORTED : 25/03/2024 15:46:20

Test Report Status	Final	Results	Units
--------------------	-------	---------	-------

URIC ACID, SERUM

URIC ACID 2.6 Adults : 2.4-5.7 mg/dL

BIOCHEMISTRY - LIPID

MEDIWHEEL HEALTH CHECKUP ABOVE 40(F)2DECHO

LIPID PROFILE, SERUM

CHOLESTEROL	188	Desirable : < 200 Borderline : 200-239 High : >or= 240	mg/dL
TRIGLYCERIDES	90	Normal : < 150 High : 150-199 Hypertriglyceridemia : 200-499 Very High : > 499	mg/dL
HDL CHOLESTEROL	58	General range : 40-60	mg/dL
LDL CHOLESTEROL, DIRECT	128	Optimum : < 100 Above Optimum : 100-129 Borderline High : 130-159 High : 160-189 Very High : >or= 190	mg/dL
NON HDL CHOLESTEROL	130	Desirable : < 130 Above Desirable : 130 -159 Borderline High : 160 - 189 High : 190 - 219 Very high : > / = 220	mg/dL
VERY LOW DENSITY LIPOPROTEIN CHOL/HDL RATIO	18.0 3.2	</= 30.0 Low Risk : 3.3 - 4.4 Average Risk : 4.5 - 7.0 Moderate Risk : 7.1 - 11.0 High Risk : > 11.0	mg/dL
LDL/HDL RATIO	2.2	Desirable/Low Risk - 0.5-3 Borderline/Moderate Risk- 3.1-6 High Risk- >6.0	

DR.SMITHA PAULSON,MD
(PATH),DPB
(Reg No - TCMC:35960)
**LAB DIRECTOR & HEAD-
HISTOPATHOLOGY & CYTOLOGY**

DR.HARI SHANKAR, MBBS MD
(Reg No - TCMC:62092)
**HEAD - Biochemistry &
Immunology**



View Details




View Report

PERFORMED AT :

DDRC AGILUS PATHLABS LIMITED
DDRC agilus TOWER, G-131,PANAMPILLY NAGAR,
ERNAKULAM, 682036
KERALA, INDIA
Tel : 93334 93334
Email : customercare.ddrc@agilus.in



Patient Ref. No. 66600008311447


PATIENT NAME : MRS. KALA SANTHOSH
REF. DOCTOR : DR. MEDIWHEEL
CODE/NAME & ADDRESS : CA00010147 -

 MEDIWHEEL ARCOFEMI HEALTHCARE LIMITED
 F701A, LADO SARAI, NEW DELHI,SOUTH DELHI,
 DELHI,
 SOUTH DELHI 110030
 8800465156

ACCESSION NO : 4126XC007552
PATIENT ID : KALAF0703794126
CLIENT PATIENT ID:
ABHA NO :
AGE/SEX : 44 Years Female
DRAWN :
RECEIVED : 23/03/2024 13:11:02
REPORTED : 25/03/2024 15:46:20
Test Report Status Final
Results
Units
HISTOPATHOLOGY
MEDIWHEEL HEALTH CHECKUP ABOVE 40(F)2DECHO
CYTOLOGY - CS (PAP SMEAR)

CYTOLOGY - CS (PAP SMEAR)

Cytology No: CY/1086/2024

Nature of specimen : Pap smear

Gross specimen : 2 Smears stained

Microscopy : Satisfactory smear shows superficial and intermediate squamous cells, in a background of lactobacilli. No atypical cells seen.

IMPRESSION :Negative for intraepithelial lesion or malignancy.

SPECIALISED CHEMISTRY - HORMONE
MEDIWHEEL HEALTH CHECKUP ABOVE 40(F)2DECHO
THYROID PANEL, SERUM

T3	118.00	Non-Pregnant : 80-200	ng/dL
		Pregnant Trimester-wise	
		1st : 81-190	
		2nd : 100-260	
		3rd : 100-260	
T4	8.08	Adults : 4.5-12.1	µg/dl
TSH 3RD GENERATION	3.480	Non-Pregnant : 0.4-4.2	µIU/mL
		Pregnant Trimester-wise :	

DR.HARI SHANKAR, MBBS MD
 (Reg No - TCMC:62092)
 HEAD - Biochemistry &
 Immunology

DR.SMITHA PAULSON,MD
 (PATH),DPB
 (Reg No - TCMC:35960)
 LAB DIRECTOR & HEAD-
 HISTOPATHOLOGY & CYTOLOGY

DR.NISHA G,MBBS MD(PATH),
 (Reg No - TCMC:45399)
 CONSULTANT PATHOLOGIST


View Details




View Report

Page 12 Of 14

PERFORMED AT :

 DDRC AGILUS PATHLABS LIMITED
 DDRC agilus TOWER, G-131,PANAMPILLY NAGAR,
 ERNAKULAM, 682036
 KERALA, INDIA
 Tel : 93334 93334
 Email : customercare.ddrc@agilus.in


Patient Ref. No. 66600008311447



PATIENT NAME : MRS. KALA SANTHOSH

REF. DOCTOR : DR. MEDIWHEEL

CODE/NAME & ADDRESS : CA00010147 -
MEDIWHEEL ARCOFEMI HEALTHCARE LIMITED
F701A, LADO SARAI, NEW DELHI,SOUTH DELHI,
DELHI,
SOUTH DELHI 110030
8800465156

ACCESSION NO : **4126XC007552**
PATIENT ID : KALAF0703794126
CLIENT PATIENT ID:
ABHA NO :

AGE/SEX : 44 Years Female
DRAWN :
RECEIVED : 23/03/2024 13:11:02
REPORTED : 25/03/2024 15:46:20

Test Report Status	Final	Results	Units
--------------------	-------	---------	-------

1st : 0.1 - 2.5
2nd : 0.2 - 3
3rd : 0.3 - 3

CLINICAL PATH - URINALYSIS

MEDIWHEEL HEALTH CHECKUP ABOVE 40(F)2DECHO

PHYSICAL EXAMINATION, URINE

COLOR PALE YELLOW
APPEARANCE CLEAR

CHEMICAL EXAMINATION, URINE

PH	5.0	4.8 - 7.4
SPECIFIC GRAVITY	1.015	1.015 - 1.030
PROTEIN	NOT DETECTED	NOT DETECTED
GLUCOSE	NOT DETECTED	NOT DETECTED
KETONES	NOT DETECTED	NOT DETECTED
BLOOD	NOT DETECTED	NOT DETECTED
BILIRUBIN	NOT DETECTED	NOT DETECTED
UROBILINOGEN	NORMAL	NORMAL
NITRITE	NOT DETECTED	NOT DETECTED
LEUKOCYTE ESTERASE	NOT DETECTED	NOT DETECTED

MICROSCOPIC EXAMINATION, URINE

RED BLOOD CELLS	NOT DETECTED	NOT DETECTED	/HPF
WBC	2-3	0-5	/HPF
EPITHELIAL CELLS	10-15	0-5	/HPF
CASTS	NOT DETECTED		

DR.NISHA G,MBBS MD(PATH),
(Reg No - TCMC:45399)
CONSULTANT PATHOLOGIST

DR.HARI SHANKAR, MBBS MD
(Reg No - TCMC:62092)
HEAD - Biochemistry & Immunology

DR.SMITHA PAULSON,MD
(PATH),DPB
(Reg No - TCMC:35960)
LAB DIRECTOR & HEAD- HISTOPATHOLOGY & CYTOLOGY



View Details



View Report

PERFORMED AT :

DDRC AGILUS PATHLABS LIMITED
DDRC agilus TOWER, G-131,PANAMPILLY NAGAR,
ERNAKULAM, 682036
KERALA, INDIA
Tel : 93334 93334
Email : customercare.ddrc@agilus.in



Patient Ref. No. 66600008311447



PATIENT NAME : MRS. KALA SANTHOSH

REF. DOCTOR : DR. MEDIWHEEL

CODE/NAME & ADDRESS : CA00010147 -
MEDIWHEEL ARCOFEMI HEALTHCARE LIMITED
F701A, LADO SARAI, NEW DELHI,SOUTH DELHI,
DELHI,
SOUTH DELHI 110030
8800465156

ACCESSION NO : **4126XC007552**
PATIENT ID : KALAF0703794126
CLIENT PATIENT ID:
ABHA NO :

AGE/SEX : 44 Years Female
DRAWN :
RECEIVED : 23/03/2024 13:11:02
REPORTED : 25/03/2024 15:46:20

Test Report Status	Final	Results	Units
--------------------	-------	---------	-------

CRYSTALS		NOT DETECTED	
BACTERIA		NOT DETECTED	NOT DETECTED
YEAST		DETECTED	NOT DETECTED

CLINICAL PATH - STOOL ANALYSIS

MEDIWHEEL HEALTH CHECKUP ABOVE 40(F)2DECHO

PHYSICAL EXAMINATION,STOOL

COLOUR	BROWN	
CONSISTENCY	WELL FORMED	
MUCUS	NOT DETECTED	NOT DETECTED
VISIBLE BLOOD	ABSENT	ABSENT
ADULT PARASITE	NOT DETECTED	

MICROSCOPIC EXAMINATION,STOOL

PUS CELLS	1-2		/hpf
RED BLOOD CELLS	NOT DETECTED	NOT DETECTED	/HPF
CYSTS	NOT DETECTED	NOT DETECTED	
OVA	NOT DETECTED		
LARVAE	NOT DETECTED	NOT DETECTED	
TROPHOZOITES	NOT DETECTED	NOT DETECTED	
FAT	ABSENT		
VEGETABLE CELLS	ABSENT		
CHARCOT LEYDEN CRYSTALS	ABSENT		

DR.NISHA G,MBBS MD(PATH),
(Reg No - TCMC:45399)
CONSULTANT PATHOLOGIST

Dr.ASWATHY VARGHESE,
MBBS, MD(MICROBIOLOGY)
(Reg No - TCMC:50839)
CONSULTANT MICROBIOLOGIST

ANCY ABRAHAM,
MSC MICROBIOLOGY
Senior Microbiologist



View Details



View Report

PERFORMED AT :

DDRC AGILUS PATHLABS LIMITED
DDRC agilus TOWER, G-131,PANAMPILLY NAGAR,
ERNAKULAM, 682036
KERALA, INDIA
Tel : 93334 93334
Email : customercare.ddrc@agilus.in



Patient Ref. No. 66600008311447



ഭാരതീയ സവിശേഷ തിരിച്ചറിയൽ അതോറിറ്റി

ഭാരത സർക്കാർ
Unique Identification Authority of India
Government of India

പോസ്റ്റ്കോഡ് നമ്പർ / Enrollment No. : 2007/33478/17753

27/12/2012

To
KALA SANTHOSH
കല സന്തോഷ്
LEKSHMI BHAVAN
CHEKKIDIKKADU P O
Thakazhy
Chekkidikkadu, Alappuzha
Kerala - 689573
4772211319



KL032967603DF
3296760



നിങ്ങളുടെ ആധാർ നമ്പർ / Your Aadhaar No. :

7315 5569 9386

ആധാർ - സാധാരണക്കാരന്റെ അവകാശം



ഭാരത സർക്കാർ
GOVERNMENT OF INDIA



കല സന്തോഷ്
KALA SANTHOSH
ഭർത്താവ് : സന്തോഷ് കുമാർ എസ്
Husband : SANTHOSH KUMAR S

ജനന വർഷം / Year of Birth: 1979
ലിംഗം / Female



7315 5569 9386

ആധാർ - സാധാരണക്കാരന്റെ അവകാശം



Name : Kala Santhosh

44F

Date: 23/03/2024

Ref : Mediwheel

Accession No:4126XC007552

ECHOCARDIOGRAPHY REPORT

Cardiac ultrasound examination was done using GE Voluson S8 machine with 5P1 transducer. Imaging and Doppler studies including Colour Flow Mapping (CFM) were performed (images and measurements attached) Relevant observations are summarized as follows:

- Normal LV size and contractility (EF: 74%)
- No regional wall motion abnormalities
- Normal valves
- No abnormal flow patterns on CFM
- No intracardiac clots
- No pericardial effusion

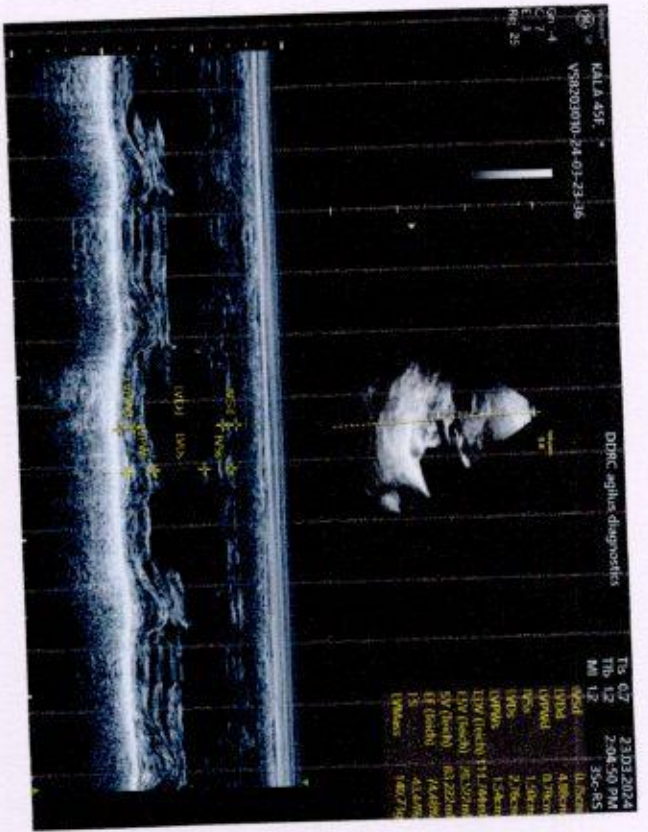


Dr. George Thomas
Cardiologist

Fellow, Indian Academy of Echocardiography

Ultrasound reports are not 100% specific and can vary significantly depending on the clinical conditions. The report has to be correlated clinically and is not for medico-legal purposes.

Thanks for the referral. Your feedback is appreciated.



DPOIC: apical diagnostics

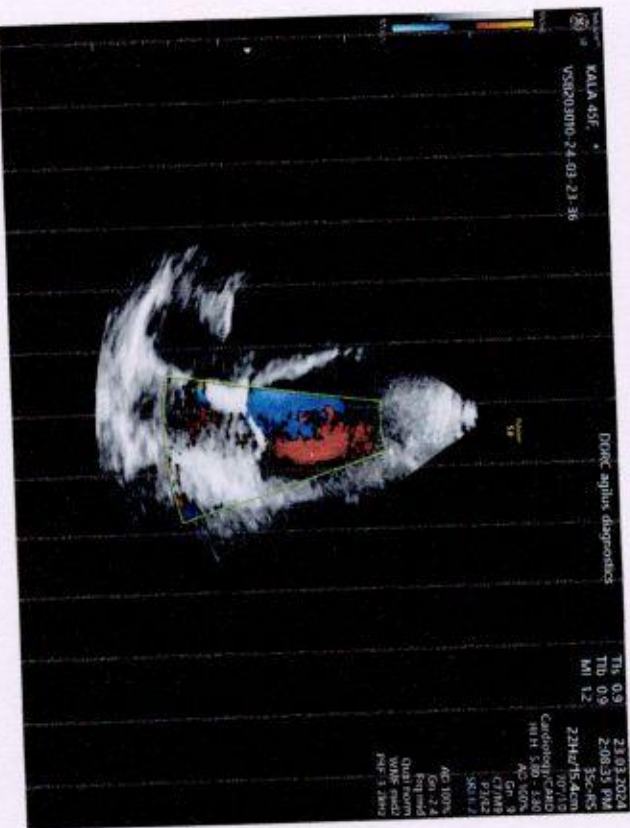
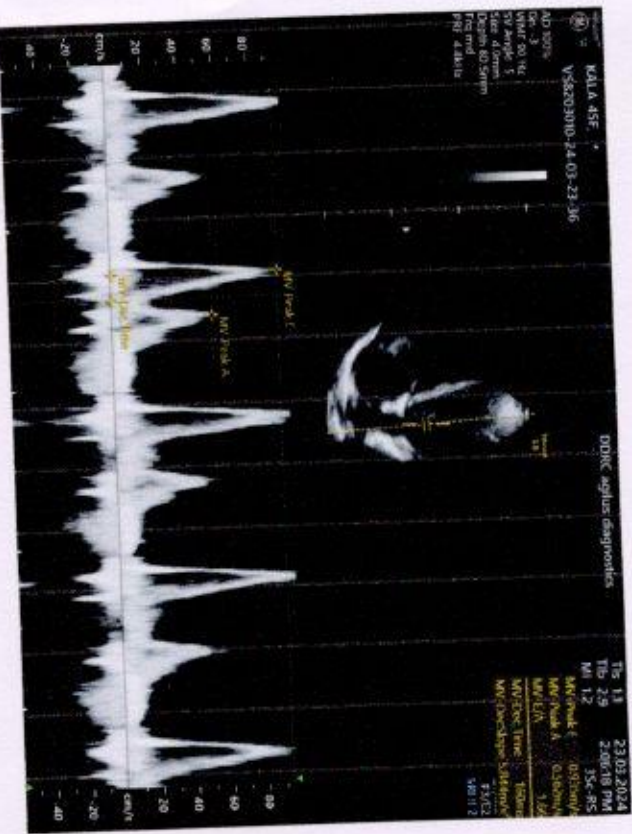
Pac ID: VS8203010-24-03-23-36

Hydroson	Volume	mL	mL	mL	mL	mL	Flow
Left Ventricle	0.75	cm	0.75				cm³
RVSD	4.88	cm	4.88				cm³
LVWd	0.79	cm	0.79				cm³
LVWd	1.50	cm	1.50				cm³
RVs	2.76	cm	2.76				cm³
LVWs	1.54	cm	1.54				cm³
LVWVs	111.704	ml	111.704				ml
EDV (Frach)	28.522	ml	28.522				ml
EDV (Frach)	83.222	ml	83.222				ml
SV (Frach)	76.408	%	76.408				%
EF (Frach)	43.84	%	43.84				%
Fract. Short	160.73	g	160.73				g
LV Mass							

23.03.2024
2:08:53 PM
35-85

Cardiologic Card
RTH: 580
Age: 220
Cv: 3
CvMB: P102
Sv: 1.2

ap: 100%
Gr: 2.4
DPOIC: 2.4
DPOIC: 2.4
DPOIC: 2.4



This is to certify that I have examined

MR / MS Kula Santhoshaged 45 and

his / her oral findings are as follows

D - Decay

M - Missing

F - Filling

8	7	6	5	4	3	2	1	1	2	3	4	5	6	7	8
8	7	6	5	4	3	2	1	1	2	3	4	5	6	7	8

Oral hygiene status : Good / Fair / Poor ✓

Calculus / Stains : ✓

Any other findings :

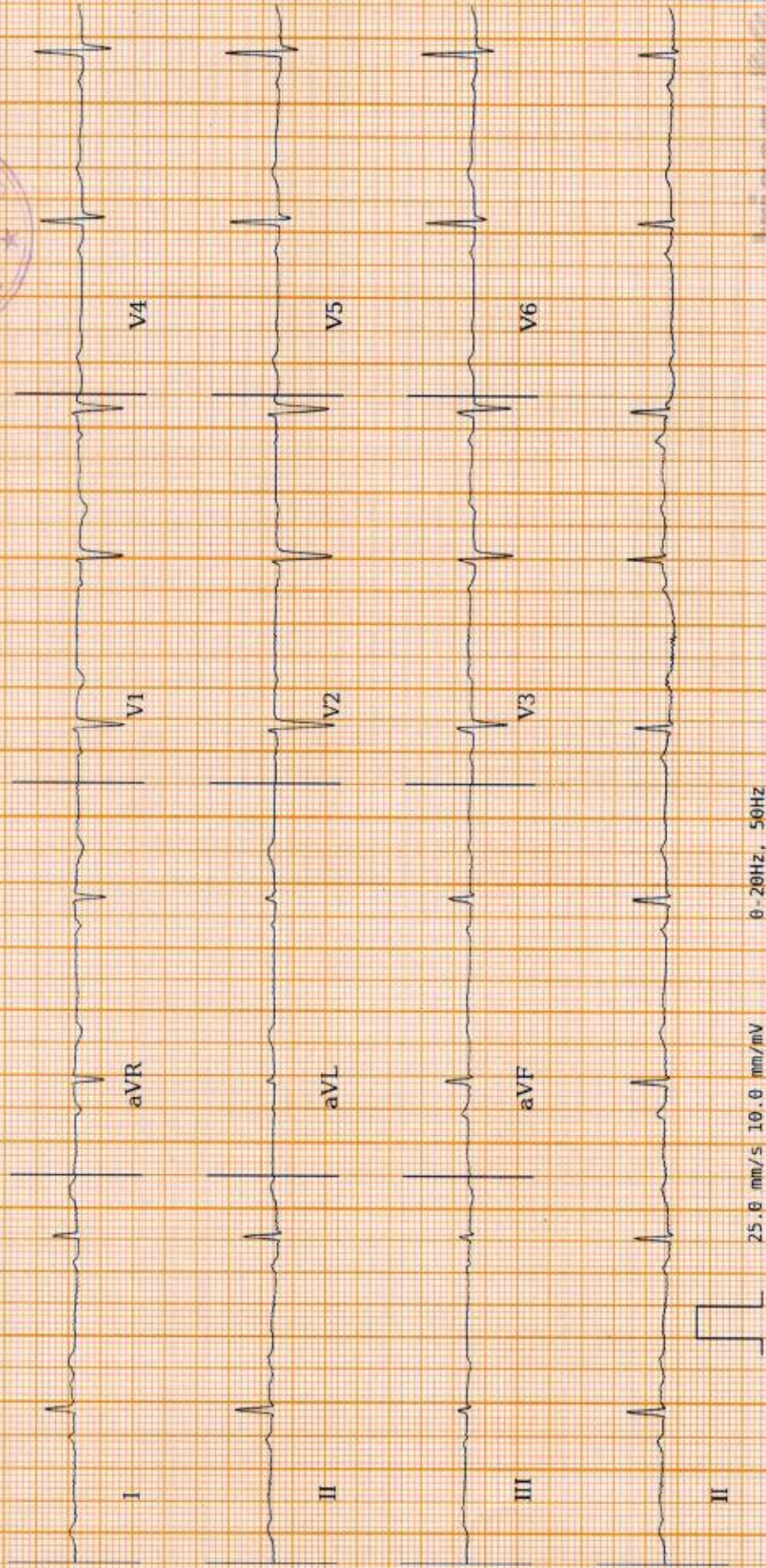
Date : 23/3/24



Dr. K C Jose
Dr. K C Jose

Age / Gender: 45/Female
Patient ID: 7552
Patient Name: Kala Santhosh

Date and Time: 23rd Mar 24 3:10 PM



Tricog

AR: 57bpm VR: 57bpm QRSD: 86ms QT: 398ms QTcB: 387.92ms PRI: 198ms P-R-T: 35° 42° 17°

Bradycardia, Sinus Arrhythmia Seen. Please correlate clinically.

REPORTED BY

Muhammad K

Dr. Nisar Muhammad K
MBBS, MEM

KMC 122445

NAME : MRS KALA SANTHOSH	STUDY DATE: 23.03.2024
AGE / SEX : 44 YRS / F	REPORTING DATE :23.03.2024
REFERRED BY: MEDIWHEEL	ACC NO: 4126XC007551

X - RAY - CHEST PA VIEW

- Both the lung fields are clear.
- B/L hila and mediastinal shadows are normal.
- Cardiac silhouette appears normal.
- Cardio – thoracic ratio is normal.
- Bilateral CP angles and domes of diaphragm appear normal.

IMPRESSION : Normal study.**Kindly correlate clinically**

Dr. Hrishikesh C.
DR. HRISHIKESH C, MBBS, DMRD
Consultant Radiologist.

Date... 23/3/24

OPHTHALMOLOGY REPORT

This is to certify that I have examined

Mr / Ms : Kala Santhosh Aged 44 and his / her

visual standards is as follows :

Visual Acuity:

For far vision

R: 6/9

L: 6/9

EPG { 6/6
6/6

For near vision

R: N8

L: N8

EPG { N6
N6

Color Vision : Normal


CIYA MARY P ROCKY
 PANAMPILLY
 NAGAR
(OPTOMETRIST)



NAME	MRS KALA SANTHOSH	AGE	44 YRS
SEX	FEMALE	DATE	March 23, 2024
REFERRAL	MEDIWHEEL	ACC NO	4126WC007552

MAMMOGRAPHY**Technique:** Bilateral MLO and CC views**Clinical details:** Screening mammography.**Findings:**

- Both breasts show ACR type - B composition.
- Breast parenchymal architecture is preserved.
- No evidence of micro/macro calcifications seen in breast.
- The skin, nipple-areola complex and retro-areolar zone are normal.
- The retro-mammary clear zone and underlying pectoralis muscle appear normal

ULTRASOUND SCREENING:**RIGHT BREAST**

- Normal stromal echogenicity.
- No focal lesions seen in the present study.
- Nipple & areola normal.
- No evidence of axillary lymphadenopathy

LEFT BREAST

- Normal stromal echogenicity.
- No focal lesions seen in the present study.
- Nipple & areola normal.
- No evidence of axillary lymphadenopathy

IMPRESSION:

✦ **No significant abnormality of both breasts - BIRADS I.**

Dr. Hrishikesh C
Dr. HRISHIKESH C MBBS DMRD
Consultant Radiologist

ACR BIRADS Category


0	More information is needed to give a final mammogram report
I	Your mammogram is normal.
II	Your mammogram shows only minor abnormalities that are not suspicious for cancer. No additional testing is needed.
III	Your mammogram shows minor abnormalities that are probably benign. The radiologist may recommend follow-up testing to make sure the suspicious area has not changed.
IV	Your mammogram shows a suspicious change, and a biopsy should probably be performed.
V	Your mammogram shows a worrisome change. A biopsy is strongly recommended.
VI	Known biopsy - proven malignancy; Surgical excision when clinically appropriate.

For Emergency Call: 9496005127. Thanks for referral. Your feedback will be appreciated.
 (Please bring relevant investigation reports during all visits)

NAME	MRS KALA SANTHOSH	AGE	44 YRS
SEX	FEMALE	DATE	March 23, 2024
REFERRAL	MEDIWHEEL	ACC NO	4126WC007552

USG ABDOMEN AND PELVIS

LIVER	Measures ~ 12.3 cm, shows mild increased echoes. Smooth margins and no obvious focal lesion within. No IHBR dilatation. Portal vein normal in caliber.
GB	No calculus within gall bladder. Normal GB wall caliber.
SPLEEN	Measures ~ 8.8 cm, normal to visualized extent. Splenic vein normal.
PANCREAS	Normal to visualized extent. PD is not dilated.
KIDNEYS	RK: 9.9 x 3.9 cm, appears normal in size and echotexture. LK: 9.3 x 4.6 cm, appears normal in size and echotexture. No focal lesion / calculus within. Maintained corticomedullary differentiation and normal parenchymal thickness. No hydronephrosis.
BLADDER	Normal wall caliber, no internal echoes/calculus within.
UTERUS	Normal in size and echopattern. Anterior wall fibroid of size ~ 17 x 12 mm noted. ET - 10 mm.
OVARIES	Normal.
FLUID	Nil to visualized extent.
BOWEL	Gross gaseous abdomen.
IMPRESSION	<ul style="list-style-type: none"> ⬇ Grade I Fatty liver. ⬇ Uterine fibroid. Kindly correlate clinically.


Dr. HRISHIKESH C MBBS DMRD
 Consultant Radiologist

Thank you for referral. Your feedback will be appreciated.

