

# YASHFEEN CARDIAC HOSPITAL™

MANAGED BY :- YASHFEEN FOUNDATION

VIRAVAL, NAVSARI. 396 445. PHONE : (H) (02637) 235725

Website : www.yashfeenhospital.in E-mail : info@yashfeenhospital.in

(Stationary For Report Only)



(Regd. No. E / 1390 / Navsari)

## 2D ECHO CARDIOGRAPHY COLOUR DOPPLER REPORT

Patient Name & No : SEJALKUMARI VANMALIBHAI PATEL CH24003! Age/Sex UHID : : 304  
Doctor : Mohil Nagad 31/ F No : : 389  
Referred By : Date : : 27/04/2024

### M-Mode findings

LVIDd : 42mm  
LVIDs : 32mm  
IVSd : 10mm  
PWd : 09mm  
EF : 60%  
Aorta : 20mm  
LA : 28mm

### 2D Imaging

Aortic Valve : Trileaflet, Normal  
Mitral Valve : Thin, Pliable, Normal Mobility, Normal function  
Tricuspid Valve : Normal  
Pulmonary Valve : Normal

=> : All cardiac chambers are normal sized.  
=> : All cardiac valves are normal.  
=> : No regional wall motion abnormality.  
=> : Normal LV systolic function.  
=> : Normal LV diastolic function.  
=> : IAS/IVS intact.  
=> : No obvious clots/ vegetations/ or effusion.  
=> : IVC Normal size.

### Doppler Findings

=> : No MS/MR, No TS/TR, No AS/AR & No PS/PR  
Mitral inflow Pattern : E > A  
Tissue Doppler Findings : E' > A'

Impression : Normal LVEF:60%, No RWMA.



Report Prepared By

-  
-  
-

Designed By : Sarita Infotech Pvt. Ltd., Navsari

Report Checked By  
**DR. MOHIL NAGAD**  
M.D. Medicine (D), Dip. Cardiology,  
Senior Consultant - Interventional Cardiology  
Reg. No. G - 22893  
YASHFEEN HOSPITAL, NAVSARI

# YASHFEEN IMAGING & RADIOLOGY DEPARTMENT

MANAGED BY :- YASHFEEN FOUNDATION

VIRAVAL, NAVSARI. 396 445. PHONE : (H) (02637) 235725

Website : [www.yashfeenhospital.in](http://www.yashfeenhospital.in) E-mail : [info@yashfeenhospital.in](mailto:info@yashfeenhospital.in)

|                 |                      |            |            |
|-----------------|----------------------|------------|------------|
| Patient's Name: | SEJALKUMARI V. PATEL | Age & Sex: | 31Yrs/F    |
| Ref. by Dr.     | SELF                 | Date:      | 27-04-2024 |

## X RAY CHEST (PA VIEW)

Both lung fields appear normal.

Both hila appear normal.

Both CP angles appear clear.

Cardiac size appears within normal limit.

Both domes of diaphragm appear normal.

Bony thoracic cage appears normal.

### IMPRESSION:

- Normal X-ray chest (PA view).

  
Dr. DHARMESH DESAI  
(M.D. Radiology)  
Reg.No. G-45284  
YASHFEEN GROUP OF HOSPITAL



Please contact immediately for any typographical error.

This is only professional opinion, not a final diagnosis. Kindly correlate clinically. Not valid for medicolegal purpose.





# YASHFEEN CARDIAC HOSPITAL™

At. & Po. Viraval, Navsari. 396 445. Phone (H) (02637) 235725

Website : www.yashfeenhospital.in E-mail : info@yashfeenhospital.in

(For Laboratory Reports Only)



Patient Name : SEJALKUMARI VANMALIBHAI PATEL      Age : 31 Years      Sex : F  
 Ref By Dr. : -      Area : Vyara      Date : 27/04/2024  
 Sample Time : 27/04/2024 08:47      No : 13      Time : 12:31PM

## HAEMOGRAM

| Test                      | Findings    | UOM                 | Normal Range                           |
|---------------------------|-------------|---------------------|--|
| HAEMOGLOBIN               | 13.8        | gm/dl               | M-13.5-17.0 gm/dl<br>F-11.5-15.5 gm/dl |
| <b>HAEMOGRAM</b>          |             |                     |  |
| RED BLOOD CELL            | 5.14        | 10 <sup>6</sup> /μL | 3.76-5.70                              |
| TOTAL LEUCOCYTE COUNT     | 5500        | cells/cumm          | 4,000-11,000cells/cumm                 |
| <b>Differential Count</b> |             |                     |  |
| Neutrophil                | 49          | %                   | 40-75 %                                |
| Lymphocytes               | <b>45</b>   | %                   | 20-40 %                                |
| Eosinophil                | 1           | %                   | 01-06 %                                |
| Monocytes                 | 5           | %                   | 02-10 %                                |
| Basophils                 | 0           | %                   | 00-00 %                                |
| PLATELET COUNT            | 340000      | lacs/cumm           | 1.5-5.5 Lacs/cumm                      |
| <b>RBC INDICES</b>        |             |                     |  |
| P.C.V.                    | 40.1        | %                   | Male-40-56%,<br>Female-37-47%          |
| M.C.V.                    | 78.0        | cu/microns          | 76.0-94.0                              |
| M.C.H.                    | <b>26.8</b> | pg                  | 27.0-30.0                              |
| M.C.H.C.                  | 34.4        | -                   | 30.0-35.0                              |
| BLOOD GROUP               | " B "       | -                   | -                                      |
| RH FACTOR                 | POSITIVE    | -                   | -                                      |
| E.S.R.(1 hour)            | 8           | mm/hr.              | Male-5-10 mm/hr,<br>Female-5-20 mm/hr  |

*P. Chaudhari*  
 Dr. PIYUSH B. CHAUDHARI  
 M.D. Medicine

Reg. No. G-21518

Remarks

Designed By: Sarita Infotech Pvt. Ltd., Navsari

Yashfeen Cardiac Hospital

*Signature*  
 Signature  
 Technician

Thanks for Reference



# YASHFEEN CARDIAC HOSPITAL™

At. & Po. Viraval, Navsari. 396 445. Phone (H) (02637) 235725  
Website : www.yashfeenhospital.in E-mail : info@yashfeenhospital.in  
(For Laboratory Reports Only)



Patient Name : SEJALKUMARI VANMALIBHAI PATEL Age : 31 Years Sex : F  
Ref By Dr. : - Area : Vyara Date : 27/04/2024  
Sample Time : 27/04/2024 09:09 No : 13 Time : 12:31PM

## HAEMOGLOBIN A1 C ESTIMATION

| Test                              | Findings | UOM   | Normal Range  |
|-----------------------------------|----------|-------|---|
| Hb A1C                            | 5.2      | %     | >8 :Action Suggested,<br>7-8 :Good Control,<br><7 :Goal,<br>6-7 :Near Normal<br>Glycemia,<br><6 :Non-diabetic Level |
| <b>Technique</b><br>METHOD - HPLC |          | -     |   |
| Mean Blood Glucose                | 102.3    | mg/dL |   |



*P. Chaudhari*  
Dr. PIYUSH B. CHAUDHARI  
M.D. Medicine  
Reg. No. G-21518

### Remarks

Designed By : Sarita Infotech Pvt. Ltd., Navsari

Yashfeen Cardiac Hospital

*S. Harbajee*  
Signature  
Technician

*Thanks for Reference*





# YASHFEEN CARDIAC HOSPITAL™

At. & Po. Viraval, Navsari. 396 445. Phone (H) (02637) 235725  
Website : www.yashfeenhospital.in E-mail : info@yashfeenhospital.in  
(For Laboratory Reports Only)



Patient Name : SEJALKUMARI VANMALIBHAI PATEL  
Ref By Dr. : -  
Sample Time : 27/04/2024 09:09 No : 13

Age : 31 Years Sex : F  
Area : Vyara Date : 27/04/2024  
Time : 12:31PM

## BIOCHEMICAL TEST REPORT

| Test                | Findings   | UOM   | Normal Range                                |
|---------------------|------------|-------|---|
| S.CREATININE        | <u>0.5</u> | mg/dL | Male-0.9-1.4 mg/dL,<br>Female-0.8-1.2 mg/dL |
| S.URIC ACID         | 4.0        | mg/dL | Male:3.5-7.2 mg/dL,<br>Female:2.6-6.0 mg/dL |
| BLOOD UREA NITROGEN | 6.4        | mg/dL | 4.7-23.0 mg/dL                              |



*P. Chaudhary*  
Dr. PIYUSH B. CHAUDHARY  
M.D. Medicine  
Reg. No. G-21513

Remarks

Designed By : Sarita Infotech Pvt. Ltd., Navsari

Yashfeen Cardiac Hospital

*Dr. Harbejee*

Signature

Technician

*Thanks for Reference*





# YASHFEEN CARDIAC HOSPITAL™

At. & Po. Viraval, Navsari. 396 445. Phone (H) (02637) 235725

Website : [www.yashfeenhospital.in](http://www.yashfeenhospital.in) E-mail : [info@yashfeenhospital.in](mailto:info@yashfeenhospital.in)  
(For Laboratory Reports Only)



Patient Name : SEJALKUMARI VANMALIBHAI PATEL  
Ref By Dr. : -  
Sample Time : 27/04/2024 09:09 No : 13

Age : 31 Years Sex : F  
Area : Vyara Date : 27/04/2024  
Time : 12:31PM

## LIPID PROFILE TEST REPORT

| Test             | Findings | UOM   | Normal Range  |
|------------------|----------|-------|---|
| S.CHOLESTEROL    | 133.3    | mg/dL | <200:Desirable,<br>200-239:Borderline High,<br>>=240:High   |
| HDL CHOLESTEROL  | 54.1     | mg/dL | <40:Low(High Risk),<br>>=60:High(Low Risk)  |
| LDL CHOLESTEROL  | 91.7     | mg/dL | <100.0: Optimal,<br>100.0-129.0: Nearoptimal/<br>Aboveoptimal,<br>130.0-159.0:Borderline<br>High,<br>160.0-189.0:High,<br>>=190.0:Very High |
| VLDL CHOLESTEROL | 9.5      | mg/dL | Upto 40.0 mg/dL   |
| S.TRIGLYCERIDES  | 47.7     | mg/dL | <150.0:Normal,<br>150.0-199.0:Borderline<br>high,<br>200.0-499.0:High,<br>>=500.0:Very High   |
| CHOL/ HDL RATIO  | 2.5      | mg/dL | LESS THAN 5.0   |
| LDL/ HDL RATIO   | 1.7      | mg/dL | LESS THAN 5.0   |



*P. Chauhan*  
Dr. PIYUSH B. CHAUDHARI  
M.D. Medicine  
Reg. No. G-2151J

### Remarks

Designed By : Sarita Infotech Pvt. Ltd., Navsari

Yashfeen Cardiac Hospital

*Dr. Harjeet*  
Signature  
Technician

*Thanks for Reference*





# YASHFEEN CARDIAC HOSPITAL™

At. & Po. Viraval, Navsari. 396 445. Phone (H) (02637) 235725  
Website : www.yashfeenhospital.in E-mail : info@yashfeenhospital.in  
(For Laboratory Reports Only)



Patient Name : SEJALKUMARI VANMALIBHAI PATEL  
Ref By Dr. : -  
Sample Time : 27/04/2024 09:09 No : 13

Age : 31 Years Sex : F  
Area : Vyara Date : 27/04/2024  
Time : 12:31PM

## LIVER FUNCTION TEST REPORT

| Test                   | Findings   | UOM   | Normal Range                                    |
|------------------------|------------|-------|---|
| TOTAL BILIRUBIN        | 0.4        | mg/dL | 0-1.0 mg/dL                                     |
| DIRECT BILIRUBIN       | 0.2        | mg/dL | 0-0.8 mg/dL                                     |
| INDIRECT BILIRUBIN     | 0.2        | mg/dL | 0-0.2 mg/dL                                     |
| SGPT                   | 14.6       | U/L   | Below 40.0 U/L                                  |
| S.ALKALINE PHOSPHATASE | 82.4       | U/L   | Child-170.0-515.0 U/L,<br>Adults-37.0-147.0 U/L |
| TOTAL PROTEIN          | 7.1        | g/dl  | 6.0-8.0 g/dl                                    |
| ALBUMIN                | 4.7        | g/dl  | 3.0-5.0 g/dl                                    |
| GLOBULIN               | <b>2.4</b> | g/dl  | 3.0-3.5 g/dl                                    |
| A/G                    | 2.0        | g/dl  |   |
| SGOT                   | 16.3       | U/L   | Below 40.0 U/L                                  |



*P. Ueda*  
Dr. PIYUSH B. CHAUDHARI  
M.D. Medicine  
Reg. No. G-21513

### Remarks

Designed By : Sarita Infotech Pvt. Ltd., Navsari

Yashfeen Cardiac Hospital

*Dr. Harjeet*  
Signature  
Technician

*Thanks for Reference*





# YASHFEEN CARDIAC HOSPITAL™

At. & Po. Viraval, Navsari. 396 445. Phone (H) (02637) 235725

Website : [www.yashfeenhospital.in](http://www.yashfeenhospital.in) E-mail : [info@yashfeenhospital.in](mailto:info@yashfeenhospital.in)  
(For Laboratory Reports Only)



Patient Name : SEJALKUMARI VANMALIBHAI PATEL Age : 31 Years Sex : F  
Ref By Dr. : - Area : Vyara Date : 27/04/2024  
Sample Time : 27/04/2024 09:09 No : 13 Time : 12:31PM

## THYROID FUNCTION TEST REPORT

| Test                 | Findings | UOM    | Normal Range  |
|----------------------|----------|--------|---|
| T3 (TRIODOTHYRONINE) | 1.17     | ng/ml  | Newborns:0.73-2.88,<br>6 Days-3<br>Months:0.80-2.75,<br>4-12Months:0.86-2.65,<br>1-6 Years:0.92-2.48,<br>7-11 Years:0.93-2.31,<br>12-20Years:0.91-2.18,<br>Adults:0.80-2.00   |
| T4(THYROXINE)        | 6.64     | µg/dl  | Newborns:5.04-18.5,<br>6 Days-3<br>Months:5.41-17.0,<br>4-12 Months:5.67-16.0,<br>1-6 Years:5.95-14.7,<br>7-11 Years:5.99-13.8,<br>12-20 Years:5.91-13.2,<br>Adults:5.10-14.1 |
| TSH                  | 1.62     | µIU/ml | Newborns:0.70-15.2,<br>6 Days-3<br>Months:0.72-11.0,<br>4-12 Months:0.73-8.35,<br>1-6 Years:0.70-5.97,<br>7-11 Years:0.60-4.84,<br>12-20 Years:0.51-4.30,<br>Adults:0.27-4.20 |

### TECHNIQUE

ELECTROCHEMILUMINESCEN  
CE



*P. Chaudhari*  
**Dr. PIYUSH B. CHAUDHARI**  
M.D. Medicine  
Reg. No. G-21513

Remarks

Designed By : Sarita Infotech Pvt. Ltd., Navsari

Yashfeen Cardiac Hospital

*Signature*  
**Signature  
Technician**

*Thanks for Reference*





# YASHFEEN CARDIAC HOSPITAL™

At. & Po. Viraval, Navsari. 396 445. Phone (H) (02637) 235725  
Website : www.yashfeenhospital.in E-mail : info@yashfeenhospital.in  
(For Laboratory Reports Only)



Patient Name : SEJALKUMARI VANMALIBHAI PATEL  
Ref By Dr. : -  
Sample Time : 27/04/2024 09:09 No : 13

Age : 31 Years Sex : F  
Area : Vyara Date : 27/04/2024  
Time : 12:32PM

## BLOOD SUGAR TEST REPORT

| Test                     | Findings | UOM   | Normal Range |
|--------------------------|----------|-------|--------------|
| FASTING BLOOD SUGAR      | 88.3     | mg/dL | 70-110 mg/dL |
| FASTING URINE SUGAR      | NIL      | -     | NIL          |
| POSTPANDRIAL BLOOD SUGAR | 101.0    | mg/dL | 70-140 mg/dL |
| POSTPANDRIAL URINE SUGAR | N.R      | -     | NIL          |



*P. Chaudhari*  
Dr. PIYUSH B. CHAUDHARI  
M.D. Medicine  
Reg. No. G-21518

### Remarks

Designed By : Sarita Infotech Pvt. Ltd., Navsari

Yashfeen Cardiac Hospital

*Signature*  
Signature  
Technician

*Thanks for Reference*



# YASHFEEN CARDIAC HOSPITAL™

At. & Po. Viraval, Navsari. 396 445. Phone (H) (02637) 235725


Website : [www.yashfeenhospital.in](http://www.yashfeenhospital.in) E-mail : [info@yashfeenhospital.in](mailto:info@yashfeenhospital.in)  
(For Laboratory Reports Only)



Patient Name : SEJALKUMARI VANMALIBHAI PATEL Age : 31 Years Sex : F  
Ref By Dr. : - Area : Vyara Date : 27/04/2024  
Sample Time : 27/04/2024 09:09 No : 13 Time : 12:32PM

## ROUTINE URINE ANALYSIS

| Test                                  | Findings                   | UOM  | Normal Range |
|---------------------------------------|----------------------------|------|--------------|
| <b><u>PHYSICAL EXAMINATION</u></b>    |                            |      |              |
| Quantity                              | -                          | -    |              |
| Colour                                | YELLOW                     | -    |              |
| Appearance                            | CLEAR                      | -    |              |
| Reaction                              | ACIDIC                     | -    |              |
| Sp. Gravity                           | 1.011                      | -    |              |
| <b><u>CHEMICAL EXAMINATION</u></b>    |                            |      |              |
| U.Albumin                             | NIL                        | -    |              |
| Sugar                                 | NIL                        | -    |              |
| Acetone                               | NIL                        | -    |              |
| Bile Salt                             | NIL                        | -    |              |
| Bile Pigment                          | NIL                        | -    |              |
| Occult Blood                          | NIL                        | -    |              |
| <b><u>MICROSCOPIC EXAMINATION</u></b> |                            |      |              |
| Pus Cells                             | 1-2                        | /hpf |              |
| Epithelial cells                      | <b>5-6</b>                 | /hpf |              |
| Red cells                             | ABSENT                     | /hpf |              |
| Casts                                 | -                          | /hpf |              |
| Crystals                              | <b>AMORPHOUS SEEN</b>      | /hpf |              |
| Others                                | <b>BACTERIA {FEW} SEEN</b> | /hpf |              |



*P. Chaudhary*  
**Dr. PIYUSH B. CHAUDHARI**  
M.D. Medicine  
Reg. No. G-21513

Remarks

Designed By : Sarita Infotech Pvt. Ltd., Navsari

Yashfeen Cardiac Hospital

*Signature*  
**Signature  
Technician**

*Thanks for Reference*





# YASHFEEN CARDIAC HOSPITAL™

At. & Po. Viraval, Navsari. 396 445. Phone (H) (02637) 235725

Website : [www.yashfeenhospital.in](http://www.yashfeenhospital.in) E-mail : [info@yashfeenhospital.in](mailto:info@yashfeenhospital.in)  
(For Laboratory Reports Only)



Patient Name : SEJALKUMARI VANMALIBHAI PATEL Age : 31 Years Sex : F  
Ref By Dr. : - Area : Vyara Date : 27/04/2024  
Sample Time : 27/04/2024 09:09 No : 13 Time : 12:32PM

## GGT TEST REPORT

| Test      | Findings | UOM | Normal Range  |
|-----------|----------|-----|---------------|
| SERUM GGT | 37.0     | U/L | 10.0-71.0 U/L |



*P. Chaudhary*  
Dr. PIYUSH B. CHAUDHARI  
M.D. Medicine  
Reg. No. G-21518

### Remarks

Designed By : Sarita Infotech Pvt. Ltd., Navsari

Yashfeen Cardiac Hospital

*Abhishek*  
signature  
Technician

*Thanks for Reference*

# YASHFEEN IMAGING & RADIOLOGY DEPARTMENT

MANAGED BY :- YASHFEEN FOUNDATION

VIRAVAL, NAVSARI. 396 445. PHONE : (H) (02637) 235725

Website : [www.yashfeenhospital.in](http://www.yashfeenhospital.in) E-mail : [info@yashfeenhospital.in](mailto:info@yashfeenhospital.in)

|           |                      |      |            |
|-----------|----------------------|------|------------|
| Name      | SEJALKUMARI V. PATEL | Age  | 31Y/F      |
| Ref by Dr | SELF                 | Date | 27/04/2024 |

## USG ABDOMEN & PELVIS (SCREENING)(TVS)

**Liver** appears normal in size & shape with normal echopattern.  
No e/o focal or diffuse lesion. IHBR appear normal.  
PV and CBD appear normal.

**Gall bladder** appears distended & normal in shape & size. No e/o calculus or mass seen.  
Walls appear normal.

**Pancreas** appears normal in size and echogenicity. No e/o focal or diffuse lesion.

**Spleen** appears normal in size and shows normal echopattern. No e/o focal lesion.

**Both Kidneys** appear normal in size and echopattern. CM Differentiation is preserved.  
No e/o calculus or hydronephrosis on either side.  
Perirenal spaces appear normal on either side.  
Suprarenal regions appear normal on either side. No e/o mass lesion.

**Bladder** is empty (due to non-compliance of patient). Adv: Follow up USG with normally distended bladder.

**Uterus** appears anteverted, normal in size & shows normal echopattern.  
Endometrial cavity is empty. ET- 5 mm. No e/o focal or diffuse mass lesion.  
**Both ovaries** appear normal in size & echopattern.  
No e/o adnexal mass on either side.

RIF region appears normal.

No e/o ascites.

### IMPRESSION:

**No significant abnormality detected.**



Dr. DHARMESH DESAI

M.D. (Radiology)  
Dr. Dharmesh Desai 45284  
UP OF HOSPITAL

Please contact immediately for any typographical error.

This is only professional opinion. Not a final diagnosis. Kindly correlate clinically. Not valid for medical/legal purposes.



SEJALKUMARI ,  
ID:  
DOB:  
31 Years , ,  
Female ,Unknown  
Med.:  
Location:  
Referring Physician:  
Notes:

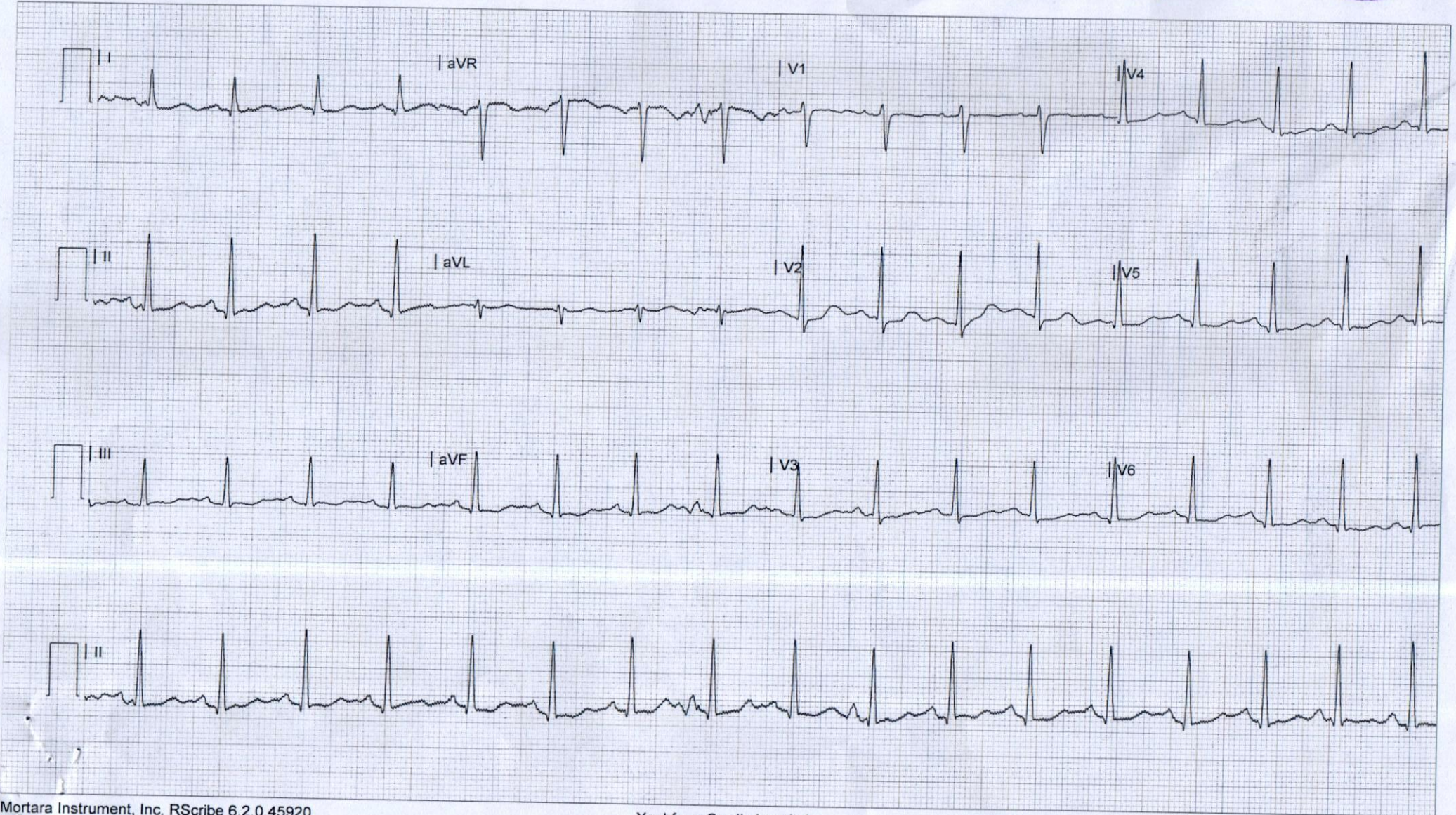
27-04-2024 09:43:07  
Vent. Rate: 101 BPM  
PR int: 156 ms  
QRS dur: 94 ms  
QT/QTc: 360/418 ms  
P-R-T axes: 60 68 75  
Avg. RR: 591 ms  
QTcB: 468 ms  
QTcF: 428 ms

SINUS TACHYCARDIA  
NONSPECIFIC ST & T-WAVE ABNORMALITY  
ABNORMAL RHYTHM ECG

UNCONFIRMED REPORT  
Reviewed by:

*f. chell*  
**Dr. PIYUSH B. CHAUDHARI**  
M.D. Medicine  
Reg. No. G-21518

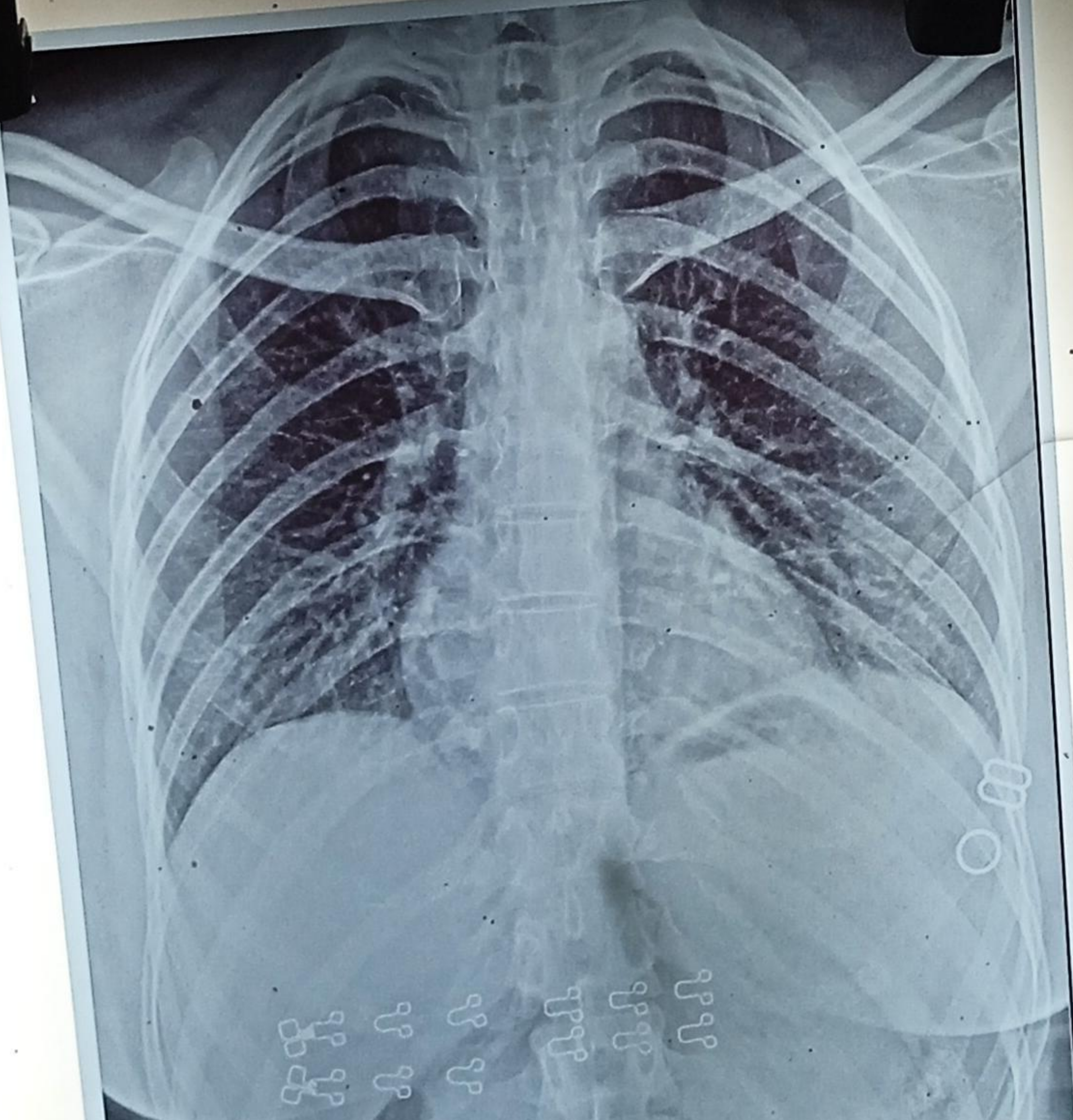
Signed by:  
Date:











4003557 SEJALKUMARI V PATEL 31/Y 270424549 ChestErect PA 27/04/2024  
YASHFEEN GROUP OF HOSPITALS NAVSARI PH:9924047789