



DEPARTMENT OF LABORATORY

NAVI MUMBAI

Patient Name : Mrs. NITAL NINAD HOMBALKAR	Age / Gender : 34 Y(s)/Female
Bill No/ UMR No : NMBC64168/NMU0049419	Referred By : Dr. DMO
Received Dt : 29-Mar-24 11:07 am	Report Date : 29-Mar-24 06:36 pm

FINAL REPORT

<u>Parameters</u>	<u>Specimen</u>	<u>Result</u>	<u>Biological Reference Intervals</u>	<u>Method</u>
CUE (COMPLETE URINE EXAMINATION)				
<u>PHYSICAL EXAMINATION</u>				
VOLUME	Urine	30ML		
COLOUR		PALE YELLOW	PALE YELLOW	
APPEARANCE		CLEAR	CLEAR	
DEPOSIT		ABSENT	ABSENT	
<u>CHEMICAL EXAMINATION</u>				
SPECIFIC GRAVITY	Urine	1.010	1.000 - 1.030	Dipstick
PH		5.0	5.0 - 8.0	Dipstick
PROTEIN		NEGATIVE	NEGATIVE	Dipstick/Heat coagulation test
GLUCOSE		ABSENT	ABSENT	Dipstick/Benedict's test
UROBILINOGEN		NORMAL	NORMAL	Dipstick
KETONE		NEGATIVE	NEGATIVE	Dipstick/Rothera's Nitroprusside test.
BILIRUBIN		NEGATIVE	NEGATIVE	Dipstick/Fouchet's test
BILE SALT		NEGATIVE	NEGATIVE	Hay's sulphur powder test
BILE PIGMENT		NEGATIVE	NEGATIVE	Fouchet test
NITRITE		NEGATIVE	NEGATIVE	Dipstick
LEUCOCYTE ESTERASE		NEGATIVE	NEGATIVE	
<u>MICROSCOPIC EXAMINATION</u>				
PUS CELLS	Urine	3-4	0 - 5 /hpf	MICROSCOPIC EXAMINATION
RBC		NIL	0 - 5 /hpf	MICROSCOPIC EXAMINATION
EPITHELIAL CELLS		6-8	0 - 5 /hpf	MICROSCOPIC EXAMINATION
CRYSTALS		NIL	NIL	MICROSCOPIC EXAMINATION
CASTS		NIL	NIL	MICROSCOPIC EXAMINATION
BACTERIA		ABSENT		MICROSCOPIC EXAMINATION
YEAST		ABSENT		MICROSCOPIC EXAMINATION
AMORPHOUS DEPOSITS		ABSENT		MICROSCOPIC EXAMINATION
SPERMATOZOA				MICROSCOPIC EXAMINATION
MUCUS THREAD		ABSENT		MICROSCOPIC EXAMINATION
NOTE		Microscopic examination of urine is carried out on centrifuged urinary sediment.		





MEDICOVER HOSPITALS

DEPARTMENT OF LABORATORY

NAVI MUMBAI

Patient Name : Mrs. NITAL NINAD HOMBALKAR

Age / Gender : 34 Y(s)/Female

Bill No/ UMR No : NMBC64168/NMU0049419

Referred By : Dr. DMO

Received Dt : 29-Mar-24 11:07 am

Report Date : 29-Mar-24 06:36 pm

Parameters

Specimen **Result**

Biological Reference In Method

*** End Of Report ***





DEPARTMENT OF LABORATORY

NAVI MUMBAI

Patient Name : Mrs. NITAL NINAD HOMBALKAR	Age / Gender : 34 Y(s)/Female
Bill No/ UMR No : NMBC64168/NMU0049419	Referred By : Dr. DMO
Received Dt : 29-Mar-24 11:07 am	Report Date : 29-Mar-24 03:15 pm

FINAL REPORT

<u>Parameters</u>	<u>Specimen</u>	<u>Result</u>	<u>Biological Reference Intervals</u>	<u>Method</u>
ESR	CITRATED BLOOD	40	0 - 20 mm/1st hour	WESTERGREN'S METHOD

COMPLETE BLOOD COUNT

RBC

R B C COUNT	EDTA Blood	4.46	3.8 - 4.8 10 ⁶ /μL
HEMOGLOBIN		11.6	12.0 - 15.0 g/dl
PCV/HCT		34.8	40 - 50 %
MCV		78.0	83 - 101 fl
MCH		26.0	27 - 32 pg
MCHC		33.4	31.5 - 34.5 g/dL
RDW(cv)		14.1	11.6 - 14.0 %

PLATELETS

PLATELET COUNT	EDTA Blood	222	150 - 400 10 ³ /μL
MPV		10.3	7.5 - 11.5 fl

WBC

TC (TOTAL LEUCOCYTE COUNT)	EDTA Blood	3.81	4.0 - 11.0 10 ³ /μl
----------------------------	------------	------	--------------------------------

DIFFERENTIAL COUNT

NEUTROPHILS	EDTA Blood	60	40 - 80 %
LYMPHOCYTES		35	20 - 40 %
MONOCYTES		03	02 - 10 %
EOSINOPHILS		02	00 - 06 %
BASOPHILS		00	00 - 01 %

PERIPHERAL SMEAR EXAMINATION
RBC

WBC

PLATELETS

ADVISED

Mild anisopoikilocytosis. Microcytic hypochromic with ovalocytes and elliptocytes.

Mild leucopenia is present.

Adequate in smear.

Serum iron studies.

BLOOD GROUPING AND RH

BLOOD GROUP

RH TYPE

Blood

" O "

POSITIVE

TUBE AGGLUTINATION

*** End Of Report ***

THIS IS A MODIFIED REPORT





MEDICOVER HOSPITALS

DEPARTMENT OF LABORATORY

NAVI MUMBAI

Patient Name : Mrs. NITAL NINAD HOMBALKAR

Age / Gender : 34 Y(s)/Female

Bill No/ UMR No : NMBC64168/NMU0049419

Referred By : Dr. DMO

Received Dt : 29-Mar-24 11:07 am

Report Date : 29-Mar-24 05:24 pm

Parameters

Specimen Result

TUBE AGGLUTINATI





DEPARTMENT OF LABORATORY

NAVI MUMBAI

Patient Name : Mrs. NITAL NINAD HOMBALKAR	Age / Gender : 34Y(s)/Female
Bill No/ UMR No : NMBC64168/NMU0049419	Referred By : Dr. DMO
Received Dt : 29-Mar-24 11:09 am	Report Date : 29-Mar-24 02:08 pm

FINAL REPORT

<u>Parameter</u>	<u>Specimen</u>	<u>Result Values</u>	<u>Biological Reference</u>	<u>Method</u>
FBS (FASTING BLOOD GLUCOSE WITH URINE GLUCOSE)				
FASTING BLOOD GLUCOSE		86	Normal Range : 70 - 99 mg/dL	Hexokinase
SERUM ELECTROLYTES				
SERUM SODIUM		141	136 - 145 mmol/L	ISE INDIRECT
SERUM POTASSIUM		4.7	3.5 - 5.1 mmol/L	ISE INDIRECT
SERUM CHLORIDES		104	98 - 107 mmol/L	ISE INDIRECT
T3,T4 AND TSH				
T3		102.2	70 - 204 ng/dL	Method : ECLIA
T4		6.02	5.1 - 14.1 ug/dL	Method : ECLIA
TSH(THYROID STIMULATING HORMONE)		1.24	0.270 - 4.20 uIU/mL	Method : ECLIA
BUN / CREATININE RATIO				
BUN (Blood Urea Nitrogen.)		6	7.0 - 21.0 mg/dL	Calculated
SERUM CREATININE		0.56	0.6 - 1.2 mg/dL	
BUN / CREATININE RATIO		10.71	10 - 20	
SERUM CREATININE				
CREATININE		0.56	0.6 - 1.2 mg/dl	Method : jaffe
LFT(LIVER FUNCTION TEST)				
TOTAL BILIRUBIN		0.3	< 1.2 mg/dL	Method : Diazo Method
DIRECT BILIRUBIN		0.1	<= 0.20 mg/dL	Method: Diazo Method
INDIRECT BILIRUBIN		0.2	<= 1.0 mg/dL	
SGPT (ALT)		12	<= 33 U/L	Method : UV without P5P
SGOT (AST)		16	<= 32 U/L	Method : UV without P5P
ALKALINE PHOSPHATASE (ALP)		69	40 - 129 U/L	Method : PNPP, AMP Buffer - IFCC Ref.
TOTAL PROTEINS		7.6	35 - 105 U/L	Method : Biuret method
SERUM ALBUMIN		4.3	6.0 - 8.0 g/dL	Method : Bromocresol Green (BCG)
GLOBULINS		3.3	3.5 - 5.2 g/dL	
A/G RATIO		1.3	2.5 - 3.5 g/dL	
GAMMA GLUTAMYL TRANSFERASE(GGT)		8	1.2 - 2.5	Method : G-glutamyl-carboxy-nitr oanilide - IFCC Ref.
			6 - 42 U/L	





DEPARTMENT OF LABORATORY

NAVI MUMBAI

Patient Name : Mrs. NITAL NINAD HOMBALKAR	Age / Gender : 34Y(s)/Female
Bill No/ UMR No : NMBC64168/NMU0049419	Referred By : Dr. DMO
Received Dt : 29-Mar-24 11:07 am	Report Date : 29-Mar-24 05:56 pm

Specimen

BUN(BLOOD UREA NITROGEN)

BUN (Blood Urea Nitrogen.) 6 7.0 - 21.0 mg/dL Calculated

TOTAL PROTEIN

TOTAL PROTEINS 7.6 6.0 - 8.0 g/dL Method : Biuret method

LIPID PROFILE

TOTAL CHOLESTEROL 165 Desirable : : < 200 mg/dL METHOD : Enzymatic colorimetric
Borderline High : : 200 - 239 mg/dL

HDL CHOLESTEROL 46 High risk : > 240 mg/dL Homogeneous enzymatic colorimetric
Low : : < 40 mg/dL
High : : > 60 mg/dL

LDL CHOLESTEROL 111 Optimal : - < 100 mg/dL
Near Optimal : 100 - 129 mg/dL
Borderline High : 130 - 159 mg/dL
High : 160 - 189 mg/dL
Very High : - > 190 mg/dL

VLDL 11
SERUM TRYGLYCERIDES 53 < 150 mg/dL METHOD: Enzymatic colorimetric
Borderline High : 150 - 199 mg/dL
High : 200 - 499 mg/dL

CHO/HDL RATIO 3.59 Normal : - < 3.5
High Risk : - > 5.0

LDL/HDL RATIO 2.41
SERUM URIC ACID 3.4 2.4 - 5.7 mg/dL uricase

PLBS (POST LUNCH BLOOD SUGAR WITH URINE SUGAR)

PLBS (POST LUNCH BLOOD GLUCOSE) 97 110 - 180 mg/dL Hexokinase

HBA1C (GLYCOSYLATED HAEMOGLOBIN)

HBA1C 5.6 < 5.7 Normal Prediabetic 5.7 TINIA
- 6.4 & >/=6.5 Diabetic %

MPG(Mean Plasma Glucose) 114 Excellent Control : 90 - 120 mg/dL
Good Control : 121 - 150 mg/dL

*** End Of Report ***

THIS IS A MODIFIED REPORT





MEDICOVER HOSPITALS

DEPARTMENT OF LABORATORY

NAVI MUMBAI

Patient Name : Mrs. NITAL NINAD HOMBALKAR
Age / Gender : 34Y(s)/Female
Bill No/ UMR No : NMBC64168/NMU0049419
Referred By : Dr. DMO
Received Dt : 29-Mar-24 11:09 am
Report Date : 30-Mar-24 09:42 am

Parameters **Specimen** **Result** **Biological Reference In Method**

Lab Incharge

Dr. VISHAL MEHROTRA, MD Pathology
Head, Laboratory Services

Verified By : : 026979

Test results related only to the item tested.

No part of the report can be reproduced without written permission of the laboratory.



Patient ID:	NMU0049419	Patient Name:	NITAL NINAD HOMBALKAR
Age:	34 Years	Sex:	F
Accession Number:	NMBC64168	Modality:	DX
Referring Physician:	DR.DMO	Study:	CHEST
Study Date:	29-Mar-2024	Study Time:	11:47:26

X RAY CHEST PA VIEW

Both lungs are clear.

The frontal cardiac dimensions are normal.

The pleural spaces are clear.

Both hilar shadows are normal in position and density.

No diaphragmatic abnormality is seen.

The soft tissues and bony thorax are normal.

Impression:

- **No significant abnormality is seen.**



DR. ANUPKUMAR AGRAWAL
Consultant & HOD Radiology
MBBS, MD

Date: 29-Mar-2024 15:32:32

Patient ID:	NMU0049419	Patient Name:	NITAL NINAD HOMBALKAR
Age:	34 Years	Sex:	F
Accession Number:	NMBC64168	Modality:	US
Referring Physician:	DR.DMO	Study:	USG ABDOMEN WHOLE
Study Date:	29-Mar-2024	Study Time:	12:04:19

USG ABDOMEN & PELVIS

The Liver is normal in size (14.4 cm) and shows normal echotexture. No focal lesion is seen. The Hepatic veins appear normal. There is no IHBR dilatation. The portal vein appears normal.

The gall bladder is physiologically distended with normal wall thickness. There is no evidence of gallstones. C.B.D. is of normal caliber.

The Pancreas is normal in size and echotexture.

The spleen is normal size (10.0 cm). No focal lesion is seen.

Both kidneys are normal in size, shape and echotexture. They shows normal cortical echogenicity with maintained cortico-medullary distinction.

The Right Kidney measures 12.0 x 3.4 cm.

The Left Kidney measures 12.4 x 3.9 cm.

There is no evidence of a calculus, hydronephrosis, or hydroureter.

The Urinary bladder is adequately distended and shows normal wall thickness. No evidence of any intraluminal mass or calculi.

The uterus is normal in size and echotexture. It measures 8.2 x 5.3 x 3.5 cm. No focal lesion is seen. The Endometrial thickness is 8.1 mm.

Both ovaries are well visualized and appear normal in size and echotexture.

The Right ovary measures 2.4 x 2.1 cm

The Left ovary measures 2.9 x 2.3 cm

There is no evidence of any ovarian or adnexal mass lesion.


Visualised bowel loops are unremarkable.

There is no evidence of significant lymphadenopathy.

No ascitis is seen.

IMPRESSION:

- No significant abnormality is seen.



DR. ANUPKUMAR AGRAWAL
Consultant & HOD Radiology
MBBS, MD

Date: 29-Mar-2024 12:45:03



MEDICOVER
HOSPITALS

NAVI MUMBAI

2D ECHO CARDIOGRAPHY WITH COLOR DOPPLER

Name : Mrs. Nital Hambalkar

Date:-29/03/2024

Age / Sex : 34 Yrs / Female

UMR No. 0049419

Referred By : Health check up

FINDINGS:

- No left ventricle regional wall motion abnormality.
- Normal left ventricle systolic function. LVEF = 60%.
- No left ventricle diastolic dysfunction.
- Trivial mitral regurgitation.
- No aortic regurgitation. No aortic stenosis.
- Trivial tricuspid regurgitation. No pulmonary hypertension.
PASP = 25 mm Hg.
- No left ventricle clot / vegetation/pericardial effusion.
- Intact IAS and IVS.
- Normal left atrium and left ventricle dimensions.
- Normal right atrium and right ventricle dimensions.
- Normal right ventricle systolic function. No hepatic congestion.

IMP:

- No RWMA.
- Trivial MR and TR. No PH.
- Normal LV and RV systolic function.

DR. SAMEER VANKAR
MD DM CARDIOLOGY





M-MODE MEASUREMENTS:

NAVI MUMBAI

LA	35	mm
AO root	29	mm
AO CUSP SEP	18	mm
LVID(s)	31	mm
LVID(d)	43	mm
IVS(d)	11	mm
LVPW(d)	10	mm
RVID(d)	29	mm
RA	31	mm
LVEF	60	%

	PEAK	MEAN	Vmax	Gradient of Regurgitation
MITRAL	N			Trivial
AORTIC	7			Nil
TRICUSPID	25			Trivial
PULMONERY	4.4			Nil



HC 49419
34 Years

NITAL HAMBALKAR
Female

3/29/2024 2:05:36 PM

Rate 71 . Sinus rhythm.....normal P axis, V-rate 50- 99

PR 144
QRSD 95
QT 405
QTc 441

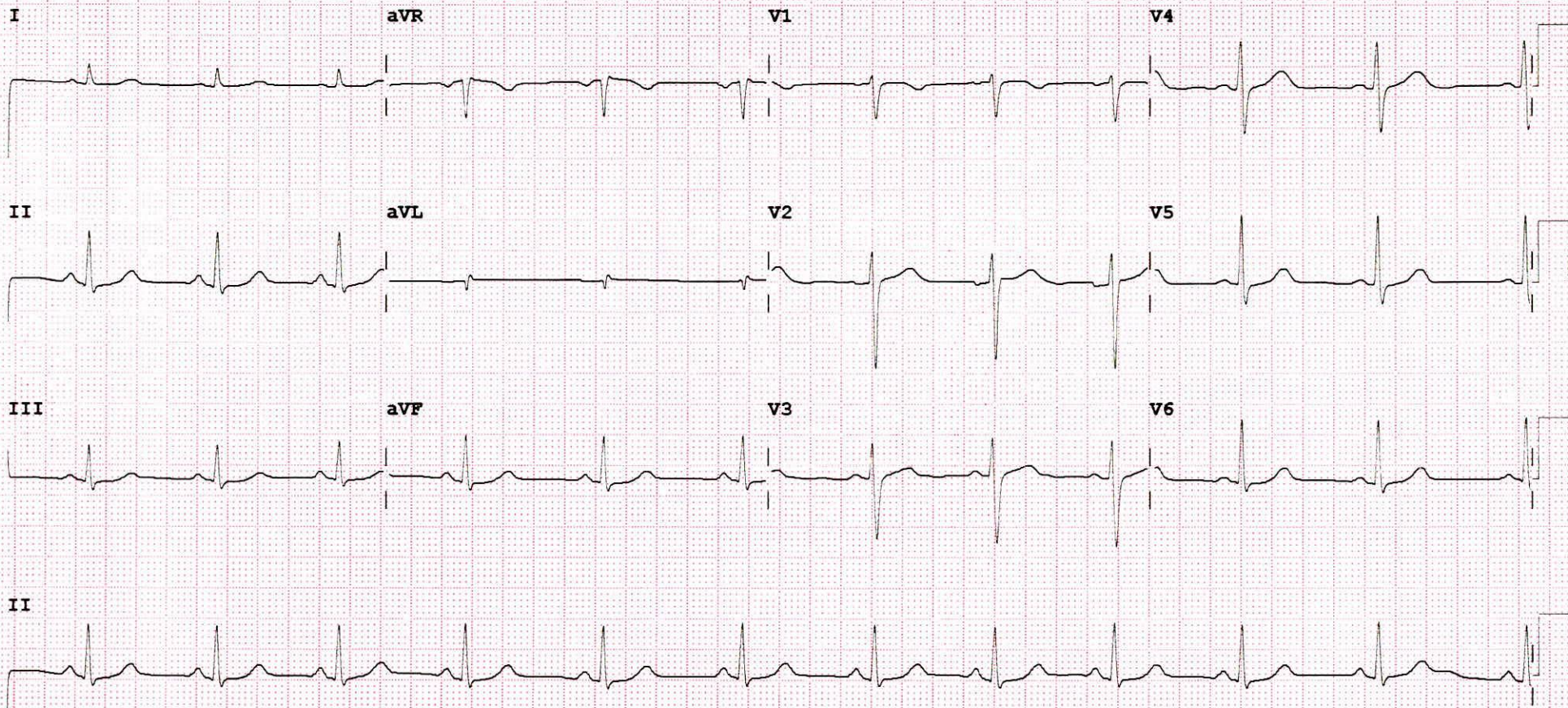
--AXIS--
P 73
QRS 63
T 58

- NORMAL ECG -

N12
h

12 Lead; Standard Placement

Unconfirmed Diagnosis





DEPARTMENT OF OPHTHALMOLOGY

MEDICOVER HOSPITALS

DATE: 29/03/24

PATIENT NAME: Mr. Nilesh Hambekar

AGE / SEX : 34/12 NAVI MUMBAI

UMR NO : WSMU0049419

	RE	LE
VA (DISTANCE)	6/6	6/6
VA (NEAR)	Ng	Ng
COLOUR VISION	Normal	Normal

		SPHERE	CYLINDER	AXIS	VA
MRx	O D	plano	_____		6/6/NG
	O S	plano	_____		6/6/NG

HISTORY :

No h/o HT/Dm/Thyroid

No h/o spectacle use

No h/o ocular Trauma (BE)

OCULAR FINDINGS :

(BE) - Ant - seg WM

(undilated) Disc (BE) - 0.3

ADVICE:

Refresh tears eld qid 1777 X /month

AS
CDR-ANUSHREE VANURAJ

