



Pathology Department

VIDHI
DIAGNOSTICS



Patient's name : PARULBEN JIGARBHAI JOSHI
Age/Sex : 53 Years/Female
Referred by : MEDI WHEEL
Collection Time : 09:41

Reg. ID : P-256-23
Accession : 26026
Order Dt/time : 13/04/2024 09:41

Complete Blood Count

Sample Type: EDTA

Test Name	Result	Units	Biological Reference Interval
<u>Blood Counts</u>			
Haemoglobin :	9.4	Gms%	12.5 - 16.0
Total R.B.C. :	4.96	mill/c.mm	4.2 - 5.4
Total W. B. C. :	7010	/cu mm	4000 - 10500
Platelet Count :	323000	/cu.mm	1,50,000 - 4,50,000
<u>Differential Count</u>			
Neutrophils :	57	%	40 - 70
Lymphocytes :	38	%	20 - 40
Eosinophils :	03	%	1 - 4
Monocytes :	02	%	2 - 6
Basophils :	00	%	0 - 01
<u>Blood Indices</u>			
P. C. V :	31.7	%	37 - 47
M. C. V. :	64.0	fl	78 - 100
M.C.H :	18.9	pg	27 - 31
M. C. H. C :	29.5	%	32 - 36
R.D.W :	15.9	%	11.5 - 14.0
<u>E.S.R.(Westergren Method)</u>			
After one hour :	10	mm/hr	3 - 12

TESTS DONE ON FULLY AUTOMATED HEMATOLOGY ANALYZER.

Dr. Gayatri M. Mehta
M. D. Patho)
Reg. No. : G-32215

DR GAYATRI MEHTA
MD(PATHOLOGY)

DR.ANAND D.PARIKH
MD(PATHOLOGY)

LAB USE ONLY (Entered by :GM Enter Date/Time:13/04/2024 5:54:00 PM) (Verify by :GM Verify Date/Time:13/04/2024 5:54:00 PM)



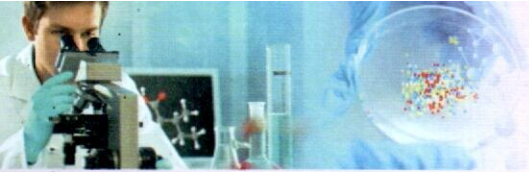Vidhi Diagnostics | Pathology Department

L-86, Swatantra Senani Nagar, Opp. Akhbarnagar Petrol Pump, Nr. Akhbarnagar Circle, Nava-Vadaj, Ahmedabad - 380 013.

M. - Pathology : 8849893954, Ph. : 079-27621406, M. 98799 29406, 98250 09406, E-mail : vidhidiagnostics@gmail.com, Web. : www.vidhidiagnostics.com
Time (Pathology) : Mon. to Sat. 8.30 am to 8.00 pm, Sunday 9 am to 12 Noon

Pathology means science behind medicine

CT SCAN & CBCT FACILITY NOW AVAILABLE



Patient's name : PARULBEN JIGARBHAI JOSHI
Age/Sex : 53 Years/Female
Referred by : MEDI WHEEL
Collection Time : 09:41

Reg. ID : P-256-23
Accession : 26026
Order Dt/time : 13/04/2024 09:41

Blood Group

Sample Type: EDTA sample.

Test Name	Result
BG :	" A "
RH :	POSITIVE
Remarks	Done by forward grouping method.

Blood Glucose

Sample Type: Serum

Test Name	Result	Units	Biological Reference Interval
Fasting Blood Glucose :	87.1	mg/dl	70 - 110
Urine Sugar :	NIL		Absent
<i>GOD-POD Method.</i>			

Blood Glucose

Sample Type: Serum

Test Name	Result	Units	Biological Reference Interval
Post Prandial Blood Glucose After 2hr. :	127.6	mg/dl	80 - 140
Urine Sugar :	NIL		Absent
<i>GOD-POD Method.</i>			

Dr. Gayatri M. Mehta
M. D. Patho)
Reg. No. : G-32215

DR GAYATRI MEHTA
MD(PATHOLOGY)

DR. ANAND D. PARIKH
MD(PATHOLOGY)

LAB USE ONLY (Entered by :GM Enter Date/Time:13/04/2024 5:55:00 PM) (Verify by :GM Verify Date/Time:13/04/2024 5:56:00 PM)



Vidhi Diagnostics | Pathology Department

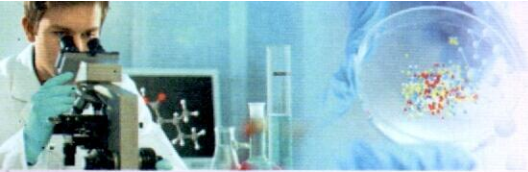L-86, Swatantra Senani Nagar, Opp. Akhbarnagar Petrol Pump, Nr. Akhbarnagar Circle, Nava-Vadaj, Ahmedabad - 380 013.

M. - Pathology : 8849893954, Ph. : 079-27621406, M. 98799 29406, 98250 09406, E-mail : vidhidiagnostics@gmail.com, Web. : www.vidhidiagnostics.com

Time (Pathology) : Mon. to Sat. 8.30 am to 8.00 pm, Sunday 9 am to 12 Noon

Pathology means science behind medicine

CT SCAN & CBCT FACILITY NOW AVAILABLE



Creating Life in Progress



Pathology Department

Patient's name : PARULBEN JIGARBHAI JOSHI
Age/Sex : 53 Years/Female
Referred by : MEDI WHEEL
Collection Time : 09:41

Reg. ID : P-256-23
Accession : 26026
Order Dt/time : 13/04/2024 09:41

HbA1C

Sample Type: EDTA

Test Name	Result	Units	Biological Reference Interval
HbA1C :	5.5	%	Non-diabetic: 4.2-6.2 Pre-diabetic : 6.3-7.2 Diabetic : 7.3-8.2
Mean Blood Glucose of Last 03 months.	111	mg/dl	

Comment

*As per the new 2009 update of American Diabetes Association regarding HbA1C & Mean Blood Glucose relationship.

NOTE:

This test is used to monitor diabetic patients compliance with the therapeutic regimen and logo It's level is proportional to both the average blood glucose concentration and the life span of the red blood cells (RBC) in circulation. HbA1c values are free of day to day glucose fluctuations and are unaffected by exercise or recent food intake.

Dr. Gayatri M. Mehta
M. D. Patho)
Reg. No. : G-32215

DR GAYATRI MEHTA
MD(PATHOLOGY)

DR. ANAND D. PARIKH
MD(PATHOLOGY)

LAB USE ONLY (Entered by :GM Enter Date/Time:13/04/2024 5:54:00 PM) (Verify by :GM Verify Date/Time:13/04/2024 5:54:00 PM)



Vidhi Diagnostics | Pathology Department

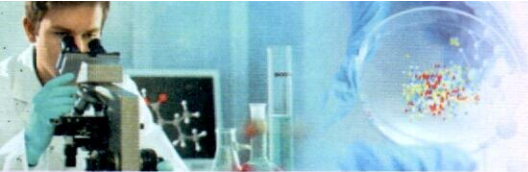L-86, Swatantra Senani Nagar, Opp. Akhbarnagar Petrol Pump, Nr. Akhbarnagar Circle, Nava-Vadaj, Ahmedabad - 380 013.

M. - Pathology : 8849893954, Ph. : 079-27621406, M. 98799 29406, 98250 09406, E-mail : vidhidiagnostics@gmail.com, Web. : www.vidhidiagnostics.com

Time (Pathology) : Mon. to Sat. 8.30 am to 8.00 pm, Sunday 9 am to 12 Noon

Pathology means science behind medicine

CT SCAN & CBCT FACILITY NOW AVAILABLE



Creating Life in Progress

Patient's name : PARULBEN JIGARBHAI JOSHI
Age/Sex : 53 Years/Female
Referred by : MEDI WHEEL
Collection Time : 09:41

Reg. ID : P-256-23
Accession : 26026
Order Dt/time : 13/04/2024 09:41

Lipid Profile

Sample Type: Serum

Test Name	Result	Units	Biological Reference Interval
S. Cholesterol : Oxidase-esterase method.	205	mg/dl	0 - 200
S. Triglyceride : Enzymatic Colorimetry method	183.3	mg/dL	0 - 200
S. HDL - Cholesterol : Serum by Enzymatic method.	40.7	mg/dL	35 - 65
S. LDL - Cholesterol : Serum by Enzymatic method	127.64	mg/dL	0 - 130
S. VLDL - Cholesterol :	36.66	mg/dL	0 - 30
S. Chole/HDL.Ratio :	5.04		1 - 6
S. LDL / HDL Cholesterol Ratio :	3.14		0 - 3.5

Dr. Gayatri M. Mehta
M. D. Patho)
Reg. No. : G-32215

DR GAYATRI MEHTA
MD(PATHOLOGY)

DR. ANAND D. PARIKH
MD(PATHOLOGY)

LAB USE ONLY (Entered by :GM Enter Date/Time:13/04/2024 5:54:00 PM) (Verify by :GM Verify Date/Time:13/04/2024 5:54:00 PM)



Vidhi Diagnostics | Pathology Department

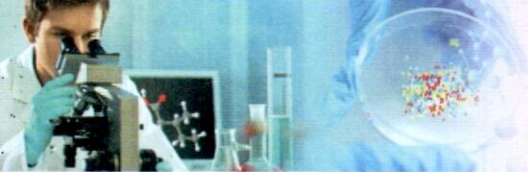L-86, Swatantra Senani Nagar, Opp. Akharnagar Petrol Pump, Nr. Akharnagar Circle, Nava-Vadaj, Ahmedabad - 380 013.

M. - Pathology : 8849893954, Ph. : 079-27621406, M. 98799 29406, 98250 09406, E-mail : vidhidiagnostics@gmail.com, Web. : www.vidhidiagnostics.com

Time (Pathology) : Mon. to Sat. 8.30 am to 8.00 pm, Sunday 9 am to 12 Noon

Pathology means science behind medicine

CT SCAN & CBCT FACILITY NOW AVAILABLE



Patient's name : PARULBEN JIGARBHAI JOSHI
Age/Sex : 53 Years/Female
Referred by : MEDI WHEEL
Collection Time : 09:41

Reg. ID : P-256-23
Accession : 26026
Order Dt/time : 13/04/2024 09:41

BIOCHEMISTRY

Sample type :Serum

Test Name	Result	Units	Biological Reference Interval
Urea, (Serum by GLDH method) :	14.1	mg/dl	10 - 50
S.Uric acid, (Serum by Uricase method) :	6.7	mg/dl	2.6-6.0
Bun :	6.6	mg/dl	6-20
Creatinine, (Serum by Enzymatic reaction) :	0.63	mg/dl	0.5-1.2
S.G.P.T (ALT) : (Serum by IFCC method)	10.8	U/L	0 - 40
S.G.O.T (AST) : (Serum by IFCC method)	13.0	U/L	0 - 37
ALK.PHOSPHATASE : (Serum by PNP method)	76	U/L	35-104
G.G.T :	19.1	U/L	8 - 78
<u>BILIRUBIN</u>			
Total :	0.55	mg/dl	Up to 1.2
Direct :	0.27	mg/dl	0-0.7
Indirect :	0.28	mg/dl	0 - 0.5
<u>SERUM PROTEINS</u>			
Total Protein (Serum by Biuret method) :	6.82	gms/dl	6.4 - 8.5
Albumin (Serum by BCG method) :	3.87	gms/dl	3.97-4.94
Globulins :	2.95	gms/dl	2.3 - 3.5
A/G Ratio :	1.312		0.9 - 2.9

Dr. Gayatri M. Mehta
(M. D. Patho)
Reg. No. : G-32215

DR GAYATRI MEHTA
MD(PATHOLOGY)

DR.ANAND D.PARIKH
MD(PATHOLOGY)

LAB USE ONLY (Entered by :GM Enter Date/Time:13/04/2024 5:52:00 PM) (Verify by :GM Verify Date/Time:13/04/2024 5:52:00 PM)



Vidhi Diagnostics | Pathology Department

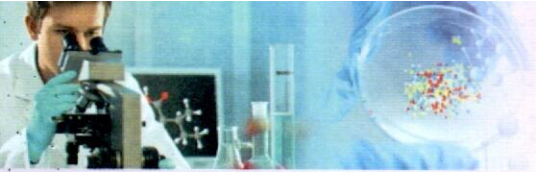L-86, Swatantra Senani Nagar, Opp. Akhbarnagar Petrol Pump, Nr. Akhbarnagar Circle, Nava-Vadaj, Ahmedabad - 380 013.

M. - Pathology : 8849893954, Ph. : 079-27621406, M. 98799 29406, 98250 09406, E-mail : vidhidiagnostics@gmail.com, Web. : www.vidhidiagnostics.com

Time (Pathology) : Mon. to Sat. 8.30 am to 8.00 pm, Sunday 9 am to 12 Noon

Pathology means science behind medicine

CT SCAN & CBCT FACILITY NOW AVAILABLE



Creating Life in Science



Pathology Department

Patient's name : PARULBEN JIGARBHAI JOSHI
Age/Sex : 53 Years/Female
Referred by : MEDI WHEEL
Collection Time : 09:41

Reg. ID : P-256-23
Accession : 26026
Order Dt/time : 13/04/2024 09:41

Thyroid Function Test

Sample Type: Serum

Test Name	Result	Units	Biological Reference Interval
TOTAL T3 :	1.21	ng/ml	1.07 - 1.86
TOTAL T4 :	7.03	µg/dL	6.09 - 12.23
TSH(Ultra sensitive) :	1.09	µIU/mL	0.4001 - 4.049

Dr. Gayatri M. Mehta
M. D. Patho
Reg. No. : G-32215

DR GAYATRI MEHTA
MD(PATHOLOGY)

DR. ANAND D. PARIKH
MD(PATHOLOGY)

LAB USE ONLY (Entered by :GM Enter Date/Time:13/04/2024 5:58:00 PM) (Verify by :GM Verify Date/Time:13/04/2024 5:58:00 PM)



Vidhi Diagnostics | Pathology Department

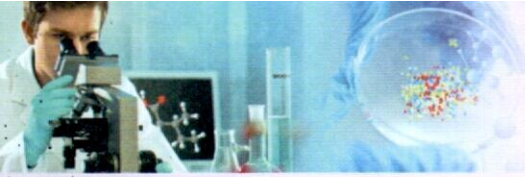L-86, Swatantra Senani Nagar, Opp. Akhbarnagar Petrol Pump, Nr. Akhbarnagar Circle, Nava-Vadaj, Ahmedabad - 380 013.

M. - Pathology : 8849893954, Ph. : 079-27621406, M. 98799 29406, 98250 09406, E-mail : vidhidiagnostics@gmail.com, Web. : www.vidhidiagnostics.com

Time (Pathology) : Mon. to Sat. 8.30 am to 8.00 pm, Sunday 9 am to 12 Noon

Pathology means science behind medicine

CT SCAN & CBCT FACILITY NOW AVAILABLE



Creating life in Science



Pathology Department

Patient's name	: PARULBEN JIGARBHAI JOSHI	Reg. ID	: P-256-23
Age/Sex	: 53 Years/Female	Accession	: 26026
Referred by	: MEDI WHEEL	Order Dt/time	: 13/04/2024 09:41
Collection Time	: 09:41		

Urine Analysis

Sample Type: Urine

Test Name	Result	Units	Biological Reference Interval
<u>Physical Examination</u>			
Quantity :	20	ml	0 - 500 ml
Colour :	Pale Yellow		Pale Yellow
Transparency :	Slight Turbid.		Clear
Reaction :	Acidic		4.6 - 8.0
Specific Gravity :	1.012		1.016 - 1.022
Sediment :	Present		
<u>Chemical Examination</u>			
Albumin :	Present (Faint Trace)		Absent
Sugar :	NIL		Absent
Acetone :	Absent		Absent
Bile Salts :	Absent		Absent
Bile Pigments :	Absent		Absent
Urobilogen :	Absent		Absent
Nitrites :	Absent		Absent
<u>Microscopic Examination</u>			
Red blood Cells :	2-3	/h.p.f	Absent
Pus Cells :	2-3	/h.p.f	Absent
Epithelial Cells :	1-2	/h.p.f	< 10.0
Amorphous :	Absent	/h.p.f	Absent
Bacteria :	Absent	/h.p.f	Absent
Crystals :	Absent	/h.p.f	Absent
Casts :	Absent	/h.p.f	Absent
Fungus :	Not seen	/h.p.f	Absent

Dr. Gayatri M. Mehta
 M. D. Patho)
 Reg. No. : G-32215

DR. GAYATRI MEHTA
 MD(PATHOLOGY)

DR. ANAND D. PARIKH
 MD(PATHOLOGY)



(Entered by :GM Enter Date/Time:13/04/2024 6:00:00 PM) (Verify by :GM Verify Date/Time:13/04/2024 6:00:00 PM)

Vidhi Diagnostics | Pathology Department

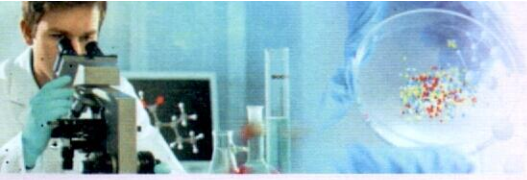L-86, Swatantra Senani Nagar, Opp. Akhbarnagar Petrol Pump, Nr. Akhbarnagar Circle, Nava-Vadaj, Ahmedabad - 380 013.

M. - Pathology : 8849893954, Ph. : 079-27621406, M. 98799 29406, 98250 09406, E-mail : vidhidiagnostics@gmail.com, Web. : www.vidhidiagnostics.com

Time (Pathology) : Mon. to Sat. 8.30 am to 8.00 pm, Sunday 9 am to 12 Noon

Pathology means science behind medicine

CT SCAN & CBCT FACILITY NOW AVAILABLE



-Pathology Department



Patient's name : PARULBEN JIGARBHAI JOSHI
Age/Sex : 53 Years/Female
Referred by : MEDI WHEEL
Collection Time : 09:41

Reg. ID : P-256-23
Accession : 26026
Order Dt/time : 13/04/2024 09:41

Stool Examination

STOOL SAMPLE NOT RECEIVED

Dr. Gayatri M. Mehta
M. D. Patho)
Reg. No. : G-32215

DR GAYATRI MEHTA
MD(PATHOLOGY)

DR. ANAND D. PARIKH
MD(PATHOLOGY)

LAB USE ONLY (Entered by :GM Enter Date/Time:13/04/2024 5:57:00 PM) (Verify by :GM Verify Date/Time:13/04/2024 5:57:00 PM)



Vidhi Diagnostics | Pathology Department

L-86, Swatantra Senani Nagar, Opp. Akhbarnagar Petrol Pump, Nr. Akhbarnagar Circle, Nava-Vadaj, Ahmedabad - 380 013.

M. - Pathology : 8849893954, Ph. : 079-27621406, M. 98799 29406, 98250 09406, E-mail : vidhidiagnostics@gmail.com, Web. : www.vidhidiagnostics.com

Time (Pathology) : Mon. to Sat. 8.30 am to 8.00 pm, Sunday 9 am to 12 Noon

Pathology means science behind medicine

CT SCAN & CBCT FACILITY NOW AVAILABLE

Health Check up Booking Request(bobS18591)

Mediwheel <wellness@mediwheel.in>
To: vidhidiagnostics@gmail.com
Cc: customercare@mediwheel.in

26 March 2024 at 15:54



Mediwheel
...Your wellness partner

011-41195959

Dear VIDHI DIAGNOSTICS

We have received a booking request with the following details. Provide your confirmation by clicking on the Yes button.

You confirm this booking? Yes No

Name : MR. JOSHI JIGAR RAMESHCHANDRA
Contact Details : 9825763758
Hospital Package Name : Mediwheel Full Body Health Checkup Female Above 40
Location : L-86 Swatantra - Senani Nagar , Opp- Akhbarnagar Bus Terminals, New Wadaj , Ahmedabad -13
Appointment Date : 13-04-2024

Member Information

Booked Member Name	Age	Gender
Parul jigar joshi	53 year	Female

Tests included in this Package -

- Mammography
- Stool Test
- Gynae Consultation
- Thyroid Profile
- ESR
- Blood Glucose (Fasting)
- General Physician Consultation
- TMT OR 2D ECHO
- Blood Group
- Blood Glucose (Post Prandial)
- Chest X-ray
- ECG
- USG Whole Abdomen
- Eye Check-up consultation
- Urine Sugar Fasting
- Urine Sugar PP
- Dental Consultation
- Urine analysis
- CBC
- Lipid Profile

- **Kidney Profile**
- **Liver profile**

Thanks,
Mediwheel Team

Please Download Mediwheel App



You have received this mail because your e-mail ID is registered with **Arcofemi Healthcare Limited** This is a system-generated e-mail please don't reply to this message.

Please visit to our Terms & Conditions for more informaion. Click here to unsubscribe.

@ 2024 - 25, Arcofemi Healthcare Pvt Limited.(Mediwheel)



ભારત સરકાર

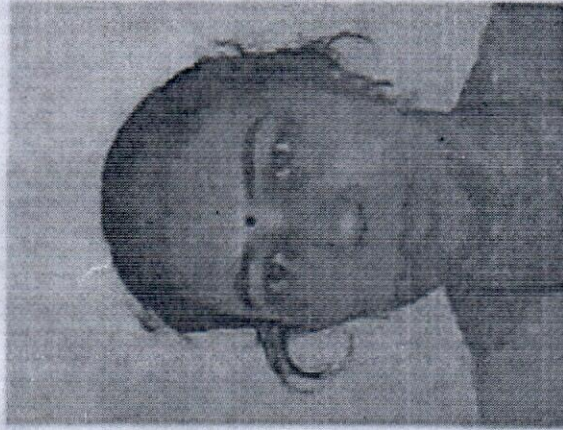
Government of India

પારુલબેન જીગરભાઈ જોશી

Parulben Jigarbhai Joshi

જન્મ તારીખ / DOB : 14/03/1971

સ્ત્રી / Female




3260 8856 4566

મારો આધાર, મારી ઓળખ

P.J.Joshi

Vidhi Diagnostics
L-86, Swatantra-Senani Nagar,
Nr. Akhbarnagar Bus Terminals
Nr. Akhbarnagar Circle,
New Wadaj, Ahmedabad-43.

Parul



 **GPS Map Camera**

Ahmedabad, Gujarat, India

15, Pragatinagar, Nirnay Nagar, Ahmedabad, Gujarat 380061, India

Lat 23.068092°

Long 72.56168°

13/04/24 09:34 AM GMT +05:30



Vidhi Diagnostics
L-86, Swatantra-Senani Nagar,
Nr. Akhbarnagar Bus Terminal
Nr. Akhbarnagar Circle,
New Wadaj, Ahmedabad-13.

Dr. Dinesh S. Modh

M.D., D.M.R.E. (Radiodiagnosis)

Consultant Radiologist & Sonologist

Ex. Junior Lecturer, B.J. Medical College, Civil Hospital, A'bad.



13/01/2021

NAME: Parulben Jigarabhai Joshi

AGE: 53

MEDICAL EXAMINATION:-

HEIGHT: 156 **WEIGHT:** 65

BP: 130/90 mm Hg. **PULSE:** 54 Per min

SPO2: 99 **TEMPERATURE:** Normal

RS: (N) **CVS:** (N)

ASYMPTOMATIC

HISTORY: H/O HTN since 10y2 Tab UTL 60. 1-0-0
NO H-O DM, Thyroid OR TB

<u>EYE CHECK-UP:-</u>	<u>RIGHT</u>	<u>LEFT</u>
<u>DISTANCE:</u>	6/6 within normal limit	6/6 within normal limit
<u>NEAR:</u>	N/6 with Spects	N/6 with Spects
<u>COLOR VISION:</u>	Normal	Normal

DENTAL CHECK-UP: Oral Hygiene Normal.
No H/O Cavities & Carries is seen.

ADV: HE/SHE IS MEDICALLY FIT She is Physically Fit

Dr. Vidhi D. Modh
Reg. No. : 674540 MBBS

Vidhi Diagnostics
L-86, Swatantra-Senani Nagar,
Nr. Akhbarnagar Bus Terminals
Nr. Akhbarnagar Circle,
New Wadaj, Ahmedabad-13.

ISO 9001:2015 Certified Diagnostics Center
Vidhi Imaging Center

L-86, Swatantra Senani Nagar, Opp. Indian Oil Petrol Pump, Akhbarnagar Circle, Nava Vadaj, Ahmedabad - 380 013.

Phone : (Radiology) 079-2762 1406 | M. 98799 29406, 98250 09406 | Time (Radiology) : Mon. to Sat. 9 am to 2 pm, 5 to 9 pm, Sunday 9 am to 12 Noon
E-mail : vidhidiagnostics@gmail.com, Website : www.vidhidiagnostics.com

Multislice CT Scan | CBCT-Dental Scan | Live 3D-4D Sonography | Colour Doppler | Echo Cardiography | Interventional Radiology | Maxillofacial Radiology | Fetal Medicine
Digital X-Ray | Digital Mammography | Digital OPG/TMJ | ECG/TMT/PFT/EEG/EMG | Audiometry | Pathology Laboratory | Health Check Up Plans | Pre Employment Check Up

CT SCAN & CBCT FACILITY NOW AVAILABLE

HR : 54 bpm
 PR : 180 ms
 QRS : 88 ms
 QT/QTc : 430/406 ms
 P/QRS/T : 49/9/65 deg.
 RV5/SV1 : 2.239/-0.824 mv
 RV5+SV1 : 3.063 mv

ID: 13494
 Name: parulben jigarbhai joshi
 Age: 53yrs
 Sex: Female
 Hospital: **Dr. Ajinabhai Bhaskar**
 M.B.B.S., D. Cardio
 Reg. No.: G-45946

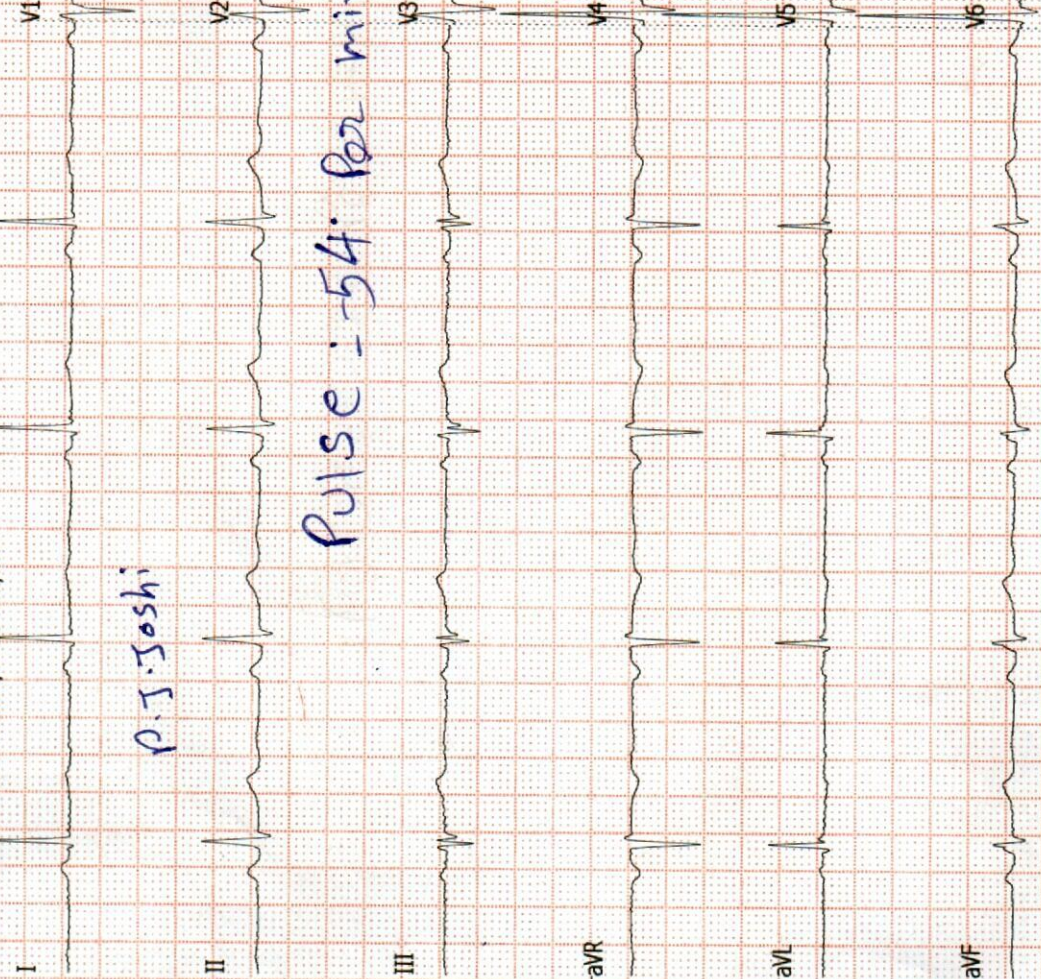
Nonspecific T wave abnormality

Vidhi Diagnostics

L-86, Swatantra-Senani Nagar,
 Nr. Akhbarnagar Bus Terminals

Nr. Akhbarnagar Circle,
 New Wadal Ahmedabad-13.
 Need to be confirmed by doctor. Doctor Name:

0.67Hz - 35Hz AC 50Hz 25 mm/s 10 mm/mv



Dr. Dinesh S. Modh

M.D., D.M.R.E. (Radiodiagnosis)
Consultant Radiologist & Sonologist
Ex. Junior Lecturer, B.J. Medical College, Civil Hospital, A'bad.
Panel Doctor of L.I.C.



Patient's name : PARULBEN JIGARBHAI JOSHI
Reg. ID : R-548-23
Referred by : MEDI WHEEL

Age/Sex : 53 Years/Male
Accession : 26047
Date : 13/04/2024

2D- ECHO REPORT

FINAL CONCLUSION:

LV IS NORMAL SIZE. GOOD LV SYSTOLIC FUNCTION NO RWMA.
LVEF - 60%. MILD CONCENTRIC LVH.
NORMAL LV COMPLANCE.
LA IS NORMAL SIZE. NO LA CLOT.
RV IS NORMAL SIZE. GOOD RV SYSTOLIC FUNCTION.
RA IS NORMAL SIZE.
MITRAL VALVE IS NORMAL. NO MS. MILD MR (15%). NO MVP.
AORTIC VALVE IS NORMAL. NO AS. NO AR.
TRICUSPID VALVE IS NORMAL. MILD TR. RVSP-29 mmHg. NO PAH.

NO CLOT, NO VEGETATION, NO PERICARDIAL EFFUSION.

DIMENSIONS:

AORTA	2.8 C.M
LEFT ATRIUM	2.7 C.M
LVDD	4.4 C.M.
IVSD	1.1 C.M
PWD	1.1 C.M
LVDS	2.6 C.M.

COLOUR DOPPLER FINDING:

STRUCTURE	VELOCITY m/sec
	Max
PULMONARY VALVE	0.7
MITRAL VALVE	E : 0.7 A: 0.4
AORTIC VALVE	1.0

Avinash
Dr. Avinash Bhaskar
MBBS. D Cardio
Reg. No. : G-45946
DR AVINASH BHASKAR
CLINICAL CARDIOLOGIST
9924836431

ISO 9001:2015 Certified Diagnostics Center

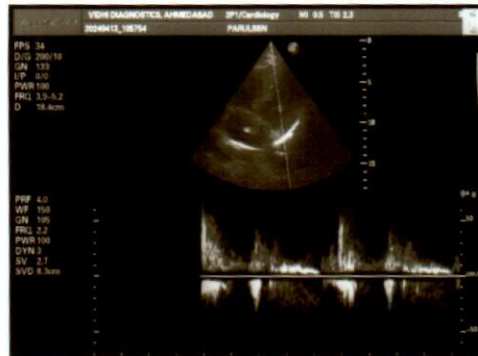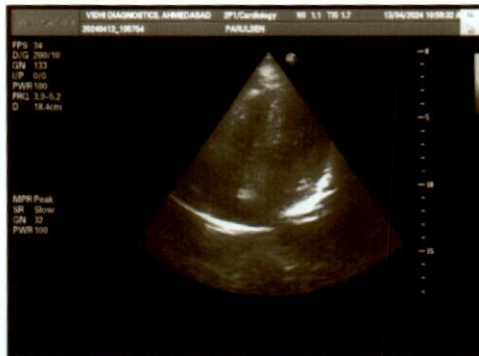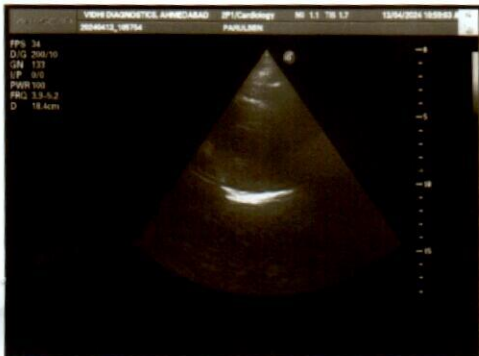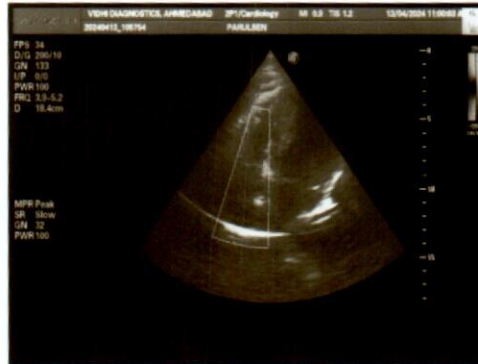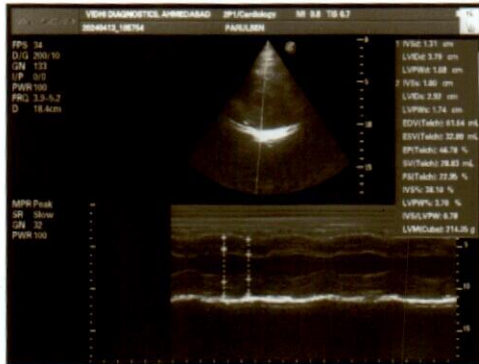
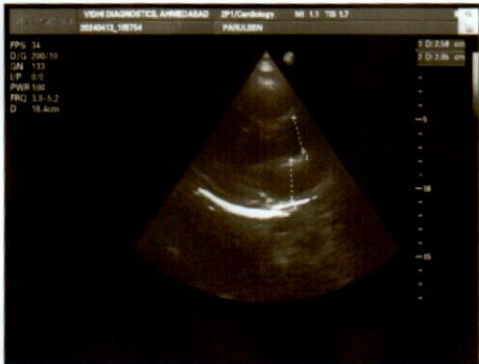Vidhi Imaging Center

L-86, Swatantra Senani Nagar, Opp. Akhbarnagar Petrol Pump, Nr. Akhbarnagar Circle, Nava-Vadaj, Ahmedabad - 380 013.

Phone : 079-2762 1406, Mobile : 98799 29406, 98250 09406, E-mail : vidhidiagnostics@gmail.com, Website : www.vidhidiagnostics.com

Time : Mon. to Sat. 9.00 am to 2.00 pm, 5.00 pm to 9.00 pm, Sunday 9.00 am to 12.00 Noon

FACILITIES : Live 3D-4D Sonography | Colour Doppler | Echo Cardiography | Interventional Radiology | Fetal Medicine | Digital X-Ray
Digital Mammography | Digital OPG / TMJ | ECG / TMT / PFT / EEG / EMG | Pathology Laboratory | Health Check Up Plans | Pre Employment Check Up



Dr. Dinesh S. Modh

M.D., D.M.R.E. (Radiodiagnosis)

Consultant Radiologist & Sonologist

Ex. Junior Lecturer, B.J. Medical College, Civil Hospital, A'bad.

Panel Doctor of L.I.C.

VIDHI
DIAGNOSTICS



Patient's name: PARULBEN JIGARBHAI JOSHI
Reg. ID : R-548-23
Referred by : MEDI WHEEL

Age/Sex : 53 Years/Male
Accession : 26047
Date : 13/04/2024

USG ABDOMEN

LIVER:- Liver appears normal in size & show normal echo texture. No evidence of diffuse or focal lesion is seen. IHBR appear normal. Portal vein and CBD appear normal. No e/o calculus is seen in bile duct.

GALL BLADDER:- Gall bladder is distended & appears normal. No evidence of calculus or cholecystitis is seen.

SPLEEN:- Spleen appears normal in size & shows normal echo texture. No evidence of diffuse or focal lesion is seen.

PANCREAS:- Pancreas appears normal size and echo pattern. No e/o diffuse or focal lesion is seen. Main pancreatic duct appears normal.

KIDNEY:- Both Kidneys appear normal in size & echo texture.
No e/o hydronephrosis/ hydroureter or calculus is seen on both sides.
Cortico-medullary differentiation is maintained on either side.
Both suprarenal regions appear normal.
No evidence of pre & para aortic lymphadenopathy is seen.

RIF & BOWEL LOOPS (By high frequency probe):- Normal.
No evidence of free fluid is seen in abdomen.
No evidence of dilated or thickened bowel loops is seen.

Urinary bladder:- appears normal. No e/o calculus or mass lesion is seen.
Both adnexal regions appear normal.
No e/o free fluid is seen in pouch of Douglas.

Thanks for reference.


Dr. Dinesh S. Modh
MD DMRE (Radiodiagnosis)
G-23825
DR DINESH S. MODH
M.D. DMRE(RADIODIAGNOSIS)

ISO 9001:2015 Certified Diagnostics Center

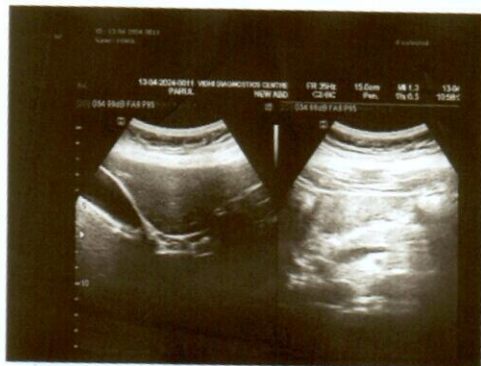
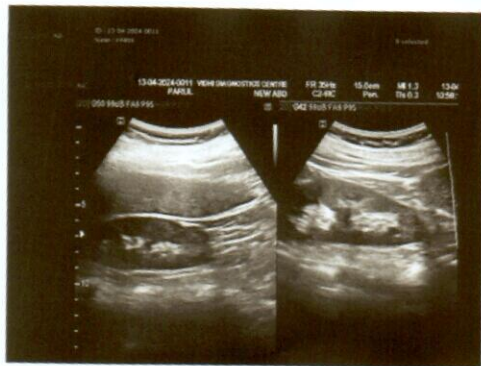
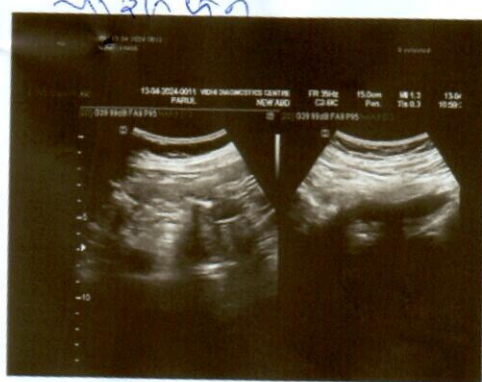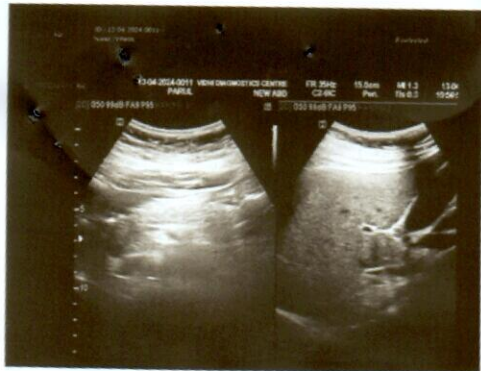
Vidhi Imaging Center

L-86, Swatantra Senani Nagar, Opp. Akhbarnagar Petrol Pump, Nr. Akhbarnagar Circle, Nava-Vadaj, Ahmedabad - 380 013.

Phone : 079-2762 1406, Mobile : 98799 29406, 98250 09406, E-mail : vidhidiagnostics@gmail.com, Website : www.vidhidiagnostics.com

Time : Mon. to Sat. 9.00 am to 2.00 pm, 5.00 pm to 9.00 pm, Sunday 9.00 am to 12.00 Noon

FACILITIES : Live 3D-4D Sonography | Colour Doppler | Echo Cardiography | Interventional Radiology | Fetal Medicine | Digital X-Ray
Digital Mammography | Digital OPG / TMJ | ECG / TMT / PFT / EEG / EMG | Pathology Laboratory | Health Check Up Plans | Pre Employment Check Up



Dr. Dinesh S. Modh

M.D., D.M.R.E. (Radiodiagnosis)

Consultant Radiologist & Sonologist

Ex. Junior Lecturer, B.J. Medical College, Civil Hospital, A'bad.

Panel Doctor of L.I.C.




Patient's name: PARULBEN JIGARBHAI JOSHI
Reg. ID : R-548-23
Referred by : MEDI WHEEL

Age/Sex : 53 Years/Male
Accession : 26047
Date : 13/04/2024

X-RAY CHEST (PA VIEW)

Both lung fields appear normal.
No e/o consolidation or cavitation is seen.
Both costo-phrenic angles appear clear.
Cardiomegaly is noted in transverse diameter.
Both domes of diaphragm appear normal.
Bony thoracic cage appears normal.

Thanks for reference.


Dr. Dinesh S. Modh
MD DMRE (Radiodiagnosis)
G-23825
DR DINESH S. MODH
M.D. DMRE(RADIODIAGNOSIS)

ISO 9001:2015 Certified Diagnostics Center

Vidhi Imaging Center

L-86, Swatantra Senani Nagar, Opp. Akhbarnagar Petrol Pump, Nr. Akhbarnagar Circle, Nava-Vadaj, Ahmedabad - 380 013.

Phone : 079-2762 1406, Mobile : 98799 29406, 98250 09406, E-mail : vidhidiagnostics@gmail.com, Website : www.vidhidiagnostics.com

Time : Mon. to Sat. 9.00 am to 2.00 pm, 5.00 pm to 9.00 pm, Sunday 9.00 am to 12.00 Noon

FACILITIES : Live 3D-4D Sonography | Colour Doppler | Echo Cardiography | Interventional Radiology | Fetal Medicine | Digital X-Ray
Digital Mammography | Digital OPG / TMJ | ECG / TMT / PFT / EEG / EMG | Pathology Laboratory | Health Check Up Plans | Pre Employment Check Up

Dr. Dinesh S. Modh

M.D., D.M.R.E. (Radiodiagnosis)

Consultant Radiologist & Sonologist

Ex. Junior Lecturer, B.J. Medical College, Civil Hospital, A'bad.

Panel Doctor of L.I.C.



Patient's name: PARULBEN JIGARBHAI JOSHI

Reg. ID : R-548-23

Referred by : MEDI WHEEL

Age/Sex : 53 Years/Male

Accession : 26047

Date : 13/04/2024

DIGITAL MAMMOGRAPHY

Digital mammography was done on Siemens mammomat-3000.

Reason for exam: - Screening.

Bilateral digital cranio-caudal and medio-lateral oblique views were taken. The breast tissue is homogeneously dense with fibro-fatty tissue on both sides. No masses, no architectural distortion, no suspicious calcifications, no asymmetries or other abnormalities are seen.

No e/o radio-opaque or radiolucent mass lesion is seen.

No e/o skin thickening is seen.

Nipple and sub-areolar tissue appear normal.

Axillary tail appears normal.

USG:-Normal.

Assessment:-Negative (BI-RADS category-1)

BI-RADS category

- 0- incomplete
- 1- Negative
- 2- Benign
- 3- Probably benign
- 4- Suspicious abnormality.
- 5- Highly suggestive of malignancy
- 6- Known biopsy-proven malignancy.

The false negative mammography is approximately 10%. Management of palpable abnormality must be based upon clinical grounds.

Thanks for reference.

Dr. Dinesh S. Modh

MD DMRE (Radiodiagnosis)

DR DINESH S. MODH

M.D. DMRE(RADIODIAGNOSIS)

ISO 9001:2015 Certified Diagnostics Center

Vidhi Imaging Center

L-86, Swatantra Senani Nagar, Opp. Akhbarnagar Petrol Pump, Nr. Akhbarnagar Circle, Nava-Vadaj, Ahmedabad - 380 013.

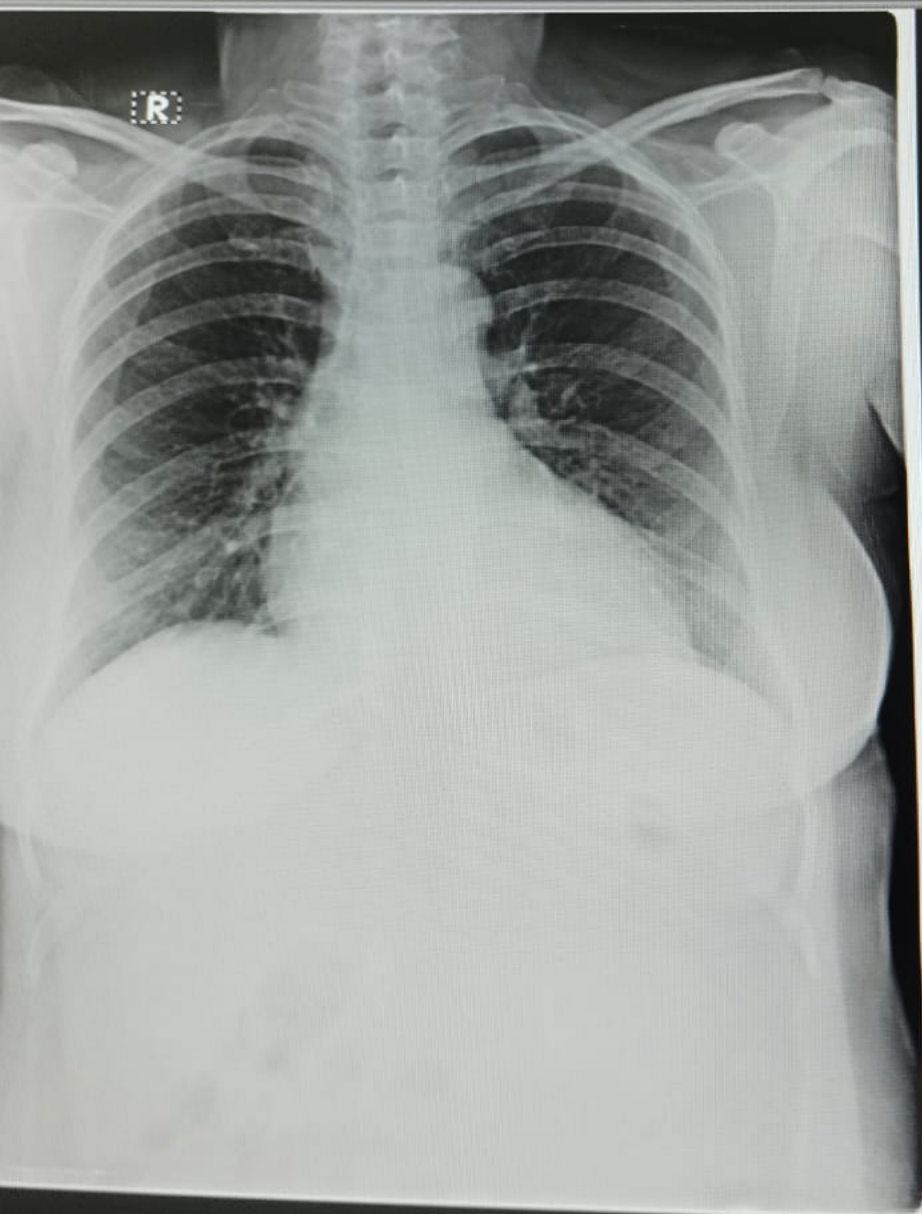
Phone : 079-2762 1406, Mobile : 98799 29406, 98250 09406, E-mail : vidhidiagnostics@gmail.com, Website : www.vidhidiagnostics.com

Time : Mon. to Sat. 9.00 am to 2.00 pm, 5.00 pm to 9.00 pm, Sunday 9.00 am to 12.00 Noon

FACILITIES : Live 3D-4D Sonography | Colour Doppler | Echo Cardiography | Interventional Radiology | Fetal Medicine | Digital X-Ray
Digital Mammography | Digital OPG/TMJ | ECG/TMT/PFT/EEG/EMG | Pathology Laboratory | Health Check Up Plans | Pre Employment Check Up

TMT, ECG, ECHO
LAB
OPG & MAMMO
X - Ray
PICK UP
TRANSFER
PHONE
RECALL

4
PARUL JOSHI 53YEAR


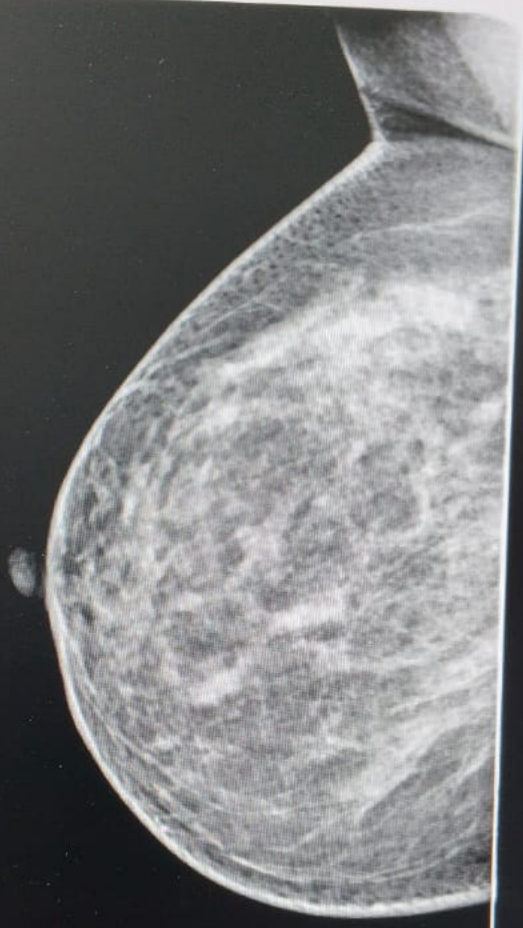


X - P001
PICK UP
TRANSFER
PHONE
RETAIL

42404

PARUL JOSHI 53YEAR

L

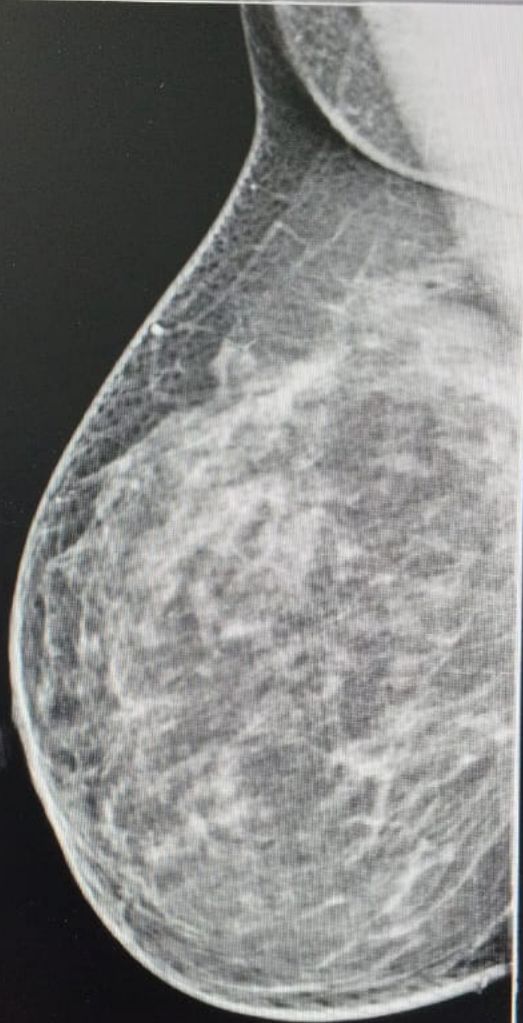

PICK UP
TRANSFER
PHONE
REDAIL

42404

PARUL JOSHI 53YEAR

R



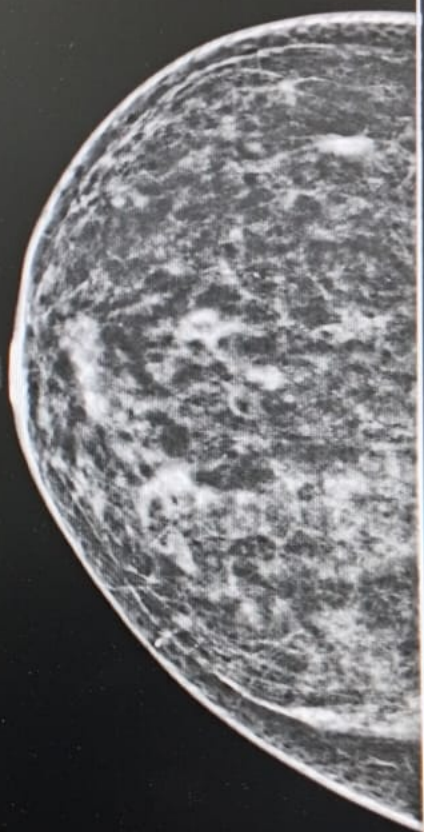
3 (6) [Play] [Close] [Magnify] [ALL] [Key]

LAB
OPG & MAMMO
X - Ray
PICK UP
TRANSFER
PHONE
RETAIL


13042404

PARUL JOSHI 53YEAR

R
L



2
(6)



ALL



LAB _____
OPG & MAMMO _____
X - Ray _____
PICK UP _____
TRANSFER _____
PHONE _____
RETAIL _____

PARUL JOSHI 53YEAR

R

