

Patient Name : Mr. AJAY KUMAR GADDAM
UHID : CKOR.0000252976
Conducted By: :
Referred By : SELF

Age : 43 Y/M
OP Visit No : CKOROPV405301
Conducted Date : 09-04-2024 15:44

Original OP Credit Bill

Name : Mr. AJAY KUMAR GADDAM
Age/Gender : 38 Y M
Contact No : +919986840407
Address : kmg
UHID : CKOR.0000252976

Bill No : CKOR-OCR-81846
Bill/Reg Date : 29.03.2024 08:35
Referred by : SELF
Center : Koramangala
Emp No/Auth Code : bobS18692



CKOR.0000252976

Corporate Name : ARCOFEMI HEALTHCARE LIMITED
Plan : ARCOFEMI MEDIWHEEL MALE AHC CREDIT PAN INDIA OP AGREEMENT

#	Department	Service Name	Qty	Rate	Discount	Amount
1	Package Charges	ARCOFEMI - MEDIWHEEL - FULL BODY ANNUAL PLUS ABOVE 50Y MALE - 2D ECHO - PAN INDIA - FY2324	1	2,300.00	0.00	2,300.00

Bill Amount: 2,300.00
Total Discount: 0.00
Net Payment: 0.00
Corporate Due: 2,300.00

Received with thanks: Zero Rupees only

Authorized Signature :(Tejaswini M)

प्रति,

समन्वयक,
Mediwheel (Arcofemi Healthcare Limited)
हेल्पलाइन नंबर: 011-41195959

महोदय/ महोदया,

विषय: बैंक ऑफ़ बड़ौदा के कर्मचारियों के लिए वार्षिक स्वास्थ्य जांच।

हम आपको सूचित करना चाहते हैं कि हमारे कर्मचारी की पत्नी/पति जिनके विवरण निम्नानुसार हैं हमारे करार के अनुसार आपके द्वारा उपलब्ध कराई गई कैशलेस वार्षिक स्वास्थ्य जांच सुविधा का लाभ लेना चाहते हैं।

स्वास्थ्य जांच लाभार्थी के विवरण	
नाम	AJAY KUMAR GADDAM
जन्म की तारीख	17-04-1981
कर्मचारी की पत्नी/पति के स्वास्थ्य जांच की प्रस्तावित तारीख	29-03-2024
बुकिंग संदर्भ सं.	23M160835100105522S
पत्नी/पति के विवरण	
कर्मचारी का नाम	MS. V KAVITHA
कर्मचारी की क.कू.संख्या	160835
कर्मचारी का पद	REGIONAL MERCHANT MANAGER
कर्मचारी के कार्य का स्थान	BENGALURU,RO BENGALURU CENTRAL
कर्मचारी के जन्म की तारीख	02-11-1985

यह अनुमोदन/ संस्तुति पत्र तभी वैध माना जाएगा जब इसे बैंक ऑफ़ बड़ौदा के कर्मचारी आईडी कार्ड की प्रति के साथ प्रस्तुत किया जाएगा। यह अनुमोदन पत्र दिनांक 25-03-2024 से 31-03-2024 तक मान्य है। इस पत्र के साथ किए जाने वाले चिकित्सा जांच की सूची अनुलग्नक के रूप में दी गई है। कृपया नोट करें कि उक्त स्वास्थ्य जांच हमारी टाई-अप व्यवस्था के अनुसार कैशलेस सुविधा है। हम अनुरोध करते हैं कि आप हमारे कर्मचारी के पत्नी/पति की स्वास्थ्य जांच संबंधी आवश्यकताओं पर उचित कार्रवाई करें तथा इस संबंध में अपनी सर्वोच्च प्राथमिकता तथा सर्वोत्तम संसाधन उपलब्ध कराएं। उपर्युक्त सारणी में दी गई कर्मचारी कूट संख्या एवं बुकिंग संदर्भ संख्या का उल्लेख अनिवार्य रूप से इनवॉइस में किया जाना चाहिए।

हम इस संबंध में आपके सहयोग की अपेक्षा करते हैं।

भवदीय,

हस्ता/-

(मुख्य महाप्रबंधक)

मानव संसाधन प्रबंधन विभाग

बैंक ऑफ़ बड़ौदा

(नोट: यह कंप्यूटर द्वारा जनरेट किया गया पत्र है। हस्ताक्षर की आवश्यकता नहीं है। कृपया किसी भी स्पष्टीकरण के लिए Mediwheel (Arcofemi Healthcare Limited)से संपर्क करें।)

SUGGESTIVE LIST OF MEDICAL TESTS

FOR MALE	FOR FEMALE
CBC	CBC
ESR	ESR
Blood Group & RH Factor	Blood Group & RH Factor
Blood and Urine Sugar Fasting	Blood and Urine Sugar Fasting
Blood and Urine Sugar PP	Blood and Urine Sugar PP
Stool Routine	Stool Routine
Lipid Profile	Lipid Profile
Total Cholesterol	Total Cholesterol
HDL	HDL
LDL	LDL
VLDL	VLDL
Triglycerides	Triglycerides
HDL / LDL ratio	HDL / LDL ratio
Liver Profile	Liver Profile
AST	AST
ALT	ALT
GGT	GGT
Bilirubin (total, direct, indirect)	Bilirubin (total, direct, indirect)
ALP	ALP
Proteins (T, Albumin, Globulin)	Proteins (T, Albumin, Globulin)
Kidney Profile	Kidney Profile
Serum creatinine	Serum creatinine
Blood Urea Nitrogen	Blood Urea Nitrogen
Uric Acid	Uric Acid
HBA1C	HBA1C
Routine urine analysis	Routine urine analysis
USG Whole Abdomen	USG Whole Abdomen
General Tests	General Tests
X Ray Chest	X Ray Chest
ECG	ECG
2D/3D ECHO / TMT	2D/3D ECHO / TMT
Stress Test	Thyroid Profile (T3, T4, TSH)
PSA Male (above 40 years)	Mammography (above 40 years) and Pap Smear (above 30 years).
Thyroid Profile (T3, T4, TSH)	Dental Check-up consultation
Dental Check-up consultation	Physician Consultation
Physician Consultation	Eye Check-up consultation
Eye Check-up consultation	Skin/ENT consultation
Skin/ENT consultation	Gynaec Consultation



ಅಧಿಕಾರ




ಅಜಯ್ ಕುಮಾರ್ ಗಡ್ಡಮ್

Ajay Kumar Gaddam

ಜನ್ಮ ದಿನಾಂಕ / DOB: 17/04/1981

ಪುರುಷ / MALE



9769 8874 8237

आधार - आम आदमी का अधिकार

42

Name : Mr. AJAY KUMAR GADDAM

Age: 38 Y

UHID:CKOR.0000252976

Sex: M



Address : kmg

OP Number:CKOROPV405301

Plan : ARCOFEMI MEDIWHEEL MALE AHC CREDIT PAN
INDIA OP AGREEMENT

Bill No :CKOR-OCR-81846

Date : 29.03.2024 08:35

Sno	Service Type/ServiceName	Department
1	ARCOFEMI - MEDIWHEEL - FULL BODY ANNUAL PLUS ABOVE 50Y MALE - 2D ECHO - PAN INDIA - FY2324	
✓1	GAMMA GLUTAMYL TRANSFERASE (GGT)	
✓2	PROSTATIC SPECIFIC ANTIGEN (PSA TOTAL)	
✓3	2D ECHO → (16)	
✓4	LIVER FUNCTION TEST (LFT)	
✓5	GLUCOSE, FASTING	
✓6	HEMOGRAM + PERIPHERAL SMEAR	
7	DIET CONSULTATION	
✓8	COMPLETE URINE EXAMINATION	
9	URINE GLUCOSE(POST PRANDIAL)	
✓10	PERIPHERAL SMEAR	
✓11	ECG	
✓12	RENAL PROFILE/RENAL FUNCTION TEST (RFT/KFT)	
13	DENTAL CONSULTATION → (15)	
✓14	GLUCOSE, POST PRANDIAL (PP), 2 HOURS (POST MEAL)	
✓15	URINE GLUCOSE(FASTING)	
✓16	HbA1c, GLYCATED HEMOGLOBIN	
✓17	X-RAY CHEST PA → (11)	
18	ENT CONSULTATION → (23) (11)	
19	FITNESS BY GENERAL PHYSICIAN	
✓20	BLOOD GROUP ABO AND RH FACTOR	
✓21	LIPID PROFILE	
22	BODY MASS INDEX (BMI)	
✓23	OPHTHAL BY GENERAL PHYSICIAN →	
✓24	ULTRASOUND - WHOLE ABDOMEN	
✓25	THYROID PROFILE (TOTAL T3, TOTAL T4, TSH)	

✓26) physio - 17

✓27) Audiometry - 19 (17)

Room No. 18.30 Am
Room No. 11
Room No. 19.00 pm
Room No. 19

WT - 85.6 kg
HT - 185 cm
BP ⇒ 112/69 mmHg
P-88 bpm

Get a complimentary dental screening
Get a complimentary eye check Opp. to
Avail a complimentary session with physiotherapist
Get a complimentary hearing check

✓ TMT

NAME: Mr. AJAY KUMAR GADDAM

AGE: 38Y

SEX: MALE

DATE: 29/03/2024

ECHOCARDIOGRAPHY REPORT

MEASUREMENT

AO - 28(20 - 35)mm	LIVD d -47(36-52)mm	IVS - 10(06 - 11)mm
LA -21(19- 40)mm	LVID s -32(23- 39)mm	PWD -11(06- 11)mm
EF - 60 (>50%)	RVID-24	

VALVES

Mitral Valve : Normal ,
Aortic Valve : NORMAL,
Tricuspid Valve : Normal, TRIVIAL TR, RVSP - 20 mmHG
Pulmonary Valve : Normal,

CHAMBERS

Left Atrium : Normal
Right Atrium : Normal
Left Ventricle : Normal ,
Right Ventricle : Normal

SEPTAE

IVS : Intact
IAS : Intact

GREAT ARTERIES

Aorta : Normal
Pulmonary Artery : Normal

DOPPLER DATA


Mitral : E > A , 0.8 / 0.5
Aortic : Normal , 1.0 m/s
Tricuspid : Normal , 0.4 / 0.6
Pulmonary : Normal, 1.10

WALL MOTION ABNORMALITIES : No RWMA

Pericardium : Normal

FINAL DIAGNOSIS

**NORMAL CHAMBERS AND VALVES
NO RWMA AT REST, LV EF - 60 %
NORMAL DIASTOLIC FUNCTION
NO OBVIOUS CLOTS/ EFFUSION/ VEGETATION**



**DR. MOHAN MURALI
DNB(MED), DNB(CARDIOLOGY)
CONSULTANT CARDIOLOGIST**

Apollo Clinic

Consent Form

Patient Name: AJAY GADDAW Age: 42

UHID Number: Company Name: BOB

I Mr/Mrs/Miss: Ajay Gaddam Employee of BOB (Spouse)

(Company) want to inform you that I am not getting the BNT

Test which is a part of health check package.

Reason If any:

And I claim the above statement in my full consciousness.

Patient Signature: [Signature] Date: 25-3-2024

OPHTHAL REPORT

NAME: Alax Kumar Raddam

AGE: 42 GENDER: MALE/FEMALE

RIGHT EYE

	SPH	CYL	AXIS	VA
DV	-3.50	—	—	6/6
NV	+1.00	—	—	NS

LEFT EYE

	SPH	CYL	AXIS	VA
DV	-3.50	—	—	6/6
NV	+1.00	—	—	NS

REMARK: psog with blue black lens

DATE: 29/03/24

cho
OPTOMETRIST

BRING THIS PRESCRIPTION IN YOUR NEXT VISIT

Patient Name : Mr. Ajay Kumar Gaddam

Patient ID : 252976

Age : 42 Year(s)

Sex : Male

Referring Doctor : H/C

Date : 29.03.2024

ULTRASOUND ABDOMEN AND PELVIS

FINDINGS:

Liver is normal in size and shows normal echotexture. No biliary dilatation. No focal lesion
CBD is not dilated. **Portal vein** is normal in size, course and calibre.

Gall bladder is normal without evidence of calculi, wall thickening or pericholecystic fluid.

Pancreas to the extent visualized, appears normal in size, contour and echogenicity

Spleen is normal in size, shape, contour and echopattern. No evidence of mass or focal lesions.

Right Kidney is normal in size, position, shape and echopattern. Corticomedullary differentiation is maintained. No evidence of calculi or hydronephrosis.

Left Kidney is normal in size, position, shape and echopattern. Corticomedullary differentiation is maintained. No evidence of calculi or hydronephrosis.

Urinary Bladder is well distended. Wall thickness is normal. No evidence of calculi, mass or mural lesion.

Prostate: normal in size and echotexture.

There is no ascites.

IMPRESSION: NO SIGNIFICANT ABNORMALITIES DETECTED.

**DR VINOD JOSEPH DNB, DMRD
RADIOLOGIST**

Patient Name	: Mr. AJAY KUMAR GADDAM	Age	: 42 Y M
UHID	: CKOR.0000252976	OP Visit No	: CKOROPV405301
Reported on	: 29-03-2024 13:29	Printed on	: 29-03-2024 13:41
Adm/Consult Doctor	:	Ref Doctor	: SELF

DEPARTMENT OF RADIOLOGY

X-RAY CHEST PA

Both lungs fields appear normal.

Both hila are normal.

Both costophrenic and cardiophrenic angles are normal.


The cardiac mediastinal shadows appear normal.

Bones and soft tissues appear normal.

IMPRESSION : NORMAL STUDY.

Printed on:29-03-2024 13:29

---End of the Report---

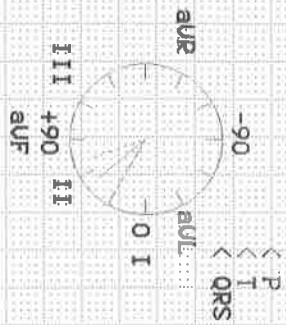

for **Dr. VINOD P JOSEPH**
MBBS, DNB, DMRD
Radiology

Male

AGE: 38

Measurement Results:

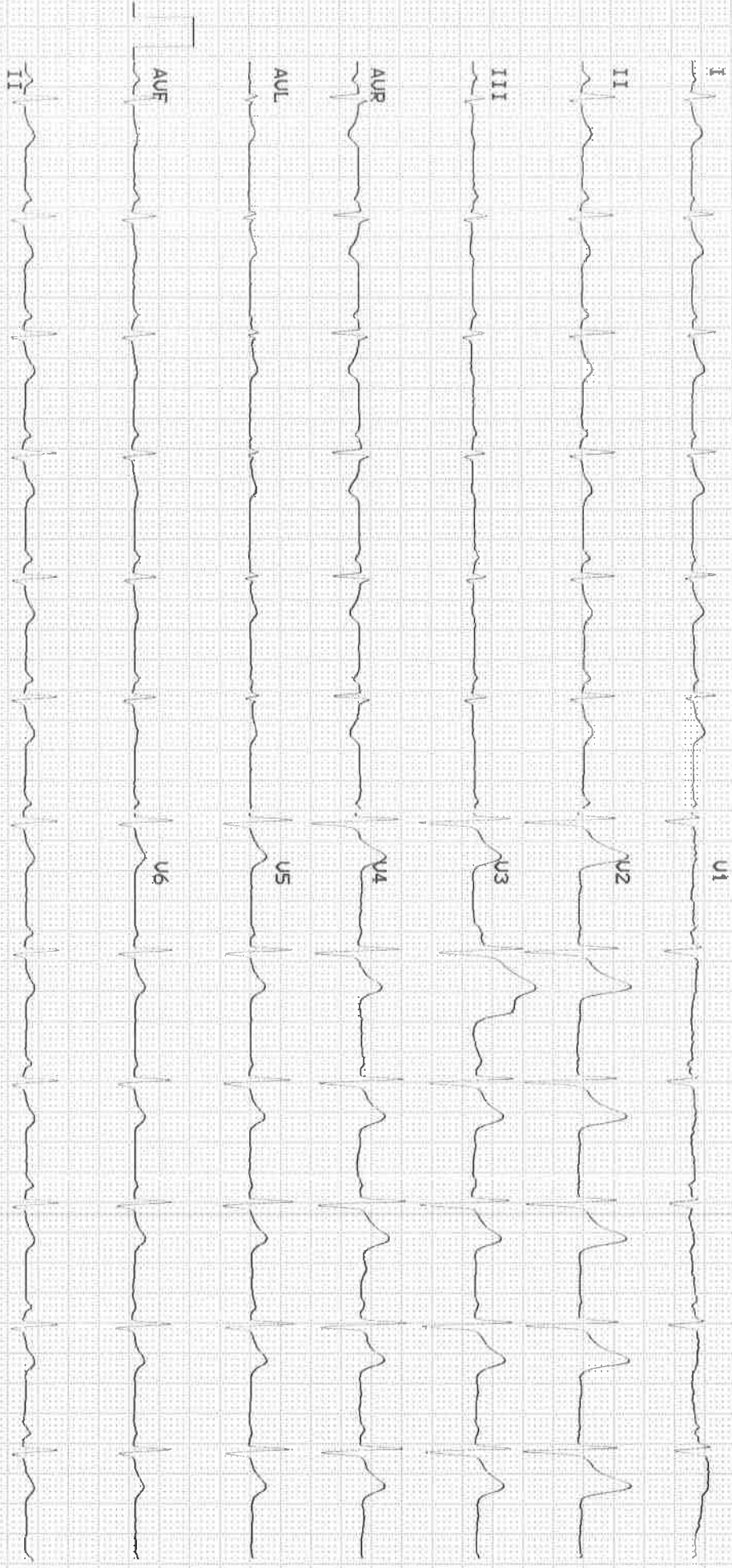
QRS	94 ms
QT/QTcB	392 / 434 ms
PR	144 ms
P	108 ms
PR/PP	816 / 800 ms
P/QRS/T	70 / 50 / 30 degrees
QTd/QTcBd	46 / 51 ms
Sokolow	1.0 mV
NK	10



Interpretation:

RSV

Unconfirmed report.



Patient Name	: Mr. AJAY KUMAR GADDAM	Age	: 42 Y/M
UHID	: CKOR.0000252976	OP Visit No	: CKOROPV405301
Reported By:	: Dr. MOHAN MURALI	Conducted Date	: 29-03-2024 11:54
Referred By	: SELF		

ECG REPORT

Observation :-

1. Normal Sinus Rhythm.
2. Heart rate is 73beats per minutes.
3. No pathological Q wave or S-T,T changes seen.
4. Normal P,Q,R,S,T waves and axis.
5. No evidence of chamber, hypertrophy or enlargement seen.

Impression:

NORMAL RESTING ECG.

Dr MOHAN MURALI
CARDIOLOGIST

NOTE:KINDLY TAKE A PHOTOCOPY OF THE GRAPH
FOR FUTURE REFERENCE IF NEEDED.

----- END OF THE REPORT -----

APOLLO MEDICAL CENTRE
KORAMANGALA
BANGALORE

Station
Telephone:

EXERCISE STRESS TEST REPORT

Patient Name: MR, AJAY KUMAR GADDAM
Patient ID: 252976
Height: 185 cm
Weight: 85.6 kg

DOB: 17.04.1981
Age: 42 yrs
Gender: Male
Race: Asian

Study Date: 29.03.2024
Test Type: --
Protocol: BRUCE
Medications:
NIL

Referring Physician: --
Attending Physician: --
Technician: AKHILA

Medical History:
NIL

Reason for Exercise Test:

--

Exercise Test Summary

Phase Name	Stage Name	Time in Stage	Speed [mph]	Grade [%]	HR [bpm]	BP [mmHg]	Comment
PRETEST	SUPINE	04:46	0.00	0.00	103	110/70	
	STANDING	00:04	0.00	0.00	98	110/70	
	HYPERV.	00:03	0.00	0.00	96	110/70	
	WARM-UP	00:06	0.00	0.00	96	110/70	
EXERCISE	STAGE 1	03:00	1.70	10.00	137	120/70	
	STAGE 2	02:05	2.50	12.00	162	130/70	
	STAGE 3	03:00	3.40	14.00	181	140/70	
	STAGE 4	00:37	4.20	16.00	190	150/70	
RECOVERY		03:04	0.00	0.00	129	140/70	1:48 No symptoms

The patient exercised according to the BRUCE for 8:41 min:s, achieving a work level of Max. METS: 12.10. The resting heart rate of 102 bpm rose to a maximal heart rate of 190 bpm. This value represents 106 % of the maximal, age-predicted heart rate. The resting blood pressure of 110/70 mmHg, rose to a maximum blood pressure of 160/70 mmHg. The exercise test was stopped due to Target heart rate achieved.

Interpretation

Summary: Resting ECG: normal.

Functional Capacity: normal.

HR Response to Exercise: appropriate.

BP Response to Exercise: NORMAL HR AND BP RESPONSE.

Chest Pain: none.

Arrhythmias: NO ANGINA OR ARRHYTHMIA.

ST Changes: NO SIGNIFICANT ST DEPRESSION DURING EXC AND REC.

Overall impression: GOOD EFFORT TOLERANCE.

Conclusions

STRESS TEST NEGATIVE FOR INDUCIBLE ISCHEMIA

Physician _____

Technician _____

M.R, AJAY KUMAR GADDAM

Patient ID: 252976

29.03.2024 Male 185 cm 85.6 kg

11:49:00am 42 yrs Asian

Exercise Test / Linked Medians

PRETEST

SUPINE

04:33

BRUCE

0.0 mph

0.0 %

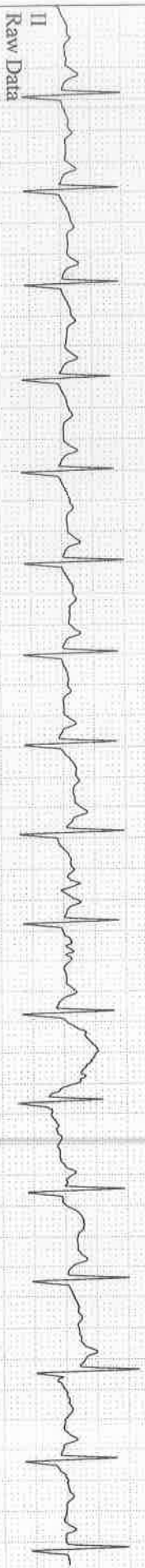
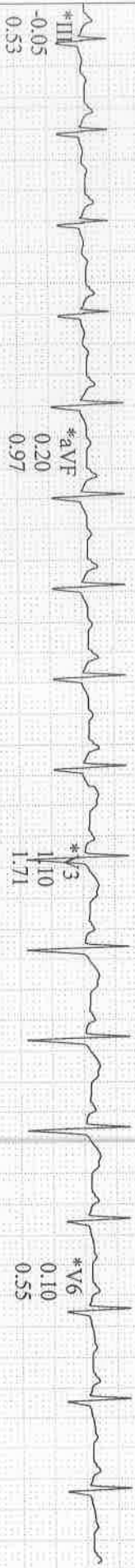
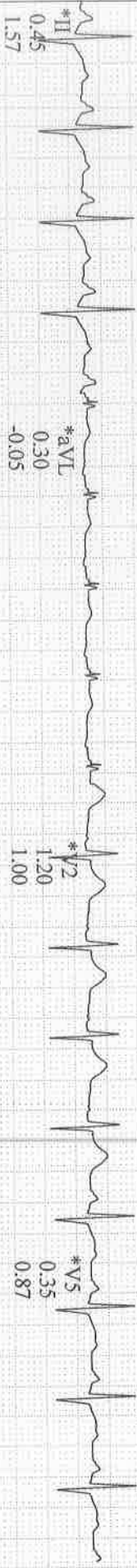
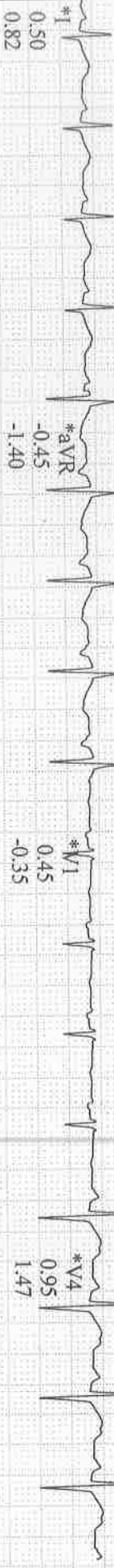
APOLLO MEDICAL CENTRE

Lead

ST Level (mm)

ST Slope (mV/s)

102 bpm



*Computer Synthesized Rhythms

GE CardioSoft V7.0 (10)
25 mm/s 10 mm/mV 50 Hz 0.05Hz FRR+ HR(V3,II)

Start of Test: 11:44:27am

MR, AJAY KUMAR GADDAM

Patient ID: 252976

29.03.2024 Male 185 cm 85.6 kg

11:52:15am 42 yrs Asian

Exercise Test / Linked Medians

EXERCISE

STAGE 1

136 bpm

120/70 mmHg

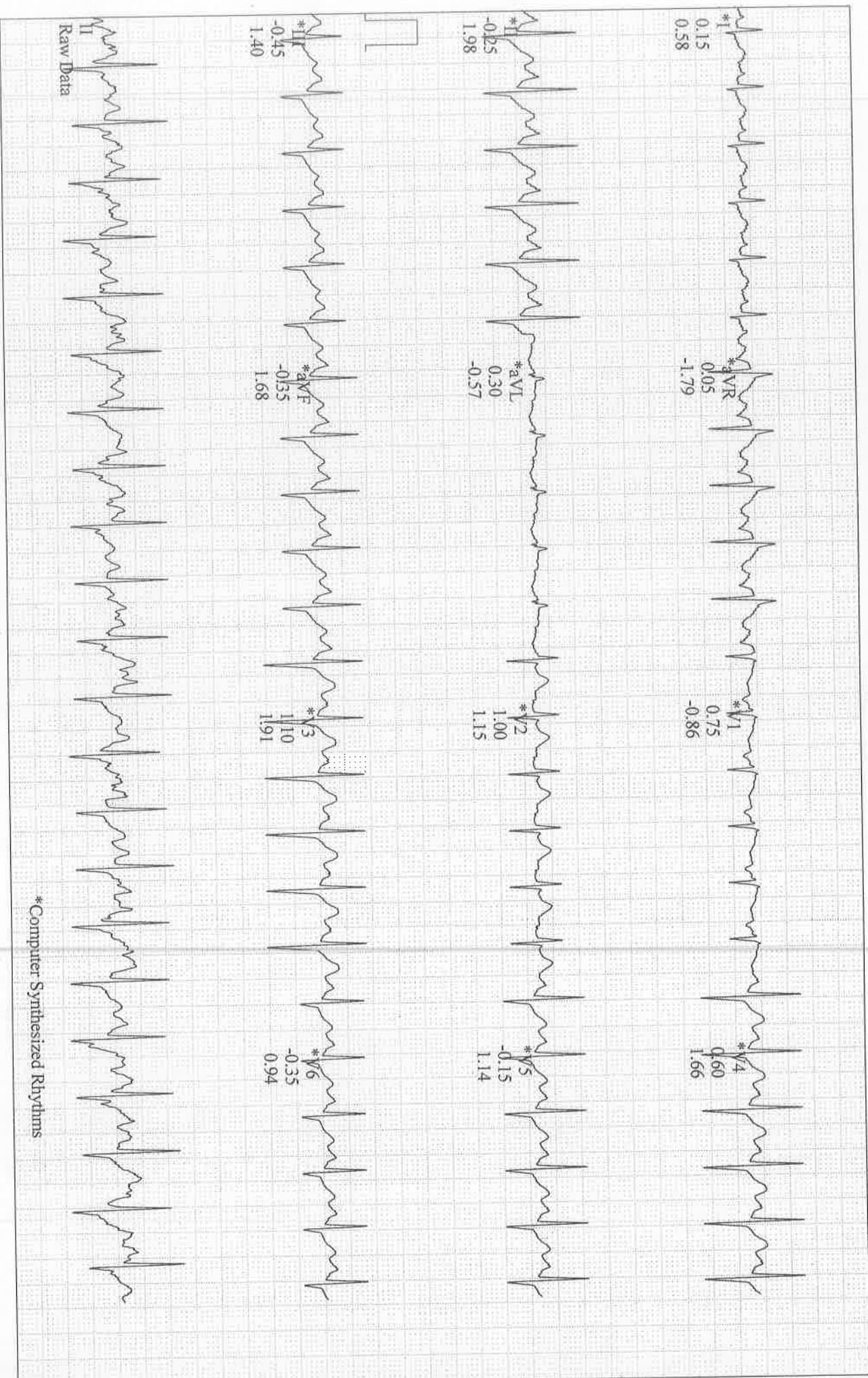
BRUCE

1.7 mph

10.0 %

APOLLO MEDICAL CENTRE

Lead
ST Level (mm)
ST Slope (mV/s)



*Computer Synthesized Rhythms

MR, AJAY KUMAR GADDAM

Patient ID: 252976

29.03.2024 Male 185 cm 85.6 kg

11:54:29am 42 yrs Asian

Exercise Test / Linked Medians

EXERCISE

STAGE 2

05:03

APOLLO MEDICAL CENTRE

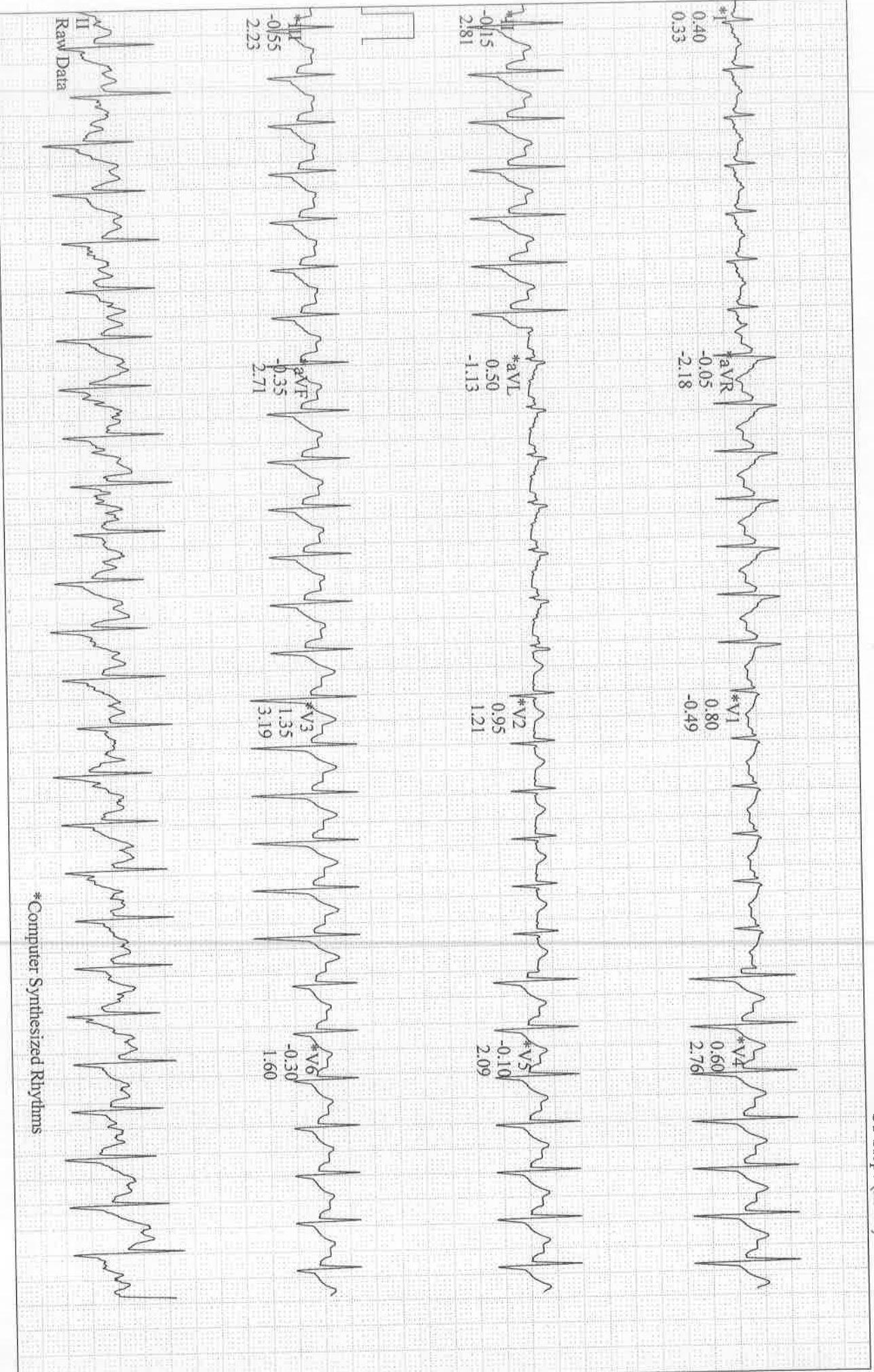
BRUCE

2.5 mph

12.0%

162 bpm
130/70 mmHg

Lead
ST Level (mm)
ST Slope (mV/s)



*Computer Synthesized Rhythms

Raw Data

GE CardioSoft V7.0 (10)
25 mm/s 10 mm/mV 50 Hz 0.05Hz FRR+ HR(V3,II)

Start of Test: 11:44:27am

MR, AJAY KUMAR GADDAM

Patient ID: 252976

29.03.2024 Male 185 cm 85.6 kg

11:57:19am 42 yrs Asian

Exercise Test / Linked Medians

EXERCISE

STAGE 3

07:54

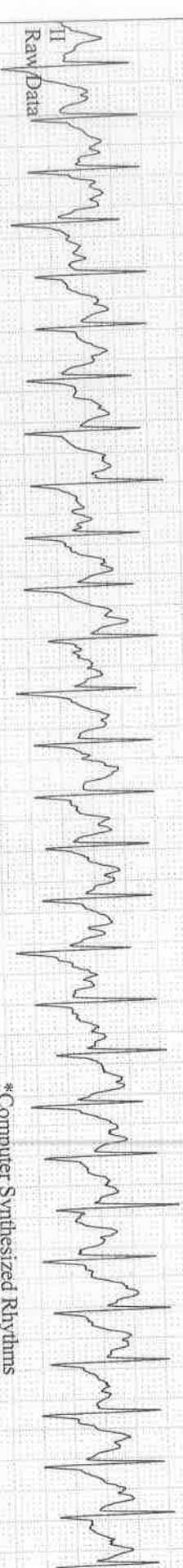
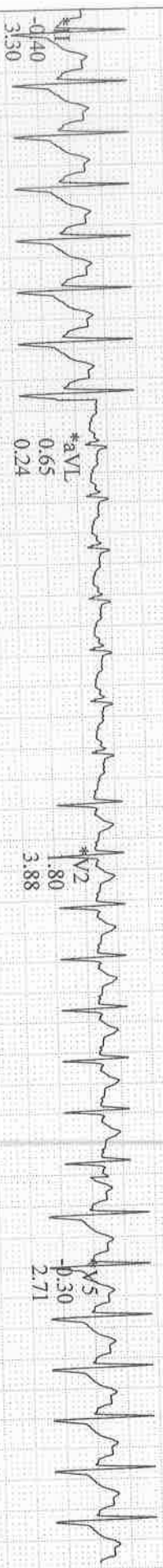
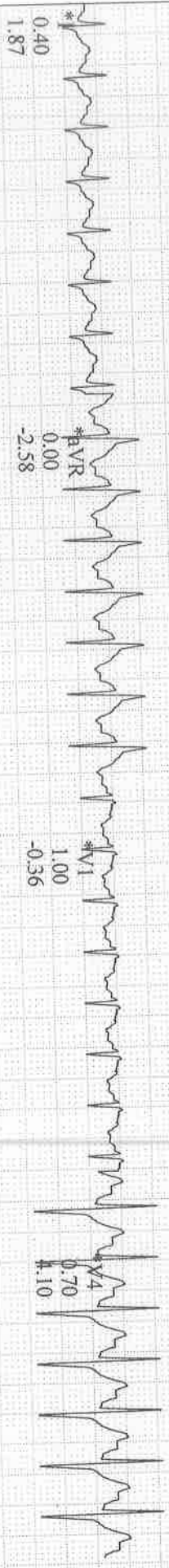BRUCE

3.4 mph

14.0 %

APOLLO MEDICAL CENTRE

Lead ' ' ST Level (mm) ST Slope (mV/s)



MR, AJAY KUMAR GADDAM

Patient ID: 252976

29.03.2024 Male 185 cm 85.6 kg

11:58:06am 42 yrs Asian

Exercise Test / Linked Medians (PEAK EXERCISE)

EXERCISE

STAGE 4

08:41

BRUCE

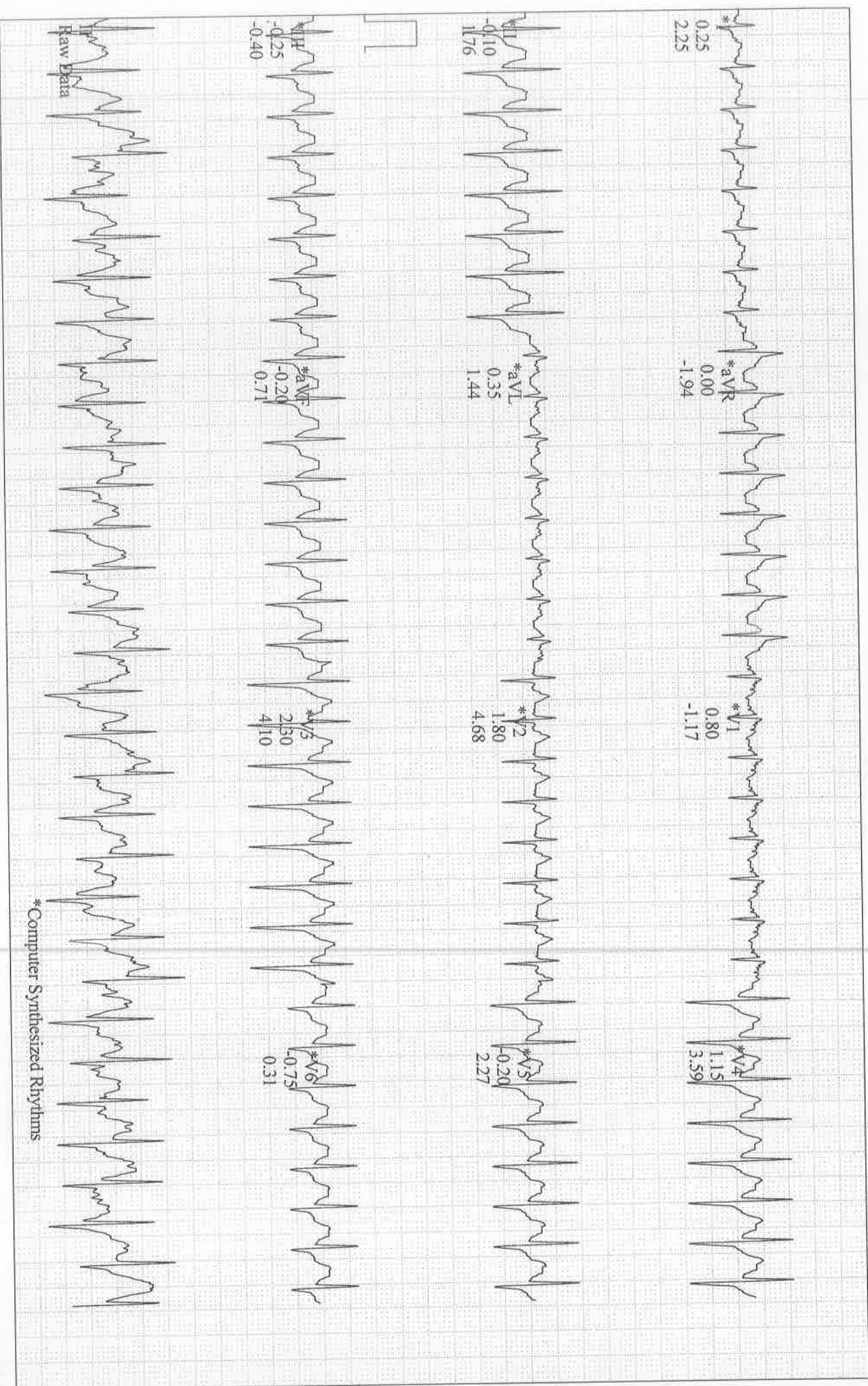
4.2 mph

16.0 %

APOLLO MEDICAL CENTRE

190 bpm
150/70 mmHg

Lead
ST Level (mm)
ST Slope (mV/s)



Raw Data

*Computer Synthesized Rhythms

GE CardioSoft V7.0 (10)
25 mm/s 10 mm/mV 50 Hz 0.05Hz FRF+ HR(V3,II)

Start of Test: 11:44:27am

MRI, AJAY KUMAR GADDAMI

Patient ID: 252976

29.03.2024 Male 185 cm 85.6 kg

11:59:06am 42 yrs Asian

Exercise Test / Linked Medians

RECOVERY

#1

01:00

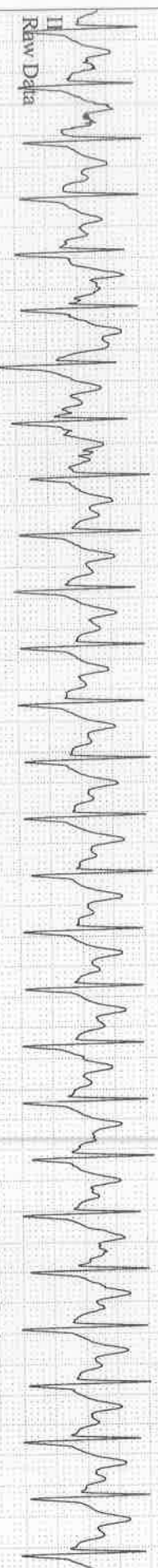
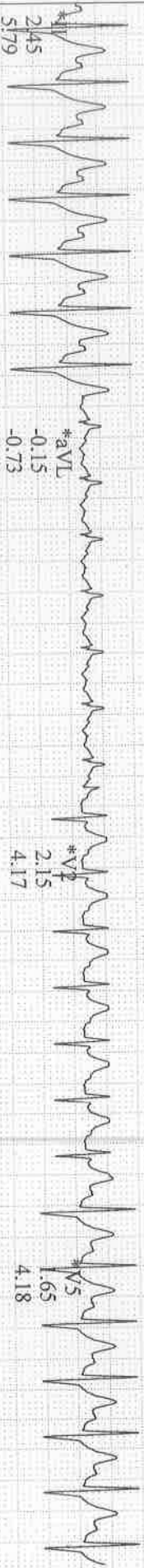
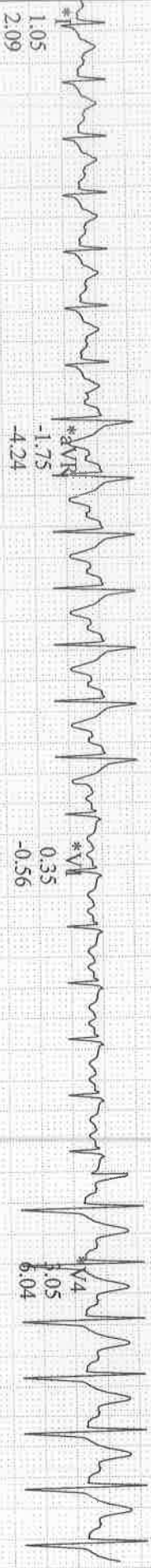
BRUCE

0.0 mph

0.0%

APOLLO MEDICAL CENTRE

Lead
ST Level (mm)
ST Slope (mV/s)



*Computer Synthesized Rhythms

MR, AJAY KUMAR GADDAM

Patient ID: 252976
29.03.2024 Male 185 cm 85.6 kg
12:01:06pm 42 yrs Asian
01:48 No symptoms

Exercise Test / Linked Medians

RECOVERY

129 bpm
140/70 mmHg

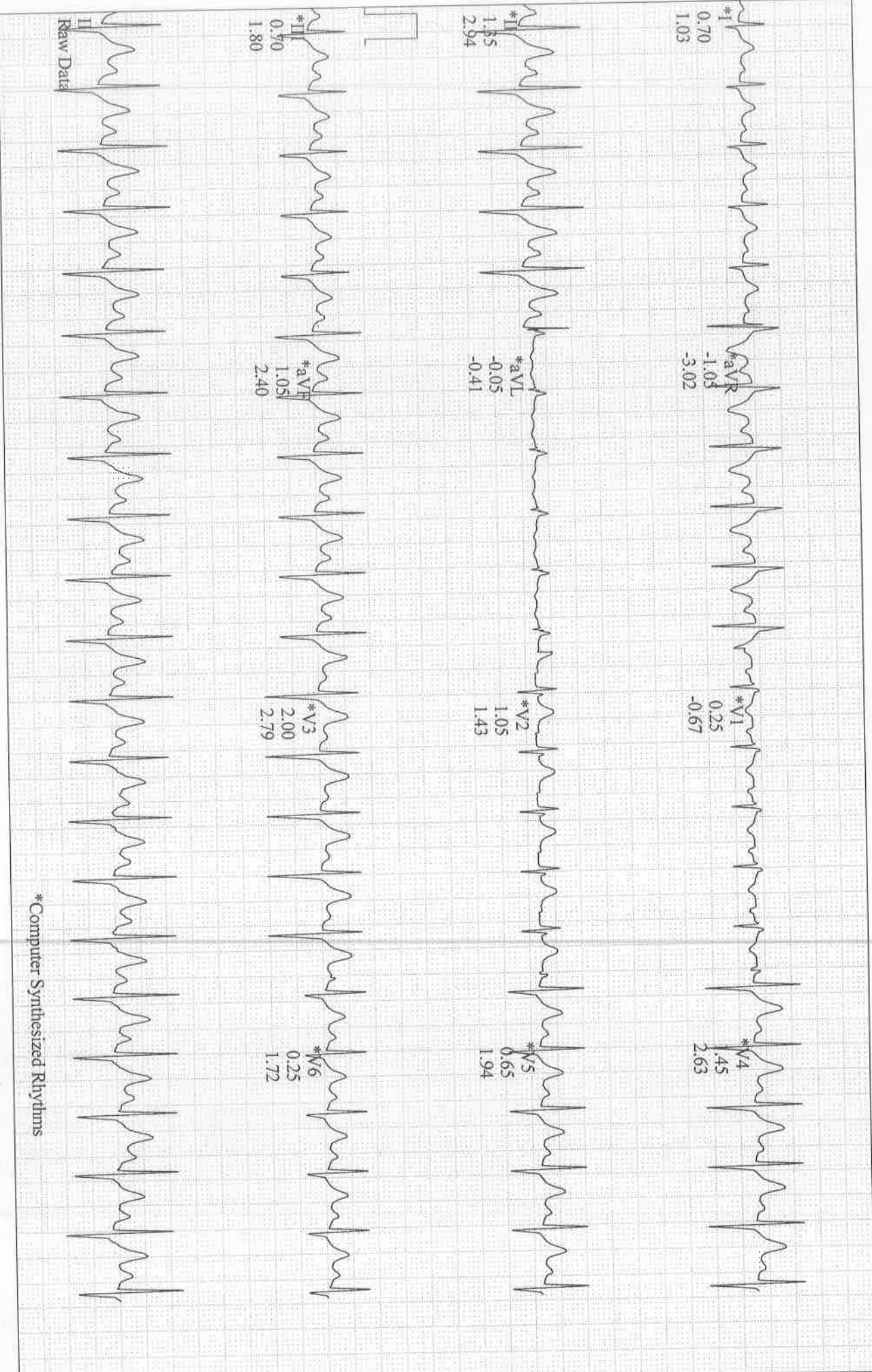
#1
03:00

BRUCE

0.0 mph
0.0%

APOLLO MEDICAL CENTRE

Lead
ST Level (mm)
ST Slope (mV/s)



GE CardioSoft V7.0 (10)
25 mm/s 10 mm/mV 50 Hz 0.05Hz FRR+ HR(V5,V4)

Start of Test: 11:44:27am

MR, AJAY KUMAR GADDAM

Patient ID: 252976
 29.03.2024 Male 185 cm 85.6 kg
 42 yrs Asian
 Meds: NIL

Test Reason:
 Medical History: NIL

Ref MD: Ordering MD:
 Technician: AKHILA Test Type:
 Comment:

Exercise Test / Selected Medians Report

APOLLO MEDICAL CENTRE

BRUCE: Exercise Time 08:41
 Max HR: 190 bpm 106 % of max predicted 178 bpm HR at rest: 102
 Max BP: 160/70 mmHg BP at rest: 110/70 Max RPP: 29920 mmHg*⁶bpm
 Maximum Workload: 12.10 METS
 Max ST: -1.45 mm, 1.36 mV/s in III; EXERCISE STAGE 3 7:29
 Arrhythmia: A:4
 ST/HR index: 0.85 μ V/bpm
 ST/HR slope: 0.79 μ V/bpm (III)
 HR reserve used: 115 %
 HR recovery: 24 bpm
 VE recovery: 0 VE/min

BASELINE EXERCISE	MAX. ST EXERCISE	PEAK EXERCISE EXERCISE	TEST END RECOVERY	BASELINE EXERCISE	MAX. ST EXERCISE	PEAK EXERCISE EXERCISE	TEST END RECOVERY
0:00 96 bpm 110/70 mmHg	7:29 181 bpm 140/70 mmHg	8:41 190 bpm 150/70 mmHg	2:50 129 bpm 140/70 mmHg	0:00 96 bpm 110/70 mmHg	7:29 181 bpm 140/70 mmHg	8:41 190 bpm 150/70 mmHg	2:50 129 bpm 140/70 mmHg
I 0.40 mm 0.30 mV/s	I 0.70 1.75	I 0.25 2.25	I 0.60 1.19	V1 0.45 -0.44	V1 0.85 -1.27	V1 0.80 -1.17	V1 0.25 -0.63
II 0.35 1.10	II -0.70 3.22	II -0.10 1.76	II 1.50 3.60	V2 1.05 0.80	V2 1.95 2.99	V2 1.80 4.68	V2 1.10 1.66
III 0.05 0.14	III -1.45 1.36	III -0.25 -0.40	III 0.90 2.19	V3 1.15 1.60	V3 1.40 3.93	V3 2.30 4.10	V3 2.25 3.36
aVR -0.40 -1.80	aVR 0.00 -2.53	aVR 0.00 -1.94	aVR -1.05 -3.46	V4 0.90 1.32	V4 0.60 3.65	V4 1.15 3.59	V4 1.70 3.17
aVL 0.20 0.20	aVL 1.10 0.30	aVL 0.35 1.44	aVL -0.15 -0.60	V5 0.35 0.82	V5 -0.60 2.06	V5 -0.20 2.27	V5 0.80 2.33
aVF 0.20 0.87	aVF -1.10 2.36	aVF -0.20 0.71	aVF 1.25 2.95	V6 0.10 0.61	V6 -1.00 1.50	V6 -0.75 0.31	V6 0.40 2.02

GE CardioSoft V7.0 (10)
 10 mm/mV 50 Hz 0.04Hz FRF HEART V5.41.1

Unconfirmed

Attending MD:

M/R, AJAY KUMAR GADDAM

Patient ID: 252976
 29.03.2024
 11:44:27am

Male 185 cm 85.6 kg
 42 yrs Asian
 Meds: NIL

Test Reason:
 Medical History: NIL

Ref. MD: Ordering MD:
 Technician: AKHILA Test Type:
 Comment:

BRUCE: Exercise Time 08:41
 Max HR: 190 bpm 106 % of max predicted 178 bpm HR at rest: 102
 Max BP: 160/70 mmHg BP at rest: 110/70 Max RPP: 29920 mmHg*bpm
 Maximum Workload: 12.10 METS
 Max. ST: -1.45 mm, 1.36 mV/s in III; EXERCISE STAGE 3 7:29
 Arrhythmia: A:4
 ST/HR index: 0.85 μ V/bpm
 ST/HR slope: 0.79 μ V/bpm (III)
 HR reserve used: 115 %
 HR recovery: 24 bpm
 VE recovery: 0 VE/min
 ST/HR hysteresis: -0.072 mV (I)
 QRS duration: BASELINE: 86 ms, PEAK EX: 84 ms, REC: 88 ms
 Reasons for Termination: Target heart rate achieved

Summary:
Resting ECG: normal. **Functional Capacity:** normal. **HR Response to Exercise:** appropriate. **BP Response to Exercise:** NORMAL HR AND BP RESPONSE. **Chest Pain:** none. **Arrhythmias:** NO ANGINA OR ARRHYTHMIA. **ST Changes:** NO SIGNIFICANT ST DEPRESSION DURING EXC AND REC. **Overall impression:** GOOD EFFORT TOLERANCE.
Conclusion: STRESS TEST NEGATIVE FOR INDUCIBLE ISCHEMIA

Room:
 Location: * 0 *

42

Name : Mr. AJAY KUMAR GADDAM

Age: 38 Y

Sex: M

UHID:CKOR.0000252976



OP Number:CKOROPV405301

Bill No :CKOR-OCR-81846

Date : 29.03.2024 08:35

Address : kmg

 Plan : ARCOFEMI MEDIWHEEL MALE AHC CREDIT PAN
 INDIA OP AGREEMENT

Sno	Service Type/ServiceName	Department
1	ARCOFEMI - MEDIWHEEL - FULL BODY ANNUAL PLUS ABOVE 50Y MALE - 2D ECHO - PAN INDIA - FY2324	
✓1	GAMMA GLUTAMYL TRANSFERASE (GGT)	
✓2	PROSTATIC SPECIFIC ANTIGEN (PSA TOTAL)	
✓3	2D ECHO → (10)	
✓4	LIVER FUNCTION TEST (LFT)	
✓5	GLUCOSE, FASTING	
✓6	HEMOGRAM + PERIPHERAL SMEAR	
7	DIET CONSULTATION	
✓8	COMPLETE URINE EXAMINATION	
9	URINE GLUCOSE(POST PRANDIAL)	
✓10	PERIPHERAL SMEAR	
✓11	ECG	
✓12	RENAL PROFILE/RENAL FUNCTION TEST (RFT/KFT)	
✓13	DENTAL CONSULTATION → (15)	
✓14	GLUCOSE, POST PRANDIAL (PP), 2 HOURS (POST MEAL)	
✓15	URINE GLUCOSE(FASTING)	
✓16	HbA1c, GLYCATED HEMOGLOBIN	
✓17	X-RAY CHEST PA → (11)	
18	ENT CONSULTATION → (23) (11)	
19	FITNESS BY GENERAL PHYSICIAN	
✓20	BLOOD GROUP ABO AND RH FACTOR	
✓21	LIPID PROFILE	
22	BODY MASS INDEX (BMI)	
✓23	OPHTHAL BY GENERAL PHYSICIAN →	
✓24	ULTRASOUND - WHOLE ABDOMEN	
✓25	THYROID PROFILE (TOTAL T3, TOTAL T4, TSH)	

✓26 physio - 17

✓27 Audiometry - 19 (N)

 Room No. 10. 30 Am
 Room No. 11
 Room No. 19. 00 pm
 Room No. 19

 WT - 85.6 kg
 HT - 185 cm
 BP → 112/69 mmHg
 P-88 bpm

 Get a complimentary dental screening
 Get a complimentary eye check Opp. to
 Avail a complimentary session with physiotherapist
 Get a complimentary hearing check

✓ TMT

CERTIFICATE OF MEDICAL FITNESS

This is to certify that I have conducted the clinical examination of AJAY
KUMAR on 30/3/24. After reviewing the medical history and on clinical examination it has been found that he/she is

<ul style="list-style-type: none"> • Medically Fit • Fit with restrictions/recommendations 	Tick <input checked="" type="checkbox"/>
Though following restrictions have been revealed, in my opinion, these are not impediments to the job. <ol style="list-style-type: none"> 1. ----- 2. ----- 3. ----- However the employee should follow the advice/medication that has been communicated to him/her. Review after -----	
<ul style="list-style-type: none"> • Currently Unfit. Review after ----- recommended • Unfit 	


 Dr. Medical Officer
 The Apollo Clinic (Location)

This certificate is not meant for medico - legal purposes.

Date : 30/3/24
 MR NO:
 Name : Ajay.
 Age/Gender: 38y/M.
 Mobile No:

Department: Physician
 Consultant : DR. Rinitha rajan
 Reg No : KMC1316
 Qualification: MBBS

Height : 185cm	Weight : 85.6kg	BMI :	Waist Circum :
Temp :	Pulse : 88/min	Resp :	B.P : 112/69mmHg

General Examination / Allergies History

LDL : 123.

Clinical Diagnosis & Management Plan

Health check up.

Adv
 Lifestyle modification

PI

Follow up date:

Doctor Signature



Patient Name	: Mr. AJAY KUMAR GADDAM	Age/Gender	: 42 Y/M
UHID/MR No.	: CKOR.0000252976	OP Visit No	: CKOROPV405301
Sample Collected on	:	Reported on	: 29-03-2024 13:29
LRN#	: RAD2285824	Specimen	:
Ref Doctor	: SELF		
Emp/Auth/TPA ID	: bobS18692		

DEPARTMENT OF RADIOLOGY

X-RAY CHEST PA

Both lungs fields appear normal.

Both hila are normal.

Both costophrenic and cardiophrenic angles are normal.

The cardiac mediastinal shadows appear normal.

Bones and soft tissues appear normal.

IMPRESSION : NORMAL STUDY.

Dr. VINOD P JOSEPH
MBBS, DNB, DMRD
Radiology

Patient Name	: Mr. AJAY KUMAR GADDAM	Age/Gender	: 42 Y/M
UHID/MR No.	: CKOR.0000252976	OP Visit No	: CKOROPV405301
Sample Collected on	:	Reported on	: 29-03-2024 13:13
LRN#	: RAD2285824	Specimen	:
Ref Doctor	: SELF		
Emp/Auth/TPA ID	: bobS18692		

DEPARTMENT OF RADIOLOGY

ULTRASOUND - WHOLE ABDOMEN

Liver is normal in size and shows normal echotexture. No biliary dilatation. No focal lesion
CBD is not dilated. **Portal vein** is normal in size, course and calibre.

Gall bladder is normal without evidence of calculi, wall thickening or pericholecystic fluid.

Pancreas to the extent visualized, appears normal in size, contour and echogenicity

Spleen is normal in size, shape, contour and echopattern. No evidence of mass or focal lesions.

Right Kidney is normal in size, position, shape and echopattern. Corticomedullary differentiation is maintained. No evidence of calculi or hydronephrosis.

Left Kidney is normal in size, position, shape and echopattern. Corticomedullary differentiation is maintained. No evidence of calculi or hydronephrosis.

Urinary Bladder is well distended. Wall thickness is normal. No evidence of calculi, mass or mural lesion.

Prostate: normal in size and echotexture.

There is no ascites.

IMPRESSION: NO SIGNIFICANT ABNORMALITIES DETECTED.



Patient Name : Mr. AJAY KUMAR GADDAM

Age/Gender : 42 Y/M

DR VINOD JOSEPH DNB,DMRD
RADIOLOGIST

Dr. VINOD P JOSEPH
MBBS, DNB, DMRD
Radiology

Name: Mr. AJAY KUMAR GADDAM
Age/Gender: 43 Y/M
Address: kmg
Location: BANGALORE, KARNATAKA
Doctor:
Department: GENERAL
Rate Plan: KORAMANGALA_06042023
Sponsor: ARCOFEMI HEALTHCARE LIMITED
Consulting Doctor: Dr. MAHABALESWAR

MR No: CKOR.0000252976
Visit ID: CKOROPV405301
Visit Date: 29-03-2024 08:35
Discharge Date:
Referred By: SELF

Eye

-:

Doctor's Signature

Name: Mr. AJAY KUMAR GADDAM
Age/Gender: 43 Y/M
Address: kmg
Location: BANGALORE, KARNATAKA
Doctor:
Department: GENERAL
Rate Plan: KORAMANGALA_06042023
Sponsor: ARCOFEMI HEALTHCARE LIMITED
Consulting Doctor: Dr. VIJAYA LAKSHMI M

MR No: CKOR.0000252976
Visit ID: CKOROPV405301
Visit Date: 29-03-2024 08:35
Discharge Date:
Referred By: SELF

Ent

:-: NO,

Doctor's Signature

Name: Mr. AJAY KUMAR GADDAM
Age/Gender: 43 Y/M
Address: kmg
Location: BANGALORE, KARNATAKA
Doctor:
Department: GENERAL
Rate Plan: KORAMANGALA_06042023
Sponsor: ARCOFEMI HEALTHCARE LIMITED
Consulting Doctor: Dr. GAZALA ANJUM

MR No: CKOR.0000252976
Visit ID: CKOROPV405301
Visit Date: 29-03-2024 08:35
Discharge Date:
Referred By: SELF

HT-CHIEF COMPLAINTS AND PRESENT KNOWN ILLNESS

SYSTEMIC REVIEW

**Weight

--->: Stable,

HT-HISTORY

Past Medical History

PAST MEDICAL HISTORY: Nil,

**Cancer: NO,

PHYSICAL EXAMINATION

SYSTEMIC EXAMINATION

IMPRESSION

RECOMMENDATION

DISCLAIMER

Disclaimer: The health checkup examinations and routine investigations have certain limitations and may not be able to detect all the diseases. Any new or persisting symptoms should be brought to the attention of the consulting physician. Additional tests, consultations and follow up may be required in some cases.,

Doctor's Signature

Name: Mr. AJAY KUMAR GADDAM
Age/Gender: 43 Y/M
Address: kmg
Location: BANGALORE, KARNATAKA
Doctor:
Department: GENERAL
Rate Plan: KORAMANGALA_06042023
Sponsor: ARCOFEMI HEALTHCARE LIMITED
Consulting Doctor: Dr. RINITHA RAJAN

MR No: CKOR.0000252976
Visit ID: CKOROPV405301
Visit Date: 29-03-2024 08:35
Discharge Date:
Referred By: SELF

HT-CHIEF COMPLAINTS AND PRESENT KNOWN ILLNESS

SYSTEMIC REVIEW

**Weight

--->: Stable,

HT-HISTORY

Past Medical History

PAST MEDICAL HISTORY: Nil,

**Cancer: NO,

PHYSICAL EXAMINATION

SYSTEMIC EXAMINATION

IMPRESSION

RECOMMENDATION

DISCLAIMER

Disclaimer: The health checkup examinations and routine investigations have certain limitations and may not be able to detect all the diseases. Any new or persisting symptoms should be brought to the attention of the consulting physician. Additional tests, consultations and follow up may be required in some cases.,

Doctor's Signature

Patient Name	: Mr. AJAY KUMAR GADDAM	Age	: 43 Y/M
UHID	: CKOR.0000252976	OP Visit No	: CKOROPV405301
Reported By:	: Dr. MOHAN MURALI	Conducted Date	: 29-03-2024 11:54
Referred By	: SELF		

ECG REPORT

Observation :-

1. Normal Sinus Rhythm.
2. Heart rate is 73beats per minutes.
3. No pathological Q wave or S-T,T changes seen.
4. Normal P,Q,R,S,T waves and axis.
5. No evidence of chamber, hypertrophy or enlargement seen.

Impression:

NORMAL RESTING ECG.

Dr MOHAN MURALI
CARDIOLOGIST

NOTE:KINDLY TAKE A PHOTOCOPY OF THE GRAPH

Patient Name	: Mr. AJAY KUMAR GADDAM	Age	: 43 Y/M
UHID	: CKOR.0000252976	OP Visit No	: CKOROPV405301
Reported By:	: Dr. MOHAN MURALI	Conducted Date	: 29-03-2024 11:54
Referred By	: SELF		

FOR FUTURE REFERENCE IF NEEDED.

----- END OF THE REPORT -----