

MRS. MAHIMA SHARMA

24 YEARS /FEMALE

BOB

01-4-2024

Height: 158 Cms

Weight: 44 Kg

BP: - 100/60 mmhg

Pulse: - 84/- Regular

BMI: - 17.6 kg/m²

EYE: - NORMAL

The Medical Examiner should record the findings under one of the following categories:-

Mild thinness



S. Chhabra
M.B.B.S., M.D.
DR. D.S. CHHABRA

DR. D.S. CHHABRA
MBBS. MD.

MRS. MAHIMA SHARMA
BANK OF BARODA**24 Years /F**
01-04-2024**HEAMOGRAM**

Test Name	Results	Normal Range
Haemoglobin (HB)	7.6	11 - 16 gm%
R.B.C. Count	4.43	3.8 - 4.8 milli./cu.mm
PCV *	27.5	36 - 46 %
MCV	62.08	80 - 98 fl
MCH	17.16	27 - 32 pg
MCHC	27.64	31.5 - 34.5 %
TOTAL WBC COUNT	4,900	4,000 to 11,000 /cu.mm
DIFFERENTIAL WBC COUNT	.	
Neutrophils	60	40 - 75 %
Lymphocytes	35	20 - 40 %
Monocytes	03	02 - 08 %
Eosinophils	02	01 - 05 %
Basophils	00	00 - 01 %
PLATELET COUNT	2.98	1.5 - 4 Lacs/cu.mm.
E.S.R	11	M- 0-10 at the end of 1 hr. F- 0-20 at the end of 1 hr

Dr. POOJA PRAPANNA
MD
DR. POOJA PRAPANNA

Note :- All pathological tests have technical and biological limitations. Please correlate clinically as well as with other investigative findings.
A review should be requested in case of any disparity. This report is not valid for medicolegal purpose.

M.D.

MRS. MAHIMA SHARMA

24 Years /F

BANK OF BARODA

01-04-2024

LIPID PROFILE

Test Name	Results	Normal Range
TOTAL LIPIDS	412	400 - 700 mg/dl
CHOLESTROL	137.0	<200 mg/dl- Desirable 200 - 239 mg/dl - Borderline High >240 Mg/dl High
HDL CHOLESTROL	42.0	35- 60 mg/dl
TRIGLYCERIDE	88.0	<150 mg/dl Normal 150 - 199 mg/dl Borderline High 200 - 499 mg/dl High
LDL CHOLESTROL	77.4	<100 mg/dl Optimal 100- 129 mg/dl Borderline high 160 - 189 mg/dl High
VLDL CHOLESTROL	17.6	<40 mg/dl
RISK RATIO	3.26	3 - 6

Dr. POOJA PRAPANNA
MDDR. POOJA PRAPANNA
M.D.

Note :- All pathological tests have technical and biological limitations. Please correlate clinically as well as with other investigative findings.
A review should be requested in case of any disparity. This report is not valid for medicolegal purpose.

MRS. MAHIMA SHARMA

24 Years /F

BANK OF BARODA

01-04-2024

Test Name	Results	Normal Range
-----------	---------	--------------

HAEMATOLOGY PROFILE

BLOOD GROUP

: -

"ABO " GROUP

"B"

Rh (D) Factor

Positive

.

.

(Cross matching & recheck of Blood Group is mandatory before any transfusion)

.

HBA1C

5.10

Normal 4-6 %

Good Control 6-7 %

Fair Control 7-8 %

Unsatisfactory

Control 8-10 %

Poor Control Above 10 %

SEROLOGY PROFILE

HBsAg

Non Reactive

.

.

* Test done by screening methods.
Requires confirmation at referral centre.

Dr. POOJA PRAPANNA

MD
Contd...2.00

DR. POOJA PRAPANNA

M.D.

MRS. MAHIMA SHARMA
BANK OF BARODA24 Years /F
01-04-2024**BIOCHEMISTRY**

Test Name	Results	Normal Range
SERUM BILIRUBIN	:-	
TOTAL BILIRUBIN	0.78	0 - 1 mg/dl
DIRECT BILIRUBIN	0.11	<0.25 mg/dl
INDIRECT BILIRUBIN	0.67	< 1.0 mg/dl
S.G.O.T	19.0	0 - 45 IU/L
S.G.P.T	17.0	0 - 45 IU/L
ALKALINE PHOSPHATE	82.0	Adult - 42 - 128 IU/L Child - 150 - 630 IU/L
TOTAL PROTEIN	7.31	6.0 to 8.0 g/dl
ALBUMIN	4.39	3.2 to 5.0 g/dl
GLOBULIN	2.92	1.9 to 3.5
A:G RATIO	1.50	1.2 TO 2.3
GAMA GT	21.0	5 - 43 Iu/l

Dr. POOJA PRAPANNA
MD
DR. POOJA PRAPANNA
M.D.

Note :- All pathological tests have technical and biological limitations. Please correlate clinically as well as with other investigative findings.
A review should be requested in case of any disparity. This report is not valid for medicolegal purpose.

MRS. MAHIMA SHARMA
BANK OF BARODA24 Years /F
01-04-2024

Test Name	Results	Normal Range
<u>BIOCHEMISTRY</u>		
FASTING BLOOD SUGAR	70.0	70 - 110 mg/dl
P.P. BLOOD SUGAR	81.0	upto 140 mg/dl
BUN	11.0	5 - 21 Mg/dl
CREATININE	0.70	0.6 - 1.4 mg\dl
URIC ACID	4.16	2.5 - 6.8 mg\dl
CALCIUM	8.22	8.5 - 10.5 mg\dl

Dr. POOJA PRAPANNA
MD
DR. POOJA PRAPANNA
M.D.

Note :- All pathological tests have technical and biological limitations. Please correlate clinically as well as with other investigative findings.
A review should be requested in case of any disparity. This report is not valid for medicolegal purpose.

MRS. MAHIMA SHARMA
BANK OF BARODA24 Years /F
01-04-2024**URINE EXAMINATION**

Test Name	Results	Normal Range
PHYSICAL EXAMINATION		
Quantity	30 ml	
Colour	Pale Yellow	
Appearance	Clear	
Deposits	Absent	
Specific Gravity	1.015	
Reaction	Acidic	
CHEMICAL EXAMINATION		
Albumin	Nil	
Sugar	Nil	
Ketones	Absent	
Bile Pigments	Negative	
Bile Salt	Negative	
Hematuria	Negative	
MICROSCOPIC EXAMINATION		
Pus Cells	1- 2 /hpf	
Red Blood Cells	Nil/hpf	
Epithelial Cell	1 - 2 /hpf	
Crystals	Nil	
Casts	Absent	

Dr. POOJA PRAPANNA
MD
DR. POOJA PRAPANNA
M.D.

Note :- All pathological tests have technical and biological limitations. Please correlate clinically as well as with other investigative findings.
A review should be requested in case of any disparity. This report is not valid for medicolegal purpose.

Pt. Name: **MRS. MAHIMA SHARMA**
Ref. By: **BANK OF BARODA**

Age/Sex: **24 Yrs /F**
Date: **01-Apr-2024**

CYTOPATHOLOGY

Material Received :- 1 Pap Smear Prepared.

Smear adequacy :- Satisfactory.

Inflammatory cells :- Mild Acute inflammatory cells seen.

Fair number of superficial and intermediate squamous epithelial cells

Endocervical cells: Seen, with squamous metaplastic cells

Organism: Normal flora (lactobacilli seen)

Negative for intraepithelial lesion or malignancy

Dr. POOJA PRAPANNA
MD

DR. POOJA PRAPANNA
M.D.

Note :- All pathological tests have technical and biological limitations. Please correlate clinically as well as with other investigative findings.

4D SONOGRAPHY • COLOR DOPPLER • ECHO • PATHOLOGY • DIGITAL X-RAY & OPG • TMT • ECG • HOLTER

MRS. MAHIMA SHARMA

24 Yrs./F

BOB

01st April, 2024

X-RAY CHEST PA VIEW

Bony cage is normal.

Trachea is central. C.P. angles are clear.

Cardiac contour and cardiothoracic ratio are normal.

Lung fields are clear.

DR.D.S.CHHABRA.

M.D.

4D SONOGRAPHY • COLOR DOPPLER • ECHO • PATHOLOGY • DIGITAL X-RAY & OPG • TMT • ECG • HOLTER

MRS. MAHIMA SHARMA

24 Yrs/F

BOB

01st April, 2024

ABDOMINAL SONOGRAPHY

Liver is of normal size, shape, has smooth margins & regular contours and the parenchyma reveals normal echostructure. No focal lesion.

Gall bladder is of normal size, shape, has thin walls & the contents are clear fluid. No evidence of any calculus. Biliary tree is undilated.

Pancreas is normal, no focal / diffuse pathology. Spleen is normal.

Both kidneys are normal in size [measure about 10.5 cms. in length], shape and echostructure. No calculus in both. The collecting system and ureter on both side are undilated.

Urinary bladder is normal in size, shape and has thin walls.

Uterus is of normal size [measures about 8.5 x 5 x 3.7 cms. in diam.] and is normal in shape. The uterine outlines are smooth & regular and the myometrial & endometrial echopattern is normal. No mass.

Both ovaries are normal in size, shape and echostructure. Multiple small follicles are seen in both.

No adnexal / pelvic mass or cyst. No pelvic collection.

There is no ascitis. No obvious abdominal lymphadenopathy. No sub / supra diaphragmatic pathology on either side.

IMPRESSION :

Normal study.

**DR.D.S.CHHABRA.**

M.D.



LABORATORY REPORT



Name : MAHIMA SHARMA	Sex/Age : Female / 24 Years	Case ID : 40401600114
Ref. By :	Dis. At :	Pt. ID :
Bill. Loc. : UNIQUE DIAGNOSTIC CENTRE INDORE		Pt. Loc. :
Reg Date and Time : 01-Apr-2024 13:18	Sample Type : Serum	Mobile No. :
Sample Date and Time : 01-Apr-2024 13:18	Sample Coll. By : non	Ref Id1 :
Report Date and Time : 01-Apr-2024 15:42	Acc. Remarks : -	Ref Id2 :

TEST	RESULTS	UNIT	BIOLOGICAL REF RANGE	REMARKS
Thyroid Function Test				
Triiodothyronine (T3) <small>CMIA</small>	116.93	ng/dL	58 - 159	
Thyroxine (T4) <small>CMIA</small>	7.20	µg/dL	5.5 - 11.0	
TSH <small>CMIA</small>	2.23	µIU/mL	0.4 - 4.2	

INTERPRETATIONS

- Circulating TSH measurement has been used for screening for euthyroidism, screening and diagnosis for hyperthyroidism & hypothyroidism. Suppressed TSH (<0.01 µIU/mL) suggests a diagnosis of hyperthyroidism and elevated concentration (>7 µIU/mL) suggest hypothyroidism. TSH levels may be affected by acute illness and several medications including dopamine and glucocorticoids. Decreased (low or undetectable) in Graves disease. Increased in TSH secreting pituitary adenoma (secondary hyperthyroidism), PRTN and in hypothalamic disease thyrotropin (tertiary hyperthyroidism). Elevated in hypothyroidism (along with decreased T4) except for pituitary & hypothalamic disease.
- Mild to modest elevations in patient with normal T3 & T4 levels indicates impaired thyroid hormone reserves & incipient hypothyroidism (subclinical hypothyroidism).
- Mild to modest decrease with normal T3 & T4 indicates subclinical hyperthyroidism.
- Degree of TSH suppression does not reflect the severity of hyperthyroidism, therefore, measurement of free thyroid hormone levels is required in patient with a suppressed TSH level.

CAUTIONS

Sick, hospitalized patients may have falsely low or transiently elevated thyroid stimulating hormone. Some patients who have been exposed to animal antigens, either in the environment or as part of treatment or imaging procedure, may have circulating antianimal antibodies present. These antibodies may interfere with the assay reagents to produce unreliable results.

TSH ref range in pregnancy

First trimester
Second trimester
Third trimester

Reference range (microIU/ml)

0.24 - 2.00
0.43-2.2
0.8-2.5

Note:(LL-VeryLow,L-Low,H-High,HH-VeryHigh ,A-Abnormal)

Dr. Chetana Bora

MD Pathology

Page 1 of 2

Dr. A Mishra

M.D. Microbiology

Dr. Soma Yadav

M.D. (Pathology)

Printed On : 01-Apr-2024 15:53

Neuberg Diagnostics Private Limited

Laboratory : 3/3, South Tukoganj, Gokuldas Hospital Road, Near Madhumilan Chouraha, Indore - 452001 Madhya Pradesh | 0731-4964961 / 62, 9713963333
neuberg.indore@supratechlabs.com

Regd. Office : Plot No. 7, Industrial Estate, Rajiv Gandhi Salai, Perungudi, Chennai - 600096, Tamil Nadu, India. | CIN - U85300TN2017PTC114099
www.neubergsupratech.com

DR. PRIYANK JAIN

M.D.,D.M.

CONSULTANT CARDIOLOGIST

UNIQUE DIAGNOSTIC CENTRE

45-B, Jaora Compound,
Opp. M.Y.Hospital, M.Y.H. Road,
INDORE - 452 001. (M. P.).
Phone : 2704118. 4082228

ECHOCARDIOGRAPHY REPORT

NAME : **MISS.NAYNEE MALVIYA** **Age** : **33 Yrs./ F**
REFERRED BY : **BOB** **Date** : **01st April, 2024**

ECHOCARDIOGRAPHIC OPINION

INTERPRETATION :-

- ** No RWMA.
- ** Good biventricular function. LVEF : 60 %.
- ** Normal cardiac valves, healthy pericardium.
- ** Grade I diastolic dysfunction.

Dr. PRIYANK JAIN
MBBS, MD, DM.
Reg. No. 19547



DR.PRIYANK JAIN. M.D.,D.M.

TWO DIMENSIONAL ECHOCARDIOGRAPHY

M Mode examination revealed normal movement of both mitral leaflets during diastole.

No SAM or mitral valve prolapse is seen.

Mitral valve opening is normal. No evidence of mitral valve prolapse is seen.

Tricuspid valve is normal, pulmonary valve is normal, aortic root is normal in size, dimensions of left atrium and left ventricle are normal.

Aortic cusps are not thickened and enclosure line is central.

Aortic valve has three cusps and its opening is not restricted.

2 - D imaging in PLAX, SAX and apical views revealed a normal sized left ventricle.

Movement of septum, anterior, posterior, inferior and lateral walls is normal. Global LVEF is 60 %.

Right atrium and right ventricle are normal in size.

Tricuspid valve leaflets move normally.

Pulmonary valve is normal.

Interatrial and interventricular septa are intact.

No intracardiac mass or thrombus is seen.

No pericardial pathology is observed.

MEASUREMENTS :

[C]	DIMENSIONS	OBSERVED VALUES	Normal Values (For Adults)
1.	Aortic Root diameter	: 2.5 cms.	2.0-3.7 cm < 2.2 cm / M ²
2.	Aortic Valve Opening	: 2.4 cms.	1.5-2.6 cm
3.	Right Ventricular Dimension	: --	
4.	Left Atrial Dimension	: 2.8 cms.	1.9-4.0 cm < 2.2 cm / M ²
5.	Left Ventricular ED Dimension	: 3.6 cms.	3.7-5.6 cm < 3.2 cm / M ²
6.	Left Ventricular ES Dimension	: 2.5 cms.	2.2-4.0 cm
7.	Inter Ventricular ED Septal thickness	: 1.1 cms.	0.6-1.2 cm
8.	Left Ventricular ED PW thickness	: 1.0 cms.	0.5-1.0 cm
9.	IVS / LVPW	: 01	< 1.3

[E] INDICES OF LEFT VENTRICULAR FUNCTION

1.	Mitral E - Septal Separation	: 0.5	< 0.9- cm
2.	Left Ventricular Ejection Fraction	: 60 %	60 - 80 %

DOPPLER

Peak Flow Velocity (M/Sec.)		Peak Gradient (mmHg.)	Regurgitation
MV	Normal	--	Normal
TV	Normal	--	Normal
AV	Normal	--	Normal
PV	Normal	--	Normal

PASP : Normal

भारत सरकार
Government of India

महिमा शर्मा
Mahima Sharma

जन्म तिथि / DOB : 25/04/1999
महिला / Female

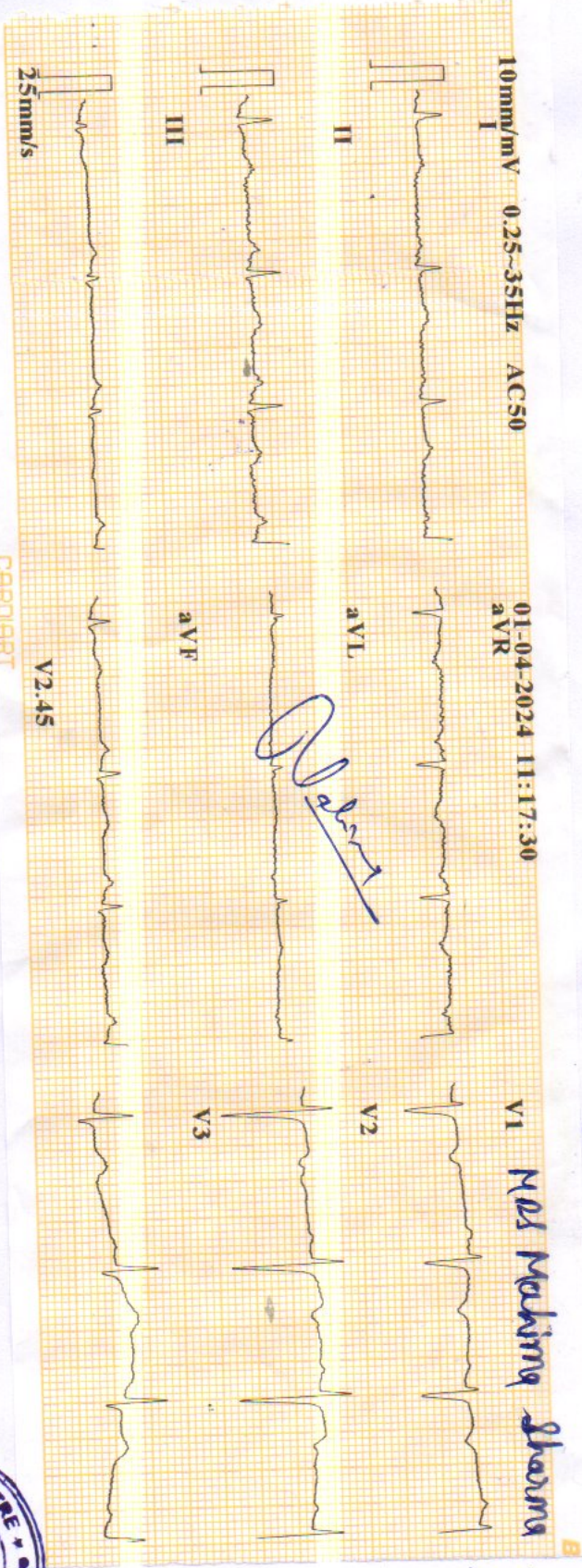

4850 2106 7273

आधार - आम आदमी का अधिकार

Dr. D. S. Chhabri
4850 2106 7273





PL

ID : 240401-1117

Name : 24 yr

Age : 24 yr

Sex : ~~F~~ Male

BP : mmHg

Height : cm

Weight : kg

HR : 84 bpm

P Dur : 105 ms

PR int : 152 ms

QRS Dur : 96 ms

QT/QTc int : 367/435 ms

P/QRST axis : 71/23/26 °

RV5/SV1 amp : 0.632/0.637 mV

RV6/SV2 amp : 1.269 mV

RV6/SV2 amp : 0.624/1.128 mV

Minnesota Code: 8-9-1 9-4-1(V3)

Diagnosis Information:
821: Sinus Arrhythmia
Normal ECG

Report Confirmed by: _____



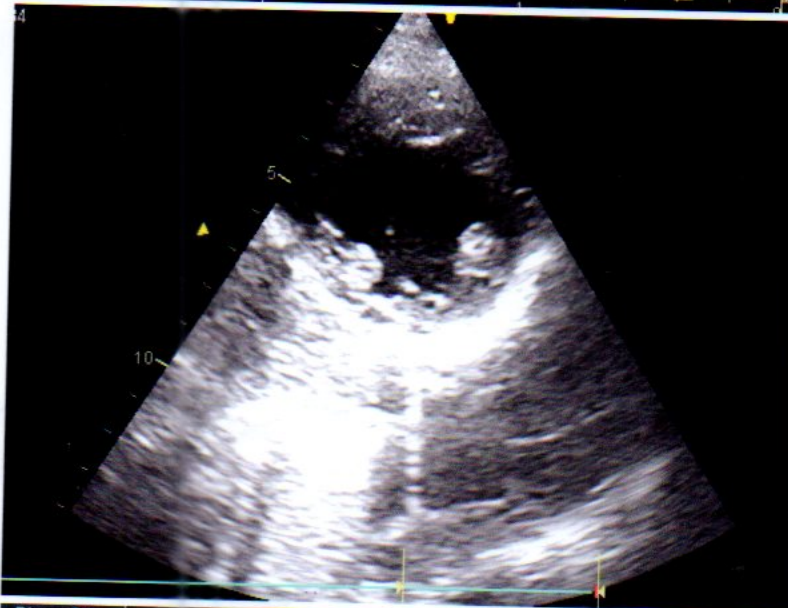
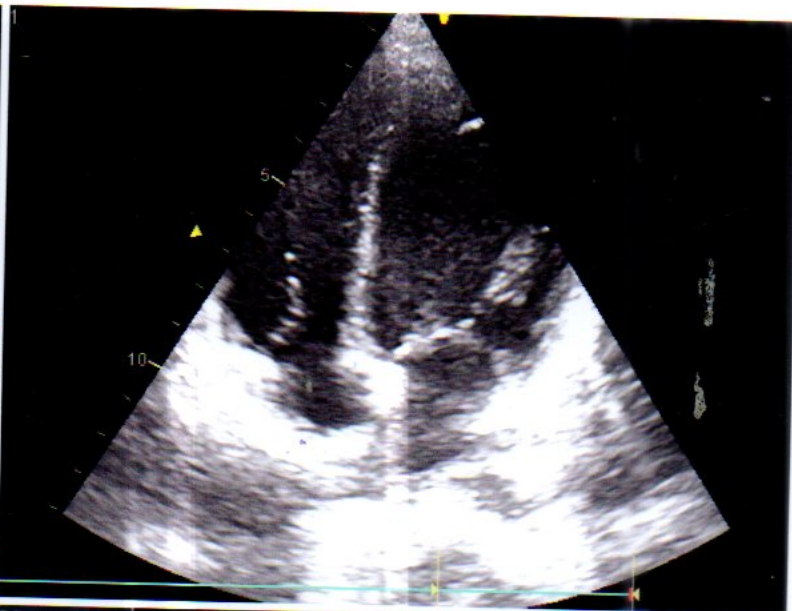
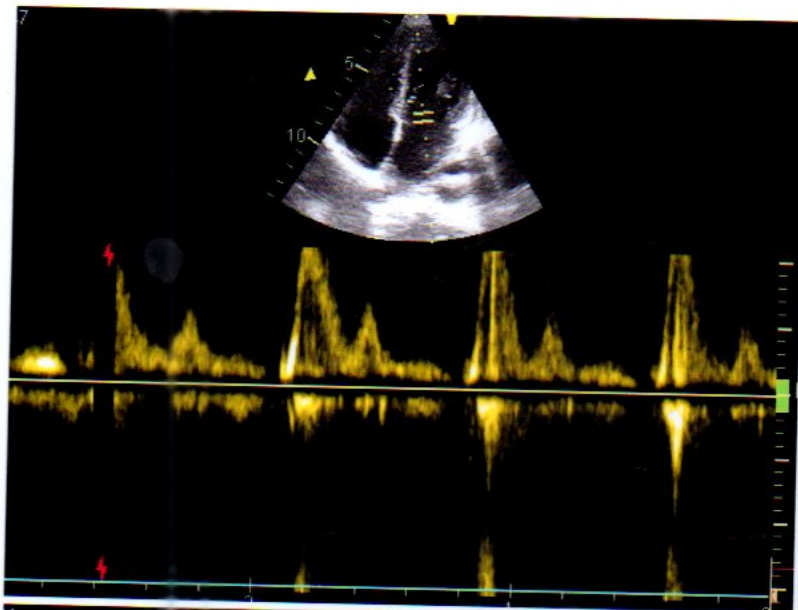
DR. PRIYANK JAIN
#MBBS, MD, DM
Reg. No. 19537

UNIQUE DIAGNOSTIC CENTRE INDORE

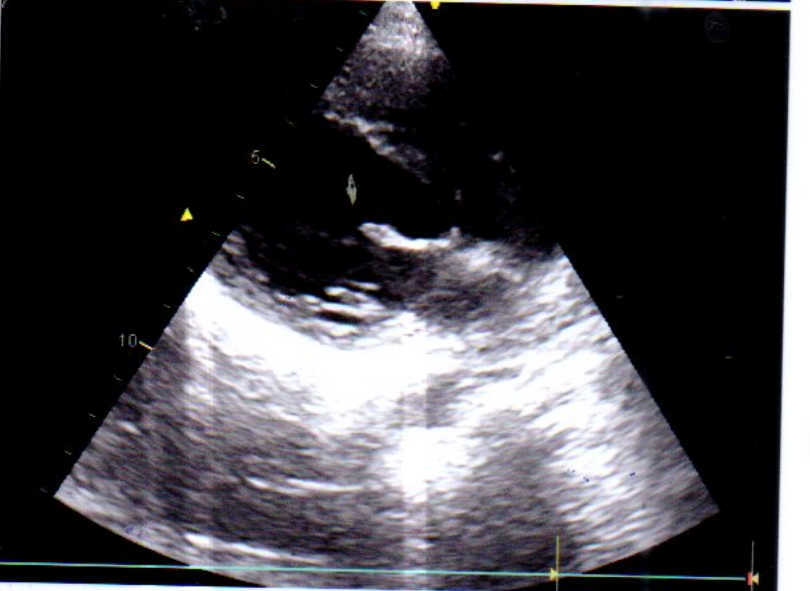
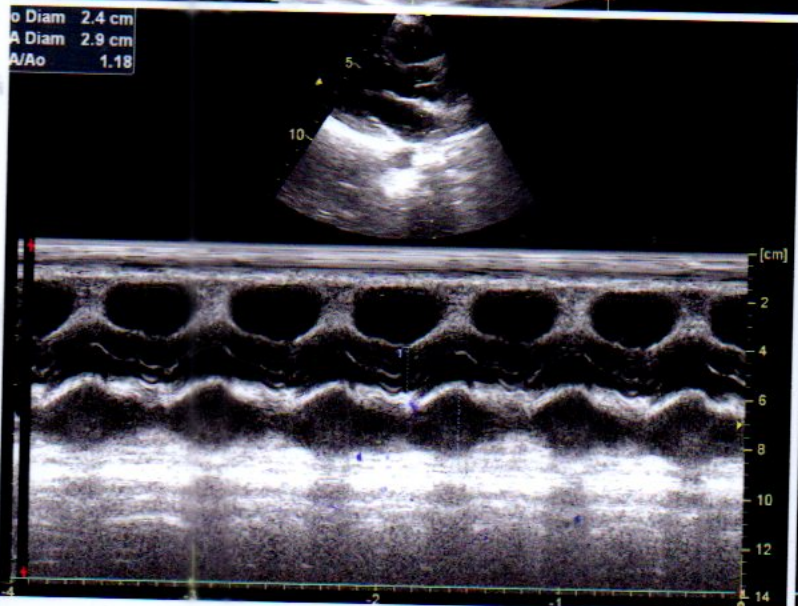
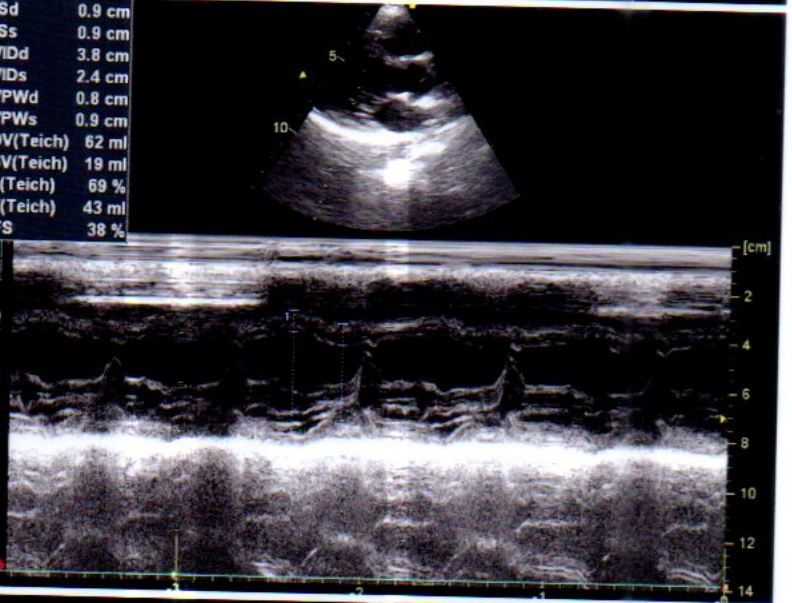
01 Apr 2024

Name : MRS. MAHIMA SHARMA

Ref. by : BOB
Done by : DR. PRIYANK JAIN M.D.,DM.



ISd	0.9 cm
ISs	0.9 cm
VIDd	3.8 cm
VIDs	2.4 cm
VPWd	0.8 cm
VPWs	0.9 cm
DV(Teich)	62 ml
SV(Teich)	19 ml
F(Teich)	69 %
V(Teich)	43 ml
FS	38 %



o Diam 2.4 cm
A Diam 2.9 cm
A/Ao 1.18

