



# Shubham Imaging & ALC Diagnostic Center

ISO 9001:2015 Certified Center

(A Unit of P. K. Arogyam Health & Wellness Center)

E-95, P.C. Colony, Near Sai Netryalaya Transformer, Kankarbagh, Patna - 20

✉ : alcdiagnostics@gmail.com

🌐 : www.pkarogyamhealthcheckup.com


☎ : 7050037694, 9153988577

OPINION MUST BE CORRELATES WITH CLINICALLY & OTHER INVESTIGATION FOR FINAL DIAGNOSIS. NOT FOR MEDICO LEGAL PURPOSE

PATIENT NAME : SONA FIRDOS PATIENT ID: 2845  
COL DATE : 24/02/2024 REPORTING DATE: 24/02/2024 AGE SEX : 34 YRS/F  
REF.BY : DR. / MEDIWHEEL

TEST NAME	RESULT	Unit	REF.RANGE
BLOOD SUGAR ( F )	81.0 mg/dl		70 - 110 mg/dl
<b>LIPID PROFILE:-</b>			
TOTAL CHOLESTROL	221.0 mg/dl		130 -250 mg/dl
TRIGLYCERIDE	134.6 mg/dl		50 -160 mg/dl
HDL CHOLESTROL	48.0 mg/dl		30 - 60 mg/dl
LDL CHOLESTROL	146.2 mg/dl		80 -130 mg/dl
VLDL CHOLESTROL	26.8 mg/dl		15 - 40 mg/dl
T.CH./HDL RATIO	4.6 : 1		Upto 5 :1
LDL /HDL RATIO	3.0 : 1		2 - 4:1

ESTB BY:-

  
24/02/2024  
Consultant Radiologist

**Dr. P. K. Tiwari**  
MD, M.Sc (Radio Imaging)  
Ph.D (AlI Nuclear Medicine)  
Consultant Imagiologist

**Dr. S. Kumar**  
MD, (Pat)  
Consultant Pathologist

**Dr. Abhishek Kumar**  
MBBS, MD  
Consultant Neuropatho Physiologist

**Dr. Kumari Suman**  
MBBS, DGO, MD  
Consultant (TVS & HSG Specialist)

**Dr. A. K. Singh**  
MBBS, PGDMCH  
Consultant Radiologist & Sonologist

PRINTING MISTAKE SHOULD BE REPORTED BACK IMMEDIATELY / यहाँ जन्म से पहले भ्रूण का लिंग जाँच नहीं होता है।



# Shubham Imaging & ALC Diagnostic Center

ISO 9001:2015 Certified Center

(A Unit of P. K. Arogyam Health & Wellness Center)

E-95, P.C. Colony, Near Sai Netryalaya Transformer, Kankarbagh, Patna - 20

✉ : [alcdiagnostics@gmail.com](mailto:alcdiagnostics@gmail.com)

🌐 : [www.pkarogyamhealthcheckup.com](http://www.pkarogyamhealthcheckup.com)

☎ : 7050037694, 9153988577

OPINION MUST BE CORRELATES WITH CLINICALLY & OTHER INVESTIGATION FOR FINAL DIAGNOSIS. NOT FOR MEDICO LEGAL PURPOSE

PATIENT NAME : SANA FIRDOS

PATIENT ID: 2842

COL DATE : 24/06/2024 REPORTING DATE: 24/06/2024 AGE SEX:- 34 YRS / F

REF.BY : DR. / MEDIWHEEL .

TEST NAME	RESULT	Unit	REF.RANGE
<b>LFT:-</b>			
SGPT	29.2 IU/L		5 - 40 IU/L
S G O T	21.0 IU/L		5 - 40 IU/L
ALKALINE PHOSPHATASE	89.9 IU/L		M - 53 - 165 IU/L F - 42 - 136 IU/L
TOTAL PROTIN	6.4 g/dl		6.0 - 8.7 g/dl
SERUM ALBUMIN	4.0 g/dl		3.5 - 5.4 g/dl
SERIUM GLUBLINE	2.4 g/dl		2.3 - 3.6 g/dl
AG RATIO	1.6: 1		1.0 - 2.3 g/dl
BILIRUBIN			
TOTAL	0.54 mg/dl		0.1 - 1.1 mg/dl
DIRECT	0.21 mg/dl		0.0 - 0.32 mg/dl
INDIRECT	0.33 mg/dl		0.0 - 0.78 mg/dl
GGTP( GGT )	21.4 iu/L		8 - 38 iu/L
<b>KFT/RFT</b>			
URIC ACID	3.8 mg/dl		3.2 - 7.0 mg/dl
SERUM CREATNINE	0.9 mg/dl		0.6 - 1.5 mg/dl
BLOOD URIA	28.4 mg/dl		5 - 45 mg/dl
BLOOD URIA NITROZEN(BUN).	13.2 mg/dl		5 - 23 mg/dl

ESTB BY:-

Consultant Radiologist

**Dr. P. K. Tiwari**

MD, M.Sc (Radio Imaging)  
Ph.D (Alt Nuclear Medicine)  
Consultant Imagiologist

**Dr. S. Kumar**

MD, (Pat)  
Consultant Pathologist

**Dr. Abhishek Kumar**

MBBS, MD  
Consultant Neuropatho Physiologist

**Dr. Kumari Suman**

MBBS, DGO, MD  
Consultant (TVS & HSG Specialist)

**Dr. A. K. Singh**

MBBS, PGDMCH  
Consultant Radiologist & Sonologist

PRINTING MISTAKE SHOULD BE REPORTED BACK IMMEDIATELY / यहाँ जन्म से पहले भ्रूण का लिंग जाँच नहीं होता है।



# Shubham Imaging & ALC Diagnostic Center

ISO 9001:2015 Certified Center

(A Unit of P. K. Arogyam Health & Wellness Center)

E-95, P.C. Colony, Near Sai Netryalaya Transformer, Kankarbagh, Patna - 20

✉ : alcdiagnostics@gmail.com

🌐 : www.pkarogayamhealthcheckup.com

☎ : 7050037694, 9153988577

OPINION MUST BE CORRELATES WITH CLINICALLY & OTHER INVESTIGATION FOR FINAL DIAGNOSIS. NOT FOR MEDICO LEGAL PURPOSE

PATIENT NAME : SANA FIRDOS

PATIENT ID: 2842

COL DATE : 24/02/2024

REPORTING DATE: 24/02/2024

AGE SEX:- 34 YRS/F

REF.BY : DR. / MEDIWHEEL .

TEST NAME	RESULT	Unit	REF.RANGE
ESR	14 mm/hr		<20 mm/hr
<b>CBC</b>			
Total W.B.C. Count	7,200 /cumm		4,000 - 11,000 /cumm
R B C COUNT	4.59 Million/ CUmm		4 - 7 Million/ CUmm
Platelets count	2.08 Lakh/ cumm		1.5 - 5.0 Lakh/ cumm
Differential Count of W.B.C.			
Neutrophils	59 %		40 -70%
Lymphocytes	36 %		25 - 40%
Eosinophils	04 %		01 - 05%
Mnonocytes	01 %		00 - 02%
Basophiles	00 %		00 - 0%
HAEMOGLOBIN	13.9 gm/dl ( 95.2 % )		14.6 gm/dl = 100%
PCV	41.7 %		35 - 47 %
MCV	90.9 fl		76 - 96 fl
MCH	30.2 pg		29 - 35 pg
MCHC	33.4 %		30 - 38 %

ESTB BY:-

  
Consultant Radiologist

**Dr. P. K. Tiwari**

MD, M.Sc (Radio Imaging)  
Ph.D (Alt Nuclear Medicine)  
Consultant Imagiologist

**Dr. S. Kumar**

MD, (Pat)  
Consultant Pathologist

**Dr. Abhishek Kumar**

MBBS, MD  
Consultant Neuropatho Physiologist

**Dr. Kumari Suman**

MBBS, DGO, MD  
Consultant (TVS & HSG Specialist)

**Dr. A. K. Singh**

MBBS, PGDMCH  
Consultant Radiologist & Sonologist

PRINTING MISTAKE SHOULD BE REPORTED BACK IMMEDIATELY / यहाँ जन्म से पहले भ्रूण का लिंग जाँच नहीं होता है।



# Shubham Imaging & ALC Diagnostic Center

ISO 9001:2015 Certified Center

(A Unit of P. K. Arogyam Health & Wellness Center)

E-95, P.C. Colony, Near Sai Netryalaya Transformer, Kankarbagh, Patna - 20

✉ : alcdiagnostics@gmail.com

🌐 : www.pkarogayamhealthcheckup.com

☎ : 7050037694, 9153988577

OPINION MUST BE CORRELATES WITH CLINICALLY & OTHER INVESTIGATION FOR FINAL DIAGNOSIS. NOT FOR MEDICO LEGAL PURPOSE

PATIENT NAME : SANA FIRDOS

PATIENT ID: 2842

COL DATE : 24/02/2024 REPORTING DATE: 24/02/2024 AGE SEX : 34 YRS/F

REF.BY : DR./ MEDIWHEEL.

## GLYCOSYLATED HEMOGLOBIN

TEST NAME	RESULT	Unit	REF.RANGE
HbA1c	3.5 %		Below 5.7 % : Normal 5.7 – 6.4 % : Prediabetic > = 6.5 % : Diabetic
AVERAGE PLASMA GLUCOSE	91.0 mg/dl		90 – 120 mg/dl : Good Control 121– 150 mg/dl : Fair Control 151- 180 mg/dl: Unsatisfactory Control >180 mg/dl : Poor Control

ESTB BY:-

**Dr. P. K. Tiwari**  
MD, M.Sc (Radio Imaging)  
Ph.D (Alt Nuclear Medicine)  
Consultant Imagiologist

**Dr. S. Kumar**  
MD, (Pat)  
Consultant Pathologist

**Dr. Abhishek Kumar**  
MBBS, MD  
Consultant Neuropatho Physiologist

**Dr. Kumari Suman**  
MBBS, DGO, MD  
Consultant (TVS & HSG Specialist)

**Dr. A. K. Singh**  
MBBS, PGDMCH  
Consultant Radiologist & Sonologist

  
24/02/2024  
Consultant Radiologist

PRINTING MISTAKE SHOULD BE REPORTED BACK IMMEDIATELY / यहाँ जन्म से पहले भ्रूण का लिंग जांच नहीं होता है।



# Shubham Imaging & ALC Diagnostic Center

ISO 9001:2015 Certified Center

(A Unit of P. K. Arogyam Health & Wellness Center)

E-95, P.C. Colony, Near Sai Netryalaya Transformer, Kankarbagh, Patna - 20

✉ : [alcdiagnostics@gmail.com](mailto:alcdiagnostics@gmail.com)

🌐 : [www.pkarogyamhealthcheckup.com](http://www.pkarogyamhealthcheckup.com)

☎ : 7050037694, 9153988577

OPINION MUST BE CORRELATES WITH CLINICALLY & OTHER INVESTIGATION FOR FINAL DIAGNOSIS. NOT FOR MEDICO LEGAL PURPOSE

PATIENT NAME : SANA FIRDOS

PATIENT ID: 2842

COL DATE : 24/02/2024 REPORTING DATE: 24/02/2024 AGE SEX : 34 YRS/F

REF.BY : DR. / MEDIWHEEL.

TEST NAME	RESULT	Unit	REF.RANGE
-----------	--------	------	-----------

BLOOD GROUP : ' AB '

Rh Typing : POSITIVE

Note: Do always cross – matching before blood transfusion

*AKS*  
24/02/2024

Consultant Radiologist

ESTB BY:-

**Dr. P. K. Tiwari**  
MD, M.Sc (Radio Imaging)  
Ph.D (Alt Nuclear Medicine)  
Consultant Imagiologist

**Dr. S. Kumar**  
MD, (Pat)  
Consultant Pathologist

**Dr. Abhishek Kumar**  
MBBS, MD  
Consultant Neuropatho Physiologist

**Dr. Kumari Suman**  
MBBS, DGO, MD  
Consultant (TVS & HSG Specialist)

**Dr. A. K. Singh**  
MBBS, PGDMCH  
Consultant Radiologist & Sonologist

PRINTING MISTAKE SHOULD BE REPORTED BACK IMMEDIATELY / यहाँ जन्म से पहले भ्रूण का लिंग जाँच नहीं होता है।



# Shubham Imaging & ALC Diagnostic Center

ISO 9001:2015 Certified Center

(A Unit of P. K. Arogyam Health & Wellness Center)

E-95, P.C. Colony, Near Sai Netryalaya Transformer, Kankarbagh, Patna - 20

✉ : alcdiagnostics@gmail.com

🌐 : www.pkarogyamhealthcheckup.com

☎ : 7050037694, 9153988577

OPINION MUST BE CORRELATES WITH CLINICALLY & OTHER INVESTIGATION FOR FINAL DIAGNOSIS. NOT FOR MEDICO LEGAL PURPOSE

PATIENT NAME : SANA FIRDOS PATIENT ID: 2842  
 COL DATE : 24/02/2024 REPORTING DATE: 24/02/2024 AGE SEX : 34 YRS/F  
 REF.BY : DR. / MEDIWHEEL..

## ROUTINE EXAMINATION OF URINE

### PHYSICAL EXAMINATION

Quantity ....	20 ml	Colour....	Strow
Appearance...	Clear	Sediment ...	Nil
Specific gravity....	1.010		


### CHEMICAL EXAMINATION

Reaction ....	6.0	Nitrite.....	Not done
Sugar ....	Nil	Bile Pigment ...	Not done
Albumin ....	Nil	Urobilinogen....	Not done
Excess of Phosphate....	Nil	Chile.....	Not done
Bile Salt	Not Done	Acetone...	Not done

### MICROSCOPIC EXAMINATION

Erythrocytes....	Nil	Casts ....	Nil
Leucocytes ....	1-4 / HPE	Crystals....	Nil
Epith. Cell ....	A, Few	Others ....	Nil

ESTB BY:-

  
Consultant Radiologist

**Dr. P. K. Tiwari**  
MD, M.Sc (Radio Imaging)  
Ph.D (Alt Nuclear Medicine)  
Consultant Imagiologist

**Dr. S. Kumar**  
MD, (Pat)  
Consultant Pathologist

**Dr. Abhishek Kumar**  
MBBS, MD  
Consultant Neuropatho Physiologist

**Dr. Kumari Suman**  
MBBS, DGO, MD  
Consultant (TVS & HSG Specialist)

**Dr. A. K. Singh**  
MBBS, PGDMCH  
Consultant Radiologist & Sonologist

PRINTING MISTAKE SHOULD BE REPORTED BACK IMMEDIATELY / यहाँ जन्म से पहले भ्रुण का लिंग जाँच नहीं होता है।



# Shubham Imaging & ALC Diagnostic Center

ISO 9001:2015 Certified Center

(A Unit of P. K. Arogyam Health & Wellness Center)

E-95, P.G. Colony, Near Sai Netryalaya Transformer, Kankarbagh, Patna - 20

✉ : alcdiagnostics@gmail.com

🌐 : www.pkarogayamhealthcheckup.com

☎ : 7050037694, 9153988577

OPINION MUST BE CORRELATES WITH CLINICALLY & OTHER INVESTIGATION FOR FINAL DIAGNOSIS. NOT FOR MEDICO LEGAL PURPOSE

PATIENT NAME : SANA FIRDOS PATIENT ID: 2842  
COL DATE : 24/02/2024 REPORTING DATE: 24/02/2024 AGE SEX : 34 YRS/F  
REF.BY : DR. / MEDIWHEEL.

Investigation	Result	Normal Range
Total Triiodothyronin T3	1.24 ng/mL	0.80 - 2.00 $\mu$ ng/mL
Total Thyroxin T4	7.97 ug/mL	5.10 - 14.10 ug/dL
Serum TSH	6.68 $\mu$ g/mL	0.27 - 4.20 $\mu$ g/mL

THYROID DISORDER (>: Increase: < Decrease: n Normal

1. T3(n) T4(n) TSH(n) :EUTHYROID STATE:
2. T3(>) T4(>) TSH(<): HYPERTHYROIDISM:
3. T3(<)T4(<) TSH(>): HYPOTHYROIDISM:
4. T3(n)T4(n) TSH(>) : SUB-CLINICAL HYPO-THYROIDISM:
5. T3(n)T4(n) TSH(<): SUB-CLINICAL HYPER-THYROIDISM:
6. T3(>) T4(n) TSH(<): T3 THYROTOXICOSIS:

Total T3/T4 level is dependent on Level:

So determination of free T3/T4is a better MARKER of Thyroid Function.

\*FREE T3/T4 ESTIMATION FACILITY IS AVAILABALE ON REQUEST.:

ESTB BY:-

**Dr. P. K. Tiwari**  
MD, M.Sc (Radio Imaging)  
Ph.D (AI Nuclear Medicine)  
Consultant Imaginationist

**Dr. S. Kumar**  
MD, (Pat)  
Consultant Pathologist

**Dr. Abhishek Kumar**  
MBBS, MD  
Consultant Neuropatho Physiologist

**Dr. Kumari Suman**  
MBBS, DGO, MD  
Consultant (TVS & HSG Specialist)

**Dr. A. K. Singh**  
MBBS, PGDMCH  
Consultant Radiologist & Sonologist

  
Consultant Radiologist

PRINTING MISTAKE SHOULD BE REPORTED BACK IMMEDIATELY / यहाँ जन्म से पहले भ्रूण का लिंग जाँच नहीं होता है।



# Shubham Imaging & ALC Diagnostic Center

ISO 9001:2015 Certified Center

(A Unit of P. K. Arogyam Health & Wellness Center)

E-95, P.C. Colony, Near Sai Netryalaya Transformer, Kankarbagh, Patna - 20

✉ : alcdiagnostics@gmail.com

🌐 : www.pkarogayamhealthcheckup.com

☎ : 7050037694, 9153988577

OPINION MUST BE CORRELATES WITH CLINICALLY & OTHER INVESTIGATION FOR FINAL DIAGNOSIS. NOT FOR MEDICO LEGAL PURPOSE

Pt. Name :- **SANA FIRDOS KHAN**  
Ref. By :- **DR./MEDIWHEEL**

Date:- **24-Feb-24**  
Age / Sex - **34 Yrs. F.**

Thanks for your kind referral

## X-RAY CHEST (P.A.VIEW)

The lungs on the either side show equal translucency.

The peripheral pulmonary vasculature is normal.

No focal lung lesion is seen.

The pleural spaces are normal.

Both hila are normal in size, have equal density and bear normal relationship.

The heart and trachea are central in position and no mediastinal abnormality is visible.

The cardiac size is normal.

The domes of the diaphragms are normal in position, and show smooth outline.

## IMPRESSION

- NO EVIDENCE OF PULMONARY OR CARDIAC PATHOLOGY IS NOTED.

ESTB BY:-

Consultant Radiologist

**Dr. P. K. Tiwari**  
MD, M.Sc (Radio Imaging)  
Ph.D (Alt Nuclear Medicine)  
Consultant Imagiologist

**Dr. S. Kumar**  
MD, (Pat)  
Consultant Pathologist

**Dr. Abhishek Kumar**  
MBBS, MD  
Consultant Neuropatho Physiologist

**Dr. Kumari Suman**  
MBBS, DGO, MD  
Consultant (TVS & HSG Specialist)

**Dr. A. K. Singh**  
MBBS, PGDMCH  
Consultant Radiologist & Sonologist

PRINTING MISTAKE SHOULD BE REPORTED BACK IMMEDIATELY / यहाँ जन्म से पहले भ्रूण का लिंग जाँच नहीं होता है।





# Shubham Imaging & ALC Diagnostic Center

ISO 9001:2015 Certified Center

(A Unit of P. K. Arogyam Health & Wellness Center)

E-95, P.C. Colony, Near Sai Netryalaya Transformer, Kankarbagh, Patna - 20

✉ : alcdiagnostics@gmail.com

🌐 : www.pkarogayamhealthcheckup.com

☎ : 7050037694, 9153988577

OPINION MUST BE CORRELATES WITH CLINICALLY & OTHER INVESTIGATION FOR FINAL DIAGNOSIS. NOT FOR MEDICO LEGAL PURPOSE

Pt. Name :- SANA FIRDOS KHAN  
Ref. By :- DR./MEDIWHEEL

Date:- 24-Feb-24  
Age / Sex -34 Yrs. F

## REAL TIME U.S.G. OF WHOLE ABDOMEN

Thanks for your kind referral

( Report.)

- LIVER** :- Measures 14.68 cm. Mild Enlarged in shape , size and echo texture fatty change seen in liver parenchyma. I.H.B.R. are not dilated.  
Hepatic veins are normal. No SOL seen.
- G.BL. :- Lumen is echo free. Wall thickness appears normal.
- C.B.D. :- Measures 3.2 mm in diameter with echo free lumen. No calculi or mass seen.
- P.V. :- Measures 7.5 mm in diameter. Appears normal. No thrombus seen.
- PANCREAS :- Normal in shape, size and echo texture. No calcification mass seen.
- SPLEEN :- Measures 10.37 cm. Normal in shape, size and echo texture.  
No SOL seen.
- KIDNEY :-Both kidney shows normal shape, size & echotexture. C.M.D.intact.  
P.C.S. are not dilated. No calculi, cyst or hydronephrosis seen on either side.  
**Right Kidney :- Measures 9.65X 4.10 cm.**  
**Left Kidney :- Measures 10.52 X 4.50 cm.**
- URETER :- Not dilated .No apparent calculi seen.
- U.BLADDER:- Shows normal in outline with echo free lumen. No calculi or mass seen.  
**Pre void – 320 ml. Post void – is in significant**
- UTERUS :-Is normal in size, shape & Anteverted position measuring 8.56 X 4.34 cm.  
Endometrial And Myometeriam appears normal in limits No focal mass lesion seen.
- ADNEXA :- Both ovary appears normal in size and shape.  
Rt Ovary Measures – 2.58 cm Lt Ovary Measures 3.26 cm
- P.O.D :- No collection seen in P.O.D.
- R.I.F. :- Son graphically no appendicular mass or collection seen.
- OTHERS :- No Ascites No Lymph Adenopathy. No pleural Effusion seen on either side.

## IMPRESSION

- **Mild Hepatomegaly With fatty liver G-I.**
- **Adv:- Further work up other investigation .**  
**Otherwise son graphically normal scan. of rest organs**

ESTB BY:-

Consultant Radiologist

**Dr. P. K. Tiwari**  
MD, M.Sc (Radio Imaging)  
Ph.D (All Nuclear Medicine)  
Consultant Imagonologist

**Dr. S. Kumar**  
MD, (Pat)  
Consultant Pathologist

**Dr. Abhishek Kumar**  
MBBS, MD  
Consultant Neuropatho Physiologist

**Dr. Kumari Suman**  
MBBS, DGO, MD  
Consultant (TVS & HSG Specialist)

**Dr. A. K. Singh**  
MBBS, PGDMCH  
Consultant Radiologist & Sonologist

PRINTING MISTAKE SHOULD BE REPORTED BACK IMMEDIATELY / यहाँ जन्म से पहले भ्रुण का लिंग जाँच नहीं होता है।



# Shubham Imaging & ALC Diagnostic Center

ISO 9001:2015 Certified Center

(A Unit of P. K. Arogyam Health & Wellness Center)

E-95, P.C. Colony, Near Sai Netryalaya Transformer, Kankarbagh, Patna - 20

✉ : alcdiagnostics@gmail.com

🌐 : www.pkarogyamhealthcheckup.com

☎ : 7050037694, 9153988577

OPINION MUST BE CORRELATES WITH CLINICALLY & OTHER INVESTIGATION FOR FINAL DIAGNOSIS. NOT FOR MEDICO LEGAL PURPOSE

## ECHOCARDIOGRAPHY & COLOR DOPPLER REPORT

Patient's Name : Mrs SANA FIRDOS KHAN

Age/Sex : 34 Yrs /F

Ref. by : DR./ MEDIWHEEL

Date : 24-Feb-24

### ECHOCARDIOGRAPHIC WINDOW: Fair 2D & M MODE ECHOCARDIOGRAPHY

#### Left ventricle

EDD:	28	mm ( 20 - 28 mm / m <sup>2</sup> )	ESD:	19	mm(13 - 21 mm / m <sup>2</sup> )
IVS :	8	mm ( 6 - 11 mm )	PW:	9	mm ( 6 - 11 mm )
Ejection fraction:	60% ( 61 ± 8% )		FS:	35	% ( 34 - 44 % )
IVS:	Intact		LV clot	Absent	

Left atrium/ Aorta 35/31 mm

Right ventricle Normal

Right atrium Normal

Pericardium Normal with no pericardial effusion

#### 2D:

Normal LA/LV Size and normally contracting left ventricle. No RWMA, concentric LVH

#### Mitral valve

AML/ PML: Normal

Tricuspid valve Normal

Aortic valve Normal

Pulmonary valve Normal

#### Continuous & Pulse Wave Doppler study

Valve	Velocity (m/sec)			Gradient (mmHg)			Valve area (PHT Method)	Regurg.
	Peak	Mean	EDV	Peak	Mean	EDG		
Mitral	E=07 A=0.6			2.3	2.0			Nil
Tricuspid	E=0.5 A=0.3			1.9	0.2			Nil
Aortic	1.12			5.0	2.5			Nil
Pulmonary	0.9			3.5	1.7			Nil

ESTB BY:-

Consultant Radiologist

**Dr. P. K. Tiwari**  
MD, M.Sc (Radio Imaging)  
Ph.D (Alt Nuclear Medicine)  
Consultant Imagiologist

**Dr. S. Kumar**  
MD, (Pat)  
Consultant Pathologist

**Dr. Abhishek Kumar**  
MBBS, MD  
Consultant Neuropathologist

**Dr. Kumari Suman**  
MBBS, DGO, MD  
Consultant (TVS & HSG Specialist)

**Dr. A. K. Singh**  
MBBS, PGDMCH  
Consultant Radiologist & Sonologist

PRINTING MISTAKE SHOULD BE REPORTED BACK IMMEDIATELY / यहाँ जन्म से पहले भ्रूण का लिंग जाँच नहीं होता है।



# Shubham Imaging & ALC Diagnostic Center

ISO 9001:2015 Certified Center

(A Unit of P. K. Arogyam Health & Wellness Center)

E-95, P.C. Colony, Near Sai Netryalaya Transformer, Kankarbagh, Patna - 20

✉ : alcdiagnostics@gmail.com

🌐 : www.pkarogyamhealthcheckup.com

☎ : 7050037694, 9153988577

OPINION MUST BE CORRELATES WITH CLINICALLY & OTHER INVESTIGATION FOR FINAL DIAGNOSIS. NOT FOR MEDICO LEGAL PURPOSE

## Colour Flow Imaging

No TR, No MR/PR, No AR

No flow shunt

## COMMENTS :

- ◆ Normal size all chamber
- ◆ Normal LV filling Pressure
- ◆ No RWMA
- ◆ Normal LV systolic function
- ◆ Grade I LV diastolic dysfunction.
- ◆ Global LVEF = 60%
- ◆ All cardiac valves are normal
- ◆ No PAH, Mild concentric LVH
- ◆ No MS / TS / AS / PS / PR
- ◆ No clot / vegetation / pericardial effusion.

## IMPRESSION:

All chambers are normal

No RWMA, No PAH

Grade I LV diastolic dysfunction.

Normal LV systolic function, LVEF – 65%

Please correlate clinically

DR. SANDEEP KUMAR MBBS MD

ESTB BY:-

Consultant Radiologist

**Dr. P. K. Tiwari**

MD, M.Sc (Radio Imaging)  
Ph.D (Alt Nuclear Medicine)  
Consultant Imagionologist

**Dr. S. Kumar**

MD, (Pat)  
Consultant Pathologist

**Dr. Abhishek Kumar**

MBBS, MD  
Consultant Neuropatho Physiologist

**Dr. Kumari Suman**

MBBS, DGO, MD  
Consultant (TVS & HSG Specialist)

**Dr. A. K. Singh**

MBBS, PGDMCH  
Consultant Radiologist & Sonologist

PRINTING MISTAKE SHOULD BE REPORTED BACK IMMEDIATELY / यहाँ जन्म से पहले भ्रुण का लिंग जाँच नहीं होता है।



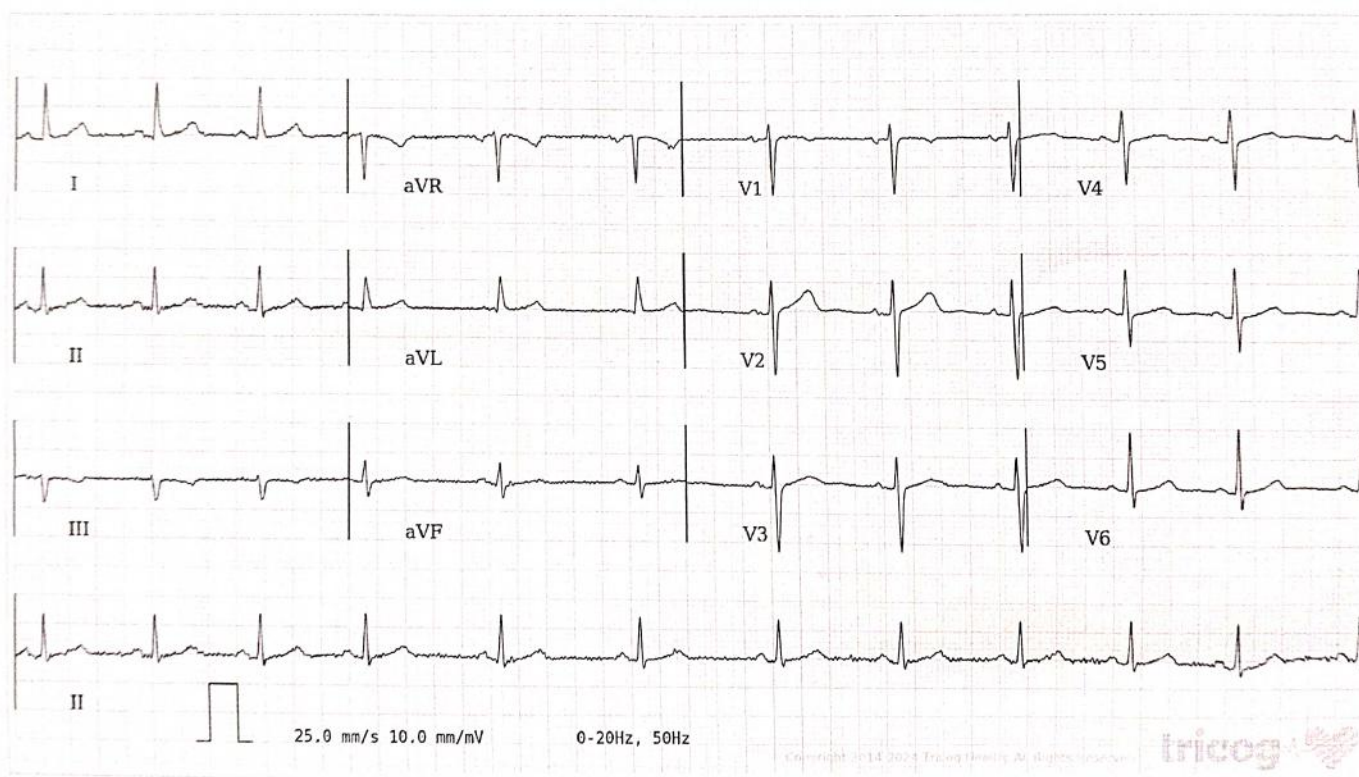
**PK AROGYAM**

Age / Gender: 34/Female

Date and Time: 24th Feb 24 1:11 PM

Patient ID: 2842

Patient Name: Sana firdos khan



AP: 72bpm

VP: 71bpm

QRSD: 80ms

QT: 362ms

QTcB: 393.79ms

PRI: 144ms

P-R-T: 42° 12° 17°

**ECG Within Normal Limits: Sinus Rhythm, Sinus Arrhythmia Seen. Please correlate clinically.**



Disclaimer: Analysis in this report is based on ECG alone and should only be used as an adjunct to clinical history, symptoms and results of other invasive and non-invasive tests and must be interpreted by a qualified physician.