

PT. Name : Mrs..PREETY TOMAR Date : 23-11-2023
 F/H Name : ABHISHEK TOMAR OPD NO : 8
 Age / Gender : 33 Y / F Mobile No : 8319365429
 UHID No : 23-10286 Fees : 0.00
 Consultant : DEVENDRA VAISHNAV Bill No : 23-31490
 Department : ANESTHESIOLOGY
 Doctor Reg No : MP-10124
 Address : GALI NO 4 ,KASTURBA NAGAR,RATLAM

1. Height	2. Weight	3. BMI	4. Build	5. Pulse Rate/min	6. Blood Pressure
Cms	Kgs		Normal	98b/m	114/76
167	69.4	24.9	Under weight	SPO ₂ - 99%	
			Over weight	7. Respiratory Rate/min	20b/m

8. Visual Acuity Whether he/she falls in the category of visually impaired

Eye	Vision	9. Dental /Oral Hygiene
Right	6/6	
Left	6/6 Abnormal 10.05	

Rx

Blood sample - Done

X-ray - Done

ECG - Done

Urine L_R - done

Pap sample test → Pt not Agree

Eye test → Done

Green with Rant

Op - Pt coming from Lucknow Chandra
 Pt have no comorbidity.

M/H/O same past medical history,

T-GR - P-8.1mmHg SB-117/76mmHg
 CVS-S₂ - R₂ - 3532 - CMS - C₂ - C₃ - C₄ - C₅ - C₆ - C₇ - C₈ - C₉ - C₁₀ - C₁₁ - C₁₂

Dr. Anam

GD HOSPITAL

80, Feet Road, Ratnapuri, Ratlam

Reg.-NH1985/JUN/2016

Rohini ID-8000080354630

10. Conclusion:

11. Recommendations:

Tests

Diet

OK

पता : 80 फीट रोड, रत्नपुरी, रत्लाम

+91 9752450505, 9111013321

info@gdhospitals.com

www.gdhospitals.com

सभी प्रमुख बीमा कंपनियों से केश लैस उपचार की सुविधा उपलब्ध है

नोट : कृपया अपॉइंटमेंट हेतु हेल्प लाईन नं. पर संपर्क करें।

रविवार को मेडिकल इमरजेंसी होने पर ही आवें।

पुनः दिखाने के लिये रविवार छोड़कर आवें।



आई.सी.यू. सुविधा उपलब्ध

डॉक्टर को दिखाने

के 7 दिन बाद

शुल्क मान्य रहेगा।



GD Pathology

जी.डी. पथोलॉजी

Reg. No. CL/1058/AUG-2020



gdpathologylab@gmail.com
www.gdhospitals.com
80 Feet Road, Ratnapuri, Ratlam (M.P.)
97524-50505, 91110-13321

Name : Mrs. PREETY TOMAR	UHID.No : 23-10286	IPD/OPD: OPD
Age/Sex : 33 Y / F	Accession No. : 20231123027	Category : MEDIWHEEL
Consultant : DEVENDRA VAISHNAV	Bill / IPD No. : 23-31574	



Registration No



Accession No

HAEMATOLOGY REPORT

Sample Collected: 23-Nov-2023 3:13 PM

Sample Type: EDTA BLOOD

Test Name	Results	Unit	Biological Reference Range
Haemoglobin	11.7	gm/dl	12-16
Total Red Blood Count	4.72	Millions/cumm	3.5-5.5
Haematocrite	36.9	%	36.0-51.0
MCV	78.18	fl	77-95
MCH	24.79	pg	26-32
MCHC	31.71	g/dl	30-36
Total Leukocyte Count	6300	cells/cumm	4,000-11,000
Neutrophils	55	%	40-70
Lymphocytes	40	%	20-45
Eosinophils	02	%	2.0-6.0
Monocytes	03	%	2.0-8.0
Basophils	00	%	0-0.1%
Platelet	3.20	lakhs/cmm	1.5-4.5
Erythrocyte Sedimentation Rate			
ESR	18	mm	0-20
BLOOD GROUP			
ABO	B		
Rh TYPE	POSITIVE		

Remarks :

DR. LEKHRAJ PATIDAR

• Home Collection Facility Available •

Note : Diagnostic test have technical limitation. | For technical disparity repeated examination are required.
No legal liability is accepted. | Clinical correlation is requested. This test is not valid for medico-legal purpose.

Name : Mrs. PREETY TOMAR	UHID.No : 23-10286	IPD/OPD: OPD
Age/Sex : 33 Y / F	Accession No. : 20231123027	Category : MEDIWHEEL
Consultant : DEVENDRA VAISHNAV	Bill / IPD No. : 23-31574	


Registration No


Accession No

BIOCHEMISTRY

Sample Collected: 23-Nov-2023 3:13 PM

Sample Type: SERUM

Test Name	Results	Unit	Biological Reference Range
LIPID PROFILE.			
TOTAL CHOLESTROL	167.4	mg/dl	0-200
TRIGLYCERIDES.	191.0	mg/dl	0-150
CHOLESTEROL HDL	47.50	mg/dl	35-85
CHOLESTEROL LDL	81.70	mg/dl	0-130
CHOLESTEROL VLDL	38.20	mg/dl	10-30
TOTAL CHOLESTEROL HDL RATIO	3.52	%	3-4.4
CHOLESTEROL LDL CHOLESTEROL HDL RATIO	1.72	%	0.1-3.0
LIVER FUNCTION TEST (LFT)			
Serum Bilirubin (Total)	0.75	mg/dl	0.1-1.0
Serum Bilirubin (Direct)	0.32	mg/dl	0.0-0.2
Serum Bilirubin (Indirect)	0.43	mg/dl	0.0-0.8
SGOT (AST)	24.98	U/L	9-40
SGPT (ALT)	26.12	U/L	9-40
Alkaline Phosphatase	126.2	U/L	100-250
Total Protein	6.98	g/dL	6.3-8.2
Albumin	4.10	g/dl	3.5-5.0
Globulin	2.88	g/dl	0-5
Albumin Globulin Ratio	1.42	Ratio	1.0-2.3
BLOOD SUGAR (FASTING)	102.7	mg/dl	70 - 110
BLOOD UREA NITROGEN	13.50	mg/dl	5-25
Serum Creatinine	0.91	mg/dl	0.70-1.40
Uric Acid	3.12	mg/dl	2.0-7.0

Remarks :


 DR. LEKHRAJ PATIDAR

• Home Collection Facility Available •

Note : Diagnostic test have technical limitation. | For technical disparity repeated examination are required.
 No legal liability is accepted. | Clinical correlation is requested. This test is not valid for medico-legal purpose.

Name : Mrs. PREETY TOMAR	UHID. No. : 23-10286	IPD/OPD Status : OPD
Age/Sex : 33 Y/Female	Lab No. : 20231123027	consultant : Dr.DEVENDRA VAISHNAV
Ref. Dr.	Receipt no : 23-31574	Location/Bed.No :

Collected at: 23/11/2023 15:13:00



Accession No

BIOCHEMISTRY

Report Gen at:



Registration No

SAMPLE TYPE : EDTA BLOOD

Investigations	Result	Unit	Biological Reference Interval
HbA1C (GLYCOSYLATED Hb)	5.20	%	4.0- 6.0 %

HbA1C

HbA1C

4.0-6.0%

Good control 6-7%

Fair control 7-8%

Poor control >8%

Estimated Blood Glucose (ABG)

97-126 mg/dl

126-154 mg/dl

154-183 mg/dl

183 mg/dl

TECHNOLOGIST


• Home Collection Facility Available •

Dr. LEKHRAJ PATIDAR

Note : Diagnostic test have technical limitation. | For technical disparity repeated examination are required.
 No legal liability is accepted. | Clinical correlation is requested. This test is not valid for medico-legal purpose.

Name : Mrs. PREETY TOMAR	UHID. No. : 23-10286	IPD/OPD Status : OPD
Age/Sex : 33 Y/Female	Lab No. : 20231123027	consultant : Dr.DEVENDRA VAISHNAV
Ref. Dr.	Receipt no : 23-31574	Location/Bed.No : ,

Collected at: 23/11/2023 15:13:00



Accession No

HAEMATOLOGY REPORT

Report Gen at:



Registration No

SAMPLE TYPE : SERUM

Investigations	Result	Unit	Biological Reference Interval
T3 (Total Triiodothyronine)	1.86	nmol/L	1.23-3.07
T4 (Total Thyroxine)	96.40	nmol/L	66-181
TSH (Thyroid Stimulating Hormone)	3.52	mIU/L	0.30-4.2

TECHNOLOGIST

• Home Collection Facility Available •

Dr. LEKHRAJ PATIDAR

Note : Diagnostic test have technical limitation. | For technical disparity repeated examination are required. No legal liability is accepted. | Clinical correlation is requested. This test is not valid for medico-legal purpose.

GD Pathology

जी.डी. पथोलॉजी

Reg. No. CL/1058/AUG-2020



gdpathologylab@gmail.com

www.gdhospitals.com

80 Feet Road, Ratnapuri, Ratlam (M.P.)

97524-50505, 91110-13321

Name : Mrs. PREETY TOMAR
Age/Sex : 33 Y / F
Consultant : DEVENDRA VAISHNAV

UHID.No : 23-10286
Accession No. : 20231123027
Bill / IPD No. : 23-31574

IPD/OPD: OPD
Category : MEDIWHEEL



Registration No



Accession No

CLINICAL PATHOLOGY

Sample Collected: 23-Nov-2023 3:13 PM

Sample Type: URINE,

Test Name

PHYSICAL EXAMINATION.

QUANTITY

COLOUR.

APPEARANCE

PH

SPECIFIC GRAVITY

CHEMICAL EXAMINATION.

Urine Sugar

Urine Albumin

BS/BP

KETONE.

MICROSCOPIC EXAMINATION.

PUS CELLS

EPITHELIAL CELLS

RBC,

CASTS

CRYSTALS

BACTERIA

YEAST

Remarks :

Results

Unit

Biological Reference Range

25ML

PALE YELLOW

CLEAR

ACIDIC

1.015

NIL

NIL

ABSENT

ABSENT

2-4

1-2

NIL

ABSENT

ABSENT

ABSENT

ABSENT

/hpf

/HPF

/HPF

/HPF

NIL

ABSENT

ABSENT

0-4

0-2

0-2

-

-

-

-

-

DR. LEKHRAJ PATIDAR

• Home Collection Facility Available •

Note : Diagnostic test have technical limitation. | For technical disparity repeated examination are required.
No legal liability is accepted. | Clinical correlation is requested. This test is not valid for medico-legal purpose.



Arihant
Pathology Laboratory



Scan QR code to check
report authenticity



MC-2202

sterling
ACCURIS
Pathology lab that cares

Passport No :

LABORATORY TEST REPORT



Patient Information	Sample Information	Client/Location Information
Name : Ms Preety Tomar	Lab Id : 112312501081	Client Name : G Y Foundation@Ratlam
Sex/Age : Female / 33 Y	Registration on : 23-Nov-2023 17:45	Location :
Ref. Id :	Collected at : non SAWPL	Approved on : 24-Nov-2023 12:39 Status : Final
Ref. By : Dr Devendra Vaishnav	Collected on : 23-Nov-2023 17:45	Printed On : 24-Nov-2023 12:39
	Sample Type : Serum	Process At : 1. NRL SAWPL Gujarat Ahmedabad Paldi

Biochemistry

Test	Result	Unit	Biological Ref. Interval
GGT L-y-GlytamyI-p-nitroanilide	18.0	U/L	12 - 43

----- End Of Report -----

Dr. Purvish Darji

Dr. Purvish Darji
MD(Path)

Dr. Sanjeev Shah
MD Path

Dr. Yash Shah
MD Path



Sterling Accuris Pathology Laboratory
Laboratory: (Arihant Pathology Laboratory), 15, Ved Vyas Colony, Ratlam, Madhya Pradesh, 457001
Ph.: 07412-297458

This is an Electronically Authenticated Report.

info.ratlam@sterlingaccuris.com

Website: www.sterlingaccuris.com

Follow us on:



Page 1 of 1



Download Accuris App

GD Hospital

गीतादेवी हॉस्पिटल

Hospital Reg. No: NH/1985/JUN-2016



info@gdhospitals.com
www.gdhospitals.com



+91-97524 50505
+91-91110 13321



80 Feet Road, Ratnapuri,
Ratlam (M.P.) 457001

Date: 23/11/2023.....

Patient Name:- : Preeti Tomar 33year female

X-RAY-CHEST (PA VIEW)

FINDINGS:-

Bilateral lung fields are normal,

The pleural spaces are normal.

Both hila are normal in size have equal density and bear normal relations

The heart and trachea are central in position and no mediastinal abnormal

No mediastinal abnormality visible

The cardiac size is normal.

The domes of diaphragm are normal in position and show smooth outline.

IMPRESSION:-

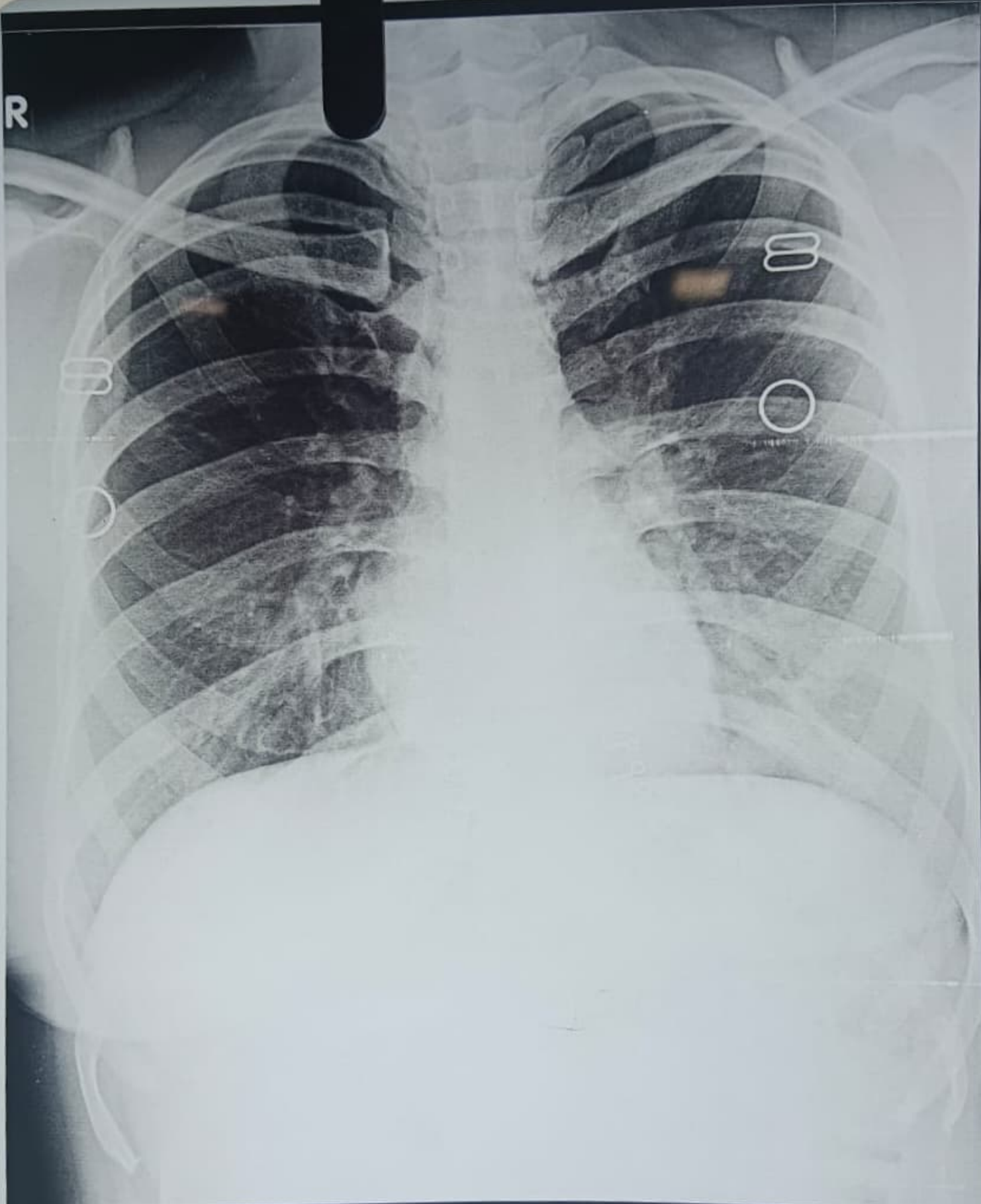
No significant abnormality seen


DR. ANUGRAH PATERIA

MBBS, MD

Consultant Radiologist.

R



MRS PREETY TOMAR 33Y 23-10286 CHEST PA 23/11/2023
GD HOSPITAL 80FEET ROAD RATNPURI, RATLAM PH:9111013321

PT. NAME	MRS. PREETI TOMAR	AGE /SEX/	33YEARS /FEMALE
REF. BY	DR. DEVENDRA VAISHNAV GD HOSPITAL, RATLAM	DATE	23/11/2023

ULTRASOUND WHOLE ABDOMEN

Liver is normal in size (13.1cm) and echotexture. Hepatic venous system appear normal. No focal lesion is seen. Intra and extra hepatic biliary radicles are not dilated. Portal vein and CBD are normal in caliber.

Gall bladder is normal in size & shape. Its lumen is echofree and nonlithiastic.

Pancreas is normal in size outline & echo pattern.

Spleen is normal in size (7.5cm) and echo pattern.

Right kidney is normal in size (11.5x4.7cm), shape and echogenicity with smooth outline. Central pelvicalyceal sinus and corticomedullary ratio are normal. No calculus seen.

Left kidney is normal in size (11.1x5.0cm), shape and echogenicity with smooth outline. Central pelvicalyceal sinus and corticomedullary ratio are normal. A concretion of size 3.8mm noted at mid pole calyx.

Urinary bladder is normal in shape & contour. Its wall is normal. Both V.U.J. are clear.

Uterus is anteverted, appears normal in size (measures 8.9x3.9CM) and shape. Myometrial echotexture appears normal. No focal lesion seen. Cervix appears normal.

Endometrium measures - 6.9mm.

Both ovaries are normal in size, shape & echotexture.

No adnexal mass or cyst is seen. No free fluid is seen in pouch of douglas.

IVC and abdominal aorta are normal in caliber. No evidence of intra abdominal lymphadenopathy. No evidence of ascites is seen.

IMPRESSION: Ultrasound whole abdomen study shows:

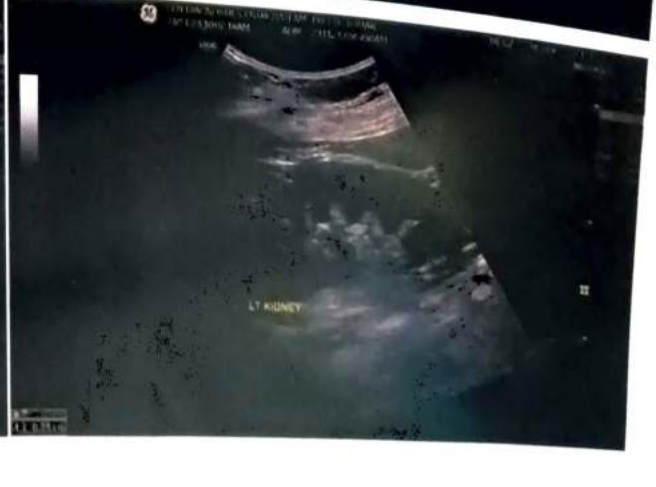
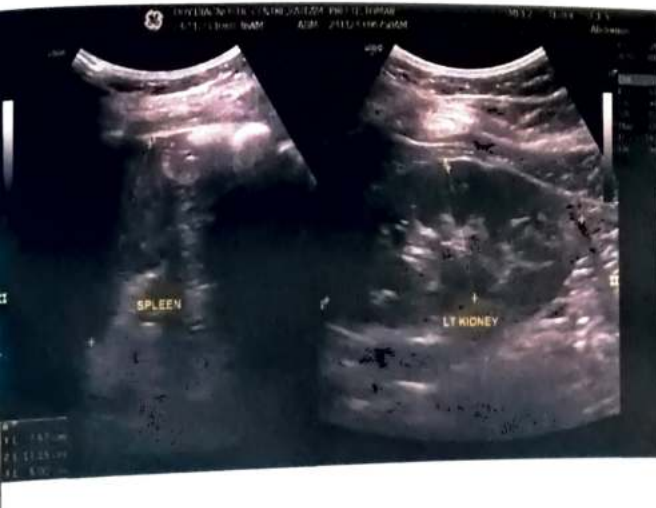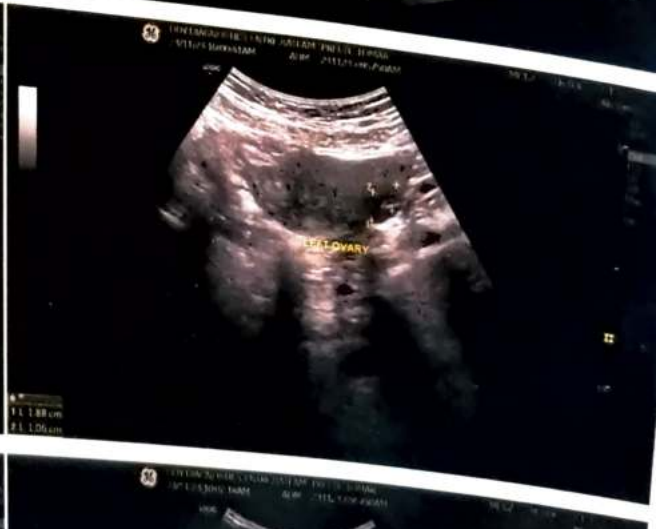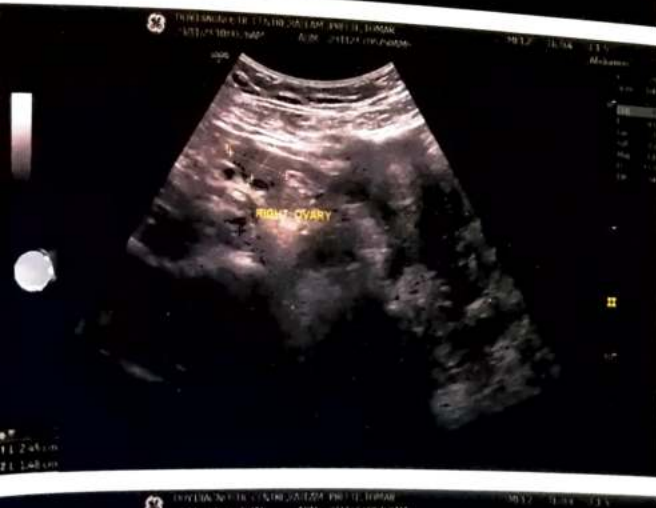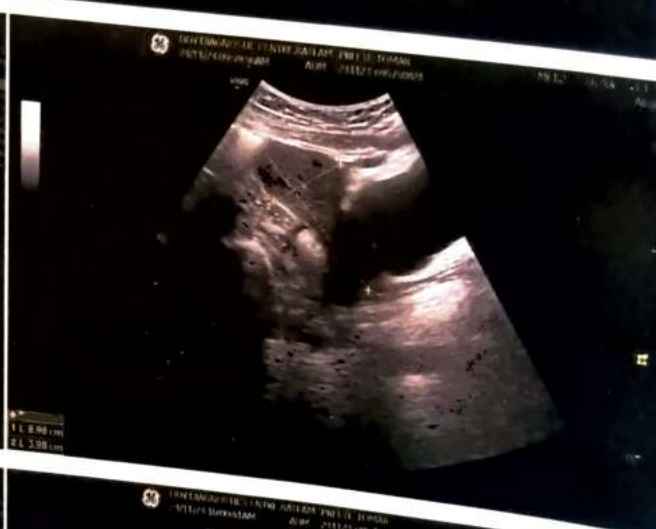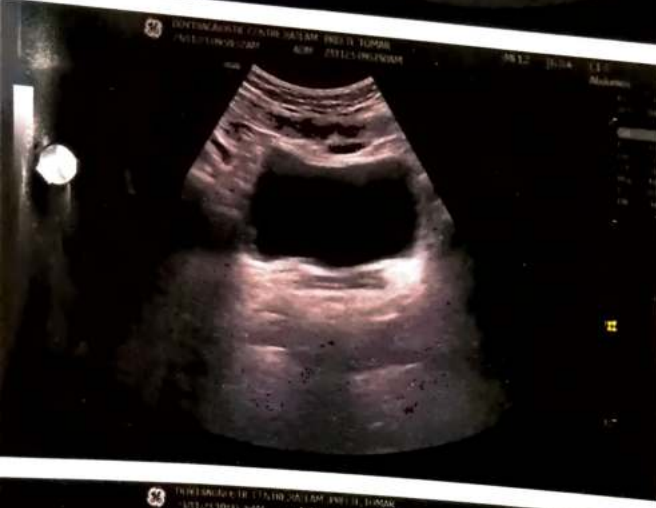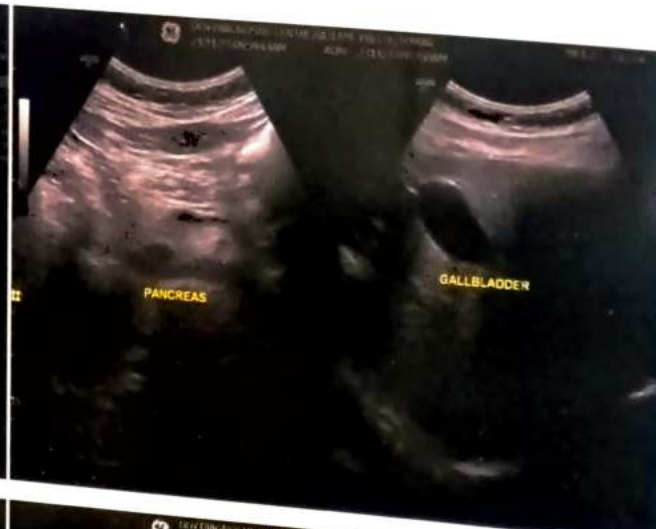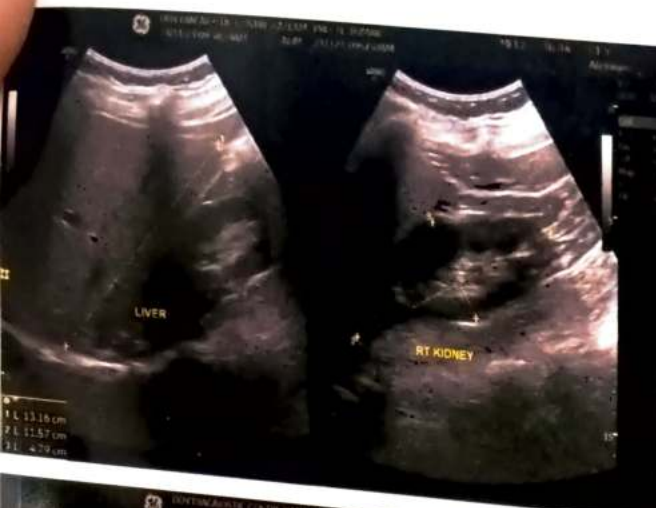- Left renal concretion.

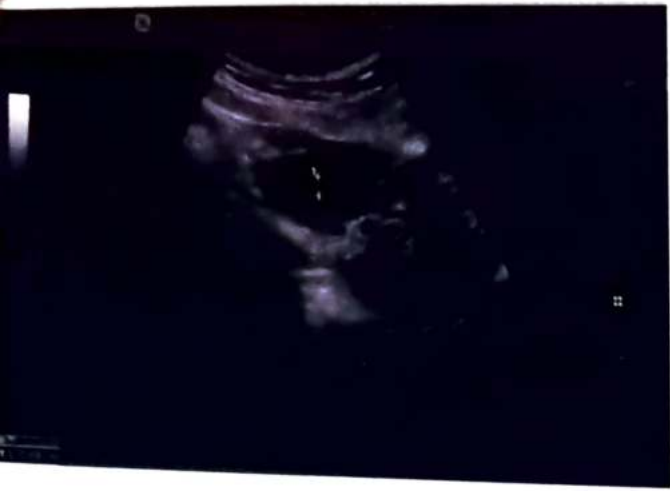Advice: Clinical correlation and further evaluation.

DR ANUGRAH PATERIA
(Radiologist)

It is a professional opinion, not valid for medico legal purpose.

DDY DIAGNOSTIC CENTRE, RATLAM.





10 mm/mV 25 mm/S

ID :
Name : *Preety Tomar*

Age : Years

Gender :

BP :
(mmHg)

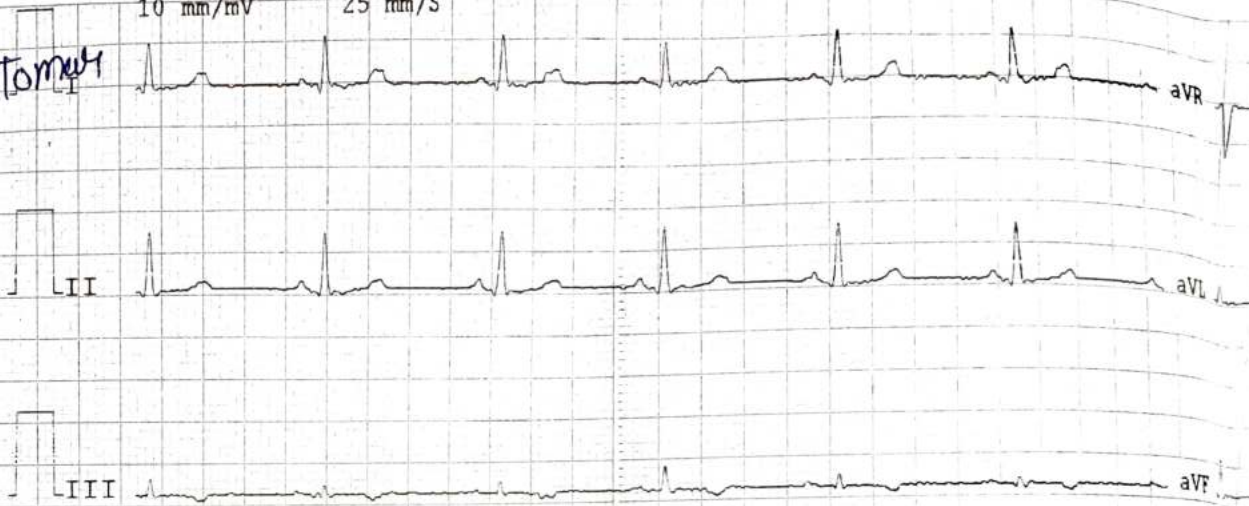Weight : Kgs

Date : 23/11/23
12:51 PM

Note :

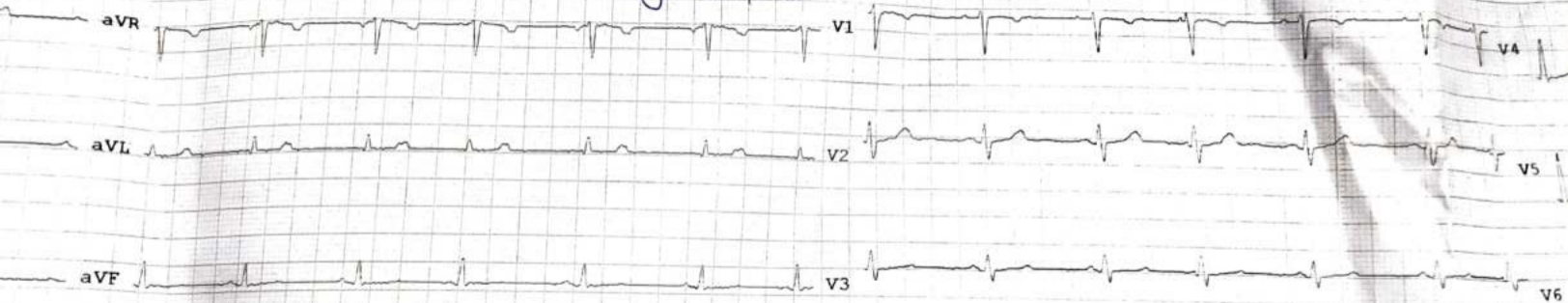
VESTA 301i
(Ver 3.15.33)

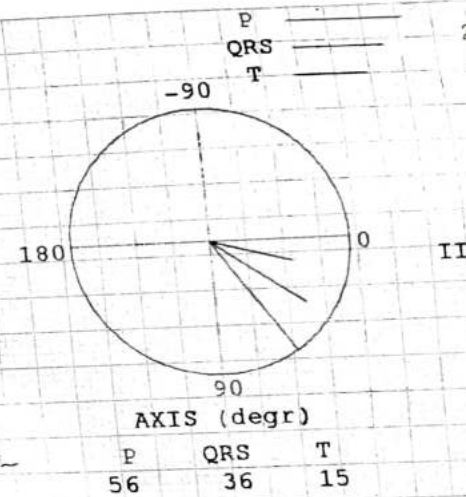
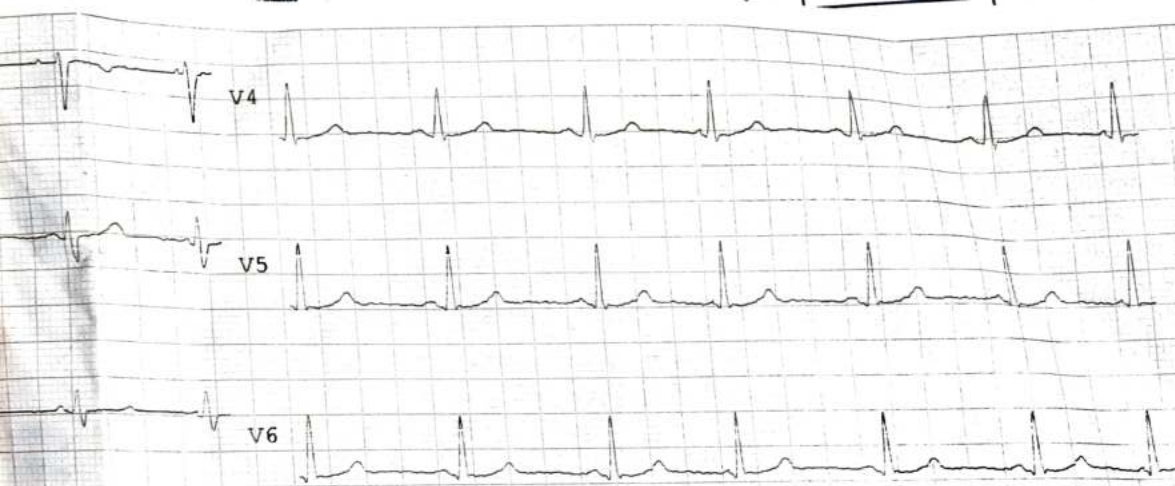www.rmsindia.com



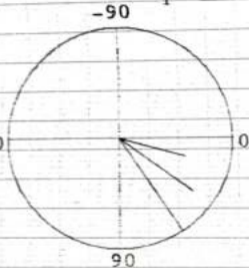
Name Preety Tomar Age 32y female

0.05-35 Hz 50 Hz



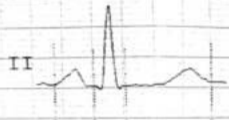


P _____
 QRS _____ 20mm/mV
 T _____ 50mm/S



AXIS (degr)

P	QRS	T
56	36	15



Parameters

HR : 70 BPM
 QRS DUR : 97 mS
 QT INT : 392 mS
 QTc INT : 423 mS
 PR INT : 132 mS
 RR INT : 857 mS
 QT/QTc : 92 %
 QT/RR : 45 %
 RV5/SV1 : 0.81/0.59 mV

Adult Interpretation Report:

Sinus Rhythm
 Normal Sinus Rhythm ECG

Note: Results may be clinically correlated