

Physical Medical Examination Format

NAME:- <u>Abhishek Shukla</u>	DATE:- <u>27/1/24</u>
DESIGNATION:- <u>-</u>	AGE:- <u>33m</u>
EMP CODE:- <u>-</u>	UNIT/DEPARTMENT:- <u>-</u>
BLOOD GROUP:- <u>-</u>	MARTIAL STATUS:-MARRIED/UNMARRIED

MEDICAL EXAMINATION

Complaints (if any)	<u>Nil</u>
Personal /family history	<u>BP</u>
Past Medical /Surgical	<u>Nil</u>
Sensitivity/Allergy (if any)	<u>Nil</u>
Habits	<u>Nil</u>
Occupational History	<u>-</u>

Height:- <u>166</u>	Weight:- <u>70</u>	BMI <u>25.4</u>	Pulse <u>100</u>
Temp:- <u>98.6</u>	SPO2 <u>99.1</u>	Resp:- <u>18</u>	B.P <u>130/80</u>

Remarks


Treatment Recommended (if any):

I Hereby Certify that I have examined Mr/Ms. Abhishek Shukla for pre-employment /periodical medical examination, I have found / not found any disease, illness, contagious illness

I Certify That Employee Is Medically.....

Fit

Unfit


Signature Of Employee

Signature & Seal Of Medical Examiner With

Registration No:-.....

Apollo Health and Lifestyle Limited

(CIN - U85110TG2000PLC046089) Regd. Office: 7-1-617/A, 7th Floor, Imperial Towers, Ameerpet, Hyderabad-500016, Telangana. | Email ID: enquiry@apollohl.com

APOLLO CLINICS NETWORK TELANGANA & AP

Hyderabad (AS Rao Nagar | Chanda Nagar | Jubilee Hills | Kondapur | Manikonda | Nallakunta | Nizampet | Uppal) | Vizag (Seethamma Peta)

Online appointments: www.apolloclinic.com

TO BOOK AN APPOINTMENT

 **1860 500 7788**

Name: Mr. Abhishek Shukla
 Age/Gender: 33 Y/M
 Address: VSKP
 Location: VISAKHAPATNAM, ANDHRA PRADESH
 Doctor:
 Department: LABORATORY
 Rate Plan: VISHAKAPATNAM_06042023
 Sponsor: ARCOFEMI HEALTHCARE LIMITED

MR No: CVIS.0000123214
 Visit ID: CVISOPV120711
 Visit Date: 27-01-2024 09:39
 Discharge Date:
 Referred By: SELF

Vitals:

Date	Pulse (Beats/min)	B.P (mmHg)	Resp (Rate/min)	Temp (F)	Height (cms)	Weight (Kgs)	Body Fat Percentage (%)	Visceral Fat Level (%)	Body Age (Years)	BMI	Waist Circum (cms)	Hip (cms)	Waist (cms)	Waist & Hip Ratio	User
27-01-2024 13:50	100 Beats/min	130/80 mmHg	18 Rate/min	98.6 F	166 cms	70 Kgs	%	%	Years	25.4	cms	cms	cms		AHLL07730

Apollo Health and Lifestyle Limited

(CIN - U85110TG2000PLC046089) Regd. Office: 7-1-617/A, 7th Floor, Imperial Towers, Ameerpet, Hyderabad-500016, Telangana. | Email ID: enquiry@apollohl.com

APOLLO CLINICS NETWORK TELANGANA & AP

Hyderabad (AS Rao Nagar | Chanda Nagar | Jubilee Hills | Kondapur | Manikonda | Nallakunta | Nizampet | Uppal)

Vizag (Seethamma Peta)

Online appointments: www.apolloclinic.com

TO BOOK AN APPOINTMENT

 **1860 500 7788**

Patient Name : Mr. Abhishek Shukla
UHID : CVIS.0000123214
Reported on : 27-01-2024 16:16
Adm/Consult Doctor :
Age : 33 Y M
OP Visit No : CVISOPV120711
Printed on : 27-01-2024 16:18
Ref Doctor : SELF

DEPARTMENT OF RADIOLOGY

ULTRASOUND - WHOLE ABDOMEN

Liver : appears normal in size and increased in echotexture. No focal lesion is seen. PV and CBD normal. No dilatation of the intrahepatic biliary radicals.

Gall bladder is well distended. No evidence of calculus. Wall thickness appears normal. No evidence of periGB collection. No evidence of focal lesion is seen.

Spleen appears normal. No focal lesion seen. Splenic vein appears normal.

Pancreas appears normal in echopattern. No focal/mass lesion/calcification. No evidence of peripancreatic free fluid or collection. Pancreatic duct appears normal.

Both the kidneys appear normal in size, shape and echopattern. Cortical thickness and CM differentiation are maintained. No calculus/ hydronephrosis seen on either side.

Right kidney : 10.6 x 4 cm

Left kidney : 9.7 x 3.5 cm

Urinary Bladder is well distended and appears normal. No evidence of any wall thickening or abnormality. No evidence of any intrinsic or extrinsic bladder abnormality detected.

Prostate : Normal in size and echo texture. No evidence of necrosis/calcification seen. its volume 14 cc

There is no evidence of ascites/ pleural effusion seen.

Patient Name : Mr. Abhishek Shukla
UHID : CVIS.0000123214
Reported on : 27-01-2024 16:16
Adm/Consult Doctor :

Age : 33 Y M
OP Visit No : CVISOPV120711
Printed on : 27-01-2024 16:18
Ref Doctor : SELF

IMPRESSION:-

***FATTY INFILTRATION OF LIVER.**

For clinico-lab correlation / follow - up / further work up.

This is only a screening test.

Printed on:27-01-2024 16:16

---End of the Report---

Aruna Pebbili

Dr. ARUNA PEBBILI
DMRD Radiology
Radiology

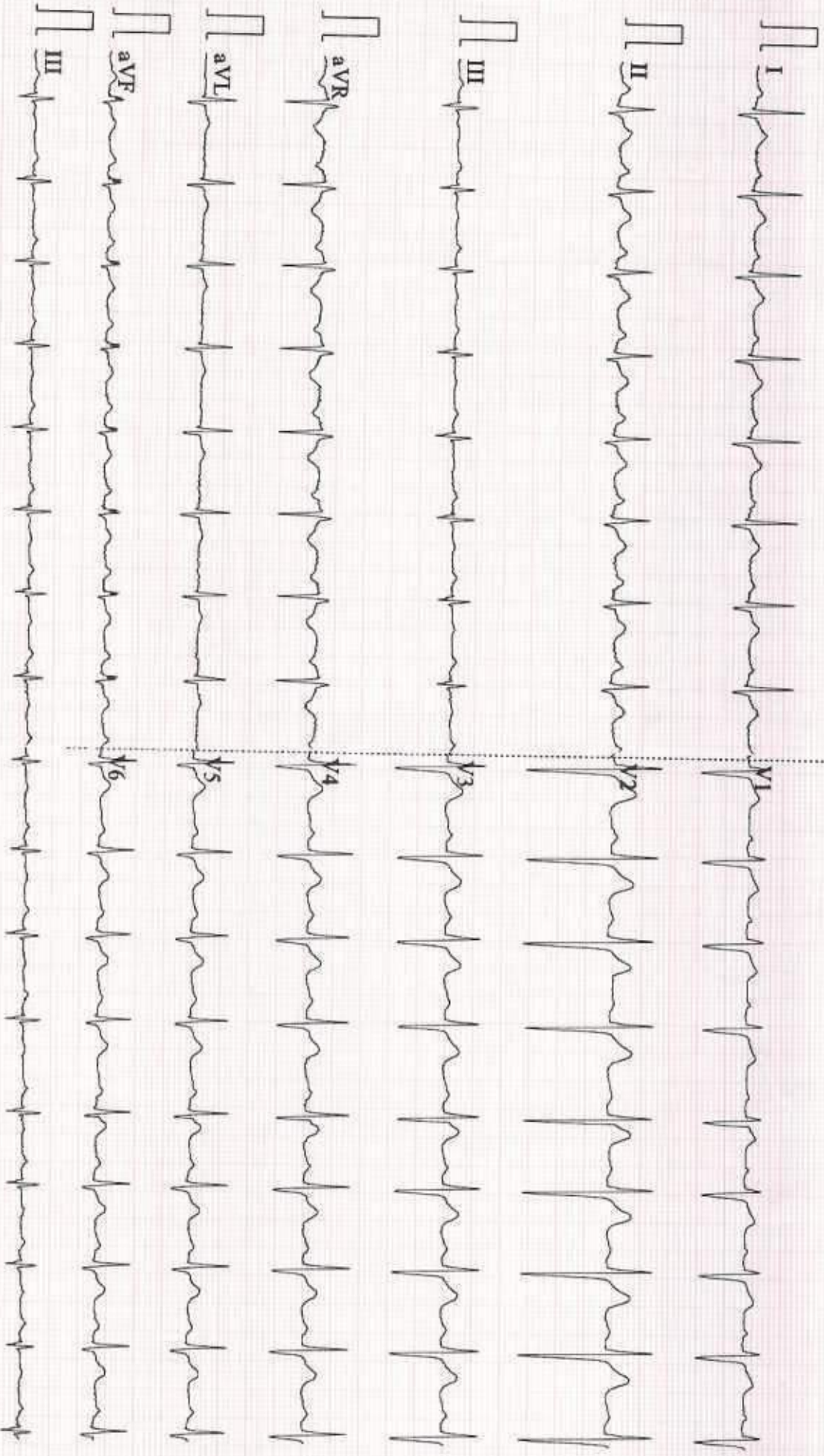
ID: 123214
Abhishek shukla
Male 33Years
Req. No. :

27-01-2024 12:05:47

HR : 100 bpm
P : 100 ms
PR : 156 ms
QRS : 94 ms
QT/QTcBz : 316/408 ms
P/QRS/T : 56/31/40 °
RV5/SV1 : 0.676/0.779 mV

Diagnosis Information:
Sinus tachycardia
Normal ECG except for rate

Report Confirmed by:



Patient Name	Mr. Abhishek Shukla	Age	: 33 Y/M
UHID	CVIS.0000123214	OP Visit No	: CVISOPV120711
Reported By:	Dr. SHASHANKA CHUNDURI	Conducted Date	: 27-01-2024 15:44
Referred By	:SELF		

ECG REPORT

Observation :-

1. Normal Sinus Rhythm.
2. Heart rate is 100 beats per minutes.
3. No pathological Q wave or S-T,T changes seen.
4. Normal P,Q,R,S,T waves and axis.
5. No evidence of chamber, hypertrophy or enlargement seen.

Impression:

NORMAL RESTING ECG.

----- END OF THE REPORT -----

Dr. SHASHANKA CHUNDURI

Exception Letter for CAP

Date: 27/1/24

Client Name: Abhishek Shukla

Gender - male

UHID:

We are Not delivered service due to late

SERVICE Eye


So that we are unable to close all reports, once client visited again will close.

Regards,

EMP Name: Y. Syolli

Apollo clinic,

Vizag.

Client Name: 

Signature: •

Ph no:

27/1/24

DR. VINAY KUMAR
MS ENT

NAME : Abhishek Shukla AGE : 33yr SEX : Male

Pt. came for Routine ENT
check-up

- O/E
- 1) EAR → SLT.M 1 (N)
 - 2) Nose → NAD
 - 3) Throat → NAD

Result → ENT → Normal

T.V.V.V
27/1/24

Patient Name	: Mr. Abhishek Shukla	Age	: 33 Y/M
UHID	: CVIS.0000123214	OP Visit No	: CVISOPV120711
Conducted By:	: Dr. SHASHANKA CHUNDURI	Conducted Date	: 27-01-2024 17:18
Referred By	: SELF		

2D-ECHO WITH COLOUR DOPPLER

Dimensions:

Ao (cd)	2.4 CM
LA (cs)	2.5 CM
LVID (cd)	2.9 CM
LVID (cs)	2.8 CM
IVS (Ed)	1.0 CM
LVPW (Ed)	0.9 CM
EF	62.00%
%FD	33.00%

MITRAL VALVE : NORMAL

AML NORMAL

PML NORMAL

AORTIC VALVE NORMAL

TRICUSPID VALVE NORMAL

RIGHT VENTRICLE NORMAL

INTER ATRIAL SEPTUM NORMAL

INTER VENTRICULAR SEPTUM NORMAL

AORTA NORMAL

RIGHT ATRIUM NORMAL

LEFT ATRIUM NORMAL

Pulmonary Valve NORMAL

PERICARDIUM NORMAL

LEFT VENTRICLE:

NO REGIONAL WALL MOTION ABNORMALITY

NORMAL LEFT VENTRICULAR SYSTOLIC FUNCTION

COLOUR AND DOPPLER STUDIES:

PF:0.8 m/sec.
MF:E>A.
AF:0.9 m/sec.

Apollo Health and Lifestyle Limited

(CIN - U85110TG2000PLC046089) Regd. Office: 7-1-617/A, 7th Floor, Imperial Towers, Ameerpet, Hyderabad-500016, Telangana. | Email ID: enquiry@apollohl.com

APOLLO CLINICS NETWORK TELANGANA & AP

Hyderabad (AS Rao Nagar | Chanda Nagar | Jubilee Hills | Kondapur | Manikonda | Nallakunta | Nizampet | Uppal)

Vizag (Seethamma Peta)

Online appointments: www.apolloclinic.com

TO BOOK AN APPOINTMENT



1860 500 7788

IMPRESSION :
NORMAL CARDIAC SIZE.
NO RWMA.
GOOD LV SYSTOLIC FUNCTION.
NO PERICARDIAL EFFUSION.
LVEF:62%

Dr. SHASHANKA
CHUNDURI



Government of India

आभिशेक शुकिया

Abhishek Shukla

आभिशेक शुकिया

Male

7759 8400 6096



ആധാർ - സാധാരണക്കാരന്റെ അറിവ്

Vizag

27/1/24

Dear Sir/Madam

Today capsule clients came for health checkup at Apollo clinic. but doctor signature did not completed because blood reports not released due to software issue. So I update tomorrow.

Thanking you.

Yours faithfully
Apollo clinic vizag,