


MER- MEDICAL EXAMINATION REPORT

Date of Examination	09/11/2024		
NAME	SHIVAM SHUKLA		
AGE	35	Gender	MALE
HEIGHT(cm)	168 cm	WEIGHT (kg)	98 kg
B.P.	120/80		
EKG	NORMAL		
X Ray	NORMAL		
Vision Checkup	NORMAL		
Present Ailments	-		
Details of Past ailments (If Any)	-		
Comments / Advice : She/He is Physically Fit	fit		
<p>BMI = 34.7 kg/m<sup>2</sup> (Obese class 2)</p>			

Panel Medical Examiner \_\_\_\_\_  
 Triveni Diagnostic & Research Centre  
 Agrawal Plaza, B-7, H.I.G. Main Road,  
 INDORE

Signature with Stamp of Medical Examiner  
  
 Dr. Mukesh Dubey  
 (MBBS DCP)  
 Registration No.-10632

भारत सरकार  
Government of India

आधार

Issue Date: 21/11/2013



शिवम शुक्ला  
Shivam Shukla  
जन्म तिथि / DOB: 10/06/1989  
पुरुष / Male

9221 5891 5959

मेरा आधार, मेरी पहचान

भारतीय विशिष्ट पहचान प्राधिकरण  
Unique Identification Authority of India

AADHAAR

पता: रामसिया शुक्ला, 56, ग्राम धेरा तहसील मीरजा, पोस्ट धेरा इलाहाबाद बैंक के पास, पोस्ट धेरा इलाहाबाद बैंक के पास, धेरा, रीवा, मध्य प्रदेश, 486333

Address: ramsiya shukla, 56, 56, post dhera near allahabad bank, gram dhera tehsil msuganj, Dhera, Rewa, Madhya Pradesh, 486333

Issue Date: 27/06/2021



9221 5891 5959

1947 help@uidai.gov.in www.uidai.gov.in

Panel Medical Examiner  
Triveni Diagnostic & Research Centre  
Agrawal Plaza, 5-7 - G. Ram Road,  
INDORE

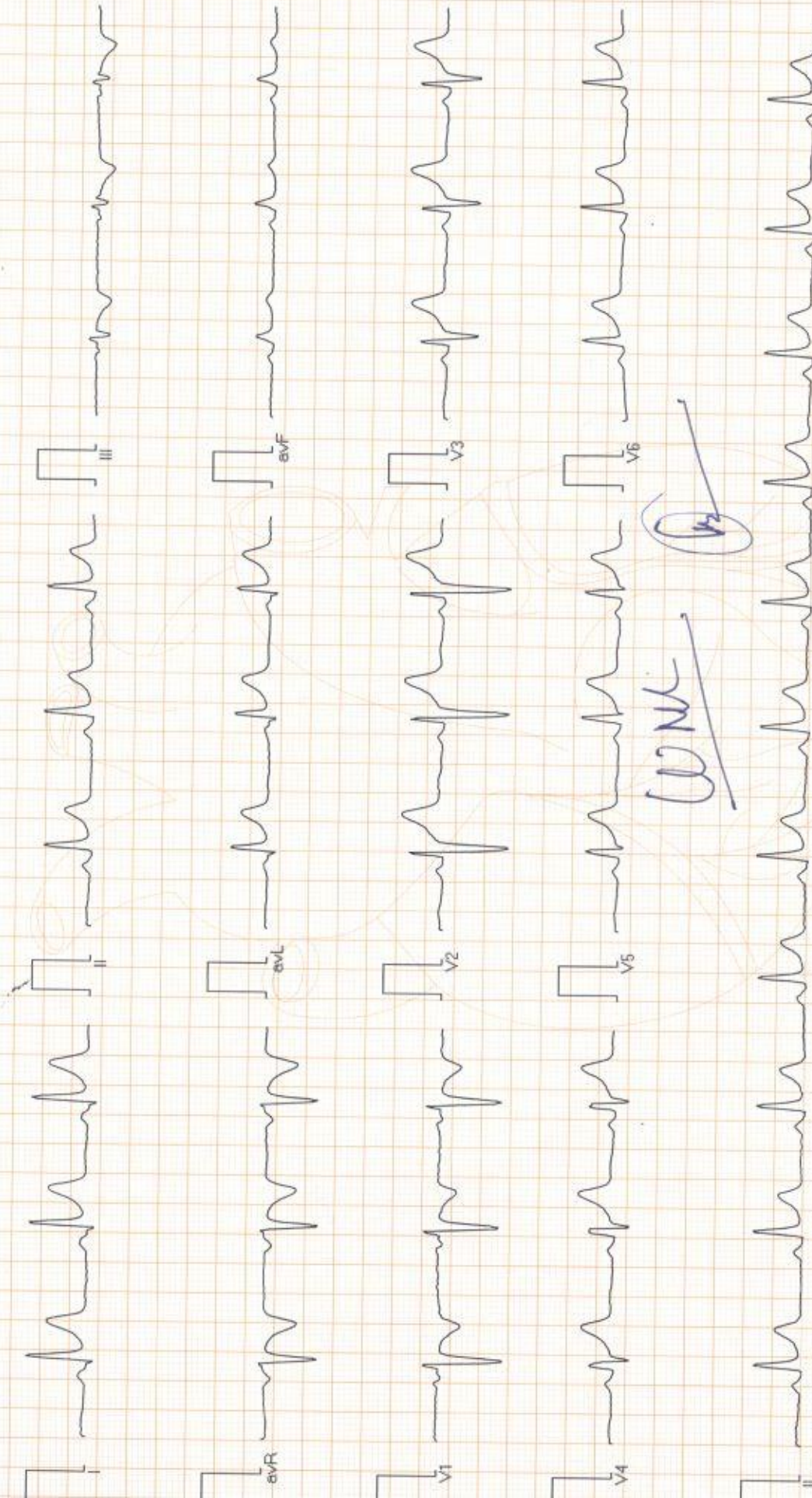


# RIVENI DIAGNOSTIC AND RESEARCH CENTER INDORE

88 / MR SHIVAM SHUKLA / 35 Yrs / M / Non Smoker

Heart Rate : 69 bpm / Tested On : 09-Nov-24 09:55:52 / HF 0.05 Hz - LF 20 Hz / Notch 50 Hz / Sn 1.00 Cm/mV / Sw 25 mm/s

## ECG



Heart Rate : 69 bpm  
PR Interval : 138 ms  
QRS Duration : 92 ms  
QTc Int : 374/390 ms  
RS-T axis : 27.00 • 25.00 • 7.00 •

Pandey Hospital  
Triveni Diagnostic & Research Centre  
Agreemurhara, B-7, H.B.G. main Road,  
INDORE

Reported By:



# डॉ. मनोज भटनागर

एम.एस.

नेत्र रोग विशेषज्ञ एवं सर्जन



6 to ver Reg. No. 5453

Rx Shivam Sheela  
35m

### विशेषज्ञ

- इन्ट्राऑक्यूलर लेंस इम्प्लांट
- फेको विधि द्वारा बाँध टाँके का मोतियाबिंद ऑपरेशन
- कॉन्टेक्ट लेंस विशेषज्ञ
- लेसिक लेजर (चश्मा उतारने की विधि)

दिनांक 9-11-24

Vision  $\left\{ \begin{array}{l} 6/6 \\ 6/6 \end{array} \right.$

Near Vision  $\left\{ \begin{array}{l} N/6 \end{array} \right.$

Colour Vision Normal

Ext-Exami NAD

Findings MB - Mild Physiological Cappage

- Rest NAD

# Dr. Bhatnagar's Multispeciality Dental Clinic

**Dr. Nikita Bhatnagar**

B.D.S., M.D.S. (Gold Medalist)

Reg. No. A-3503

Mob.: 96699-37000

Clinic: E-4, HIG Colony, HIG Main Road  
Indore-452011 (M.P.)

**डॉ. निकिता भटनागर**

बी.डी.एस., एम.डी.एस., (गोल्ड मेडलिस्ट)

रजि. नं. ए-3503

मो.: 96699-37000

क्लीनिक: ई-4, एच.आई.जी. कारलोनी, एच.आई.जी. मेनरोड  
इन्दौर-452011 (म.प्र.)

Mr. Shivam Shukla

Date..... 09/11/2024

Colgate perogard toothpaste

Vantij Aqua m/c

Thermoseal Ultralsoft  
toothbrush

Tab. Truance plus

→

x 15 days

1  
Klikuli

(15)

NB

## COSMETIC DENTISTRY

- Smile designing
- Teeth whitening & bleaching
- Tooth jewellery
- Composite & ceramic veneers
- Invisalign / Orthodontic braces
- Tooth colored fillings

## GENERAL DENTISTRY

- Instant Dental X-rays
- Root Canal Treatment
- Gum treatment
- Atraumatic Extractions
- Wisdom tooth treatment
- Crown and bridges

## PREVENTIVE DENTISTRY

- Teeth cleaning & polishing
- Fluoride application
- Treatment for Precancerous
- Conditions & lesions
- Tobacco chewing habit cessation

## GERIATRIC DENTISTRY

- Dental Implants
- Dentures
- Oro-facial pain
- TMJ Disorders

Adv: ① Extraction  $\bar{c}$   $\frac{1}{6}$

② Filling Class II  $\bar{c}$   $\frac{1}{7}$

③ Implant  $\bar{c}$   $\frac{1}{6}$  (missing).

Notice ...





# Triveni Diagnostic Centre

Reg No. : 98584 VISITID : 0000103212  
PATIENT NAME : Mr. SHIVAM SHUKLA SPEC. NO : 1905432872  
AGE/SEX : 35 YEARS/MALE SAMP. DATE : 09/11/2024 12:29:00  
REF. BY : Dr. ARCOFEMI HEALTHCARE LIMITED RESULT DATE : 09/11/2024 18:52:07

## HEMATOLOGY

### CBC (COMPLETE BLOOD COUNT)

NAME OF TEST	RESULT VALUE	REFERENCE RANGE	UNIT
HAEMOGLOBIN	14.1	13.5 - 18	gm/dl
TOTAL RBC COUNT	4.67	4 - 6.5	mill/cummm
HAEMATOCRIT (PCV)	41.9	41.5 - 50.4	%
MEAN CORPUS VOL(MCV)	89.72	80 - 96	f l
MEAN CORPUS HB (MCH)	30.19	27.5 - 33.2	picograms
MEAN CORPUS HB CONC (MCHC)	33.65	33.4 - 35.5	%
RDW	12.4	11.5 - 15.5	%
PDW	17.8	-	f l
MPV	11.1	-	f l
PCT	0.19	-	%
P-LCR	45.1	-	%
TOTAL WBC	7100	4000 - 11000	/cumm
PLATELET COUNT	1.80	1.5 - 4.0	Lacs/cumm
<b>DIFFERENTIAL COUNT</b>			
NEUTROPHILS	54	40 - 70	%
LYMPHOCYTES	43	20 - 40	%
MONOCYTES	02	1 - 8	%
EOSINOPHILS	01	0 - 6	%
BASOPHILS	00	0 - 1	%
ABSOLUTE NEUTROPHILS	3834	4000 - 7500	/cumm
ABSOLUTE LYMPHOCYTES	3053	800 - 4950	/cumm
ABSOLUTE MONOCYTE	142	0 - 880	/cumm
ABSOLUTE EOSINOPHIL	71	40 - 400	/cumm
ABSOLUTE BASOPHIL	00	0 - 110	/cumm
ESR	12	0 - 20	mm at end of 1
MP (MALARIA PARASITE)	.	-	

METHOD:- By five part automated analyzer (sysmex XS1000 i) Japan

DR. MUKESH DUBEY  
(MBBS. DCP) (DIRECTOR)

DR. VIJAY BHURIYA  
MBBS DMRD

DR. YOGESH PAWDE  
M. D. (CONS. PATHOLOGIST)

DR. P.S. TRIPATHI  
M.D.(RADIO DIAGNOSIS)

DR. SANJAY YADAV  
CON. MICROBIOLOGIST

Report Checked By:

Address : Agrawal Plaza, B-7, HIG Main Road, Indore Ph. : 0731-4289992-3  
Website : www.trivenidiagnostic.com, email : trivenidi@trivenidi.com



# Triveni Diagnostic Centre

Reg No. : 98584 VISITID : 0000103212  
PATIENT NAME : Mr. SHIVAM SHUKLA SPEC. NO : 1905432870  
AGE/SEX : 35 YEARS/MALE SAMP. DATE : 09/11/2024 12:29:00  
REF. BY : Dr. ARCOFEMI HEALTHCARE LIMITED RESULT DATE : 09/11/2024 18:48:07

## DEPARTMENT OF PATHOLOGY

NAME OF TEST	RESULT VALUE	REFERENCE RANGE	UNIT
<b>BLOOD GROUP</b>			
BLOOD GROUP	"B"	-	
RH FACTOR	Positive	-	
<b>RESULT REMARKS :</b>			
<b>FBS</b>			
FBS	279	70 - 110	mg / dl
<b>RESULT REMARKS :</b>	Test done by -"Roche COBAS- ENTEGRA 400 PLUS "fully bichemistry analyser .		
<b>PPBS</b>			
PPBS (POST PRANDIAL BLOOD SUGAR)	384	70 - 140	mg / dl
<b>RESULT REMARKS :</b>	Test done by -"Roche COBAS- ENTEGRA 400 PLUS "fully bichemistry analyser .		
<b>RENAL PROFILE</b>			
UREA	28	10 - 40	mg / dl
CREATININE	0.91	0.7 - 1.4	mg / dl
SERUM SODIUM	139.4	135 - 155	mmol/L
SERUM POTASIUM	4.20	3.5 - 5.5	mmol/L
<b>RESULT REMARKS :</b>			

DR. MUKESH DUBEY  
(MBBS DCP) (DIRECTOR)

DR. VIJAY BHURIYA  
MBBS DMRD

DR. YOGESH PAWDE  
M. D. (CONS. PATHOLOGIST)

DR. P.S. TRIPATHI  
M.D. (RADIO DIAGNOSIS)

DR. SANJAY YADAV  
CON. MICROBIOLOGIST

Report Checked By :





# Triveni Diagnostic Centre

Reg No. : 98584 VISITID : 0000103212  
PATIENT NAME : Mr. SHIVAM SHUKLA SPEC. NO : 1905432871  
AGE/SEX : 35 YEARS/MALE SAMP. DATE : 09/11/2024 12:29:00  
REF. BY : Dr. ARCOFEMI HEALTHCARE LIMITED RESULT DATE : 09/11/2024 18:51:27

## BIO-CHEMISTRY

### HBA1 C (GLYCOSYLATED HEAMOGLOBIN)

NAME OF TEST	RESULT VALUE	REFERENCE RANGE	UNIT
HBA1 C (GLYCOSYLATED HEAMOGLOBIN)	9.0	Normal: 4-6 Good control: 6.1-7.0 Fair control : 7.0-8.2 Unsatisfactory control: 8.0-10.2 Poor control: Above 10.0	%
MEAN PLASMA GLUCOSE (MPG)	212	Exelent Control: 90-120 Good Control: 121-150 Avrege Control: 151-180 Action Suggested: 181-210 Panic value : >211	mg/dL

Test done by -"Roche COBAS- ENTEGRA 400 PLUS "fully bichemistry analyser .

METHOD BY: Turbidimetric inhibition immunoassay(TINIA)

Average blood glucose value is calculated from HBA1C value and indicates average blood sugar level over past three months.

DR. MUKESH DUBEY  
(MBBS, DCP) (DIRECTOR)

DR. VIJAY BHURIYA  
MBBS DMRD

DR. YOGESH PAWDE  
M. D. (CONS. PATHOLOGIST)

DR. P.S. TRIPATHI  
M.D. (RADIO DIAGNOSIS)

DR. SANJAY YADAV  
CON. MICROBIOLOGIST

Report Checked By:

Address : Agrawal Plaza, B-7, HIG Main Road, Indore Ph. : 0731-4289992-3  
Website : www.trivenidiagnostic.com email : trivenidiagnostic@unhcc.co.in



# Triveni Diagnostic Centre

Reg No. : 98584  
PATIENT NAME : Mr. SHIVAM SHUKLA  
AGE/SEX : 35 YEARS/MALE  
REF. BY : Dr. ARCOFEMI HEALTHCARE LIMITED

VISITID : 0000103212  
SPEC. NO : 1905432868  
SAMP. DATE : 09/11/2024 12:29:00  
RESULT DATE : 09/11/2024 18:49:30

NAME OF TEST	RESULT VALUE		REFERENCE RANGE	UNIT
	IN RANGE	OUT RANGE		
<b>LFT (LIVER FUNCTION TEST)</b>				
TOTAL BILIRUBIN	0.79		0.2 - 1.3	mg/dL
DIRECT BILIRUBIN	0.41		0.2 - 0.65	mg / dl
INDIRECT BILIRUBIN	0.38		0.2 - 0.8	mg / dl
SGOT(AST)	28		0 - 40	U / L
SGPT(ALT)	20		0 - 40	U / L
ALKALINE PHOSPHATASE	96		37 - 143	U / L
PROTEINS	6.87		6 - 8.3	g / dl
ALBUMIN	4.12		3.5 - 5	gm/dl
GLOBULIN	2.75		1.9 - 3.5	g / dl
A.G.RATIO	1.49		0.5 - 2	mg / dl
PT (PROTHROMBIN TIME)		14	-	seconds
CONTROL		14	-	seconds
(INR) INTERNATIONALNARMLISED RATIO		1.0	-	

**REMARKS :**

METHOD: BY COBAS INTEGRA 400 PLUS.

DR. MUKESH DUBEY  
(MBBS, DCP) (DIRECTOR)

DR. VIJAY BHURIYA  
MBBS DMRD

DR. YOGESH PAWDE  
M. D. (CONS. PATHOLOGIST)

DR. P.S. TRIPATHI  
M.D. (RADIO DIAGNOSIS)

DR. SANJAY YADAV  
CON. MICROBIOLOGIST

Report Checked By :

Address : Agrawal Plaza, B-7, HIG Main Road, Indore Ph. : 0731-4289992-3  
email : trivenidiagnostic@yahoo.co.in





# Triveni Diagnostic Centre

Reg No. : 98584 VISITID : 0000103212  
PATIENT NAME : Mr. SHIVAM SHUKLA SPEC. NO : 1905432868  
AGE/SEX : 35 YEARS/MALE SAMP. DATE : 09/11/2024 12:29:00  
REF. BY : Dr. ARCOFEMI HEALTHCARE LIMITED RESULT DATE : 09/11/2024 18:50:35

## BIO-CHEMISTRY

NAME OF TEST	RESULT VALUE		REFERENCE RANGE	UNIT
	IN RANGE	OUT RANGE		
<b>GAMA GT</b>				
<b>GAMA GT</b>				
GGT (GAMMA GLUTAMYL TRANSFERASE)	14.2		8 - 52	U / L
<b>LIPID PROFILE</b>				
CHOLESTEROL	181		0 - 200	mg / dl
TRIGLYCERIDES	138		50 - 190	mg / dl
HDL(HIGH DENSITY LIPIDS)	52		35 - 65	mg / dl
LDL	101.4		50 - 190	mg / dl
VLDL (VERY LOW DENSITY LIPIDS)	27.6		15 - 30	mg / dl
Cholestrol : HDL		3.48	3.5 - 5.5	
LDL : HDL	1.95		0 - 3.5	mg / dl

### DESCRIPTION :

{\rtf1\ansi\ansicpg1252\deff0\deflang1033{\fonttbl{\f0\fnil\fcharset0 Arial;}}  
\viewkind4\uc1\pard\fs17 Test done by -"Roche COBAS- ENTEGRA 400 PLUS "fully bichemistry analyser .  
\par  
\par }



# Triveni Diagnostic Centre

Reg No. : 98584 VISITID : 0000103212  
PATIENT NAME : Mr. SHIVAM SHUKLA SPEC. NO : 1905432868  
AGE/SEX : 35 YEARS/MALE SAMP. DATE : 09/11/2024 12:29:00  
REF. BY : Dr. ARCOFEMI HEALTHCARE LIMITED RESULT DATE : 09/11/2024 18:49:50

## IMMUNO ASSAY

### T3,T4 TSH

NAME OF TEST	RESULT VALUE	REFERENCE RANGE	UNIT
T3 (TRIIODOTHYRONINE)	0.88	Adults:- 0.60-1.58 Children:- 0-3 days:- 0.96- 2.92 1-11 months 0.81-2.81 1-5 years 0.83-2.52 6-10 years 0.92-2.19 11-15years 0.83-2.15	ng/ml
T4 (THYROXINE)	7.4	Adults:- 5.01-11.0 Children:- 0-3 days 11.80-22.60 4-30 days not Established 1-2 weeks 9.80-16.60 1-4 months 7.20-14.40 4-12 months 7.80-16.50	ug/dl
TSH (THYROID STIMULATING HORMONE)	4.09	Adults:- 0.38-4.31 Children:- 0-3 days:- 1.0-39.0 4-30 days:- 0.43-16.1 2-12 months:- 0.62-8.05 2-6 years:- 0.54-4.53 7-11 years:- 0.66-4.14 12-19 years:- 0.53-3.59	uIU/ml

Method: By AIA-360 (TOSOH) fully automated electro chemiluminescence immunoassay

**INTERPRETATION:** Suppressed TSH values are seen in hyperthyroid patients with the exception of hyperthyroidism caused by a TSH producing pituitary tumors. In addition TSH is suppressed in individuals treated with the exogenous thyroid hormones. Elevated TSH values are seen in primary hypothyroidism with the exception of hypothyroidisms caused by pituitary disorders. Note: Total T3 and T4 values may also be altered in other conditions due to changes in serum proteins or binding sites pregnancy, drugs (Androgens, Estrogens, O C pills, Phenyton) nephrosis etc. In such cases free T3 and T4 give corrected values.

**DR. MUKESH DUBEY**  
(MBBS, DCP) (DIRECTOR)

**DR. VIJAY BHURIYA**  
MBBS DMRD

**DR. YOGESH PAWDE**  
M. D. (CONS. PATHOLOGIST)

**DR. P.S. TRIPATHI**  
M.D. (RADIO DIAGNOSIS)

**DR. SANJAY YADAV**  
CON. MICROBIOLOGIST

Report Checked By:

Address : Agrawal Plaza, B-7, HIG Main Road, Indore Ph. : 0731-4289992-3  
Website : www.trivenidiagnostic.com email : trivenidiagnostic@yahoo.co.in

Page 1 of 1





# Triveni Diagnostic Centre

Reg No. : 98584 VISITID : 0000103212  
PATIENT NAME : Mr. SHIVAM SHUKLA SPEC. NO : 1905432869  
AGE/SEX : 35 YEARS/MALE SAMP. DATE : 09/11/2024 12:29:00  
REF. BY : Dr. ARCOFEMI HEALTHCARE LIMITED RESULT DATE : 09/11/2024 18:51:45

## CLINICAL-PATHOLOGY

### URINE EXAMINATION

NAME OF TEST	RESULT VALUE	REFERENCE RANGE	UNIT
<b>PHYSICAL EXAMINATION</b>			
QUANTITY	30	-	ml
COLOUR	Pale Yellow	-	
APPEARANCE	Clear	-	
REACTION	Acidic	-	
Specific Gravity	1.010	-	
<b>CHEMICAL EXAMINATION</b>			
ALBUMIN	Nil	-	
URINE SUGAR	Nil	-	
Ketone Bodies	Nil	-	
BLOOD	Nil	-	
Bile Pigment	Nil	-	
Bile Salts	Nil	-	
<b>MICROSCOPIC EXAMINATION</b>			
Pus Cells	3-4 /hpf	2 - 5	/hpf
Epithelial Cells	2-3 /hpf	5 - 10	
RBCs	Nil	-	/hpf
Casts	Nil	-	
Crystals	Nil	-	
Spermatozoa	Nil	-	
Bacteria	Nil	-	
Others		-	

DR. MUKESH DUBEY  
(MBBS DCP) (DIRECTOR)

DR. VIJAY BHURIYA  
MBBS DMRD

DR. YOGESH PAWDE  
M. D. (CONS. PATHOLOGIST)

DR. P.S. TRIPATHI  
M.D. (RADIO DIAGNOSIS)

DR. SANJAY YADAV  
CON. MICROBIOLOGIST

Report Checked By:

Address : Agrawal Plaza, B-7, HIG Main Road, Indore Ph. : 0731-4289992-3  
Website : www.trivenidiagnostic.com email : trivenidiagnostic@yahoo.co.in

Page 1 of 1



# Triveni Diagnostic Centre

Reg. No. : 98584	Visit ID	: O000103212
Patient Name : Mr. SHIVAM SHUKLA	Order Date	: 09/11/24 12:18PM
Age / Sex : 35 YEARS / MALE	Report Date	: 09/11/24 02:42PM
Ref. By : Dr. ARCOFEMI HEALTHCARE LIMITED		

## SONOGRAPHY

### USG WHOLE ABDOMEN(MALE)

Liver is normal in size 12.7cm , shape and **echotexture appears mildly raised**. No focal parenchymal lesion noted. Portal vein is of normal caliber. There is no evidence of dilatation of Intra and extra hepatic biliary radicals.

Gall bladder appears normal. Does not show any sludge or calculus. Its walls are smooth and normal in wall thickness.

Pancreas is normal in size, shape and shows normal echogenecity, no localised solid or cystic mass is identified in pancreas. Pancreatic duct is not dilated.

Spleen is normal in size 12.1cm , and shows normal echogenecity, no localised or cystic mass is identified in spleen.

Both kidneys are normal in size (Rt. 10.2 x 5.4 cm & Lt. 10.8 x 5.5 cm), shape and echotexture. There is no evidence of dilation of collecting system of either of the kidney. Ureters are not dilated.

Visualised bowel loops appear normal.  
No evidence of any adenopathy or ascitis.

Urinary bladder is adequately filled with anechoic contents. The wall appears thin with smooth mucosa.

Prostate appears normal in size , shape and echotexture.

### IMPRESSION: -Mild fatty liver.

Kindly correlate.

DR. MUKESH DUBEY  
(MBBS, DCP)

DR. VIJAY BHURIYA  
MBBS DMRD

DR. AMIT SHANKHWAR  
M.D. RADIO DIAGNOSIS

DR. P.S. TRIPATHI  
M.D. (RADIO DIAGNOSIS)

DR. SANJAY YADAV  
CONSULTANT MICROBIOLOGIST





# Triveni Diagnostic Centre

Reg. No. : 98584 Visit ID : O000103212  
Patient Name : Mr. SHIVAM SHUKLA  
Age / Sex : 35 YEARS / MALE Order Date : 09/11/24 12:18PM  
Ref. By : Dr. ARCOFEMI HEALTHCARE LIMITED Report Date : 09/11/24 02:10PM

## X-RAY X-RAY CHEST PA

Trachea is central.

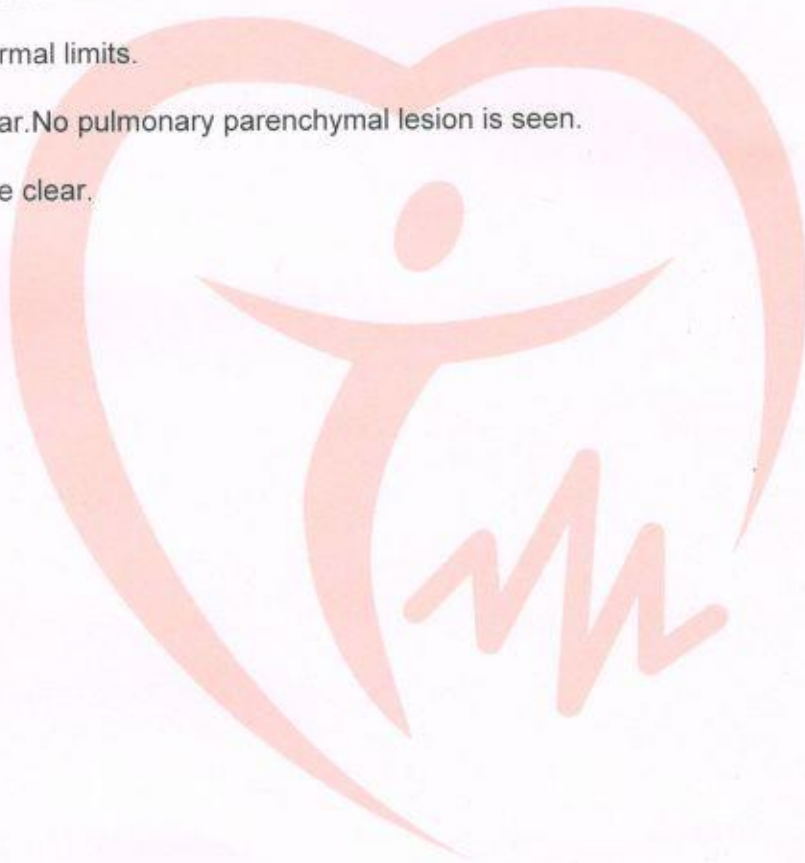
Bony rib cage and soft tissue wall of the thorax are normal.

Cardiac size is within normal limits.

Both lungs fields are clear.No pulmonary parenchymal lesion is seen.

Costo-phrenic angles are clear.

Kindly correlate.



**DR. MUKESH DUBEY**  
(MBBS, DCP)

**DR. VIJAY BHURIYA**  
MBBS DMRD

**DR. AMIT SHANKHWAR**  
M.D. RADIO DIAGNOSIS

**DR. P.S. TRIPATHI**  
M.D.(RADIO DIAGNOSIS)

**DR. SANJAY YADAV**  
CONSULTANT MICROBIOLOGIST



# Triveni Diagnostic Centre

Reg. No. : 98584

Visit ID : 0000103212

Patient Name : Mr. SHIVAM SHUKLA

Age / Sex : 35 YEARS / MALE

Order Date : 09/11/24 12:18PM

Ref. By : Dr. ARCOFEMI HEALTHCARE LIMITED

Report Date : 09/11/24 02:34PM

## CARDIOLOGY

### 2D ECHO


**INTERPRETATION:- Normal 2-D Echo / Dopplar.**

**No LV RWMA seen.**

**LVEF IS 66 %.**

2 IMAGING M Mode examination revealed normal movement of both mitral leaflets during diastole. No SAM or mitral valve prolapsed is seen. Aortic cups are normal and enclosure line is central. Tricuspid valve is normal. Pulmonary valve is normal. Aortic root is normal in size. Dimension of left atrium and left ventricles are normal.

3. Dimaging in PLAX.SAX and apical views revealed a normal left ventricle. Movement of septum anterior, posterior, inferior and lateral walls is normal. Global LVEF 66%. mitral valve opening is normal. No evidence of mitral valve prolapsed is seen. Aortic valve has three cups and its opening is not restricted. Right atrium & right ventricle are normal sized. Tricuspid valve leaflets move normally. Pulmonary valve is normal. Interatrial and intraventricular septa are intact. No intracardiac mass or thrombus is seen. No pericardial pathology is observed.

  
**Dr. RAHUL TALATI MD**

**DR. MUKESH DUBEY**  
(MBBS, DCP)

**DR. VIJAY BHURIYA**  
MBBS DMRD

**DR. AMIT SHANKHWAR**  
M.D. RADIO DIAGNOSIS

**DR. P.S. TRIPATHI**  
M.D. (RADIO DIAGNOSIS)

**DR. SANJAY YADAV**  
CONSULTANT MICROBIOLOGIST



**Mr. Shivam Shukla 09/11/2024**

**Valve**

Aortic root diameter	3.0cms	2.0-3.7cm<2.2cm/M2
Aortic valve opening	1.8cms	1.5-2.6cm
Right ventricular dimension	2.1cms	0.7-2.5cm<2.2cm/M2
Left atrium dimension	3.6cms	1.9-4.0cm<2.2cm/M2
Left ventricular ED dimension	4.4cms	3.7-5.6cm<3.2cm/M2
Left ventricular ES dimension	2.9cms	2.2-4.0cm
Intraventricular ED septal thickness	0.9cms	0.6-1.2 cm
Left vent ED PW thickness	0.9cms	0.5- 1.0 cm
IVS/LVPW	<N	<1.3

**INDICES OF LEFT VENTRICLE FUNCTION:**

Mitral E – septal separation	.5	cms <0.9 cm
LV Ejection Fraction	66%	60 %- 80%

**COLOR DOPPER**

	PV(m/sec)	PG(mm of Hg)	Regurgitation
AV	1.5	9.06	NIL
MV	0.8	2.75	NIL
TV	N	N	NIL
PV	1.15	5.25	NIL

# TRIVENI DIAGNOSTI & RESEARCH CENTER

09 Nov 2024  
 Namé : shivam shukla

