

उपचार कक्ष [11A]

Blood Pressure: 110/70	mm of Hg	Weight: 58 kg	cm
Height: 153	cm	Body Mass Index:: 24.1	
PULSE - 96		SPO2 93	%

WHL/NAG/CC/HCU/03

ka

buradkar

05-Nov-24 12:25:06 PM

wockhardt hospitals

85 . Age not entered, assumed to be 50 years old for purpose of ECG interpretation
 . Sinus rhythm.....normal P axis, V-rate 50- 99

135
 91
 344
 409

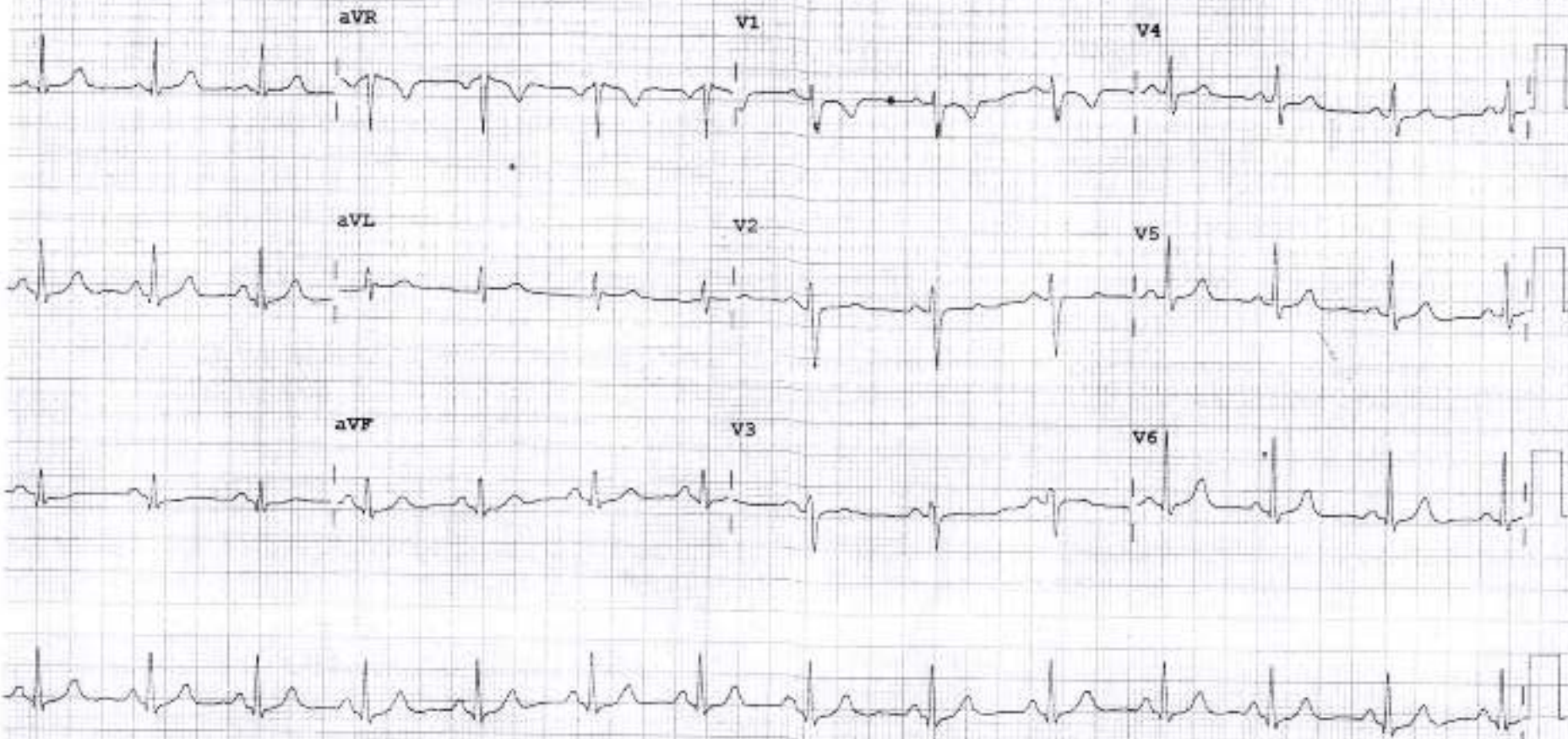
S--

74
 33
 30

- NORMAL ECG -

ad: Standard Placement

Unconfirmed Diagnosis



2D ECHOCARDIOGRAPHY & COLOUR DOPPLER STUDY

Name : Mrs. Renuka Buradkar

Age / Sex : 29 Yrs. / Female

Done By : Dr. Nitin Tiwari

Date : November 05, 2024

OPD

UHID : 365577

Comments :

Sector echo done in plax, psax, apical 4 & 5 chambers. subcostal view shows:

Normal morphology of mitral, aortic, tricuspid and pulmonary valves.

The left atrium, left ventricle, right atrium and right ventricle are normal in dimension and morphology. There is no regional wall motion abnormality of left ventricle at rest. The left ventricular systolic function is **good**. The global left ventricular ejection fraction is 64 %

The IAS and IVS are intact.

The pericardium is normal. There is no pericardial effusion

There is no clot or vegetation seen.

CW, PW and Colour Doppler: Transmitral flow is suggestive of normal left ventricular diastolic function present. The flow pattern across other cardiac valves is normal. There is no evidence of pulmonary hypertension.

Impression:

Normal cardiac valves and chamber dimensions

No regional wall motion abnormality of left ventricle at rest

Good left ventricular systolic function. LVEF – 64 %

Normal LV diastolic function

No pulmonary hypertension

Dr. Nitin Tiwari
MD, DNB (Med.), DM, DNB (Card.),
MNAMS, MAPSIC
Sr. Interventional Cardiologist



DEPARTMENT OF LABORATORY MEDICINE

Patient Name	: MRS. RENUKA PANKAJ BURADKAR	Bill No.	: OCR3/25/0005077
Age/Sex	: 29 Years/Female	Sample Collection	: 05/11/2024 12:39 PM
UHID	: WHN2.0000365577	Receiving Date Time	: 05/11/2024 01:05 PM
Primary Consultant	: DR. WOCKHARDT DOCTOR	Report Date	: 05/11/2024 02:41 PM
Order Date	: 05/11/2024 09:01 AM	Approval Date Time	: 05/11/2024 02:42 PM
Order No.	: 38656	Specimen	: Fluoride Blood
Visit Code	: QP3.0093540	Bed No.	:

BIOCHEMISTRY

Final Report

PARAMETER	METHOD	RESULT	UNIT	B.R.I
Serum Urea	Urease-GLOH	17.8	mg/dL	1-50
Blood Urea Nitrogen	Calculated	8.31	mg/dL	6-20
Creatinine- Serum				
Creatinine	Enzymatic colorimetric	0.73	mg/dL	0.51-0.95
Plasma Glucose				
Plasma Glucose - Fasting	Enzymatic Hexokinase	99.45	mg/dL	74-109
Urine Sugar Fasting	Double Sequential Enzyme Reaction - GOD/ POD	Absent		
Uric Acid- Serum				
Uric Acid	Enzymatic colorimetric	4.4	mg/dL	2.4-5.7
Lipid Profile				
Cholesterol	Colorimetric - Cholesterol Oxidase	147.69	mg/dL	0-200
Triglycerides	Enzymatic colorimetric	80.7	mg/dL	0-150
HDL Cholesterol - Direct	Direct Homogenous Enzymatic Colorimetric	43.6		1. No Risk: >65 2. Moderate Risk: 45-65 3. High Risk: <45
LDL Cholesterol - Direct	Direct Homogenous Enzymatic Colorimetric	87.95	mg/dL	0-100
VLDL Cholesterol	Calculated	16.14	mg/dL	10-35
Chol/HDL Ratio		3.38		1. Low Risk: 3.3-4.4 2. Average Risk: 4.4-7.1 3. Moderate Risk: 7.1-11.0 4. High Risk: >11.0
Liver Function Test (L.F.T.)				
Alkaline Phosphatase	Colorimetric IFCC	105	U/L	35-104
S.G.O.T (AST)	IFCC Without Pyridoxal 5 Phosphate	11.3	U/L	0-32
S.G.P.T (ALT)	IFCC Without Pyridoxal 5 Phosphate	5.8	U/L	0-35
Total Protein (Serum)	Colorimetric - Biuret Method	7.38	g/dL	6.4-8.3
Albumin, BCG	Colorimetric - Bromo-Cresol Green	4.41	g/dL	3.5-5.2
Globulin	Calculated	2.97	g/dL	1.9-3.5
Albumin/Globulin Ratio	Calculated	1.48		0.9-2

DEPARTMENT OF LABORATORY MEDICINE

Patient Name	: MRS. RENUKA PANKAJ BURADKAR	Bill No.	: OCR3/25/0005077
Age/Sex	: 29 Years/Female	Sample Collection	: 05/11/2024 12:39 PM
UHID	: WHN2.0000365577	Receiving Date Time	: 05/11/2024 01:05 PM
Primary Consultant	: DR. WOCKHARDT DOCTOR	Report Date	: 05/11/2024 02:41 PM
Order Date	: 05/11/2024 09:01 AM	Approval Date Time	: 05/11/2024 02:42 PM
Order No.	: 38556	Specimen	: Fluoride Blood
Visit Code	: OP3.0093540	Bed No.	:


BIOCHEMISTRY

Final Report

PARAMETER	METHOD	RESULT	UNIT	B.R.I
Liver Function Test (L.F.T.)				
Serum Total Bilirubin	Colorimetric Diazo	0.26	mg/dL	0-1.2
Serum Direct Bilirubin	Colorimetric Diazo	0.12	mg/dL	0-0.4
Serum Indirect Bilirubin	Calculated	0.14	mg/dL	0-1

--- END OF REPORT ---

SOHEL KHAN
Verified By


Dr. LAXMI LOKESH
 Consultant Pathologist
 MDPATH

Partial reproduction of Report not permitted This Report Relates to Sample received by Laboratory
* B.R.I - BIOLOGICAL REFERENCE INTERVAL

DEPARTMENT OF LABORATORY MEDICINE

Patient Name	: MRS. RENUKA PANKAJ BURADKAR	Bill No.	: OCR3/25/0005077
Age/Sex	: 29 Years/Female	Sample Collection	: 05/11/2024 12:39 PM
UHID	: WHN2.0000385577	Receiving Date Time	: 05/11/2024 01:05 PM
Primary Consultant	: DR. WOCKHARDT DOCTOR	Report Date	: 05/11/2024 02:41 PM
Order Date	: 05/11/2024 09:01 AM	Approval Date Time	: 05/11/2024 02:42 PM
Order No.	: 38656	Specimen	: Fluoroide Blood
Visit Code	: OP3.0093540	Bed No.	:

HEMATOLOGY

Final Report

PARAMETER	METHOD	RESULT	UNIT	B.R.I
Complete Blood Count (With ESR)- EDTA Blood				
Haemoglobin	SLS Method	12.8	g%	12.0-16.0
Haematocrit	RBC Pulse Height Detection	42.3	%	40 - 50
MCV	Calculated	87.6	fl	83-101
MCH	Calculated	26.5	pg	27-32
MCHC	Calculated	30.3	g/dl	32-35
RBC Count	DC Detection	4.83	Million/ul	3.8-4.8
RDW-CV	Calculated	14.6	%	12-14
WBC Total Count (TLC)	Electrical Impedance	5240	Cells/cumm	4000 - 10000
Neutrophils		53	%	40-80
Lymphocytes		38	%	28-48
Monocytes		08	%	2-10
Eosinophils		01	%	0-6
Basophils		00	%	0-2
Platelet Count	Hydrodynamic Focussing DC	306	Thou/Cumm	150-450
PDW	Calculated	10.4	fL	9.0-17
P-LCR	Calculated	22.7	%	13.0-43.0
MPV	Calculated	9.8	fl	9.4-12.3
PCT	Calculated	0.30	%	0.17-0.35
Blood ESR	Westergren Method	21	mm/hr	0-20

--- END OF REPORT ---

SOHEL KHAN
Verified By


Dr. LAXMI LOKESH
 Consultant Pathologist
 MDPATH

Partial reproduction of report not permitted. This result relates to sample received by laboratory.
 * B.R.I - BIOLOGICAL REFERENCE INTERVAL

DEPARTMENT OF LABORATORY MEDICINE

Patient Name	: MRS. RENUKA PANKAJ BURADKAR	Bill No.	: OCR3/25/0005077
Age/Sex	: 29 Years/Female	Sample Collection	: 05/11/2024 12:39 PM
UHID	: WHN2.0000365577	Receiving Date Time	: 05/11/2024 01:05 PM
Primary Consultant	: DR. WOCKHARDT DOCTOR	Report Date	: 05/11/2024 02:41 PM
Order Date	: 05/11/2024 09:01 AM	Approval Date Time	: 05/11/2024 02:42 PM
Order No.	: 38656	Specimen	: Fluoride Blood
Visit Code	: OP3.0093540	Bed No.	:

BIOCHEMISTRY

Final Report

PARAMETER	METHOD	RESULT	UNIT	B.R.I
-----------	--------	--------	------	-------

Glycosylated Haemoglobin- EDTA Blood

Glycosylated Haemoglobin	HPLC	5.1	%
Estimated Mean glucose	Calculated	104.26	mg/dL

Action required: 7.0-8.0%
 Good control: 6.5-7.0%
 Normal control: 4.8-6.4%
 Poor control: >8.0%

--- END OF REPORT ---

SOHEL KHAN
 Verified By


 Dr. LAXMI LOKESH
 Consultant Pathologist
 MDPATH

Partial reproduction of report not permitted. This Report Relates to Sample received by LabID2017
 * B.R.I.: BIOLOGICAL REFERENCE INTERVAL

DEPARTMENT OF LABORATORY MEDICINE

Patient Name	: MRS. RENUKA PANKAJ BURADKAR	Bill No.	: DCR3/25/0005077
Age/Sex	: 29 Years/Female	Sample Collection	: 05/11/2024 12:39 PM
UHID	: WHN2.0000365577	Receiving Date Time	: 05/11/2024 01:05 PM
Primary Consultant	: DR. WOCKHARDY DOCTOR	Report Date	: 05/11/2024 02:41 PM
Order Date	: 05/11/2024 09:01 AM	Approval Date Time	: 05/11/2024 02:42 PM
Order No.	: 38656	Specimen	: Fluoride Blood
Visit Code	: OP3.0093540	Bed No.	: 1

BIOCHEMISTRY

Final Report

<u>PARAMETER</u>	<u>METHOD</u>	<u>RESULT</u>	<u>UNIT</u>	<u>B.R.I</u>
Plasma Glucose Post Prandial				
Plasma Glucose Post Prandial	Enzymatic Hexokinase	98.54	mg/dl	70-140
Urine Sugar Post Prandial	Double Sequential Enzyme Reaction - GOD/ POD	NA		

--- END OF REPORT ---

SONAL SINGH
Verified By


Dr. LAXMI LOKESH
 Consultant Pathologist
 MDPATH

Partial Reproduction of Report not permitted This Report Relates to Sample received by Laboratory
* B. I. - BIOLOGICAL REFERENCE INTERVAL

DEPARTMENT OF LABORATORY MEDICINE

Patient Name	: MRS. RENUKA PANKAJ BURADKAR	Bill No.	: OCR3/25/0005077
Age/Sex	: 29 Years/Female	Sample Collection	: 05/11/2024 12:39 PM
UHID	: WHN2.0000365577	Receiving Date Time	: 05/11/2024 01:05 PM
Primary Consultant	: DR. WÖCKHARDT DOCTOR	Report Date	: 05/11/2024 02:41 PM
Order Date	: 05/11/2024 09:01 AM	Approval Date Time	: 05/11/2024 02:42 PM
Order No.	: 38656	Specimen	: Fluoride Blood
Visit Code	: OP3-0093540	Bed No.	:


IMMUNOLOGY

Final Report

PARAMETER	METHOD	RESULT	UNIT	B.R.I
T3 T4 TSH- Serum				
TOTAL T3	ECLIA	121.9	ng/dl	80-200
TOTAL T4	ECLIA	8.44	ug/dl	4.5-11.7
TSH	ECLIA	1.78	µIU/mL	0.27-4.2

--- END OF REPORT ---

SOHEL KHAN
Verified By


Dr. LAXMI LOKESH
 Consultant Pathologist
 MOPATH

Partial Reproduction of Report not permitted This Report Relates to Sample received by Laboratory
* B.R.I - BIOLOGICAL REFERENCE INTERVAL

DEPARTMENT OF LABORATORY MEDICINE

Patient Name	: MRS. RENUKA PANKAJ BURADKAR	Bill No.	: OCR3/25/0005077
Age/Sex	: 29 Years/Female	Sample Collection	: 05/11/2024 12:39 PM
UHID	: WHN2.0000365577	Receiving Date Time	: 05/11/2024 01:05 PM
Primary Consultant	: DR. WOCKHARDT DOCTOR	Report Date	: 05/11/2024 02:41 PM
Order Date	: 05/11/2024 09:01 AM	Approval Date Time	: 05/11/2024 02:42 PM
Order No.	: 3865G	Specimen	: Fluoride Blood
Visit Code	: OP3.0093540	Bed No.	:


CLINICAL PATHOLOGY

Final Report

PARAMETER	METHOD	RESULT	UNIT	B.R.I
Urine Routine				
Physical Examination				
Colour		Pale Yellow		
Appearance		Clear		
Urinalyser (Roche UriSys 1100)				
Specific Gravity		1.015		1.003 - 1.035
Reaction [pH]		6		
Leukocytes, microscopy		neg	/hpf	
Erythrocytes, microscopy		neg	/hpf	
Nitrite, urinalyser		neg		
Protein, urinalyser		neg		
Glucose, urinalyzer		neg		
Ketone, urinalyser		neg		
Urobilinogen urinalyser		neg		
Billirubin ulrnalyser		neg		

--- END OF REPORT ---

SOHEL KHAN
Verified By


 Dr. LAXMI LOKESH
 Consultant Pathologist
 MOPATH

Partial reproduction of Report not permitted. This Report Relates to Sample received by Laboratory
* B.R.I : BIOLOGICAL REFERENCE INTERVAL

DEPARTMENT OF RADIO DIAGNOSTICS

Patient Name : MRS. RENUKA PANKAJ BURADKAR
Age/Sex : 29 Yrs / Female
UHID : WHN2.0000365577
Reporting Date : 05/11/2024 12:02 PM
Bill No. : OCR3/25/0005077
Order Date : 05/11/2024 09:01 AM
Referred by :
Order No. : 15246

USG ABDOMEN WITH PELVIS :

Real time sonography of the abdomen and pelvis was performed using the 3.5 MHz transducer.

The liver is normal in size and echotexture. No focal parenchymal lesion noted.

Intrahepatic biliary tree and venous radicles are normal.

The portal vein and CBD appear normal in course and calibre.

The gall bladder is normal in size with a normal wall thickness and there are no calculi noted within.

The pancreas is normal in size and echotexture. No evidence of focal lesion or calcification or duct dilatation seen.

The spleen is normal in size and echotexture.

Both kidneys are normal in size, position and echogenicity.

Cortical thickness and corticomedullary differentiation are normal.

No hydronephrosis or calculi noted.

The bladder is normal in contour, capacity and wall thickness.

No vesical calculi noted.

The uterus is normal in size and anteverted in position.

Myometrial echotexture is homogenous. No focal lesions seen.

Endometrial echocomplex is central in position and 5 mm in thickness.

Bilateral ovaries are enlarged in size and show multiple small cysts arranged around periphery with central echogenic stroma.

Right ovary measures 10.7 cc.

Left ovary measures 13.5 cc.

There is no evidence of free fluid in pouch of Douglas.

There is no evidence of ascites.

Impression :

Bilateral polycystic ovarian disease.

DR. VISHAL GAJBHIYE

M.B.B.S., M.D.

CONSULTANT - RADIOLOGIST

DEPARTMENT OF RADIO DIAGNOSTICS

Patient Name : MRS. RENUKA PANKAJ BURADKAR
Age/Sex : 29 Yrs / Female Order Date : 05/11/2024 09:01 AM
UHID : WHN2.0000365577 Referred by :
Reporting Date : 05/11/2024 12:24 PM Order No. : 15246
Bill No. : OCR3/25/0005077

CHEST X-RAY PA VIEW :

Both lung fields are clear.

The costophrenic angles and domes of diaphragm appear normal.

No hilar or mediastinal lesion seen.

Cardiac silhouette is within normal limits.

Visualised bony thorax and soft tissues appear normal.

Impression:
Normal Chest X-Ray.

DR. VISHAL GAJBHIYE
M.B.B.S., M.D.
CONSULTANT - RADIOLOGIST