


<b>Name</b> : Mr. Darshan V Gudigar  <b>Address</b> : Bangalore  <b>Plan</b> : ARCOFEMI MEDIWHEEL MALE AHC CREDIT PAN INDIA OP AGREEMENT	<b>Age</b> : 32 Y  <b>Sex</b> : M	<b>UHID</b> :CINR.0000161854  <b>OP Number</b> :CINROPV217019 <b>Bill No</b> :CINR-OCR-93198 <b>Date</b> : 25.01.2024 09:01
--	---	---

Sno	Service Type/ServiceName	Department
1	ARCOFEMI - MEDIWHEEL - FULL BODY ANNUAL PLUS MALE - 2D ECHO - PAN INDIA - FY2324	
1	GAMMA-GLUTAMYL TRANSFERASE (GGT)	
2	2 D ECHO — 9.30 am	
3	LIVER FUNCTION TEST (LFT)	
4	GLUCOSE, FASTING	
5	HEMOGRAM + PERIPHERAL SMEAR	
6	DIET CONSULTATION	
7	COMPLETE URINE EXAMINATION	
8	URINE GLUCOSE(POST PRANDIAL)	
9	PERIPHERAL SMEAR	
10	ECG — 6	
11	RENAL PROFILE/RENAL FUNCTION TEST (RFT/KFT)	
12	DENTAL CONSULTATION — 1	
13	GLUCOSE, POST PRANDIAL (PP), 2 HOURS (POST MEAL)	
14	URINE GLUCOSE(FASTING)	
15	HbA1c, GLYCATED HEMOGLOBIN	
16	X-RAY CHEST PA — 10	
17	ENT CONSULTATION — 7	
18	FITNESS BY GENERAL PHYSICIAN	
19	BLOOD GROUP ABO AND RH FACTOR	
20	LIPID PROFILE	
21	BODY MASS INDEX (BMI) — 6	
22	OPHTHAL BY GENERAL PHYSICIAN — 5	
23	ULTRASOUND - WHOLE ABDOMEN — 9 after 19.M	
24	THYROID PROFILE (TOTAL T3, TOTAL T4, TSH)	

25.01.2024

Mr. Darshan Gudigar

32 yrs / M

Height :	Weight :	BMI :	Waist Circum :
Temp :	Pulse :	Resp :	B.P :

General Examination / Allergies  
History

Clinical Diagnosis & Management Plan

Arcofeni - A.Hc.

Ears: Ms

Nose: Ms

Throat: Ms

Follow up date:

  
Dr. RAVINDRANATH KUDVA  
M. D. O. P. Signature  
E.N.T. SURGEON

KMC REG. No : 18554

**Apollo Clinic, Indiranagar**

#2012, 1st Floor, 100 Feet Road, HAL 2nd Stage, Indiranagar - 560038

Phone: (080) 2521 4614/15

Follow us  /ApolloClinicIndia  /ApolloClinics

BOOK YOUR APPOINTMENT TODAY!

Whatsapp Number : 970 100 3333

Toll Number : 1860 500 7788

Website : [www.apolloclinic.com](http://www.apolloclinic.com)

Date : 25-01-2024

Department : GENERAL

MR NO : CINR.0000161854

Doctor :

Name : Mr. Darshan V Gudigar

Registration No :

Age/ Gender : 32 Y / Male

Qualification :

Consultation Timing: 09:00

Height: 175-c	Weight: 74.7kg	BMI: 24.39kg/m <sup>2</sup>	Waist Circum: 85-c
Temp: 98.6 of	Pulse: 69 bpm	Resp: 18 bpm	B.P: 118 / 70 mmHg

General Examination / Allergies  
History

Clinical Diagnosis & Management Plan

Follow up date:

Doctor Signature

**OPHTHAL PRESCRIPTION**

PATIENT NAME: *Mr. Dhanu V Gudde* DATE: *25/1/24*

UHID NO: *61854*

AGE: *32*

OPTOMETRIST NAME: Ms. Swathi

GENDER: *M*

This is to certify that I have examined  
years and findings of his/her eye examination are as follows,

	RIGHT EYE				LEFT EYE			
	SPH	CYL	AXIS	BCVA	SPH	CYL	AXIS	BCVA
Distance		<i>Plano</i>				<i>Plano</i>		
Add								

PD - RE: *31* - LE: *31* -

Colour Vision: *normal (3.6)*


Remarks: *best at this dist*

11.03.1991  
32 Years

Male

25.01.2024 11:28:48  
APOLLO CLINIC  
INDIRANAGAR  
BANGALORE

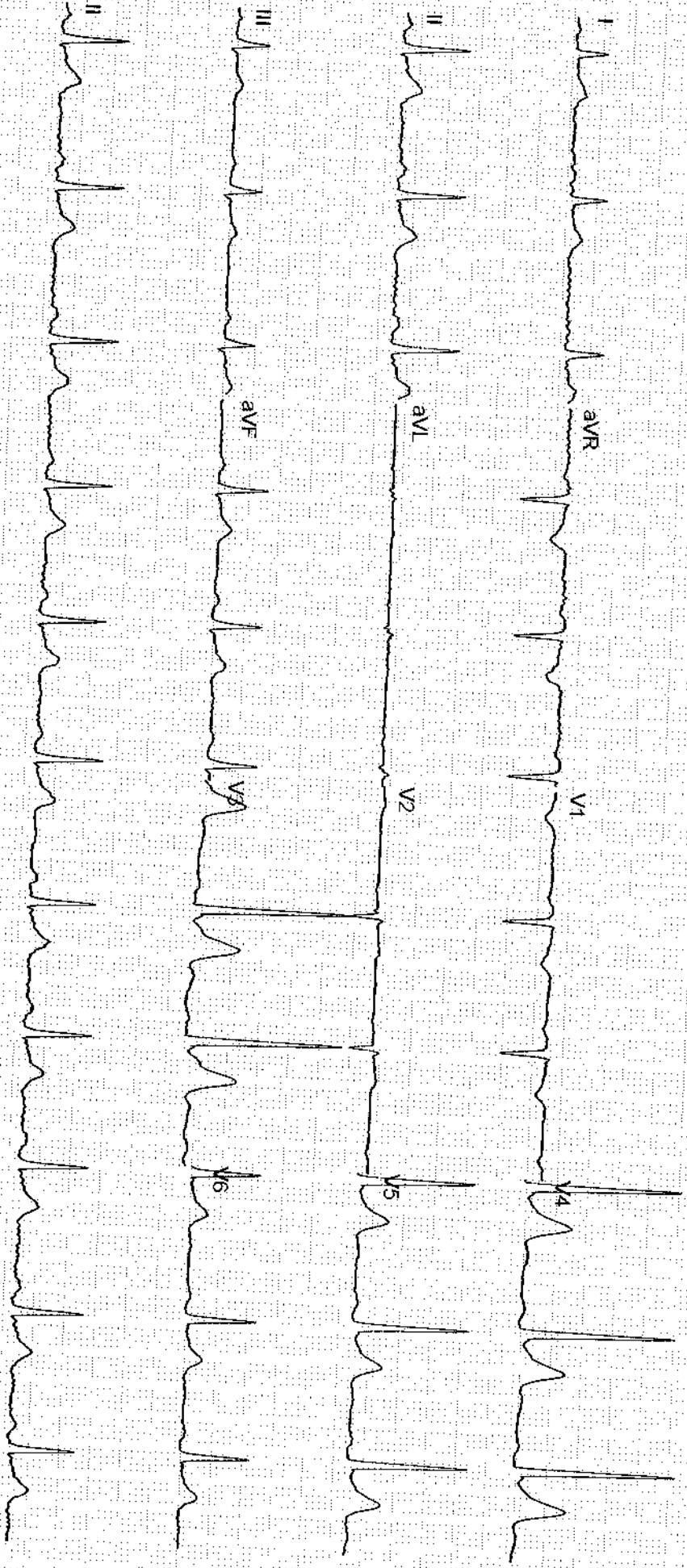
QRS	90 ms
QT/QTcBaz	388 / 403 ms
PR	184 ms
P	108 ms
RR/PP	916 / 923 ms
P/QRS/T	67 / 56 / 45 degrees



Location: Room:  
Order Number:  
Indication:  
Medication 1:  
Medication 2:  
Medication 3:

Technician:  
Ordering Ph:  
Referring Ph:  
Attending Ph:

*Handwritten signature*



65 bpm  
-7 mmHg

GE MAC2000 1.1 12SL™ V241 25 mm/s 10 mm/mV ADS 0.56-20 Hz 50 Hz 4x2 5x3 25\_R1 Unconfirmed 1/1

NAME: MR DHARSHAN      AGE/SEX: 32/M      OP NUMBER: 161854  
 Ref By : SLEF      DATE: 25-01-2024

**M mode and doppler measurements:**

CM	CM	M/sec	
AO: 2.6	IVS(D): 1.0	MV: E Vel: 0.5	A Vel : 0.3
LA: 3.3	LVIDD(D): 4.2	AV Peak: 1.6	
	LVPW(D):1.1	PV peak: 0.7	
	IVS(S): 1.4		
	LVID(S):2.4		
	LVPW(S):1.4		
	LVEF: 60%		
	TAPSE:2.0		

**Descriptive findings:**

Left Ventricle	NORMAL
Right Ventricle:	Normal
Left Atrium:	Normal
Right Atrium:	Normal
Mitral Valve:	Normal
Aortic Valve:	Bicuspid with Raphe
Tricuspid Valve:	Normal
IAS:	Normal
IVS:	Normal

Pericardium:	Normal
IVC:	Normal
Others	---

**IMPRESSION :**

**Congenital Heart Disease**

**Bicuspid AV with Grade I AR (Two Jets)**

**MILD TR**


**No Regional wall motion abnormality**

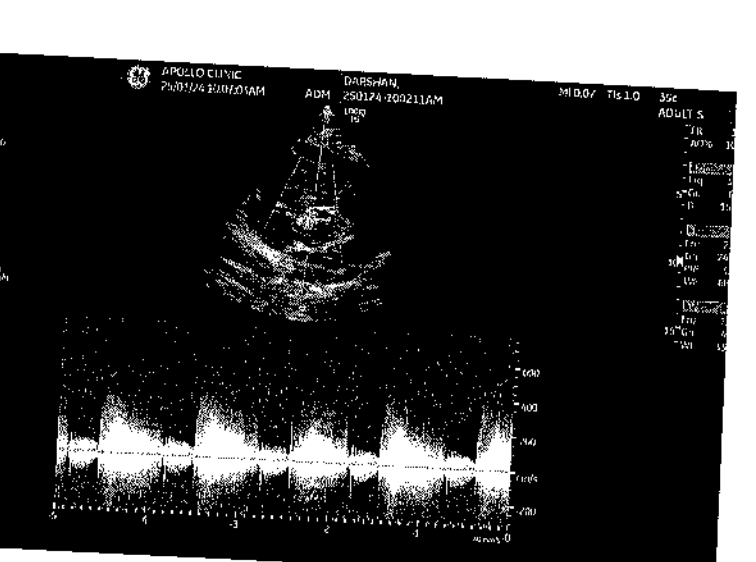
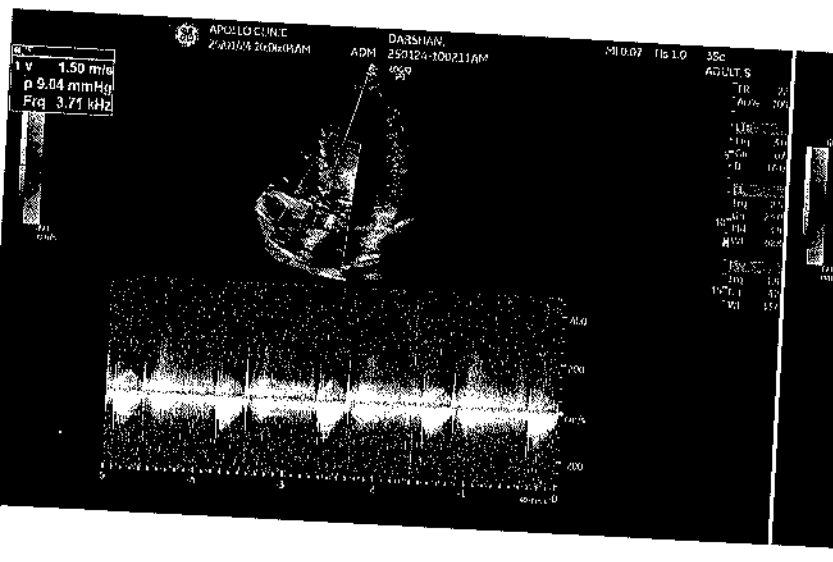
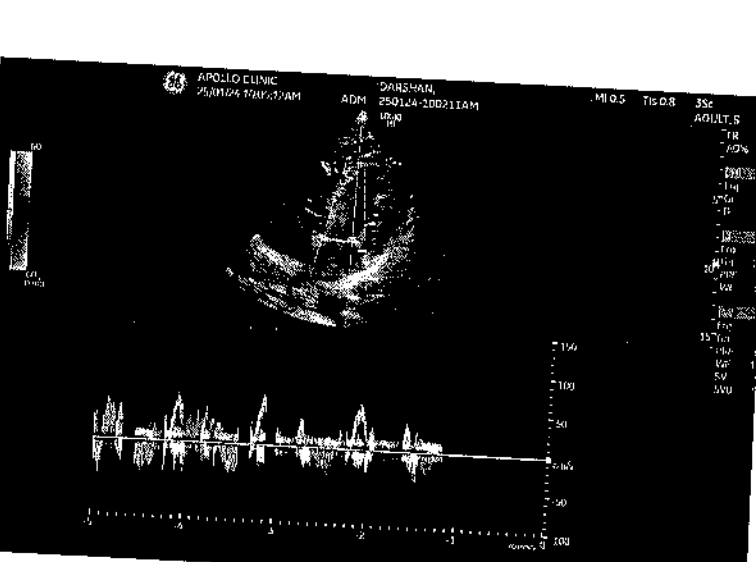
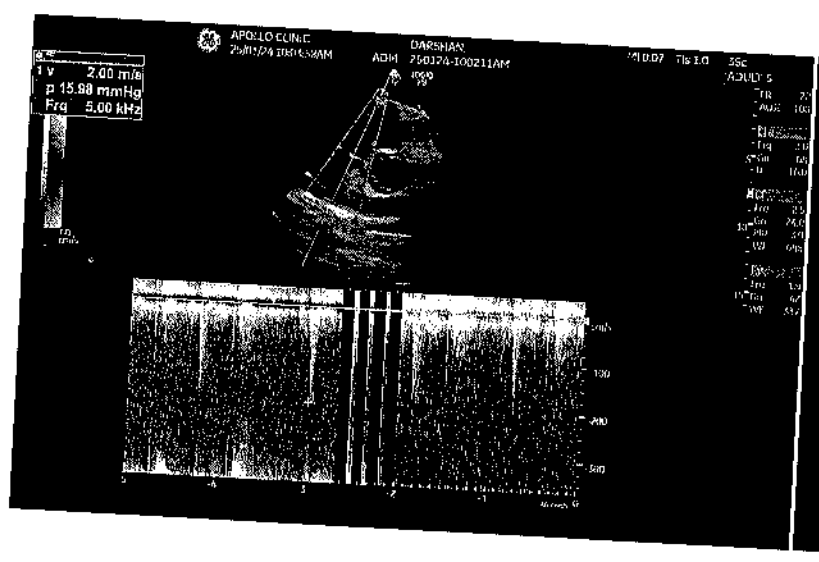
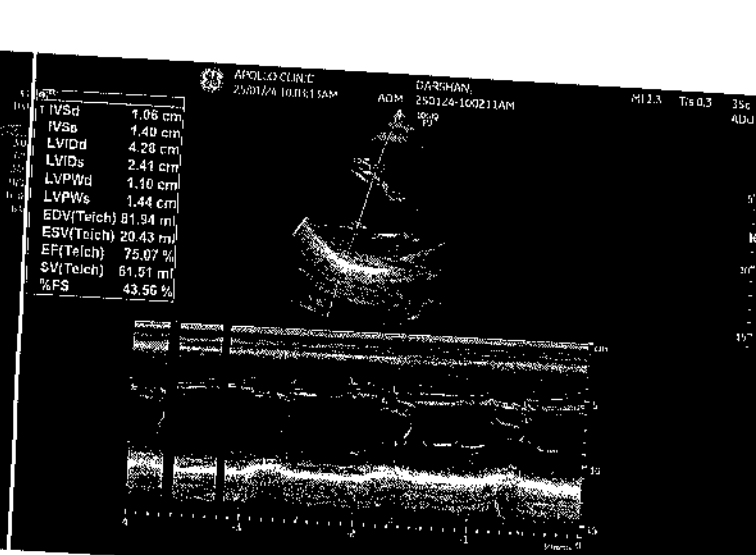
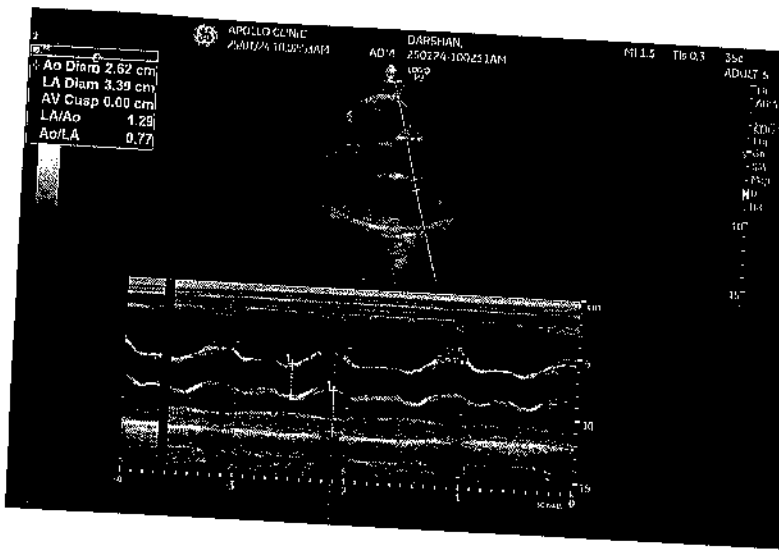
**No clot/vegetation/pericardial effusion**

**Normal LV systolic function - LVEF= 60%**

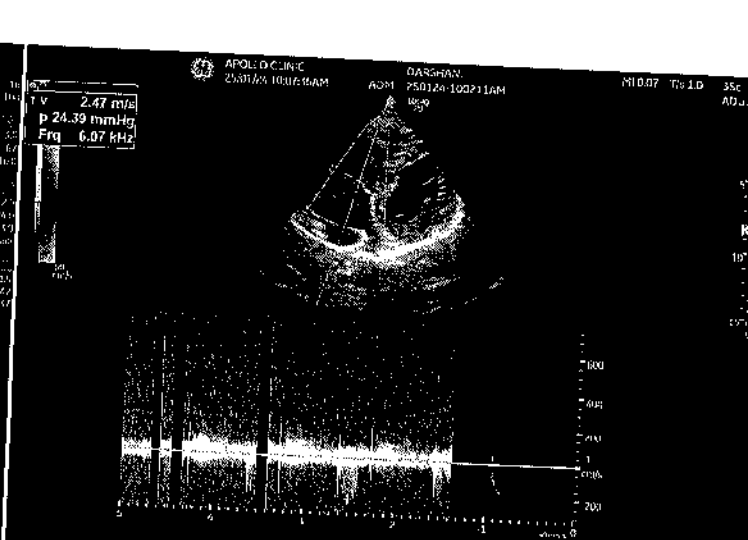
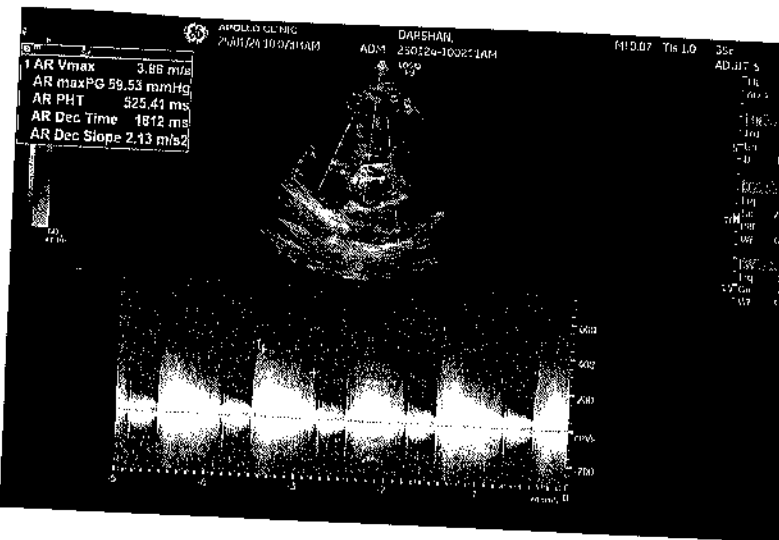
**DR JAGADEESH H V MD,DM**

**CONSULTANT CARDIOLOGIST**

  
**Dr. JAGADEESH H V**  
MBBS, MD, DM (Cardio)  
Consultant Cardiologist  
KMC Reg No. 86848  
Apollo Clinic







**From:** Customer Care :Mediwheel : New Delhi <customercare@mediwheel.in>

**Sent:** 24 January 2024 11:20

**To:** Corporate Apollo Clinic <corporate@apolloclinic.com>

**Cc:** Wellness : Mediwheel : New Delhi <wellness@mediwheel.in>; Network : Mediwheel : New Delhi <network@mediwheel.in>; deepak <deepak.c@apolloclinic.com>

**Subject:** Health Check-up Bookings No. 24 (Annual)

Dear Team,

Please find the attached Health Check-up Bookings file and confirm the same.

bobS6246	namrita	25 year	Female	DARSH.GUDIGAR@
bobE6245	MR. GUDIGAR DARSHAN	32 year	Male	DARSH.GUDIGAR@

Thanks & Regards

Arcofemi Health Care Ltd. | F-701 A, Lado Sarai, Mehrauli | New Delhi – 110 030  
Ph No. 011-41195959

8738 7369 7093  
Government of India

ಕರ್ನಾಟಕ ರೂರಲ್  
ಡಾರ್ಟನ್ ವೆಂಕಟೇಶ್ ಗುಡ್ಗರ್  
ಬಿ. ಡಿ.ಎಸ್/DOB: 11/03/1991  
SSB/ MALE

8738 7369 7093  
NO: 8113 4617 3560 3279  
ನನ್ನ ಆಧಾರ್, ನನ್ನ ಗುರುತು

**Patient Name** : Mr. Darshan V Gudigar

**Age/Gender** : 32 Y/M

**UHID/MR No.** : CINR.0000161854

**OP Visit No** : CINROPV217019

**Sample Collected on** :

**Reported on** : 25-01-2024 14:55

**LRN#** : RAD2216209

**Specimen** :

**Ref Doctor** : SELF

**Emp/Auth/TPA ID** : 8277676522

---

**DEPARTMENT OF RADIOLOGY**

---

**X-RAY CHEST PA**

Both lung fields and hila are normal .

No obvious active pleuro-parenchymal lesion seen .

Both costophrenic and cardiophrenic angles are clear .

Both diaphragms are normal in position and contour .

Thoracic wall and soft tissues appear normal.

**CONCLUSION :**

No obvious abnormality seen



**Dr. DHANALAKSHMI B**  
**MBBS, DMRD**  
Radiology

**Patient Name** : Mr. Darshan V Gudigar

**Age/Gender** : 32 Y/M

**UHID/MR No.** : CINR.0000161854

**OP Visit No** : CINROPV217019

**Sample Collected on** :

**Reported on** : 25-01-2024 14:07

**LRN#** : RAD2216209

**Specimen** :

**Ref Doctor** : SELF

**Emp/Auth/TPA ID** : 8277676522

## DEPARTMENT OF RADIOLOGY

### ULTRASOUND - WHOLE ABDOMEN

**LIVER:** Appears normal in size, shape and echopattern. No focal parenchymal lesions identified. No evidence of intra/extrahepatic biliary tree dilatation noted. Portal vein appears to be of normal size.

**GALLBLADDER:** Moderately distended. No definite calculi identified. No evidence of abnormal wall thickening noted.

**SPLEEN:** Appears normal in size, shape and echopattern. No focal parenchymal lesions identified.

**PANCREAS:** Obscured by bowel gas. However, the visualized portion appear normal.

**KIDNEYS:** Both kidneys appear normal in size, shape and echopattern. Corticomedullary differentiation appears maintained. No evidence of calculi or hydronephrosis on either side.

**URINARY BLADDER:** Distended and appears normal. No evidence of abnormal wall thickening noted.

**PROSTATE:** Prostate is normal in size and echo-pattern.

No free fluid or lymphadenopathy is seen.

#### IMPRESSION:

**NO SIGNIFICANT SONOGRAPHIC ABNORMALITY DETECTED.**



**Dr. DHANALAKSHMI B**  
MBBS, DMRD  
Radiology