

Branch :

Ground Floor, 12-C, Moti Mahal, C.S. No. 1631, Churchgate, Mumbai-400 020.
Tel. : +91 22 3574 1977 / 93241 87465 / 77100 84304

Patient Name : MRS.MOUNIKA SOGALA
Age : 26 YEARS
REF DR. : MEDIWHEEL

ID No : 44040
Sex : FEMALE
Date : 17.04.2024

2D ECHOCARDIOGRAPHY & COLOR DOPPLER REPORT

DIMENSIONS (M MODE)

LA	28.5	mm
AO	22	mm
LVID (d)	43.8	mm
LVID (s)	30.1	mm
IVS(d)	7.6	mm
LVPW (d)	8.9	mm

2 D ECHOCARDIOGRAPHY & DOPPLER FINDINGS:

ALL CARDIAC CHAMBERS ARE NORMAL IN DIMENSIONS

NO RWMA

LVEF = 60 %

NORMAL LV AND RV SYSTOLIC FUNCTION

NORMAL LV DIASTOLIC FUNCTION

ALL CARDIAC VALVES ARE NORMAL IN MORPHOLOGY.

NO AS/AR/MS/MR.

TRIVIAL TR

IVC NORMAL IN SIZE AND COLLAPSING WITH RESPIRATION

IAS/IVS INTACT

NO PULMONARY HYPERTENSION

LEFT AORTIC ARCH NO COA

Branch :

Ground Floor, 12-C, Moti Mahal, C.S. No. 1631, Churchgate, Mumbai-400 020.
Tel. : +91 22 3574 1977 / 93241 87465 / 77100 84304

Patient Name : MRS.MOUNIKA SOGALA
Age : 26 YEARS
REF DR. : MEDIWHEEL

ID No : 44040
Sex : FEMALE
Date : 17.04.2024

NO CLOTS/ VEGETATIONS/EFFUSION.

CONCLUSIONS:

NORMAL CHAMBER SIZE

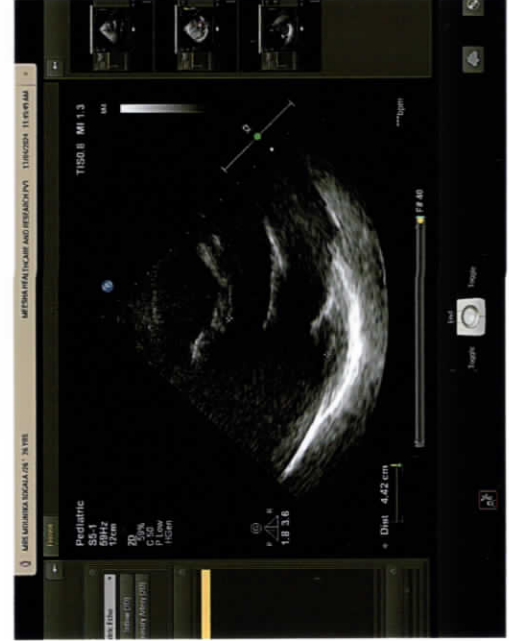
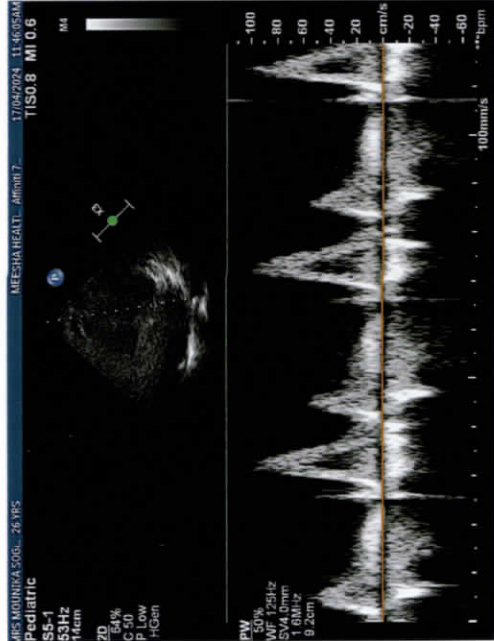
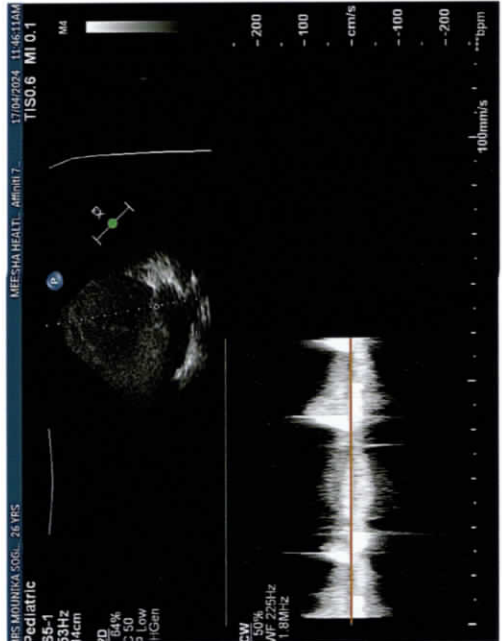
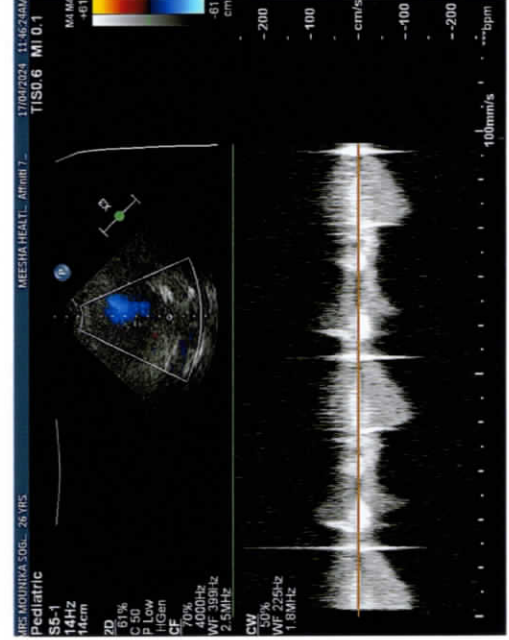
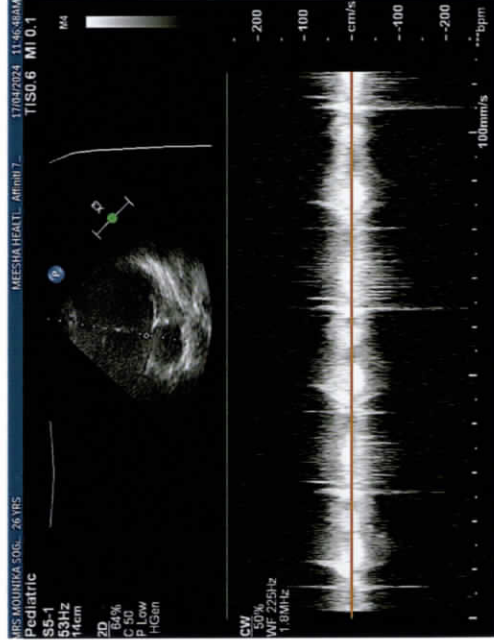
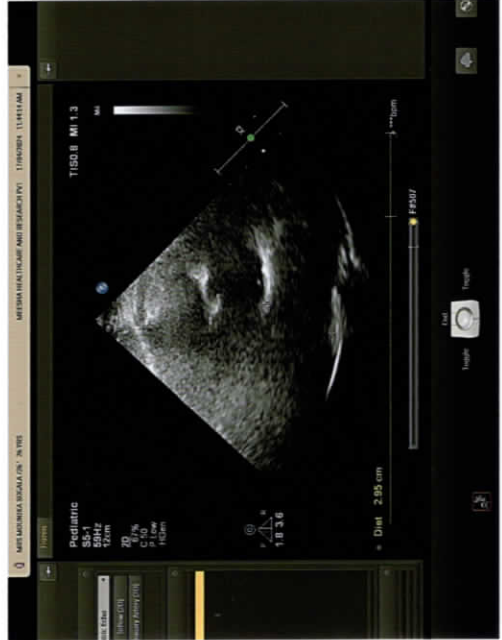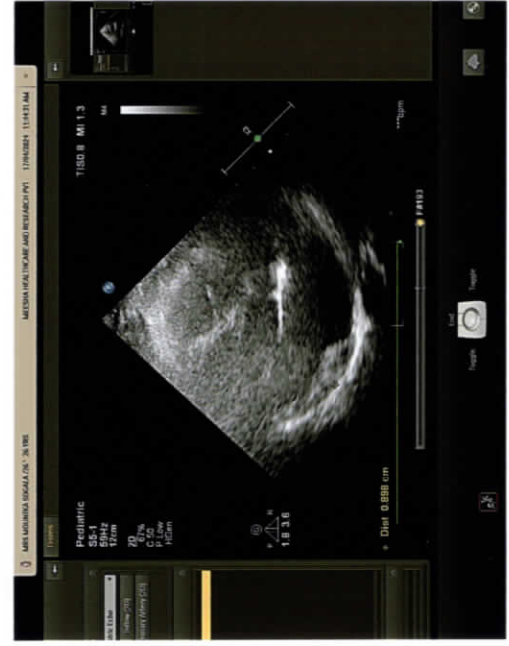
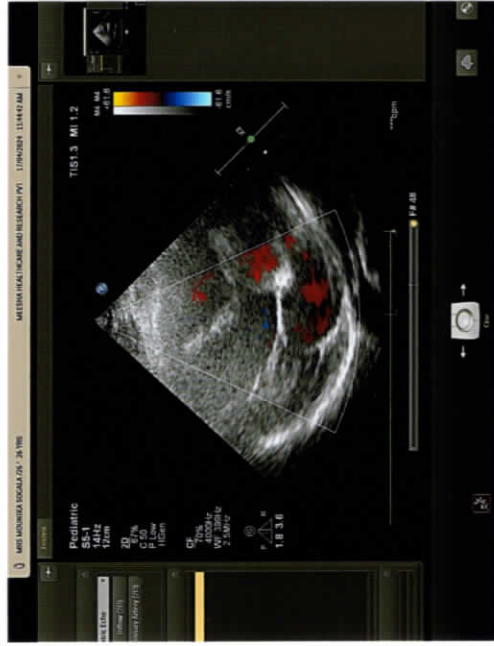
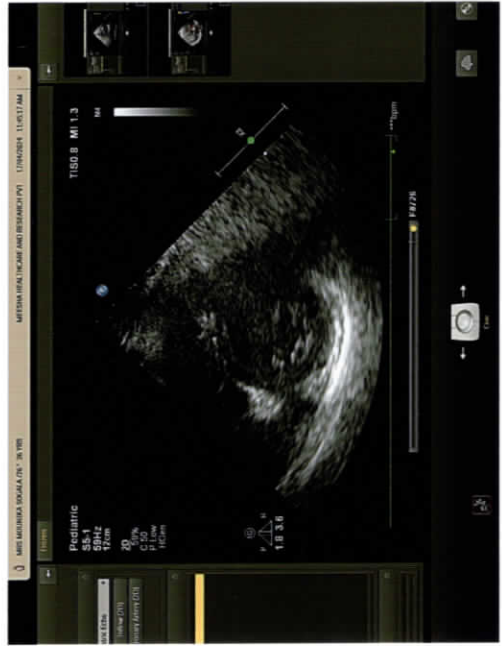
NO RWMA

NORMAL LV SYSTOLIC FUNCTION (LVEF = 60 %)

NORMAL LV DIASTOLIC FUNCTION

NO PULMONARY HYPERTENSION

Dr. YOGESH SHILIMKAR
MBBS, MD (MEDICINE)
Dr. YOGESH SHILIMKAR
MBBS, MD (MED), DM (CARDIOLOGY)
Consultant Interventional Cardiologist





MEESHA HEALTHCARE & RESEARCH PVT LTD

La View,1st Floor,B.J. Marg,Jacob Circle,Saat Rasta,Mahalaxmi Mumbai

Pin - 400011

Phone No. 022-23053534/36/7710084305

www.meeshahealth.net Email: info@meeshahealth.net

Name	MOUNIKA SOGALA				
Age/Sex	026Y/F	Patient ID	44040	Referred By	MEDIWHEEL
Study Date	2024-04-17 11:26		Report Date	2024-04-17 12:16	

RADIOGRAPH OF THE CHEST PA VIEW

FINDINGS:

Both the lung fields are clear.

Both the costophrenic angles are clear.

Hilar shadows appear normal.

Cardiothoracic ratio is within normal limits.

Hemidiaphragms are normal in position and contour.

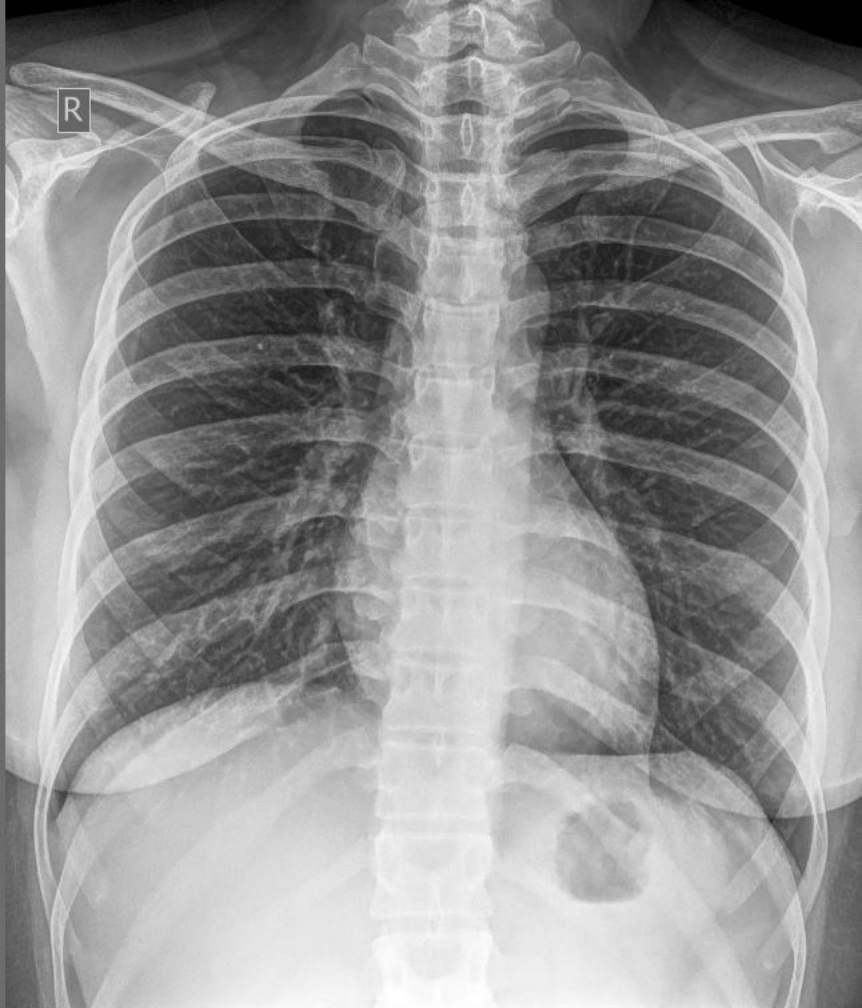Trachea is in the midline.

Bony thorax under view is unremarkable.

IMPRESSION:

Radiograph chest does not reveal any significant abnormality.

Dr Anil Kumar Shukla
MBBS, MD (Radiology)



MONIKA SOGALA Female

CHEST PA

17-Apr-24 11:26:19 AM

44040

26 year(s)

7386804799

MEDMHEEL

MEESHA HEALTHCARE & RESEARCH PVT LTD

YOUR PARTNER IN HEALTH



MEESHA
DIAGNOSTICS AND POLYCLINIC

1st Floor, La View, B. J. Marg, Jacob Circle,
Mahalaxmi, Mumbai-400 011.
Tel. : +91 22 2305 3536 / 6538 3536
info@meeshahealth.com | www.meeshahealth.com

Timings : Monday to Saturday : 8.00 am to 9.00 pm

DENTAL PROFILE

Dear Sir / Madam,

We have examined your teeth and oral cavity and we recommend the following

NAME Mourike Sogala Age : 27/R

1. Extraction of _____ teeth
2. Restorative treatment of _____ teeth
 - a) Crown _____
 - b) fillings
 - i) Silver _____
 - ii) Composite _____
 - iii) Inlays _____
 - c) Root canal fillings _____
3. Scaling and Gum Treatment _____
4. Replacement of _____ teeth
 - a) Removable _____
 - b) Fixed _____
 - c) Implant _____
5. Orthodontics _____
6. X-rays a) Dental _____ b) Orthopantomogram _____
7. Any Others _____
8. Remarks

Carries in $\frac{87A}{878}$ Adv Restoration
 $\frac{878}{878}$, $\frac{87}{878}$ extraction



Consultant Dental Surgeon

Patient: 5

HR 76/min

Axis: 43°

SINUS RHYTHM
NORMAL ECG

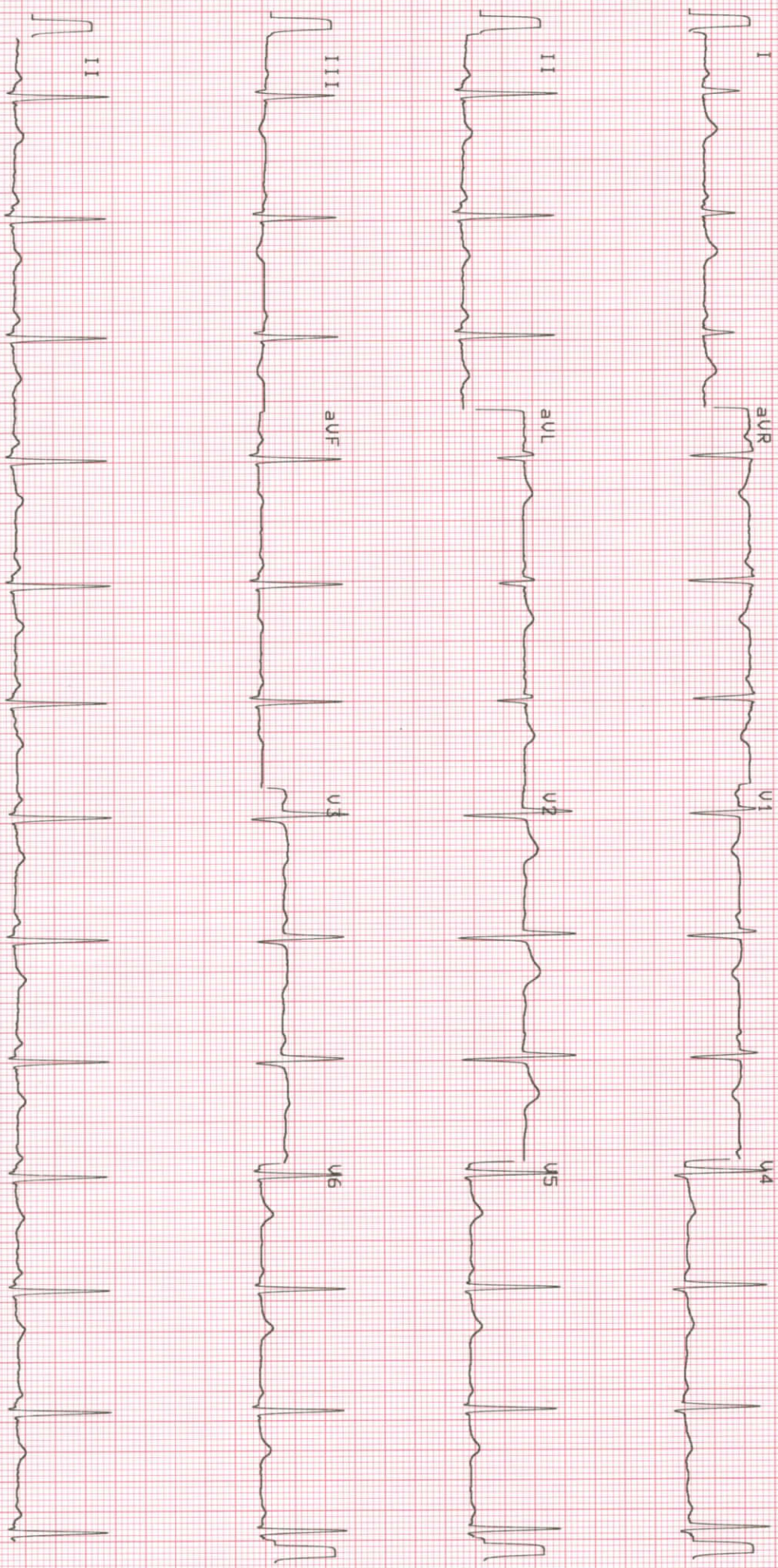
WNL

MOUNIKR SOGALA
44040
26 year / F
166 cm / 74 kg
120/80 mmHg
MEDIWHEEL

Intervals:	RR	793 ms	P	100 ms	P (II)	0.13 mV
	PR	138 ms	QR5	84 ms	S (V1)	-1.01 mV
	QT	390 ms	QTc	438 ms	R (V5)	1.72 mV
					Sokol	3.14 mV

10 mm/mV

10 mm/mV



25 mm/s

0.05-25Hz

F50 SSF 5rJ

We 17-APR-24 13:33:50

MEESHA D., DIAGNOSTICS/POLYCLINIC

AT-2plus 4.14 CM

DR (MD) RAJNESH SINGH
 M M C REG. NO 49217
 Meesha Healthcare & Research Pvt. Ltd

SCHILLER

Pac1 No 2 157017M

CE 0123

M 00

**MEESHA HEALTHCARE & RESEARCH PVT LTD**

La View,1st Floor,B.J. Marg,Jacob Circle,Saat Rasta,Mahalaxmi Mumbai
Pin - 400011
Phone No. 2223053536/7710084305
www.meeshahealth.net
email: info@meeshahealth.net

LAB REPORT

Printed Date: 2024-04-17 08:28 PM

Patient Id : 44040	Patient Name : Mrs. MOUNIKA SOGALA	TreatmentId : 21082
Age/Gender : 26Y/Female	Mobile No : 7386804799	Ref. By :
Registered On : 17-04-2024 10:30 AM	Collected On : 17-04-2024 10:35 AM	Reported On : 17-04-2024 08:13 PM
Nationality : Indian	Patient Type : Sponsor	Sponsor Name : MediWheel(Arcofemi Healthcare Pvt. Ltd.)

LFT - LIVER FUNCTION TEST

<u>Test Name</u>	<u>Test Result</u>	<u>Normal Values</u>	<u>Unit</u>
Serum Bilirubin Total	0.44	0.1 - 1.2	mg/dl
Serum Bilirubin Direct	0.20	0 - 0.5	mg/dl
Serum Bilirubin Indirect	0.24	0 - 0.9	mg/dl
Serum SGOT (AST)	09	0 - 40	IU/L
Serum SGPT (ALT)	13	0 - 40	IU/L
Serum Alkaline Phosphatase	165 H	40 - 111	IU/L
Comment: -Rechecked.			
Serum GGT	18	11 - 50	U/L
Serum Total Proteins	7.0	6.4 - 8.3	g/dl
Serum Albumin	3.3 L	3.5 - 5.2	g/dl
Serum Globulin	3.70 H	1.6 - 3.5	g/dl
A/G Ratio	0.89	0 - 100	micro IU/mL

Equipment: ERBA-EM 200 FULLY AUTOMATED CLINICAL CHEMISTRY ANALYSER.**--End Of Report--****Shradha Mhaskar**
(Technician Name)**Dr Tabassum Shaikh**
MBBS,MD (Pathology)
Consultant Pathologist



MEESHA HEALTHCARE & RESEARCH PVT LTD

La View,1st Floor,B.J. Marg,Jacob Circle,Saat Rasta,Mahalaxmi Mumbai
Pin - 400011
Phone No. 2223053536/7710084305
www.meeshahealth.net
email: info@meeshahealth.net

LAB REPORT

Printed Date: 2024-04-17 08:20 PM

Patient Id : 44040	Patient Name : Mrs. MOUNIKA SOGALA	TreatmentId : 21082
Age/Gender : 26Y/Female	Mobile No : 7386804799	Ref. By :
Registered On : 17-04-2024 10:30 AM	Collected On : 17-04-2024 10:35 AM	Reported On : 17-04-2024 08:19 PM
Nationality : Indian	Patient Type : Sponsor	Sponsor Name : MediWheel(Arcofemi Healthcare Pvt. Ltd.)

Profile Name:- PAP SMEAR

Test Name	Test Result
<u>Clinical Details</u>	: Routine Health Check up
<u>Smears Received</u>	: 2 unstained fixed slides
<u>Adequacy</u>	: Cellular and Representative
<u>Cell Type</u>	: Predominantly many superficial cells & few Intermediate cells seen. Occasional parabasal cells noted. Few neutrophils seen amidst.
<u>Endocervical cells</u>	: Not seen
<u>Lactobacilli</u>	: Seen
<u>Pathogenic Organisms</u>	: Not seen
<u>Atypical Cells</u>	: Not seen
<u>Impression</u>	: Negative for Intraepithelial Lesion or Malignancy
<u>comment</u>	: -

--End Of Report--

Shradha Mhaskar
(Technician Name)

Dr Tabassum Shaikh
MBBS,MD (Pathology)
Consultant Pathologist

**MEESHA HEALTHCARE & RESEARCH PVT LTD**

La View, 1st Floor, B.J. Marg, Jacob Circle, Saat Rasta, Mahalaxmi Mumbai
Pin - 400011
Phone No. 2223053536/7710084305
www.meeshahealth.net
email: info@meeshahealth.net

LAB REPORT

Printed Date: 2024-04-17 08:20 PM

Patient Id : 44040	Patient Name : Mrs. MOUNIKA SOGALA	TreatmentId : 21082
Age/Gender : 26Y/Female	Mobile No : 7386804799	Ref. By :
Registered On : 17-04-2024 10:30 AM	Collected On : 17-04-2024 10:35 AM	Reported On : 17-04-2024 08:13 PM
Nationality : Indian	Patient Type : Sponsor	Sponsor Name : MediWheel(Arcofemi Healthcare Pvt. Ltd.)

CBC (COMPLETE BLOOD COUNT)

<u>Test Name</u>	<u>Test Result</u>	<u>Normal Values</u>	<u>Unit</u>
Haemoglobin	10.8 L	12 - 15	g/dl
R.B.C. Count	4.70	3.8 - 4.8	mill/cumm
Hematocrit(PCV)	35.4 L	36 - 46	%
M.C.V.	75.32 L	83 - 101	fl
M.C.H.	22.98 L	27 - 32	pg
M.C.H.C.	30.51 L	31 - 35	g/dl
RDW-CV	15.6 H	11.5 - 14	%
RDW-SD	44.4		
Platelet Count	323000	150000 - 400000	/cumm
Platelet On Smear	Adequate		
TOTAL WHITE BLOOD CELLS	9000	4000 - 10500	/cumm
Neutrophils	66	40 - 70	%
Band cells	00	0 - 10	%
Eosinophils	05	1 - 6	%
Lymphocytes	26	20 - 40	%
Monocytes	03	2 - 10	%
Basophils	00	0 - 02	%
R.B.C. Morphology	Mild-Hypo Mild-Micro Mild-Aniso Macrocytes Few Ovalocytosis Few		
W.B.C Morphology	Normal		
Parasite	-		
Comment	-		

Equipment: CELL COUNTER ERBA H 360**--End Of Report--****Shradha Mhaskar**
(Technician Name)**Dr Tabassum Shaikh**
MBBS,MD (Pathology)
Consultant Pathologist



MEESHA HEALTHCARE & RESEARCH PVT LTD

La View, 1st Floor, B.J. Marg, Jacob Circle, Saat Rasta, Mahalaxmi Mumbai
Pin - 400011
Phone No. 2223053536/7710084305
www.meeshahealth.net
email: info@meeshahealth.net

LAB REPORT

Printed Date: 2024-04-17 08:20 PM

Patient Id	: 44040	Patient Name	: Mrs. MOUNIKA SOGALA	TreatmentId	: 21082
Age/Gender	: 26Y/Female	Mobile No	: 7386804799	Ref. By	:
Registered On	: 17-04-2024 10:30 AM	Collected On	: 17-04-2024 10:35 AM	Reported On	: 17-04-2024 08:13 PM
Nationality	: Indian	Patient Type	: Sponsor	Sponsor Name	: MediWheel(Arcofemi Healthcare Pvt. Ltd.)

CREATININE

<u>Test Name</u>	<u>Test Result</u>	<u>Normal Values</u>	<u>Unit</u>
Serum Creatinine	0.60	0.6 - 1.3	mg/dl

Equipment: ERBA-EM 200 FULLY AUTOMATED CLINICAL CHEMISTRY ANALYSER.

--End Of Report--

Shradha Mhaskar
(Technician Name)

Dr Tabassum Shaikh
MBBS, MD (Pathology)
Consultant Pathologist



MEESHA HEALTHCARE & RESEARCH PVT LTD

La View, 1st Floor, B.J. Marg, Jacob Circle, Saat Rasta, Mahalaxmi Mumbai
Pin - 400011
Phone No. 2223053536/7710084305
www.meeshahealth.net
email: info@meeshahealth.net

LAB REPORT

Printed Date: 2024-04-17 08:20 PM

Patient Id	: 44040	Patient Name	: Mrs. MOUNIKA SOGALA	TreatmentId	: 21082
Age/Gender	: 26Y/Female	Mobile No	: 7386804799	Ref. By	:
Registered On	: 17-04-2024 10:30 AM	Collected On	: 17-04-2024 10:35 AM	Reported On	: 17-04-2024 08:13 PM
Nationality	: Indian	Patient Type	: Sponsor	Sponsor Name	: MediWheel(Arcofemi Healthcare Pvt. Ltd.)

BUN /CREATININE RATIO

<u>Test Name</u>	<u>Test Result</u>	<u>Normal Values</u>	<u>Unit</u>
Serum BUN	08	0 - 20	mg/dl
Serum Creatinine	0.60	0.6 - 1.3	mg/dl
BUN / Creat Ratio	13.33 L	30 - 40	/cumm

Equipment: ERBA-EM 200 FULLY AUTOMATED CLINICAL CHEMISTRY ANALYSER.

--End Of Report--

Shradha Mhaskar
(Technician Name)

Dr Tabassum Shaikh
MBBS,MD (Pathology)
Consultant Pathologist



MEESHA HEALTHCARE & RESEARCH PVT LTD

La View,1st Floor,B.J. Marg,Jacob Circle,Saat Rasta,Mahalaxmi Mumbai
Pin - 400011
Phone No. 2223053536/7710084305
www.meeshahealth.net
email: info@meeshahealth.net

LAB REPORT

Printed Date: 2024-04-17 08:20 PM

Patient Id	: 44040	Patient Name	: Mrs. MOUNIKA SOGALA	TreatmentId	: 21082
Age/Gender	: 26Y/Female	Mobile No	: 7386804799	Ref. By	:
Registered On	: 17-04-2024 10:30 AM	Collected On	: 17-04-2024 10:35 AM	Reported On	: 17-04-2024 08:13 PM
Nationality	: Indian	Patient Type	: Sponsor	Sponsor Name	: MediWheel(Arcofemi Healthcare Pvt. Ltd.)

BUN

<u>Test Name</u>	<u>Test Result</u>	<u>Normal Values</u>	<u>Unit</u>
Serum BUN	08	0 - 20	mg/dl

Equipment: ERBA-EM 200 FULLY AUTOMATED CLINICAL CHEMISTRY ANALYSER.

--End Of Report--

Shradha Mhaskar
(Technician Name)

Dr Tabassum Shaikh
MBBS,MD (Pathology)
Consultant Pathologist



MEESHA HEALTHCARE & RESEARCH PVT LTD

La View, 1st Floor, B.J. Marg, Jacob Circle, Saat Rasta, Mahalaxmi Mumbai
Pin - 400011
Phone No. 2223053536/7710084305
www.meeshahealth.net
email: info@meeshahealth.net

LAB REPORT

Printed Date: 2024-04-17 08:20 PM

Patient Id	: 44040	Patient Name	: Mrs. MOUNIKA SOGALA	TreatmentId	: 21082
Age/Gender	: 26Y/Female	Mobile No	: 7386804799	Ref. By	:
Registered On	: 17-04-2024 10:30 AM	Collected On	: 17-04-2024 10:35 AM	Reported On	: 17-04-2024 08:13 PM
Nationality	: Indian	Patient Type	: Sponsor	Sponsor Name	: MediWheel(Arcofemi Healthcare Pvt. Ltd.)

URIC ACID SERUM

<u>Test Name</u>	<u>Test Result</u>	<u>Normal Values</u>	<u>Unit</u>
Serum Uric Acid	5.2	2.5 - 6.8	mg/dl

Equipment: ERBA-EM 200 FULLY AUTOMATED CLINICAL CHEMISTRY ANALYSER.

--End Of Report--

Shradha Mhaskar
(Technician Name)

Dr Tabassum Shaikh
MBBS, MD (Pathology)
Consultant Pathologist



MEESHA HEALTHCARE & RESEARCH PVT LTD

La View, 1st Floor, B.J. Marg, Jacob Circle, Saat Rasta, Mahalaxmi Mumbai
Pin - 400011
Phone No. 2223053536/7710084305
www.meeshahealth.net
email: info@meeshahealth.net

LAB REPORT

Printed Date: 2024-04-17 08:20 PM

Patient Id	: 44040	Patient Name	: Mrs. MOUNIKA SOGALA	TreatmentId	: 21082
Age/Gender	: 26Y/Female	Mobile No	: 7386804799	Ref. By	:
Registered On	: 17-04-2024 10:30 AM	Collected On	: 17-04-2024 10:35 AM	Reported On	: 17-04-2024 08:13 PM
Nationality	: Indian	Patient Type	: Sponsor	Sponsor Name	: MediWheel(Arcofemi Healthcare Pvt. Ltd.)

LIPID PROFILE

<u>Test Name</u>	<u>Test Result</u>	<u>Normal Values</u>	<u>Unit</u>
Serum Cholesterol Total	101 L	140 - 250	mg/dl
Serum HDL Cholesterol	36.1	30 - 70	mg/dl
Serum Triglycerides	45.3	0 - 165	mg/dl
Serum LDL Cholesterol	55.84 L	85 - 130	mg/dl
Serum VLDL Cholesterol	9.06	0 - 40	mg/dl
LDL - HDL Ratio	1.55	0 - 100	ug/dl

Comment: -Rechecked.

Equipment: ERBA-EM 200 FULLY AUTOMATED CLINICAL CHEMISTRY ANALYSER.

--End Of Report--

Shraddha Mhaskar
(Technician Name)

Dr Tabassum Shaikh
MBBS,MD (Pathology)
Consultant Pathologist

**MEESHA HEALTHCARE & RESEARCH PVT LTD**

La View, 1st Floor, B.J. Marg, Jacob Circle, Saat Rasta, Mahalaxmi Mumbai
Pin - 400011
Phone No. 2223053536/7710084305
www.meeshahealth.net
email: info@meeshahealth.net

LAB REPORT

Printed Date: 2024-04-17 08:20 PM

Patient Id : 44040	Patient Name : Mrs. MOUNIKA SOGALA	TreatmentId : 21082
Age/Gender : 26Y/Female	Mobile No : 7386804799	Ref. By :
Registered On : 17-04-2024 10:30 AM	Collected On : 17-04-2024 10:35 AM	Reported On : 17-04-2024 08:13 PM
Nationality : Indian	Patient Type : Sponsor	Sponsor Name : MediWheel(Arcofemi Healthcare Pvt. Ltd.)

T3,T4,TSH (THYROID PROFILE)

<u>Test Name</u>	<u>Test Result</u>	<u>Normal Values</u>	<u>Unit</u>
SERUM T3 (Tri-Iodothyronine)	78	55 - 205	ng/dl
SERUM T4 (Tetra-Iodothyronine)	5.95	3.5 - 12.5	ug/dl
SERUM TSH (Thyroid Stimulating Hormone)	1.55	0.25 - 5.0	µIU/ml

Interpretation: REFERENCE RANGE : a. ADULT :-Euthyroid : 0.25 - 5.0 IU/ml
Hypothyroid : >7.0 IU/ml
Hyperthyroid:< 0.15 IU/ml

NOTE : TSH values between 0.15 - 0.25 IU/ml and between 5.0 - 7.0 IU/ml are to be considered as a borderline. Repeat results after 2 weeks.

b. PREGNANCY :- First Trimester : 0.25 - 4.0 IU/ml
Second Trimester : 0.5 - 4.0 IU/ml
Third Trimester : 0.4 - 5.0 IU/ml

c. NEWBORN :
1 - 4 days : 1.0 - 39.0 IU/ml
1 - 4 weeks : 1.7 - 9.1 IU/ml
1 - 12 months : 0.8 - 8.2 IU/ml
1 - 5 years : 0.7 - 5.7 IU/ml

NOTE : This assay is performed as per the standard kit protocol.

Equipment: BIOMERIEUX VIDAS

--End Of Report--

Shraddha Mhaskar
(Technician Name)

Dr Tabassum Shaikh
MBBS,MD (Pathology)
Consultant Pathologist



MEESHA HEALTHCARE & RESEARCH PVT LTD

La View,1st Floor,B.J. Marg,Jacob Circle,Saat Rasta,Mahalaxmi Mumbai
Pin - 400011
Phone No. 2223053536/7710084305
www.meeshahealth.net
email: info@meeshahealth.net

LAB REPORT

Printed Date: 2024-04-17 08:20 PM

Patient Id : 44040	Patient Name : Mrs. MOUNIKA SOGALA	TreatmentId : 21082
Age/Gender : 26Y/Female	Mobile No : 7386804799	Ref. By :
Registered On : 17-04-2024 10:30 AM	Collected On : 17-04-2024 10:35 AM	Reported On : 17-04-2024 08:13 PM
Nationality : Indian	Patient Type : Sponsor	Sponsor Name : MediWheel(Arcofemi Healthcare Pvt. Ltd.)

HbA1c (GLYCOSYLATED HAEMOGLOBIN)

<u>Test Name</u>	<u>Test Result</u>	<u>Normal Values</u>	<u>Unit</u>
GLYCOSYLATED HAEMOGLOBIN(HBA1C)	5.8	4.6 - 6.2	%
MEAN PLASMA GLUCOSE	119.76	0 - 154	mg/dl

Interpretation: 6.2 - 7.0 %----- Near Normal Glycemia
7.0 - 8.0 %----- Fair Control
8.0 - 10.0 %----- Unsatisfactory Control
Above 10.0 % ----- Poor control

TRACIBILITY :
The method has been certified by the National Glycohaemoglobin Standardization Program

CLINICAL SIGNIFICANCE :
HbA1c is a glycated form of haemoglobin formed by the attachment of glucose residues in the blood to the haemoglobin molecules. The level of HbA1c is proportional to the level of glucose in the blood & has been widely accepted as an indicator of the mean blood glucose concentration in the preceding 6-8 weeks. It is therefore a long term indicator of diabetic control. For routine use HbA1c levels should be monitored every 3-4 months.

Equipment: mispa-i2

--End Of Report--

Shraddha Mhaskar
(Technician Name)

Dr Tabassum Shaikh
MBBS,MD (Pathology)
Consultant Pathologist



MEESHA HEALTHCARE & RESEARCH PVT LTD

La View, 1st Floor, B.J. Marg, Jacob Circle, Saat Rasta, Mahalaxmi Mumbai
Pin - 400011
Phone No. 2223053536/7710084305
www.meeshahealth.net
email: info@meeshahealth.net

LAB REPORT

Printed Date: 2024-04-17 08:20 PM

Patient Id	: 44040	Patient Name	: Mrs. MOUNIKA SOGALA	TreatmentId	: 21082
Age/Gender	: 26Y/Female	Mobile No	: 7386804799	Ref. By	:
Registered On	: 17-04-2024 10:30 AM	Collected On	: 17-04-2024 10:35 AM	Reported On	: 17-04-2024 08:13 PM
Nationality	: Indian	Patient Type	: Sponsor	Sponsor Name	: MediWheel(Arcofemi Healthcare Pvt. Ltd.)

BSF AND PP

<u>Test Name</u>	<u>Test Result</u>	<u>Normal Values</u>	<u>Unit</u>
Blood Sugar (F)	91	70 - 110	mg/dl
Blood Sugar (PP)	104	70 - 140	mg/dl

Equipment: ERBA-EM 200 FULLY AUTOMATED CLINICAL CHEMISTRY ANALYSER.

--End Of Report--

Shraddha Mhaskar
(Technician Name)

Dr Tabassum Shaikh
MBBS, MD (Pathology)
Consultant Pathologist



MEESHA HEALTHCARE & RESEARCH PVT LTD

La View,1st Floor,B.J. Marg,Jacob Circle,Saat Rasta,Mahalaxmi Mumbai
Pin - 400011
Phone No. 2223053536/7710084305
www.meeshahealth.net
email: info@meeshahealth.net

LAB REPORT

Printed Date: 2024-04-17 08:20 PM

Patient Id	: 44040	Patient Name	: Mrs. MOUNIKA SOGALA	TreatmentId	: 21082
Age/Gender	: 26Y/Female	Mobile No	: 7386804799	Ref. By	:
Registered On	: 17-04-2024 10:30 AM	Collected On	: 17-04-2024 10:35 AM	Reported On	: 17-04-2024 08:13 PM
Nationality	: Indian	Patient Type	: Sponsor	Sponsor Name	: MediWheel(Arcofemi Healthcare Pvt. Ltd.)

BLOOD GROUP AND Rh TYPING

<u>Test Name</u>	<u>Test Result</u>
Blood Group	A
Rh Factor (D)	Positive

Interpretation: -1. Agglutination is a positive result and indicates the presence of A, B or D (Rho) Antigen
2. No agglutination is a negative result and indicates the absence of A, B or D (Rho) Antigen
--End Of Report--

Shraddha Mhaskar
(Technician Name)

Dr Tabassum Shaikh
MBBS,MD (Pathology)
Consultant Pathologist



MEESHA HEALTHCARE & RESEARCH PVT LTD

La View, 1st Floor, B.J. Marg, Jacob Circle, Saat Rasta, Mahalaxmi Mumbai
Pin - 400011
Phone No. 2223053536/7710084305
www.meeshahealth.net
email: info@meeshahealth.net

LAB REPORT

Printed Date: 2024-04-17 08:20 PM

Patient Id : 44040	Patient Name : Mrs. MOUNIKA SOGALA	TreatmentId : 21082
Age/Gender : 26Y/Female	Mobile No : 7386804799	Ref. By :
Registered On : 17-04-2024 10:30 AM	Collected On : 17-04-2024 10:35 AM	Reported On : 17-04-2024 08:13 PM
Nationality : Indian	Patient Type : Sponsor	Sponsor Name : MediWheel(Arcofemi Healthcare Pvt. Ltd.)

URINE ROUTINE

<u>Test Name</u>	<u>Test Result</u>
PHYSICAL EXAMINATION	
Quantity	50 ml
Appearance	Slightly Hazy
Colour	Pale Yellow
Specific Gravity	1.020
Blood	Absent
CHEMICAL EXAMINATION	
Reaction (pH)	Acidic 5.0
Albumin	Absent
Glucose	Absent
Ketone Bodies	Absent
Bile Pigment	Absent
Urobilinogen	Normal
Occult blood	Absent
MICROSCOPIC EXAMINATION	
Epithelial Cells	7-8/hpf
Pus Cells	1-2/hpf
Red Blood Cells	0-1/hpf
Yeast cell	Absent
Casts	Absent
Crystals	Absent
Amorphous Deposit	Absent
Bacteria	Absent

--End Of Report--

Shradha Mhaskar
(Technician Name)

Dr Tabassum Shaikh
MBBS,MD (Pathology)
Consultant Pathologist



MEESHA HEALTHCARE & RESEARCH PVT LTD

La View, 1st Floor, B.J. Marg, Jacob Circle, Saat Rasta, Mahalaxmi Mumbai
Pin - 400011
Phone No. 2223053536/7710084305
www.meeshahealth.net
email: info@meeshahealth.net

LAB REPORT

Printed Date: 2024-04-17 08:20 PM

Patient Id	: 44040	Patient Name	: Mrs. MOUNIKA SOGALA	TreatmentId	: 21082
Age/Gender	: 26Y/Female	Mobile No	: 7386804799	Ref. By	:
Registered On	: 17-04-2024 10:30 AM	Collected On	: 17-04-2024 10:35 AM	Reported On	: 17-04-2024 08:13 PM
Nationality	: Indian	Patient Type	: Sponsor	Sponsor Name	: MediWheel(Arcofemi Healthcare Pvt. Ltd.)

ESR (Erythrocyte Sedimentation Rate)

<u>Test Name</u>	<u>Test Result</u>	<u>Normal Values</u>	<u>Unit</u>
ESR	<u>70 H</u>	0 - 20	mm/hr

--End Of Report--

Shradha Mhaskar
(Technician Name)

Dr Tabassum Shaikh
MBBS,MD (Pathology)
Consultant Pathologist

Branch :

Ground Floor, 12-C, Moti Mahal, C.S. No. 1631, Churchgate, Mumbai-400 020.
Tel. : +91 22 3574 1977 / 93241 87465 / 77100 84304

Patient Name : MRS.MOUNIKA SOGALA
Age : 26 YEARS
Ref. By : MEDIWHEEL

ID No : 44040
Sex : FEMALE
Date : 17.04.2024

ULTRASONOGRAPHY OF THE ABDOMEN AND PELVIS

Liver

Is normal in size measures 14.1 cm and shows normal echotexture.

No focal or diffuse lesion is seen.

The biliary tree and portal vein radicals are normal.

Portal vein measures 10.4 mm Common bile duct measures 3.4 mm

Gall bladder

Is physiologically distended and reveals an anechoic lumen.

No gallstone or evidence of cholecystitis is seen.

Pancreas

Reveals a homogenous normal parenchymal echotexture and appears normal in size.

No solid or cystic mass lesion is seen. No pancreatic calcification or duct dilatation is seen.

Spleen

Is mildly enlarged in size measures 12 cms. The parenchymal echotexture is normal.

No focal mass lesion is seen.

Kidneys

The right kidney measures 10.4 x 4.4 cms. The left kidney measures 11.6 x 4.2 cms

Both kidneys are normal in size, shape and reveal normal differentiation of cortex, medulla and central echo complex.

No hydronephrosis, calculus or scarring is seen.

Urinary bladder

Was distended and revealed no intrinsic abnormality.

No para aortic lymphadenopathy or ascites is seen.

Branch :

Ground Floor, 12-C, Moti Mahal, C.S. No. 1631, Churchgate, Mumbai-400 020.
Tel. : +91 22 3574 1977 / 93241 87465 / 77100 84304

Patient Name : MRS.MOUNIKA SOGALA
Age : 26 YEARS
Ref. By : MEDIWHEEL

ID No : 44040
Sex : FEMALE
Date : 17.04.2024

Uterus

Is anteverted and normal in size. Uterus measures 5.0 x 4.1 x 3.4 cms.
The myometrium and endometrium reveal normal echogenicity.
No mass lesion is seen.
Endometrium thickness is normal and measures 5.2 mm.

Ovaries

Both ovaries appear normal in size and echotexture.
Right ovary measures 3.2 x 2.6 x 2.0 cms.(vol-9.4 cc)
Left ovary measures 3.2 x 2.7 x 1.0 cms.(vol-8.6 cc)

Minimal free fluid in Cul de sac.


IMPRESSION :

- **Mild splenomegaly.**
 - **Minimal free fluid in Cul de sac.**
- Suggest Clinicopathological correlation.**

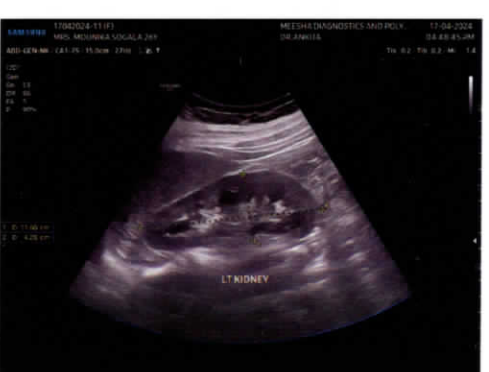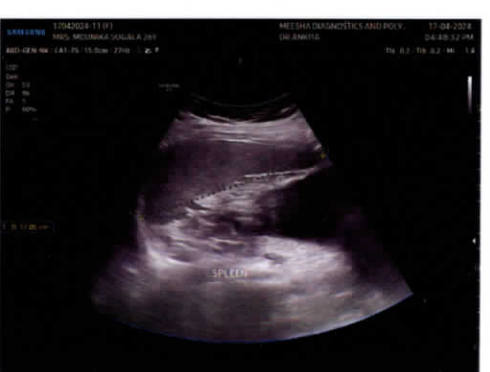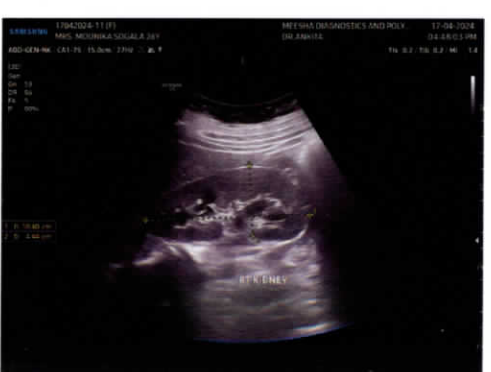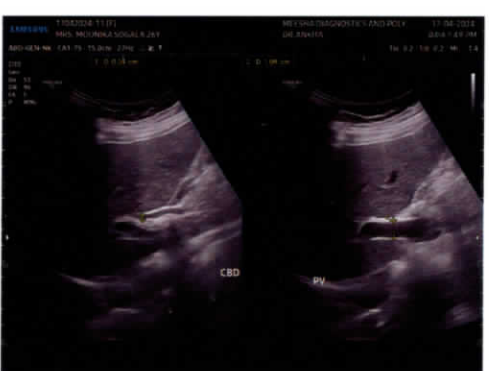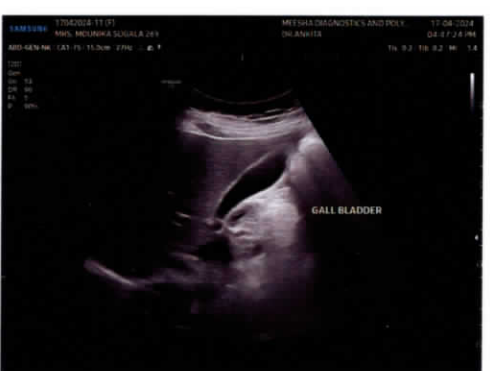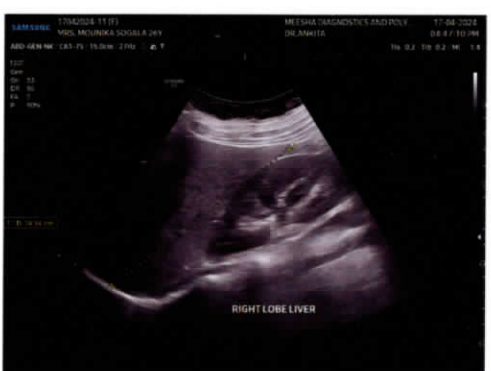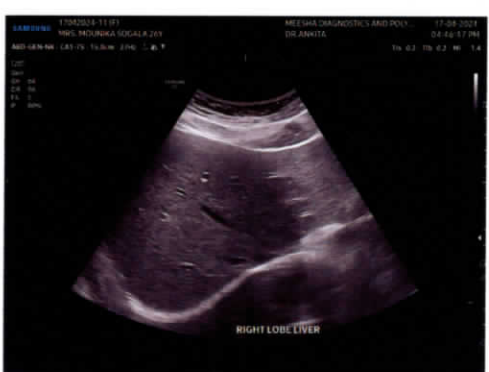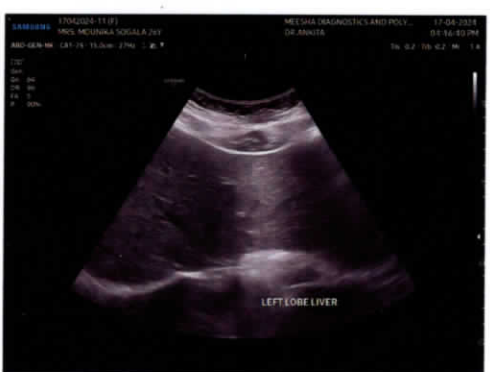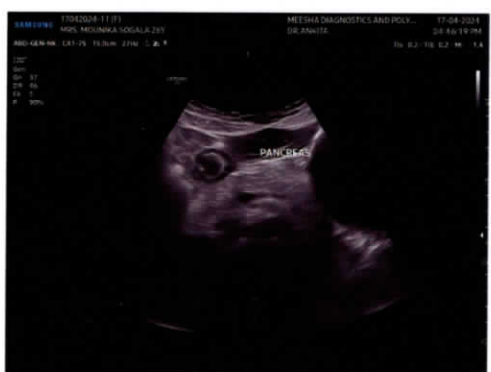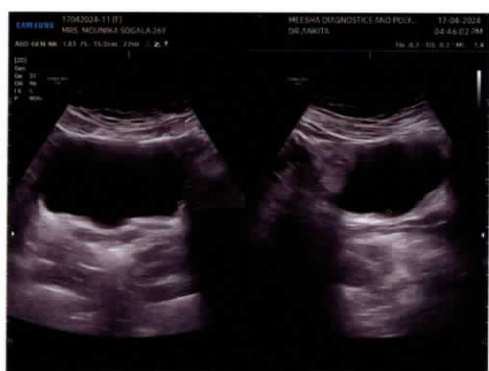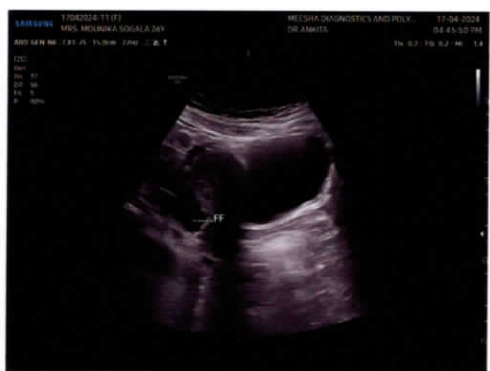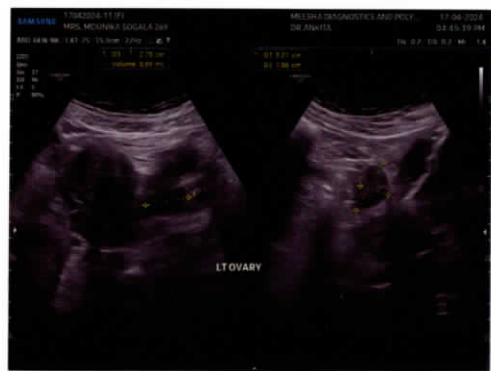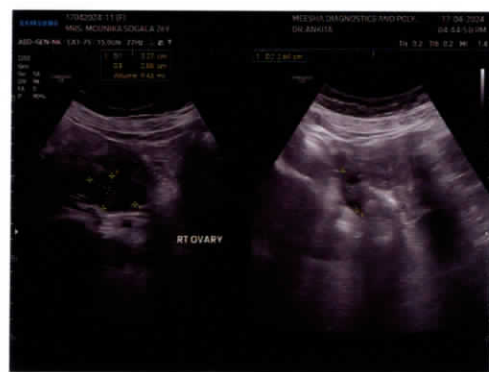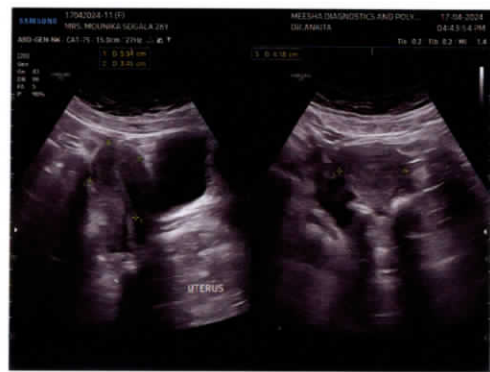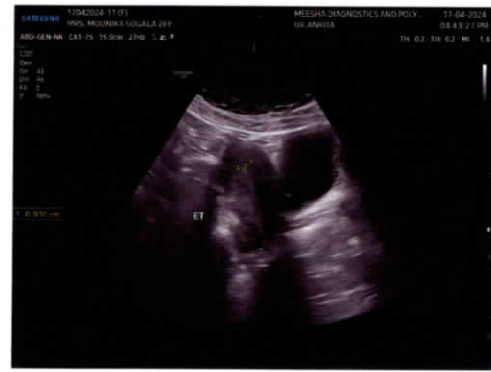Dr. Ankita Vinod Marewar

M.B.B.S, D.M.R.E.

Reg. No. 2016050985



DR. ANKITA V. MAREWAR
M.B.B.S, D.M.R.E
CONSULTANT RADIOLOGIST



Branch :

Ground Floor, 12-C, Moti Mahal, C.S. No. 1631, Churchgate, Mumbai-400 020.
Tel. : +91 22 3574 1977 / 93241 87465 / 77100 84304

Patient Name : MRS.MOUNIKA SOGALA
Age : 26 YEARS
Ref. By : MEDIWHEEL

ID No : 44040
Sex : FEMALE
Date : 17.04.2024

SONOMAMMOGRAPHY BOTH BREASTS

Technique:

Real time ultrasonographic examination was done using a high resolution, high frequency 12 MHZ transducer.

Right breast:-

The fibro fatty and glandular tissue appears normal in echotexture.

No architectural distortion is seen.

No micro or macro calcifications are seen.

Screening of the right axilla reveals few reactive lymph nodes with intact fatty hilum, largest measuring 2.2 x 0.6 cm

Left breast:-

The fibro fatty and glandular tissue appears normal in echotexture.

No architectural distortion is seen.

No micro or macro calcifications are seen.

Screening of the left axilla reveals few reactive lymph nodes with intact fatty hilum, largest measuring 1.5 x 0.7 cm

IMPRESSION :

- No significant abnormality seen in either breast. BI-RADS-I
- Few rective bilateral axillary lymph nodes.

Suggest clinical correlation.


Dr. Ankita Vinod Marewar
M.B.B.S, D.M.R.E.
Reg. No. 2016050985

DR. ANKITA V. MAREWAR
M.B.B.S, D.M.R.E
CONSULTANT RADIOLOGIST

ISO : 9001:2015 Certified

Right Diagnosis, Right Treatment, Right Place

