



CID : 2405000524
Name : MRS.SONAL PARESH TANK
Age / Gender : 53 Years / Female
Consulting Dr. : -
Reg. Location : Kandivali East (Main Centre)

Collected : 19-Feb-2024 / 08:48
Reported : 19-Feb-2024 / 16:42

Use a QR Code Scanner
Application To Scan the Code

MEDIWHEEL FULL BODY HEALTH CHECKUP FEMALE ABOVE 40/2D ECHO

CBC (Complete Blood Count), Blood

<u>PARAMETER</u>	<u>RESULTS</u>	<u>BIOLOGICAL REF RANGE</u>	<u>METHOD</u>
<u>RBC PARAMETERS</u>			
Haemoglobin	15.0	12.0-15.0 g/dL	Spectrophotometric
RBC	5.14	3.8-4.8 mil/cmm	Elect. Impedance
PCV	44.6	36-46 %	Calculated
MCV	86.9	81-101 fl	Measured
MCH	29.2	27-32 pg	Calculated
MCHC	33.7	31.5-34.5 g/dL	Calculated
RDW	12.4	11.6-14.0 %	Calculated
<u>WBC PARAMETERS</u>			
WBC Total Count	7420	4000-10000 /cmm	Elect. Impedance
<u>WBC DIFFERENTIAL AND ABSOLUTE COUNTS</u>			
Lymphocytes	35.9	20-40 %	
Absolute Lymphocytes	2660	1000-3000 /cmm	Calculated
Monocytes	6.7	2-10 %	
Absolute Monocytes	500	200-1000 /cmm	Calculated
Neutrophils	55.8	40-80 %	
Absolute Neutrophils	4130	2000-7000 /cmm	Calculated
Eosinophils	1.6	1-6 %	
Absolute Eosinophils	120	20-500 /cmm	Calculated
Basophils	0.0	0.1-2 %	
Absolute Basophils	0.0	20-100 /cmm	Calculated
Immature Leukocytes	-		
WBC Differential Count by Absorbance & Impedance method/Microscopy.			
<u>PLATELET PARAMETERS</u>			
Platelet Count	282000	150000-410000 /cmm	Elect. Impedance
MPV	7.2	6-11 fl	Measured
PDW	11.5	11-18 %	Calculated
<u>RBC MORPHOLOGY</u>			
Hypochromia	-		
Microcytosis	-		



CID : 2405000524
Name : MRS.SONAL PARESH TANK
Age / Gender : 53 Years / Female
Consulting Dr. : -
Reg. Location : Kandivali East (Main Centre)

Collected : 19-Feb-2024 / 08:48
Reported : 19-Feb-2024 / 16:34

Use a QR Code Scanner
Application To Scan the Code

Macrocytosis	-
Anisocytosis	-
Poikilocytosis	-
Polychromasia	-
Target Cells	-
Basophilic Stippling	-
Normoblasts	-
Others	Normocytic, Normochromic
WBC MORPHOLOGY	-
PLATELET MORPHOLOGY	-
COMMENT	-

Specimen: EDTA Whole Blood

ESR, EDTA WB-ESR 6 2-30 mm at 1 hr. Sedimentation

Clinical Significance: The erythrocyte sedimentation rate (ESR), also called a sedimentation rate is the rate red blood cells sediment in a period of time.

Interpretation:

Factors that increase ESR: Old age, Pregnancy, Anemia

Factors that decrease ESR: Extreme leukocytosis, Polycythemia, Red cell abnormalities- Sickle cell disease

Limitations:

- It is a non-specific measure of inflammation.
- The use of the ESR as a screening test in asymptomatic persons is limited by its low sensitivity and specificity.

Reflex Test: C-Reactive Protein (CRP) is the recommended test in acute inflammatory conditions.

Reference:

- Pack Insert
- Brigden ML. Clinical utility of the erythrocyte sedimentation rate. American family physician. 1999 Oct 1;60(5):1443-50.

*Sample processed at SUBURBAN DIAGNOSTICS (INDIA) PVT. LTD SDRL, Vidyavihar Lab

*** End Of Report ***



Dr. TRUPTI SHETTY
M. D. (PATH)
Pathologist



CID : 2405000524
Name : MRS.SONAL PARESH TANK
Age / Gender : 53 Years / Female
Consulting Dr. : -
Reg. Location : Kandivali East (Main Centre)

Use a QR Code Scanner Application To Scan the Code
Collected : 19-Feb-2024 / 08:48
Reported : 19-Feb-2024 / 16:42

MEDIWHEEL FULL BODY HEALTH CHECKUP FEMALE ABOVE 40/2D ECHO

<u>PARAMETER</u>	<u>RESULTS</u>	<u>BIOLOGICAL REF RANGE</u>	<u>METHOD</u>
GLUCOSE (SUGAR) FASTING, Fluoride Plasma	128.3	Non-Diabetic: < 100 mg/dl Impaired Fasting Glucose: 100-125 mg/dl Diabetic: >/= 126 mg/dl	Hexokinase
GLUCOSE (SUGAR) PP, Fluoride Plasma PP/R	178.7	Non-Diabetic: < 140 mg/dl Impaired Glucose Tolerance: 140-199 mg/dl Diabetic: >/= 200 mg/dl	Hexokinase
Urine Sugar (Fasting)	Absent	Absent	
Urine Ketones (Fasting)	Absent	Absent	

*Sample processed at SUBURBAN DIAGNOSTICS (INDIA) PVT. LTD SDRL, Vidyavihar Lab
*** End Of Report ***



Dr. ANUPA DIXIT
M.D.(PATH)
Consultant Pathologist & Lab Director



CID : 2405000524
Name : MRS.SONAL PARESH TANK
Age / Gender : 53 Years / Female
Consulting Dr. : -
Reg. Location : Kandivali East (Main Centre)

Collected : 19-Feb-2024 / 08:48
Reported : 19-Feb-2024 / 17:02

Use a QR Code Scanner
Application To Scan the Code

MEDIWHEEL FULL BODY HEALTH CHECKUP FEMALE ABOVE 40/2D ECHO
KIDNEY FUNCTION TESTS

<u>PARAMETER</u>	<u>RESULTS</u>	<u>BIOLOGICAL REF RANGE</u>	<u>METHOD</u>
BLOOD UREA, Serum	35.4	19.29-49.28 mg/dl	Calculated
BUN, Serum	16.5	9.0-23.0 mg/dl	Urease with GLDH
CREATININE, Serum	0.69	0.55-1.02 mg/dl	Enzymatic
Note: Kindly note in change in reference range w.e.f. 07-09-2023			
eGFR, Serum	104	(ml/min/1.73sqm) Normal or High: Above 90 Mild decrease: 60-89 Mild to moderate decrease: 45-59 Moderate to severe decrease: 30-44 Severe decrease: 15-29 Kidney failure: <15	Calculated
Note: eGFR estimation is calculated using 2021 CKD-EPI GFR equation w.e.f 16-08-2023			
TOTAL PROTEINS, Serum	7.4	5.7-8.2 g/dL	Biuret
ALBUMIN, Serum	4.4	3.2-4.8 g/dL	BCG
GLOBULIN, Serum	3.0	2.3-3.5 g/dL	Calculated
A/G RATIO, Serum	1.5	1 - 2	Calculated
URIC ACID, Serum	5.4	3.1-7.8 mg/dl	Uricase/ Peroxidase
PHOSPHORUS, Serum	2.9	2.4-5.1 mg/dl	Phosphomolybdate
CALCIUM, Serum	9.6	8.7-10.4 mg/dl	Arsenazo
SODIUM, Serum	140	136-145 mmol/l	IMT
POTASSIUM, Serum	4.3	3.5-5.1 mmol/l	IMT
CHLORIDE, Serum	105	98-107 mmol/l	IMT

*Sample processed at SUBURBAN DIAGNOSTICS (INDIA) PVT. LTD SDRL, Vidyavihar Lab
*** End Of Report ***



Dr. Vrushali Shroff

Dr.VRUSHALI SHROFF
M.D.(PATH)
Pathologist



CID : 2405000524
Name : MRS.SONAL PARESH TANK
Age / Gender : 53 Years / Female
Consulting Dr. : -
Reg. Location : Kandivali East (Main Centre)

Collected : 19-Feb-2024 / 08:48
Reported : 19-Feb-2024 / 16:38

Use a QR Code Scanner
Application To Scan the Code

MEDIWHEEL FULL BODY HEALTH CHECKUP FEMALE ABOVE 40/2D ECHO
GLYCOSYLATED HEMOGLOBIN (HbA1c)

PARAMETER	RESULTS	BIOLOGICAL REF RANGE	METHOD
Glycosylated Hemoglobin (HbA1c), EDTA WB - CC	6.2	Non-Diabetic Level: < 5.7 % Prediabetic Level: 5.7-6.4 % Diabetic Level: >/= 6.5 %	HPLC
Estimated Average Glucose (eAG), EDTA WB - CC	131.2	mg/dl	Calculated

Intended use:

- In patients who are meeting treatment goals, HbA1c test should be performed at least 2 times a year
- In patients whose therapy has changed or who are not meeting glycemic goals, it should be performed quarterly
- For microvascular disease prevention, the HbA1C goal for non pregnant adults in general is Less than 7%.

Clinical Significance:

- HbA1c, Glycosylated hemoglobin or glycated hemoglobin, is hemoglobin with glucose molecule attached to it.
- The HbA1c test evaluates the average amount of glucose in the blood over the last 2 to 3 months by measuring the percentage of glycosylated hemoglobin in the blood.

Test Interpretation:

- The HbA1c test evaluates the average amount of glucose in the blood over the last 2 to 3 months by measuring the percentage of Glycosylated hemoglobin in the blood.
- HbA1c test may be used to screen for and diagnose diabetes or risk of developing diabetes.
- To monitor compliance and long term blood glucose level control in patients with diabetes.
- Index of diabetic control, predicting development and progression of diabetic micro vascular complications.

Factors affecting HbA1c results:

Increased in: High fetal hemoglobin, Chronic renal failure, Iron deficiency anemia, Splenectomy, Increased serum triglycerides, Alcohol ingestion, Lead/opiate poisoning and Salicylate treatment.

Decreased in: Shortened RBC lifespan (Hemolytic anemia, blood loss), following transfusions, pregnancy, ingestion of large amount of Vitamin E or Vitamin C and Hemoglobinopathies

Reflex tests: Blood glucose levels, CGM (Continuous Glucose monitoring)

References: ADA recommendations, AACC, Wallach's interpretation of diagnostic tests 10th edition.

*Sample processed at SUBURBAN DIAGNOSTICS (INDIA) PVT. LTD SDRL, Vidyavihar Lab

*** End Of Report ***



Dr. TRUPTI SHETTY
M. D. (PATH)
Pathologist



CID : 2405000524
Name : MRS.SONAL PARESH TANK
Age / Gender : 53 Years / Female
Consulting Dr. : -
Reg. Location : Kandivali East (Main Centre)

Collected : 19-Feb-2024 / 08:48
Reported : 19-Feb-2024 / 16:41

Use a QR Code Scanner
Application To Scan the Code

MEDIWHEEL FULL BODY HEALTH CHECKUP FEMALE ABOVE 40/2D ECHO
EXAMINATION OF FAECES

<u>PARAMETER</u>	<u>RESULTS</u>	<u>BIOLOGICAL REF RANGE</u>	<u>METHOD</u>
<u>PHYSICAL EXAMINATION</u>			
Colour	Yellow	Brown	-
Form and Consistency	Semi Solid	Semi Solid	-
Mucus	Absent	Absent	-
Blood	Absent	Absent	-
<u>CHEMICAL EXAMINATION</u>			
Reaction (pH)	Acidic (6.0)	-	pH Indicator
Occult Blood	Absent	Absent	Guaiaac
<u>MICROSCOPIC EXAMINATION</u>			
Protozoa	Absent	Absent	-
Flagellates	Absent	Absent	-
Ciliates	Absent	Absent	-
Parasites	Absent	Absent	-
Macrophages	Absent	Absent	-
Mucus Strands	Absent	Absent	-
Fat Globules	Absent	Absent	-
RBC/hpf	Absent	Absent	-
WBC/hpf	Absent	Absent	-
Yeast Cells	Absent	Absent	-
Undigested Particles	Present +	-	-
Concentration Method (for ova)	No ova detected	Absent	-
Reducing Substances	-	Absent	Benedicts

*Sample processed at SUBURBAN DIAGNOSTICS (INDIA) PVT. LTD Borivali Lab, Borivali West
*** End Of Report ***



Bmhasakar

Dr.KETAKI MHASKAR
M.D. (PATH)
Pathologist



CID : 2405000524
Name : MRS.SONAL PARESH TANK
Age / Gender : 53 Years / Female
Consulting Dr. : -
Reg. Location : Kandivali East (Main Centre)

Use a QR Code Scanner
Application To Scan the Code
Collected : 19-Feb-2024 / 08:48
Reported : 19-Feb-2024 / 16:41

MEDIWHEEL FULL BODY HEALTH CHECKUP FEMALE ABOVE 40/2D ECHO
URINE EXAMINATION REPORT

<u>PARAMETER</u>	<u>RESULTS</u>	<u>BIOLOGICAL REF RANGE</u>	<u>METHOD</u>
<u>PHYSICAL EXAMINATION</u>			
Color	Pale yellow	Pale Yellow	-
Reaction (pH)	5.0	4.5 - 8.0	Chemical Indicator
Specific Gravity	1.020	1.001-1.030	Chemical Indicator
Transparency	Clear	Clear	-
Volume (ml)	30	-	-
<u>CHEMICAL EXAMINATION</u>			
Proteins	Absent	Absent	pH Indicator
Glucose	Absent	Absent	GOD-POD
Ketones	Absent	Absent	Legals Test
Blood	2+	Absent	Peroxidase
Bilirubin	Absent	Absent	Diazonium Salt
Urobilinogen	Normal	Normal	Diazonium Salt
Nitrite	Absent	Absent	Griess Test
<u>MICROSCOPIC EXAMINATION</u>			
Leukocytes(Pus cells)/hpf	2-3	0-5/hpf	
Red Blood Cells / hpf	3-4	0-2/hpf	
Epithelial Cells / hpf	1-2		
Casts	Absent	Absent	
Crystals	Absent	Absent	
Amorphous debris	Absent	Absent	
Bacteria / hpf	+(>20/hpf)	Less than 20/hpf	
Others	-		

Interpretation: The concentration values of Chemical analytes corresponding to the grading given in the report are as follows:

- Protein (1+ = 25 mg/dl , 2+ =75 mg/dl , 3+ = 150 mg/dl , 4+ = 500 mg/dl)
- Glucose(1+ = 50 mg/dl , 2+ =100 mg/dl , 3+ =300 mg/dl ,4+ =1000 mg/dl)
- Ketone (1+ =5 mg/dl , 2+ = 15 mg/dl , 3+= 50 mg/dl , 4+ = 150 mg/dl)

Reference: Pack inert

*Sample processed at SUBURBAN DIAGNOSTICS (INDIA) PVT. LTD Borivali Lab, Borivali West
*** End Of Report ***



Bmhasakar

Dr.KETAKI MHASKAR
M.D. (PATH)
Pathologist



CID : 2405000524
Name : MRS.SONAL PARESH TANK
Age / Gender : 53 Years / Female
Consulting Dr. : -
Reg. Location : Kandivali East (Main Centre)

Collected : 19-Feb-2024 / 08:48
Reported : 19-Feb-2024 / 14:17

Use a QR Code Scanner
Application To Scan the Code

MEDIWHEEL FULL BODY HEALTH CHECKUP FEMALE ABOVE 40/2D ECHO
BLOOD GROUPING & Rh TYPING

<u>PARAMETER</u>	<u>RESULTS</u>
ABO GROUP	B
Rh TYPING	Positive

NOTE: Test performed by automated Erythrocytes magnetized technology (EMT) which is more sensitive than conventional methods.

Specimen: EDTA Whole Blood and/or serum

Clinical significance:
ABO system is most important of all blood group in transfusion medicine

Limitations:

- ABO blood group of new born is performed only by cell (forward) grouping because allo antibodies in cord blood are of maternal origin.
- Since A & B antigens are not fully developed at birth, both Anti-A & Anti-B antibodies appear after the first 4 to 6 months of life. As a result, weaker reactions may occur with red cells of newborns than of adults.
- Confirmation of newborn's blood group is indicated when A & B antigen expression and the isoagglutinins are fully developed at 2 to 4 years of age & remains constant throughout life.
- Cord blood is contaminated with Wharton's jelly that causes red cell aggregation leading to false positive result
- The Hh blood group also known as Oh or Bombay blood group is rare blood group type. The term Bombay is used to refer the phenotype that lacks normal expression of ABH antigens because of inheritance of hh genotype.

References:

1. Denise M Harmening, Modern Blood Banking and Transfusion Practices- 6th Edition 2012. F.A. Davis company. Philadelphia
2. AABB technical manual

*Sample processed at SUBURBAN DIAGNOSTICS (INDIA) PVT. LTD SDRL, Vidyavihar Lab
*** End Of Report ***



Dr. Vrushi Shroff

Dr.VRUSHALI SHROFF
M.D.(PATH)
Pathologist



CID : 2405000524
Name : MRS.SONAL PARESH TANK
Age / Gender : 53 Years / Female
Consulting Dr. : -
Reg. Location : Kandivali East (Main Centre)

Collected : 19-Feb-2024 / 08:48
Reported : 19-Feb-2024 / 17:02

Use a QR Code Scanner
Application To Scan the Code

MEDIWHEEL FULL BODY HEALTH CHECKUP FEMALE ABOVE 40/2D ECHO
LIPID PROFILE

PARAMETER	RESULTS	BIOLOGICAL REF RANGE	METHOD
CHOLESTEROL, Serum	200.6	Desirable: <200 mg/dl Borderline High: 200-239mg/dl High: >/=240 mg/dl	CHOD-POD
TRIGLYCERIDES, Serum	98.0	Normal: <150 mg/dl Borderline-high: 150 - 199 mg/dl High: 200 - 499 mg/dl Very high:>/=500 mg/dl	Enzymatic colorimetric
HDL CHOLESTEROL, Serum	51.3	Desirable: >60 mg/dl Borderline: 40 - 60 mg/dl Low (High risk): <40 mg/dl	Elimination/ Catalase
NON HDL CHOLESTEROL, Serum	149.3	Desirable: <130 mg/dl Borderline-high:130 - 159 mg/dl High:160 - 189 mg/dl Very high: >/=190 mg/dl	Calculated
LDL CHOLESTEROL, Serum	129.7	Optimal: <100 mg/dl Near Optimal: 100 - 129 mg/dl Borderline High: 130 - 159 mg/dl High: 160 - 189 mg/dl Very High: >/= 190 mg/dl	Calculated
VLDL CHOLESTEROL, Serum	19.6	< /= 30 mg/dl	Calculated
CHOL / HDL CHOL RATIO, Serum	3.9	0-4.5 Ratio	Calculated
LDL CHOL / HDL CHOL RATIO, Serum	2.5	0-3.5 Ratio	Calculated

*Sample processed at SUBURBAN DIAGNOSTICS (INDIA) PVT. LTD SDRL, Vidyavihar Lab
*** End Of Report ***



Signature

Dr.VRUSHALI SHROFF
M.D.(PATH)
Pathologist



CID : 2405000524
 Name : MRS.SONAL PARESH TANK
 Age / Gender : 53 Years / Female
 Consulting Dr. : -
 Reg. Location : Kandivali East (Main Centre)

Use a QR Code Scanner
 Application To Scan the Code
 Collected : 19-Feb-2024 / 08:48
 Reported : 19-Feb-2024 / 16:48

MEDIWHEEL FULL BODY HEALTH CHECKUP FEMALE ABOVE 40/2D ECHO
THYROID FUNCTION TESTS

<u>PARAMETER</u>	<u>RESULTS</u>	<u>BIOLOGICAL REF RANGE</u>	<u>METHOD</u>
Free T3, Serum	5.0	3.5-6.5 pmol/L	CLIA
Free T4, Serum	13.9	11.5-22.7 pmol/L	CLIA
sensitiveTSH, Serum	2.230	0.55-4.78 microIU/ml mIU/ml	CLIA



CID : 2405000524
Name : MRS.SONAL PARESH TANK
Age / Gender : 53 Years / Female
Consulting Dr. : -
Reg. Location : Kandivali East (Main Centre)

Use a QR Code Scanner Application To Scan the Code
Collected : 19-Feb-2024 / 08:48
Reported : 19-Feb-2024 / 16:48

Interpretation:

A thyroid panel is used to evaluate thyroid function and/or help diagnose various thyroid disorders.

Clinical Significance:

- 1)TSH Values between high abnormal upto15 microIU/ml should be correlated clinically or repeat the test with new sample as physiological factors can give falsely high TSH.
- 2)TSH values may be trasiently altered becuae of non thyroidal illness like severe infections,liver disease, renal and heart severe burns, trauma and surgery etc.

TSH	FT4 / T4	FT3 / T3	Interpretation
High	Normal	Normal	Subclinical hypothyroidism, poor compliance with thyroxine, drugs like amiodarone, Recovery phase of non-thyroidal illness, TSH Resistance.
High	Low	Low	Hypothyroidism, Autoimmune thyroiditis, post radio iodine Rx, post thyroidectomy, Anti thyroid drugs, tyrosine kinase inhibitors & amiodarone, amyloid deposits in thyroid, thyroid tumors & congenital hypothyroidism.
Low	High	High	Hyperthyroidism, Graves disease, toxic multinodular goiter, toxic adenoma, excess iodine or thyroxine intake, pregnancy related (hyperemesis gravidarum, hydatiform mole)
Low	Normal	Normal	Subclinical Hyperthyroidism, recent Rx for Hyperthyroidism, drugs like steroids & dopamine), Non thyroidal illness.
Low	Low	Low	Central Hypothyroidism, Non Thyroidal Illness, Recent Rx for Hyperthyroidism.
High	High	High	Interfering anti TPO antibodies, Drug interference: Amiodarone, Heparin, Beta Blockers, steroids & anti epileptics.

Diurnal Variation:TSH follows a diurnal rhythm and is at maximum between 2 am and 4 am , and is at a minimum between 6 pm and 10 pm. The variation is on the order of 50 to 206%. Biological variation:19.7%(with in subject variation)

Reflex Tests:Anti thyroid Antibodies,USG Thyroid ,TSH receptor Antibody. Thyroglobulin, Calcitonin

Limitations:

1. Samples should not be taken from patients receiving therapy with high biotin doses (i.e. >5 mg/day) until atleast 8 hours following the last biotin administration.
2. Patient samples may contain heterophilic antibodies that could react in immunoassays to give falsely elevated or depressed results. this assay is designed to minimize interference from heterophilic antibodies.

Reference:

- 1.O.koulouri et al. / Best Practice and Research clinical Endocrinology and Metabolism 27(2013)
- 2.Interpretation of the thyroid function tests, Dayan et al. THE LANCET . Vol 357
- 3.Tietz ,Text Book of Clinical Chemistry and Molecular Biology -5th Edition
- 4.Biological Variation:From principles to Practice-Callum G Fraser (AACC Press)

*Sample processed at SUBURBAN DIAGNOSTICS (INDIA) PVT. LTD SDRL, Vidyavihar Lab
*** End Of Report ***



Anupa

Dr.ANUPA DIXIT
M.D.(PATH)
Consultant Pathologist & Lab Director



CID : 2405000524
Name : MRS.SONAL PARESH TANK
Age / Gender : 53 Years / Female
Consulting Dr. : -
Reg. Location : Kandivali East (Main Centre)

Use a QR Code Scanner
Application To Scan the Code
Collected : 19-Feb-2024 / 08:48
Reported : 19-Feb-2024 / 17:02

MEDIWHEEL FULL BODY HEALTH CHECKUP FEMALE ABOVE 40/2D ECHO
LIVER FUNCTION TESTS

<u>PARAMETER</u>	<u>RESULTS</u>	<u>BIOLOGICAL REF RANGE</u>	<u>METHOD</u>
BILIRUBIN (TOTAL), Serum	0.58	0.3-1.2 mg/dl	Vanadate oxidation
BILIRUBIN (DIRECT), Serum	0.18	0-0.3 mg/dl	Vanadate oxidation
BILIRUBIN (INDIRECT), Serum	0.40	<1.2 mg/dl	Calculated
TOTAL PROTEINS, Serum	7.4	5.7-8.2 g/dL	Biuret
ALBUMIN, Serum	4.4	3.2-4.8 g/dL	BCG
GLOBULIN, Serum	3.0	2.3-3.5 g/dL	Calculated
A/G RATIO, Serum	1.5	1 - 2	Calculated
SGOT (AST), Serum	19.7	<34 U/L	Modified IFCC
SGPT (ALT), Serum	18.6	10-49 U/L	Modified IFCC
GAMMA GT, Serum	27.4	<38 U/L	Modified IFCC
ALKALINE PHOSPHATASE, Serum	86.3	46-116 U/L	Modified IFCC

*Sample processed at SUBURBAN DIAGNOSTICS (INDIA) PVT. LTD SDRL, Vidyavihar Lab
*** End Of Report ***

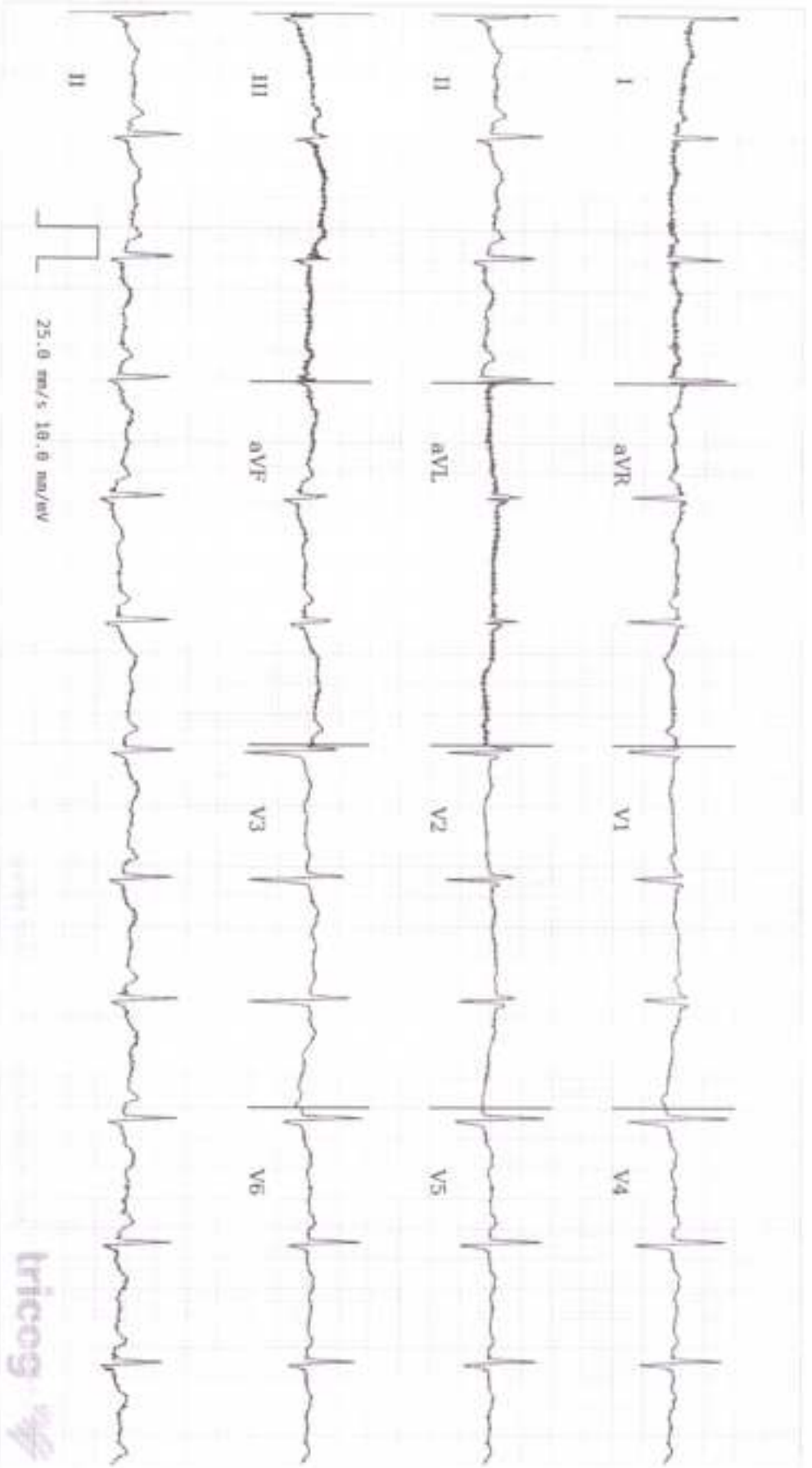


Dr. Vrushi Shroff

Dr.VRUSHALI SHROFF
M.D.(PATH)
Pathologist

Patient Name: SONAL PARESH TANK
Patient ID: 2405000524

Date and Time: 19th Feb 24 10:51 AM



Age: 53 years
Sex: Female
Heart Rate: 75bpm

BP: 150/90 mmHg
Weight: 78 kg
Height: 158 cm
Pulse: NA
SpO2: NA
Resp: NA
Others: NA

Measurements

QRSD: 86ms
QT: 408ms
QTcB: 455ms
PR: 158ms
P-R-T: 64° 26° 50°

ECG Within Normal Limits: Sinus Rhythm. Please correlate clinically.

REPORTED BY

DR. AKSHIL PARESHKAR
MD, MBBS, MRCP(C), DNB(Cardiology)
Cardiologist
2017000003



Date:- 19/2/24

CID: 2405000524

Name:- Sonal Tank

Sex/Age: 53/F

EYE CHECK UP

Chief complaints: No

Systemic Diseases: No

Past history: No

Unaided Vision:

Aided Vision: 6/6 6/6
 N/G N/G

Refraction:

	(Right Eye)				(Left Eye)			
	Sph	Cyl	Axis	Vn	Sph	Cyl	Axis	Vn
Distance								
Near								

Colour Vision: Normal / Abnormal

Remark:

SUBURBAN DIAGNOSTICS (INDIA) PVT. LTD.
Row House No. 3, Aangan,
Thakur Village, Kandivli (east).
Mumbai - 400101.
Tel : 61700000

Authenticity Check



Use a QR Code Scanner
Application To Scan the Code

CID : 2405000524
Name : Mrs SONAL PARESH TANK
Age / Sex : 53 Years/Female
Ref. Dr :
Reg. Location : Kandivali East Main Centre

Reg. Date : 19-Feb-2024
Reported : 19-Feb-2024 / 16:33

MAMMOGRAPHY

X RAY MAMMOGRAPHY:

Both mammograms have been performed with Cranio-Caudal and Medio-Lateral Oblique views

Mixed fibroglandular and fatty pattern is noted in both breasts partly limiting optimal evaluation (Type C).

No evidence of any speculated high density mass lesion / focal asymmetric density / retraction / clusters of microcalcification is seen.

No abnormal skin thickening is seen.

SONOMAMMOGRAPHY:

Both breasts reveal normal parenchymal echotexture.

No focal solid or cystic mass lesion is seen.

No ductal dilatation is seen.

Bilateral axillae appear normal.

Click here to view images <http://3.111.232.119/IRISViewer/NeoradViewer?AccessionNu=2024021908471985>

Authenticity Check



Use a QR Code Scanner
Application To Scan the Code

CID : 2405000524
Name : Mrs SONAL PARESH TANK
Age / Sex : 53 Years/Female
Ref. Dr :
Reg. Location : Kandivali East Main Centre

Reg. Date : 19-Feb-2024
Reported : 19-Feb-2024 / 16:33

IMPRESSION:

Normal Mammography and Sonomammography of both breasts.

ACR BIRADS Category- I (Negative).

Follow-up Mammography after 1 year is suggested. Please bring all the films for comparison.

ACR BIRADS CATEGORY

- I. Negative
- II. Benign.
- III. Probably benign.
- IV. Suspicious / Indeterminate.
- V. Highly Suggestive of malignancy.

-----End of Report-----


DR. SHRIKANT M. BODKE
D.M.R.E., M.B.B.S.
Reg. No. 2006/04/2376

Note : Investigations have their limitations. Solitary radiological investigations never confirm the final diagnosis. They only help in diagnosing the disease in correlation to clinical symptoms and other related tests. Mammography is known to have inter-observer variations. False negative rate of Mammography is approximately 10 %. Management of palpable abnormality must be based on clinical grounds. Further / Follow-up imaging may be needed in some case for confirmation of findings Please interpret accordingly. Patient has been explained in detail about the Mammography findings and limitations. In case of any typographical error in the report, patient is requested to immediately contact the center for rectification within 7 days post which the center will not be responsible for any rectification. If you detect any lump or any other change in the breast before your next screening, consult your doctor immediately.

Click here to view images <http://3.111.232.119/IRISViewer/NeoradViewer?AccessionNo=2024021908471985>



Use a QR Code Scanner
Application To Scan the Code

CID : 2405000524
Name : Mrs SONAL PARESH TANK
Age / Sex : 53 Years/Female
Ref. Dr :
Reg. Location : Kandivali East Main Centre
Reg. Date : 19-Feb-2024
Reported : 19-Feb-2024 / 9:23

USG WHOLE ABDOMEN

LIVER:

The liver is normal in size (12.8 cm), shape and smooth margins. It shows bright parenchymal echo pattern. The intra hepatic biliary and portal radical appear normal. No evidence of any intra hepatic cystic or solid lesion seen. The main portal vein measures 10 mm and CBD measures 2.5 mm appears normal.

GALL BLADDER: The gall bladder appears normal. No evidence of gall stones or mass lesions seen

PANCREAS: The pancreas appears normal. No evidence of solid or cystic mass lesion.

KIDNEYS:

Right kidney measures 9.8 x 4.6 cm. Left kidney measures 10.0 x 4.2 cm.
Both the kidneys are normal in size shape and echotexture.
No evidence of any calculus, hydronephrosis or mass lesion seen.

SPLEEN:

The spleen is normal in size (8.4 cm) and echotexture. No evidence of focal lesion is noted.
There is no evidence of any lymphadenopathy or ascites.

URINARY BLADDER: The urinary bladder is well distended and reveal no intraluminal abnormality.

UTERUS & OVARIES : are small and atrophic, post-menopausal status.

IMPRESSION:-

GRADE I FATTY LIVER.

-----End of Report-----

DR. Akash Chhari
MBBS, MD, Radio-Diagnosis Mumbai
MMC REG NO - 2011/08/2862

Click here to view images <http://3.111.232.119/iRISViewer/NeuroViewer?AccessionNo=2024021908471906>

PATIENT NAME : MRS SONAL PARESH TANK	SEX : FEMALE
REFERRED BY : Arcofemi Healthcare Limited	AGE : 53 YEARS
CID NO : 2405000524	DATE : 19/02/2024

2D & M-MODE ECHOCARDIOGRAM REPORT

MITRAL VALVE: has thin leaflets with normal subvalvar motion.
No mitral regurgitation.

AORTIC VALVE : has three thin leaflets with normal opening.
No aortic regurgitation.

LEFT VENTRICLE : is normal, has normal wall thickness, No regional wall motion abnormality.
Normal LV systolic contractions. EF - 60%.

LEFT ATRIUM: is normal.

RIGHT ATRIUM & RIGHT VENTRICLE: normal in size.

TRICUSPID VALVE & PULMONARY VALVES : normal.
NO TR / PH.

No pericardial effusion.

IMP :

Normal LV systolic function. EF-60%.
Normal other chambers and valves.
No regional wall motion abnormality/ scar.
No clot / vegetation / thrombus / pericardial effusion.

M- MODE :

LA (mm)	24
AORTA (mm)	20
LVDD (mm)	42
LVSD (mm)	30
IVSD (mm)	10
PWD (mm)	10
EF	60%
E/A	1.5



DR AKHIL PARULEKAR
DNB CARDIOLOGIST
REG. NO 2012082483



Use a QR Code Scanner
Application To Scan the Code

R
E
P
O
R
T

CID : 2405000524
Name : Mrs SONAL PARESH TANK
Age / Sex : 53 Years/Female
Ref. Dr :
Reg. Location : Kandivali East Main Centre
Reg. Date : 19-Feb-2024
Reported : 19-Feb-2024 / 13:22

X-RAY CHEST PA VIEW

Both lung fields are clear.
Both costo-phrenic angles are clear.
The cardiac size and shape are within normal limits.
The domes of diaphragm are normal in position and outlines.
The skeleton under review appears normal.

IMPRESSION:
NO SIGNIFICANT ABNORMALITY IS DETECTED.

-----End of Report-----

DR. Akash Chhari
MBBS, MD, Radio-Diagnosis Mumbai
MMC REG NO - 2011/08/2862

Click here to view images <http://3.111.232.119/iRISViewer/NeoradViewer?AccessionNo=2024021908472000>

Page no 1 of 1

Name : Sanal Tank Age / Gender - 53/F
Dr. : Date : 19/12/24

GYNAEC EXAMINATION REPORTS

PERSONAL HISTORY

CHIEF COMPLAINTS :

MARITAL STATUS :

MENSTRUAL HISTORY :

(i) MENARCHE :

(ii) PRESENT MENSTRUAL HISTORY :

(iii) PAST MENSTRUAL HISTORY :

(M)
married

@ age - 15 yr

| Postmenopausal

OBSTETRIC HISTORY :

PAST HISTORY :

PREVIOUS SURGERIES :

ALLERGIES :

FAMILY HISTORY :

DRUG HISTORY :

BOWEL HABITS :

BLADDER HABITS :

G2 P1 L1 A1

Retinal detachment 19 yrs ago

LE Cataract, CBCS

NO

Mother - DM

NO

(N)

Dr. Jagruti Dhale
MBBS
Consultant Physician
Reg.No.69548

Name :	Sonal Tank	Age / Gender	33/F
Dr. :		Date :	-


GYNAEC EXAMINATION REPORTS

GENERAL EXAMINATION

TEMPERATURE : (N)
PULSE : 72bmt
BP : 105/90
RS :
CVs : /N
Breasts :
Per Abdomen : - NAD Uses Scar Healthy
Per vaginal : PLS - G Healthy

RECOMMENDATIONS

ADVISE :


Dr. Jagruti Dhale
MBBS
Consultant Physician
Reg.No.69548