

Patient Name : Mrs.SWETHA S	Collected : 09/Nov/2024 07:40AM
Age/Gender : 36 Y 6 M 18 D/F	Received : 09/Nov/2024 12:01PM
UHID/MR No : CIND.0000173110	Reported : 09/Nov/2024 03:58PM
Visit ID : CINDOPV244781	Status : Final Report
Ref Doctor : Self	Sponsor Name : ARCOFEMI HEALTHCARE LIMITED
Emp/Auth/TPA ID : 22E37159	

DEPARTMENT OF HAEMATOLOGY

ARCOFEMI - MEDIWHEEL - FULL BODY HEALTH ANNUAL PLUS CHECK - FEMALE - 2D ECHO - PAN INDIA - FY2324

Test Name	Result	Unit	Bio. Ref. Interval	Method
HEMOGRAM , WHOLE BLOOD EDTA				
HAEMOGLOBIN	12.9	g/dL	12-15	Spectrophotometer
PCV	38.10	%	36-46	Electronic pulse & Calculation
RBC COUNT	4.2	Million/cu.mm	3.8-4.8	Electrical Impedance
MCV	90.8	fL	83-101	Calculated
MCH	30.7	pg	27-32	Calculated
MCHC	33.8	g/dL	31.5-34.5	Calculated
R.D.W	12.4	%	11.6-14	Calculated
TOTAL LEUCOCYTE COUNT (TLC)	4,780	cells/cu.mm	4000-10000	Electrical Impedance
DIFFERENTIAL LEUCOCYTIC COUNT (DLC)				
NEUTROPHILS	46.3	%	40-80	Electrical Impedance
LYMPHOCYTES	40.2	%	20-40	Electrical Impedance
EOSINOPHILS	3.5	%	1-6	Electrical Impedance
MONOCYTES	9.3	%	2-10	Electrical Impedance
BASOPHILS	0.7	%	<1-2	Electrical Impedance
ABSOLUTE LEUCOCYTE COUNT				
NEUTROPHILS	2213.14	Cells/cu.mm	2000-7000	Calculated
LYMPHOCYTES	1921.56	Cells/cu.mm	1000-3000	Calculated
EOSINOPHILS	167.3	Cells/cu.mm	20-500	Calculated
MONOCYTES	444.54	Cells/cu.mm	200-1000	Calculated
BASOPHILS	33.46	Cells/cu.mm	0-100	Calculated
Neutrophil lymphocyte ratio (NLR)	1.15		0.78- 3.53	Calculated
PLATELET COUNT	>150000	cells/cu.mm	150000-410000	Electrical impedance
ERYTHROCYTE SEDIMENTATION RATE (ESR)	4	mm at the end of 1 hour	0-20	Modified Westegren method
PERIPHERAL SMEAR				

RBCs: are normocytic normochromic

WBCs: are normal in total number with normal distribution and morphology.

Dr. Vidya Aniket Gore
M.B.B.S,M.D(Pathology)
Consultant Pathologist

Dr Priya Murthy
M.B.B.S,M.D(Pathology)
Consultant Pathologist



Patient Name : Mrs.SWETHA S	Collected : 09/Nov/2024 07:40AM
Age/Gender : 36 Y 6 M 18 D/F	Received : 09/Nov/2024 12:01PM
UHID/MR No : CIND.0000173110	Reported : 09/Nov/2024 03:58PM
Visit ID : CINDOPV244781	Status : Final Report
Ref Doctor : Self	Sponsor Name : ARCOFEMI HEALTHCARE LIMITED
Emp/Auth/TPA ID : 22E37159	

DEPARTMENT OF HAEMATOLOGY

ARCOFEMI - MEDIWHEEL - FULL BODY HEALTH ANNUAL PLUS CHECK - FEMALE - 2D ECHO - PAN INDIA - FY2324


PLATELETS: appear adequate on smear. Many tiny platelets aggregates seen.

HEMOPARASITES: negative

IMPRESSION: NORMOCYTIC NORMOCHROMIC BLOOD PICTURE



Dr. Vidya Aniket Gore
M.B.B.S,M.D(Pathology)
Consultant Pathologist



Dr Priya Murthy
M.B.B.S,M.D(Pathology)
Consultant Pathologist



Patient Name : Mrs.SWETHA S	Collected : 09/Nov/2024 07:40AM
Age/Gender : 36 Y 6 M 18 D/F	Received : 09/Nov/2024 11:31AM
UHID/MR No : CIND.0000173110	Reported : 09/Nov/2024 01:05PM
Visit ID : CINDOPV244781	Status : Final Report
Ref Doctor : Self	Sponsor Name : ARCOFEMI HEALTHCARE LIMITED
Emp/Auth/TPA ID : 22E37159	

DEPARTMENT OF IMMUNOLOGY

ARCOFEMI - MEDIWHEEL - FULL BODY HEALTH ANNUAL PLUS CHECK - FEMALE - 2D ECHO - PAN INDIA - FY2324

Test Name	Result	Unit	Bio. Ref. Interval	Method
THYROID PROFILE TOTAL (T3, T4, TSH) , SERUM				
TRI-iodothyronine (T3, TOTAL)	1.3	ng/mL	0.7-2.04	CLIA
THYROXINE (T4, TOTAL)	8.1	µg/dL	5.48-14.28	CLIA
THYROID STIMULATING HORMONE (TSH)	11.080	µIU/mL	0.34-5.60	CLIA

Comment:

For pregnant females	Bio Ref Range for TSH in uIU/ml (As per American Thyroid Association)
First trimester	0.1 - 2.5
Second trimester	0.2 – 3.0
Third trimester	0.3 – 3.0

- TSH is a glycoprotein hormone secreted by the anterior pituitary. TSH activates production of T3 (Triiodothyronine) and its prohormone T4 (Thyroxine). Increased blood level of T3 and T4 inhibit production of TSH.
- TSH is elevated in primary hypothyroidism and will be low in primary hyperthyroidism. Elevated or low TSH in the context of normal free thyroxine is often referred to as sub-clinical hypo- or hyperthyroidism respectively.
- Both T4 & T3 provides limited clinical information as both are highly bound to proteins in circulation and reflects mostly inactive hormone. Only a very small fraction of circulating hormone is free and biologically active.
- Significant variations in TSH can occur with circadian rhythm, hormonal status, stress, sleep deprivation, medication & circulating antibodies.

TSH	T3	T4	FT4	Conditions
High	Low	Low	Low	Primary Hypothyroidism, Post Thyroidectomy, Chronic Autoimmune Thyroiditis
High	N	N	N	Subclinical Hypothyroidism, Autoimmune Thyroiditis, Insufficient Hormone Replacement Therapy.
N/Low	Low	Low	Low	Secondary and Tertiary Hypothyroidism
Low	High	High	High	Primary Hyperthyroidism, Goitre, Thyroiditis, Drug effects, Early Pregnancy
Low	N	N	N	Subclinical Hyperthyroidism
Low	Low	Low	Low	Central Hypothyroidism, Treatment with Hyperthyroidism
Low	N	High	High	Thyroiditis, Interfering Antibodies
N/Low	High	N	N	T3 Thyrotoxicosis, Non thyroidal causes

Dr.Govinda Raju N L
 MSc,PhD(Biochemistry)
 Consultant Biochemistry

Dr Priya Murthy
 M.B.B.S,M.D(Pathology)
 Consultant Pathologist



SIN No:IRA241100689

Apollo Health and Lifestyle Limited, Apollo Health & Lifestyle Ltd, RRL BANGALORE Laboratory

Regd. Office: 10/22/20, Anand Nagar, Bangalore-560025, Karnataka, India. Phone: 080-4561 7777, Fax: 080-4561 7700

www.apolloclinics.com


1860 500 7788
www.apolloclinic.com


Patient Name : Mrs.SWETHA S	Collected : 09/Nov/2024 07:40AM
Age/Gender : 36 Y 6 M 18 D/F	Received : 09/Nov/2024 11:31AM
UHID/MR No : CIND.0000173110	Reported : 09/Nov/2024 01:05PM
Visit ID : CINDOPV244781	Status : Final Report
Ref Doctor : Self	Sponsor Name : ARCOFEMI HEALTHCARE LIMITED
Emp/Auth/TPA ID : 22E37159	

DEPARTMENT OF IMMUNOLOGY

ARCOFEMI - MEDIWHEEL - FULL BODY HEALTH ANNUAL PLUS CHECK - FEMALE - 2D ECHO - PAN INDIA - FY2324

High	High	High	High	Pituitary Adenoma; TSHoma/Thyrotropinoma
------	------	------	------	--


Dr.Govinda Raju N L
 MSc,PhD(Biochemistry)
 Consultant Biochemistry


Dr Priya Murthy
 M.B.B.S,M.D(Pathology)
 Consultant Pathologist



SIN No:IRA241100689

This test has been performed at Apollo Health & Lifestyle Ltd, RRL BANGALORE Laboratory.

APOLLO HEALTH AND LIFESTYLE LIMITED - RRL BANGALORE
 Apollo Health and Lifestyle Limited
 Regd. Office: 10/22/20, Anand Nagar, 4th Cross, 4th Stage, 4th Cross, Anand Nagar, Hyderabad, Telangana - 500016
 www.apolloclinic.com | Email ID: rrl@apolloclinic.com, Ph No: 040-6664 7777, Fax No: 040-6664 7766

APOLLO
 Apollo Health and Lifestyle Limited
 Regd. Office: 10/22/20, Anand Nagar, 4th Cross, Anand Nagar, Hyderabad, Telangana - 500016
 www.apolloclinic.com | Email ID: rrl@apolloclinic.com, Ph No: 040-6664 7777, Fax No: 040-6664 7766

Patient Name : Mrs.SWETHA S	Collected : 09/Nov/2024 07:40AM
Age/Gender : 36 Y 6 M 18 D/F	Received : 09/Nov/2024 08:36PM
UHID/MR No : CIND.0000173110	Reported : 09/Nov/2024 09:25PM
Visit ID : CINDOPV244781	Status : Final Report
Ref Doctor : Self	Sponsor Name : ARCOFEMI HEALTHCARE LIMITED
Emp/Auth/TPA ID : 22E37159	

DEPARTMENT OF CLINICAL PATHOLOGY

ARCOFEMI - MEDIWHEEL - FULL BODY HEALTH ANNUAL PLUS CHECK - FEMALE - 2D ECHO - PAN INDIA - FY2324

Test Name	Result	Unit	Bio. Ref. Interval	Method
COMPLETE URINE EXAMINATION (CUE) , URINE				
PHYSICAL EXAMINATION				
COLOUR	PALE YELLOW		PALE YELLOW	Scattering of light
TRANSPARENCY	Clear		CLEAR	Scattering of light
pH	6.5		5-7.5	Bromothymol Blue
SP. GRAVITY	1.002		1.002-1.030	Bromothymol Blue
BIOCHEMICAL EXAMINATION				
URINE PROTEIN	NEGATIVE		NEGATIVE	PROTEIN ERROR OF INDICATOR
GLUCOSE	NORMAL		NEGATIVE	GOD-POD
URINE BILIRUBIN	NEGATIVE		NEGATIVE	Diazonium Salt
URINE KETONES (RANDOM)	NEGATIVE		NEGATIVE	Sodium nitro prusside
UROBILINOGEN	NORMAL		NORMAL (0.1-1.8mg/dl)	Diazonium salt
NITRITE	NEGATIVE		NEGATIVE	Sulfanilic acid
LEUCOCYTE ESTERASE	NEGATIVE		NEGATIVE	Diazonium salt
CENTRIFUGED SEDIMENT WET MOUNT AND MICROSCOPY				
PUS CELLS	0	/hpf	0-5	Automated Image based microscopy
EPITHELIAL CELLS	0	/hpf	< 10	Automated Image based microscopy
RBC	0	/hpf	0-2	Automated Image based microscopy
CASTS	NEGATIVE	/lpf	0-2 Hyaline Cast	Automated Image based microscopy
CRYSTALS	NEGATIVE	/hpf	Occasional-Few	Automated Image based microscopy

Comment:

All urine samples are checked for adequacy and suitability before examination. All abnormal chemical examination are rechecked and verified by manual methods. Microscopy findings are reported as an average of 10 high power fields.

Dr. Vidya Aniket Gore
M.B.B.S,M.D(Pathology)
Consultant Pathologist

Dr Priya Murthy
M.B.B.S,M.D(Pathology)
Consultant Pathologist



Patient Name : Mrs.SWETHA S	Collected : 09/Nov/2024 02:14PM
Age/Gender : 36 Y 6 M 18 D/F	Received : 10/Nov/2024 02:28PM
UHID/MR No : CIND.0000173110	Reported : 12/Nov/2024 10:02AM
Visit ID : CINDOPV244781	Status : Final Report
Ref Doctor : Self	Sponsor Name : ARCOFEMI HEALTHCARE LIMITED
Emp/Auth/TPA ID : 22E37159	

DEPARTMENT OF CYTOLOGY

ARCOFEMI - MEDIWHEEL - FULL BODY HEALTH ANNUAL PLUS CHECK - FEMALE - 2D ECHO - PAN INDIA - FY2324

LBC PAP SMEAR , CERVICAL BRUSH SAMPLE

	CYTOLOGY NO.	24527/24
I	SPECIMEN	
a	SPECIMEN ADEQUACY	ADEQUATE
b	SPECIMEN TYPE	LIQUID-BASED PREPARATION (LBC)
	SPECIMEN NATURE/SOURCE	CERVICAL SMEAR
c	ENDOCERVICAL-TRANSFORMATION ZONE	ABSENT
d	COMMENTS	SATISFACTORY FOR EVALUATION
II	MICROSCOPY	Superficial and intermediate squamous epithelial cells with benign morphology. Inflammatory cells, predominantly neutrophils. Negative for intraepithelial lesion/malignancy.
III	RESULT	
a	EPITHELIAL CELL	
	SQUAMOUS CELL ABNORMALITIES	NOT SEEN
	GLANDULAR CELL ABNORMALITIES	NOT SEEN
b	ORGANISM	NIL
IV	INTERPRETATION	NEGATIVE FOR INTRAEPITHELIAL LESION OR MALIGNANCY

Pap Test is a screening test for cervical cancer with inherent false negative results. Regular screening and follow-up is recommended (Bethesda-TBS-2014) revised

***** End Of Report *****

Result/s to Follow:
PERIPHERAL SMEAR

Dr. Reshma Stanly
M.B.B.S,DNB(Pathology)
Consultant Pathologist



SIN No:IRA241101142

This test has been performed at Apollo Health & Lifestyle Ltd, Global Reference Laboratory,Hyderabad

Regd. Office: 102/202, A Block, Rajaganga 4th Cross, 4th Floor, Rajanganga, Hyderabad, Telangana - 500016
www.apolloclinics.com | Email ID: enquiry@apolloclinics.com, Ph: No: 043-6664 7777, Fax No: 4664 7766

APOLLOCLINICS NETWORK

Telangana: Hyderabad | AS Rao Nagar | Charla Nagar | Korangal | Malakpet | Miryala | Nizampet | Nizampet | Uppal | Andhra Pradesh: Vijaya Vittala | Karnataka: Bangalore | Channarayana | Solapur | Electronics City | Trarav Town | HSR Layout | India: Bangalore | Mysore | Chennai | Coimbatore | Kozhikode | Kerala: Thiruvananthapuram | Madhya Pradesh: Indore | Maharashtra: Pune | Odisha: Bhubaneswar | West Bengal: Kolkata | Gujarat: Ahmedabad | Karnataka: Bangalore | Andhra Pradesh: Hyderabad | Telangana: Hyderabad



Patient Name	: Mrs. Swetha S	Age	: 36Yrs 6Mths 22Days
UHID	: CIND.0000173110	OP Visit No.	: CINDOPV244781
Printed On	: 12-11-2024 06:35 AM	Advised/Pres Doctor	: --
Department	: Cardiology	Qualification	: --
Referred By	: Self	Registration No.	: --
Employer Id	: 22E37159		

DEPARTMENT OF CARDIOLOGY

ECG

Observation :-

1. Normal Sinus Rhythm.
2. Heart rate is Normal
3. No pathological Q wave or ST-T changes seen.
4. Normal P,QRS,T waves and axis.
5. No evidence of chamber, hypertrophy or enlargement seen.

Impression:-

NORMAL RESTING ECG.

NOTE:-KINDLY TAKE A PHOTOCOPY OF THE GRAPH FOR FUTURE REFERENCE IF NEEDED

---End Of The Report---



Dr.M SUDHAKAR RAO
MBBS, MD, DM (Cardio)
0000018
Cardiology

Patient Name	: Mrs. Swetha S	Age	: 36Yrs 6Mths 21Days
UHID	: CIND.0000173110	OP Visit No.	: CINDOPV244781
Printed On	: 11-11-2024 12:20 PM	Advised/Pres Doctor	: --
Department	: Cardiology	Qualification	: --
Referred By	: Self	Registration No.	: --
Employer Id	: 22E37159		

DEPARTMENT OF CARDIOLOGY

M mode and doppler measurements:

CM CM M/sec

AO: 2.7 IVS(D): 0.6 MV: E Vel: 0.8 A Vel : 0.7

LA: 2.8 LVIDD(D): 3.6 AV Peak: 1.2

 LVPW(D): 0.8 PV peak: 0.7

 IVS(S): 0.7

 LVID(S): 2.3

 LVPW(S): 1.0

 LVEF: 60%

Descriptive findings:

Left Ventricle Normal
Right Ventricle: Normal
Left Atrium: Normal
Right Atrium: Normal
Mitral Valve: Normal
Aortic Valve: Normal
Tricuspid Valve: Normal
IAS: Normal

IVS:	Normal
Pericardium:	Normal
IVC:	Normal
Others	---

IMPRESSION :

Normal cardiac chamber and valves
No Regional wall motion abnormality
Normal PA pressure
No clot/vegetation/pericardial effusion
Normal LV systolic function - LVEF= 60%


DR JAGADEESH H V MD,DM
CONSULTANT CARDIOLOGIST

---End Of The Report---



Dr.JAGADEESH H V

MBBS, MD, DM
86848
Cardiology



Patient Name	: Mrs. Swetha S	Age	: 36Yrs 6Mths 19Days
UHID	: CIND.0000173110	OP Visit No.	: CINDOPV244781
Printed On	: 09-11-2024 12:23 PM	Advised/Pres Doctor	: --
Department	: Radiology	Qualification	: --
Referred By	: Self	Registration No.	: --
Employer Id	: 22E37159		

DEPARTMENT OF RADIOLOGY

X-RAY CHEST PA VIEW

Both lung fields and hila are normal .

No obvious active pleuro-parenchymal lesion seen .

Both costophrenic and cardiophrenic angles are clear .

Both diaphragms are normal in position and contour .

Thoracic wall and soft tissues appear normal.

CONCLUSION :

No obvious abnormality seen

For clinical correlation.

---End Of The Report---



Dr.DHANALAKSHMI B
MBBS, DMRD
29543
Radiology

09.11.2024

Mrs. Smita

36y / F.

Height :	Weight :	BMI :	Waist Circum :
Temp :	Pulse :	Resp :	B.P :

General Examination / Allergies
History

Clinical Diagnosis & Management Plan

Acropur - A He

Ears: NTD

Nose: NTD

Throat: NTD



Follow up date:

Dr. RAVINDRA K. DEY
M.B.B.S., D.L.O. **Doctor Signature**

E.N.T. SURGEON
KWC REG. No. 18554

Apollo Clinic

CONSENT FORM

Patient Name: Sweetha S Age: 36

UHID Number: Company Name:

I Mr/Mrs/Ms Sweetha S Employee of Bank of Baroda

(Company) Want to inform you that I am ~~not~~ interested in getting the consultation on

Tests done which is a part of my routine health check package.

And I claim the above statement in my full consciousness.

18/11/2024
(Tentative Date)

Patient Signature: [Signature] Date: 09/11/2024

Apollo Health and Lifestyle Limited

(CIN - U85110TG2000PLC115819)

Regd. Office: 1-10-60/62, Ashoka Raghupathi Chambers, 5th Floor, Begumpet, Hyderabad, Telangana - 500 016.

Ph No: 040-4904 7777, Fax No: 4904 7744 | Email ID: enquiry@apollohl.com | www.apollohl.com

APOLLO CLINICS NETWORK KARNATAKA

Bangalore (Basavanagudi | Bellandur | Electronic City | Fraser Town | HSR Layout | Indira Nagar | JP Nagar | Kundalahalli | Koramangala | Sarjapur Road) Mysore (VV Mohalla)

TO BOOK AN APPOINTMENT

1860 500 7788

Date : 09/11/2024 Department : Obstetrics & Gynaecology
 Patient Name : Mrs. Swetha S Doctor : Dr. V S GANGARANI
 UHID : CIND.0000173110 Registration No. : 63332
 Age / Gender : 36Yrs 6Mths 18Days/
 Female Qualification : MBBS, DGO, DNB (OBG)
 Consultation Timing : 7:38 AM

Height : 164	Weight : 58.1kg	BMI : 21.6	Waist Circum : 80cm
Temp : 98°F	Pulse : 78bpm	Resp : 18rpm	B.P. : 116/77mmHg

General Examination / Allergies
History

Nov 9/2024

Clinical Diagnosis & Management Plan

36w R/cycles, D, L, L OB Sym
 LSCS Comp 26th Oct.
 LBC pap test P E nil
 done complaints
 Adv PA -
 H1v vaccine. soft mast
 Niramai P/S -
 Cx healthy ✓
 vaginls + +
 Pbs. Shie kit - 1 pack. Sri
 Hy wash kit ✓ - ✓
 100 H2O

Follow up date:

Doctor Signature

OPHTHAL PRESCRIPTION

PATIENT NAME : Swetha S

DATE : 09.11.24

UHID NO : 173100

AGE : 36y

OPTOMETRIST NAME : Karthi

GENDER : female

This is to certify that I have examined

years and findings of his/her eye examination are as follows,

	RIGHT EYE				LEFT EYE			
	SPH	CYL	AXIS	BCVA	SPH	CYL	AXIS	BCVA
Distance	Plures			6/6	-0.50			6/6
Add								

PD - RE: 32 - LE: 32 -

Colour Vision: Normal

Remarks: for computer glasses only

Apollo clinic Indiranagar

Mrs swetha
ID: 173110

22.04.1988
36 Years

Female

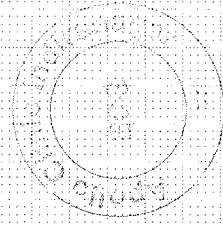
QRS : 80 ms
QT / QTcBaz : 374 / 489 ms
PR : 148 ms
P : 94 ms
RR / PP : 580 / 582 ms
P / QRS / T : 66 / 86 / 64 degrees

09.11.2024 8:30:19
APOLLO CLINIC
INDIRANAGAR
BANGALORE

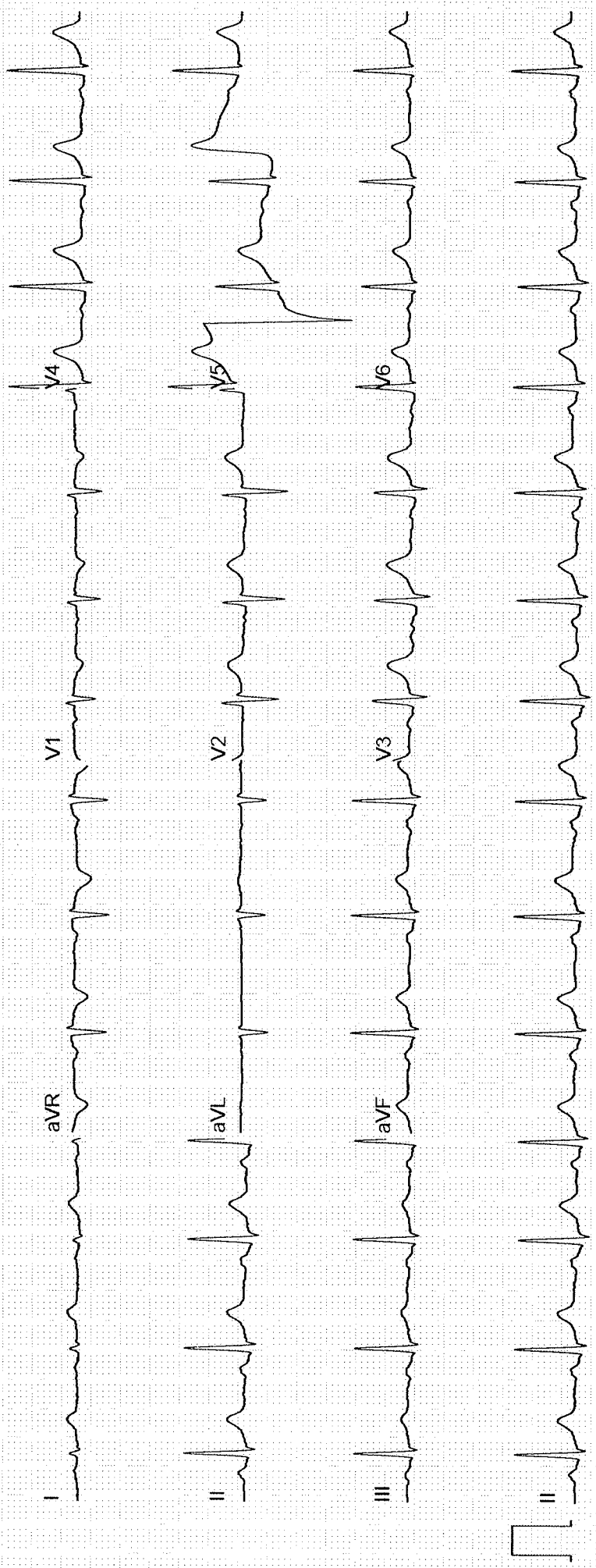
Location:
Room:
Order Number:
Indication:
Medication 1:
Medication 2:
Medication 3:

103 bpm
-- / -- mmHg

Technician:
Ordering Ph:
Referring Ph:
Attending Ph:



[Handwritten signature]





NAME: Mrs. Swetha S	AGE/SEX: 36Y/F	OP NUMBER: 173110
Ref By : SELF	DATE: 09-11-2024	

M mode and doppler measurements:

CM	CM	M/sec	
AO: 2.7	IVS(D): 0.6	MV: E Vel: 0.8	A Vel : 0.7
LA: 2.8	LVIDD(D): 3.6	AV Peak: 1.2	
	LVPW(D): 0.8	PV peak: 0.7	
	IVS(S): 0.7		
	LVID(S): 2.3		
	LVPW(S): 1.0		
	LVEF: 60%		

Descriptive findings:

Left Ventricle	Normal
Right Ventricle:	Normal
Left Atrium:	Normal
Right Atrium:	Normal
Mitral Valve:	Normal
Aortic Valve:	Normal
Tricuspid Valve:	Normal
IAS:	Normal
IVS:	Normal
Pericardium:	Normal
IVC:	Normal
Others	---

011-41195959

Dear **MS. S SWETHA**,

We are pleased to confirm your health checkup booking request with the following details.

Hospital Package Name : Mediwheel Full Body Health Checkup Female Below 40

Name of Diagnostic/Hospital : Apollo Clinic - Indiranagar

Address of Diagnostic/Hospital : 2012,1st floor, Above vision express, Next to Starbucks, 100 feet road, HAL 2nd stage, Indiranagar - 560038

City : Bangalore

State : Karnataka

Pincode : 560038

Appointment Date : 09-11-2024

Confirmation Status : Booking Confirmed

Booking Status : Booking Confirmed

Member Information		
Booked Member Name	Age	Gender
MS. S SWETHA	36 year	Female

Note - Please note to not pay any amount at the center.

Instructions to undergo Health Check:

- Please ensure you are on complete fasting for 10-To-12-Hours prior to check.
- During fasting time do not take any kind of medication, alcohol, cigarettes, tobacco or any other liquids (except Water) in the morning.
- Bring urine sample in a container if possible (containers are available at the Health Check centre).
- Please bring all your medical prescriptions and previous health medical records with you.
- Kindly inform the health check reception in case if you have a history of diabetes and cardiac problems.

For Women:

- Pregnant Women or those suspecting are advised not to undergo any X-Ray test.
- It is advisable not to undergo any Health Check during menstrual cycle.



बैंक ऑफ़ बड़ौदा
Bank of Baroda


नाम
Name


श्वेता एस
Swetha S

E.C No.

160387




जारीकर्ता प्राधिकारी
Issuing Authority


धारक के हस्ताक्षर
Signature of Holder