

DR. NETRAVALKAR'S ASHWINI PATHOLOGY LABORATORY

(For all investigations in Histopathology, Cytopathology, Haematology, Clinical Pathology, Microbiology & Hormonal Chemistry)

Consultant Pathologist **Dr. Prasad Netravalkar** MBBS MD (Path) BOM

(HOME COLLECTION FACILITY AVAILABLE)

Panaji : 1st, Floor, Rizvi Sadan, Above Saroj Emporium, Near Inox Theatre, Opp. Municipal Market, Panaji.
Ph.: 2229142, 8407912840, 8390242524

E-mail : ashwinilabpanaji@gmail.com, drprasadnetravalkar@gmail.com

Mapusa : F8, Ramchandra Chambers, 1st Floor, Mapusa Clinic Road, Mapusa - Bardez, Goa Ph 2252320

Pt.No. : 39 031024

Pt.Name : - Simran Sharma

Age : 28 Yrs. Sex : F

Ref. By : -

Date : 28/09/2024

Normal Range

COMPLETE HEMOGRAM

Haemoglobin	: 11.1	g/dl	11.5 - 16.5 g/dl
W.B.C Count	: 9500	cells/ cu-mm	4000 - 11000 cells/ cu-mm
R.B.C Count	: 4.14	millions / cu-mm	3.8 - 4.5 millions / cu-mm
MCV	: 81.3	fl	80 - 99 fl
MCH	: 26.8	Pg	27 - 33 Pg
MCHC	: 33.0	%	32 - 37 %
PCV	: 33.7	%	37 - 47 %
Platelet Count	: 2.21	lakhs /cu mm	1.5 - 4.5 lakhs /cu mm
E.S.R (Westergren)	: 12	mm/hr	0 - 20 mm/hr

DIFFERENTIAL COUNT

Stab Cells	: 05	%	1-5 %
Neutrophils	: 63	%	40- 60 %
Lymphocytes	: 03	%	20 - 45 %
Eosinophils	: 03	%	1 - 6 %
Monocytes	: 05	%	0 - 10 %
Basophils	: 00	%	0 - 1 %
Abnormal Cells	: Nil		

SMEAR EXAMINATION

kBC Morphology	: Normocytic , Normochromic
W.B.C Morphology	: Within Normal Limits
Platelets on Smear	: Adequate
Parasites	: Absent
Blood Group	: 'A' Rh Positive



Pathologist



Dr. Prasad Netravalkar
MBBS, MD (Bom)
GMC Reg. No. 1294

We Care

All Diagnostic facilities under one roof in Panaji centre - Lab, ultrasound, X ray, ECG, TMT, ECHO

DR. NETRAVALKAR'S ASHWINI PATHOLOGY LABORATORY

(For all investigations in Histopathology, Cytopathology, Haematology, Clinical Pathology, Microbiology & Hormonal Chemistry)
Consultant Pathologist : **Dr. Prasad Netravalkar** MBBS, MD. (Path) BOM.

(HOME COLLECTION FACILITY AVAILABLE)

Panaji : 1st, Floor, Rizvi Sadan, Above Saroj Emporium, Near Inox Theatre, Opp. Municipal Market, Panaji.
Ph.: 2229142, 8407912840, 8390242524

E-mail : ashwinilabpanaji@gmail.com, drprasadnetravalkar@gmail.com

Mapusa : F8, Ramchandra Chambers, 1st Floor, Mapusa Clinic Road, Mapusa - Bardez, Goa. Ph.: 2252320

Pt.No. : 39 031024
Pt.Name : - Simran Sharma
Ref. By : -

Age : 28 Yrs. Sex : F
Date : 28/09/2024

Normal Range

Fasting Urine Glucose	: Absent	
2 Hrs. Urine Glucose	: Absent	
Fasting Blood Sugar	: 94.0 mg/dl	70-110 mg/dl
2 Hrs. Blood Sugar	: 93.0 mg/dl	110-140 mg/dl

GLYCOSYLATED HAEMOGLOBIN IN BLOOD (HPLC METHOD)

HbA1C : 4.50 %
Mean Blood Glucose : 82 mg %

INTERPRETATION:

HbA1c %

NORMAL

Below 6.5 %

GOOD DIABETIC CONTROL

6.5 % - 7.5 %

FAIR CONTROL

7.5 % - 8.0 %

UNSATISFACTORY CONTROL

8.0 % - 10.0 %

POOR CONTROL

Above 10.0 %



Prasad Netravalkar
Pathologist

Dr. Prasad Netravalkar
MBBS, MD (Bom)
GMC Reg. No. 1294

We Care

All Diagnostic facilities under one roof in Panaji centre - Lab, ultrasound, X ray, ECG, TMT, ECHO

DR. NETRAVALKAR'S ASHWINI PATHOLOGY LABORATORY

(For all investigations in Histopathology, Cytopathology, Haematology, Clinical Pathology, Microbiology & Hormonal Chemistry)

Consultant Pathologist : **Dr. Prasad Netravalkar** MBBS, MD. (Path) BOM.

(HOME COLLECTION FACILITY AVAILABLE)

Panaji : 1st, Floor, Rizvi Sadan, Above Saroj Emporium, Near Inox Theatre, Opp. Municipal Market, Panaji.
Ph.: 2229142, 8407912840, 8390242524

E-mail : ashwinilabpanaji@gmail.com, drprasadnetravalkar@gmail.com

Mapusa : FS, Ramchandra Chambers, 1st Floor, Mapusa Clinic Road, Mapusa - Bardez, Goa. Ph.: 2252320

Pt.No. : 39 031024
Pt.Name : - Simran Sharma
Ref. By : -

Age : 28 Yrs. Sex : F
Date : 28/09/2024

Normal Range

LIPID PROFILE

Total Cholesterol	: 155.0 mg/dl	130 - 220 mg/dl
S. Triglycerides	: 122.0 mg/dl	35 - 170 mg/dl
HDL Cholesterol	: 48.0 mg/dl	> 45 mg/dl
LDL Cholesterol	: 83 mg/dl	< 130 mg/dl
VLDL Cholesterol	: 24 mg/dl	Upto 35 mg/dl
TC/HDLC Ratio	: 3.2	< 4.5
LDLC/HDLC Ratio	: 1.7	2.5 - 3.5



Pathologist



Dr. Prasad Netravalkar
MBBS, MD (Bom)
GMC Reg. No. 1294

We Care

All Diagnostic facilities under one roof in Panaji centre - Lab, ultrasound, X ray, ECG, TMT, ECHO

DR. NETRAVALKAR'S ASHWINI PATHOLOGY LABORATORY

(For all investigations in Histopathology, Cytopathology, Haematology, Clinical Pathology, Microbiology & Hormonal Chemistry)

Consultant Pathologist : **Dr. Prasad Netravalkar** MBBS, MD. (Path) BOM.

(HOME COLLECTION FACILITY AVAILABLE)

Panaji : 1st Floor, Rizvi Sadan, Above Saroj Emporium, Near Inox Theatre, Opp. Municipal Market, Panaji.
Ph.: 2229142, 8407912840, 8390242524

E-mail : ashwinilabpanaji@gmail.com, drprasadnetravalkar@gmail.com

Mapusa : F8, Ramchandra Chambers, 1st Floor, Mapusa Clinic Road, Mapusa - Bardez, Goa. Ph.: 2252320

Pt.No. : 39 031024

Pt.Name : - Simran Sharma

Ref. By : -


Age : 28 Yrs. Sex : F

Date : 28/09/2024

Normal Range

LIVER FUNCTION TEST

S. Bilirubin (Total)	: 0.65	mg/dl	0 - 1 mg/dl
S. Bilirubin (Direct)	: 0.25	mg/dl	0 - 0.25 mg/dl
S. Bilirubin (Indirect)	: 0.4	mg/dl	0 - 0.75 mg/dl
S.G.O.T	: 20.0	U/L	0 - 42 U/L
S.G.P.T	: 18.0	U/L	0 - 42 U/L
S. Alkaline Phosphatase	: 90.0	IU/L	15 - 112 IU/L
GGTP	: 16.0	U/L	9-37 U/L
Total Proteins	: 6.50	g/dl	6.0 - 10.0 g/dl
S. Albumin	: 4.0	gm%	3.2 - 5.5 gm%
S. Globulin	: 2.5	g/dl	2.3 - 3.5 g/dl
A/G Ratio	: 1.6 : 1		



Pathologist

Dr. Prasad Netravalkar
MBBS, MD (Bom)
GMC Reg. No. 1294

We Care

All Diagnostic facilities under one roof in Panaji centre - Lab, ultrasound, X ray, ECG, TMT, ECHO

DR. NETRAVALKAR'S ASHWINI PATHOLOGY LABORATORY

(For all investigations in Histopathology, Cytopathology, Haematology, Clinical Pathology, Microbiology & Hormonal Chemistry)
Consultant Pathologist : **Dr. Prasad Netravalkar** MBBS, MD. (Path) BOM.

(HOME COLLECTION FACILITY AVAILABLE)

Panaji : 1st, Floor, Rizvi Sadan, Above Saroj Emporium, Near Inox Theatre, Opp. Municipal Market, Panaji.
Ph.: 2229142, 8407912840, 8390242524

E-mail : ashwinilabpanaji@gmail.com, drprasadnetravalkar@gmail.com

Mapusa : F8, Ramchandra Chambers, 1st Floor, Mapusa Clinic Road, Mapusa - Bardez, Goa. Ph.: 2252320

Pt.No. : 39 031024
Pt.Name : - Simran Sharma
Ref. By : -

Age : 28 Yrs. Sex : F

Date : 28/09/2024

Normal Range

KIDNEY FUNCTION TESTS

Blood Urea	: 20.0 mg/dl	15 - 40 mg/dl
S. Creatinine	: 0.78 mg/dl	0.5 - 1.2 mg/dl
S. Uric Acid.	: 4.90 mg/dl	1.5 - 6.0 mg/dl



Pathologist

Dr. Prasad Netravalkar
MBBS, MD (Bom)
GMC Reg. No. 1294

We Care

All Diagnostic facilities under one roof in Panaji centre - Lab, ultrasound, X ray, ECG, TMT, ECHO

DR. NETRAVALKAR'S ASHWINI PATHOLOGY LABORATORY

(Special Investigations in Histopathology, Cytopathology, Haematology, Clinical Pathology, Microbiology & Hormonal Chemistry)
Consultant Pathologist **Dr. Prasad Netravalkar** MBBS, MD (Path), BOM

(HOME COLLECTION FACILITY AVAILABLE)

Panaji : 1st. Floor, Rivvi Sadan, Above Saroj Emporium, Near Inox Theatre, Opp. Municipal Market, Panaji.
Ph.: 2229142, 8407912840, 8390242524

E-mail : ashwinilabpanaji@gmail.com, drprasadnetravalkar@gmail.com

Mapusa : PS, Ramchandra Chambers, 1st Floor, Mapusa Clinic Road, Mapusa - Bardez, Goa. Ph.: 2252320

Pt.No. : 39 031024

Pt.Name : - Simran Sharma

Ref. By : -

Age : 28 Yrs. Sex : F

Date : 28/9/24

EXAMINATION OF URINE

PHYSICAL EXAMINATION


Quantity : 20 ml
Colour : Pale Yellow
Appearance : Slightly Hazy
pH : 6.5
Specific Gravity : 1.010

CHEMICAL EXAMINATION


Proteins : Absent
Glucose : Absent
Ketone Bodies : Absent
Bile Salts : Absent
Bile Pigments : Absent
Occult Blood : Negative
Urobilinogen : Normal

MICROSCOPIC EXAMINATION [As per hpf]

Epithelial Cells : 5 - 6 /hpf
Pus Cells : 1 - 2 /hpf
Red Blood Cells : Absent
Casts : Absent
Crystals : Absent


28/9/24

Pathologist



Dr. Prasad Netravalkar
MBBS, MD (Bom)
GMC Reg. No. 1294

We Care

All Diagnostic facilities under one roof in Panaji centre - Lab, ultrasound, X ray, ECG, TMT, ECHO

DR. NETRAVALKAR'S ASHWINI PATHOLOGY LABORATORY

(For all investigations in Histopathology, Cytopathology, Haematology, Clinical Pathology, Microbiology & Hormonal Chemistry)
Consultant Pathologist: **Dr. Prasad Netravalkar** MBBS MD (Path) BOM

(HOME COLLECTION FACILITY AVAILABLE)

Panaji : 1st, Floor, Rizvi Sadan, Above Saroj Emporium, Near Inox Theatre, Opp. Municipal Market, Panaji.
Ph.: 2229142, 8407912840, 8390242524

E-mail : ashwinilabpanaji@gmail.com, drprasadnetravalkar@gmail.com

Mapusa : F8, Ramchandra Chambers, 1st Floor, Mapusa Clinic Road, Mapusa - Bardez, Goa. Ph. 2252320

Patient Name : SIMRAN SHARMA

Age / Gender : 28 / Female

Patient ID : 35021

Source : DIRECT

Referral : SELF

Reporting Time : Sep 28 2024 01:47 p.m.

Sample ID :



Test Description	Value(s)	Reference Range	Unit
Thyroid Profile			
T3 (Total) Method: Serum ECL	2.63	1.30 - 3.10	nmol/l
T4 (Total)* Method: Serum ECL	142.5	66.0 - 181.0	nmol/l
TSH(Ultraseensitive)* Method: Serum ECL	4.51	0.270 - 4.20	uIU/ml

END OF REPORT

Pathologist

Dr. Prasad Netravalkar
MBBS MD (Bom)
GAC Reg. No. 1294

No. Care

All Diagnostic facilities available only in Panaji centre. Lab. address: 7, Map. ECG. TMT. ECG.

**DR. NETRAVALKAR'S
ASHWINI PATHOLOGY LABORATORY**

(For all investigations in Histopathology, Cytopathology, Haematology, Clinical Pathology, Microbiology & Hormonal Chemistry)
Consultant Pathologist **Dr. Prasad Netravalkar** MBBS, MD (Path) BOM
(HOME COLLECTION FACILITY AVAILABLE)

Panaji : 1st. Floor, Rizvi Sadan, Above Saroj Emporium, Near Inox Theatre, Opp. Municipal Market, Panaji.
Ph.: 2229142, 8407912840, 8390242524
E-mail : ashwinilabpanaji@gmail.com, drprasadnetravalkar@gmail.com
Mapusa : FS, Ramchandra Chambers, 1st Floor, Mapusa Clinic Road, Mapusa - Bardez, Goa. Ph.: 2252320

Patients Name : Simran Sharma , 28Y/F Date : 02/10/2024

Ref. by Dr :

CYTOPATHOLOGY REPORT

Specimen Sent : Pap Smears.

Report : Pap smears show moderate sheets of superficial epithelial cells, occasional sheets of intermediate epithelial cells and occasional groups of endocervical epithelial cells.

The epithelial cells show normal nucleus:cytoplasm ratio. Their nuclear chromatin is regular and well scattered.

Occasional neutrophils & Dod .Bacilli are seen in background.

No fungi or protozoa seen.

No evidence of dysplasia or malignancy seen.

Opinion : Pap smears show no significant pathology.



Pathologist



Dr. Prasad Netravalkar
MBBS, MD (Bom)
GMC Reg. No. 1294

We Care

All Diagnostic facilities under one roof in Panaji centre - Lab, ultrasound, X ray, ECG, TMT, ECHO


CERTIFICATE OF MEDICAL FITNESS

This is to certify that I have conducted the clinical examination


of SIMRAN SHARMA on 28/9/24

After reviewing the medical history and on clinical examination it has been found that he/she is

	Tick
<ul style="list-style-type: none">• Medically Fit	<input checked="" type="checkbox"/>
<ul style="list-style-type: none">• Fit with restrictions/recommendations <p>Though following restrictions have been revealed, in my opinion, these are not impediments to the job.</p> <p>1.....</p> <p>2.....</p> <p>3.....</p> <p>However the employee should follow the advice/medication that has been communicated to him/her.</p> <p>Review after _____</p>	
<ul style="list-style-type: none">• Currently Unfit. <p>Review after _____ recommended</p>	
<ul style="list-style-type: none">• Unfit	

Dr. 
Medical Officer
The Apollo Clinic, (Location)

This certificate is not meant for medico-legal purposes



MER- MEDICAL EXAMINATION REPORT

Date of Examination	28/9/24		
NAME	Sumran Shaima		
AGE	28	Gender	F
HEIGHT(cm)	160	WEIGHT (kg)	74
B.P.	120/80		
ECG	Normal		
X Ray	Normal		
Vision Checkup	Color Vision: Normal		
	Far Vision Ratio: 6/6		
	Near Vision Ratio: 6/6		
Present Ailments	- NO -		
Details of Past ailments (If Any)	- NO -		
Comments / Advice : She /He is Physically Fit	Healthy		

Mh

Signature with Stamp of Medical Examine



भारत सरकार
Government of India




Simran Sharma
Date of Birth/DOB: 08/04/1998
Female/ FEMALE

4765 9590 7829

VID : 9115 7424 0889 8840

मेरा आधार, मेरी पहचान

Simran Sharma



कृ. नं.




भारतीय विशिष्ट पहचान प्राधिकरण

Unique Identification Authority of India



Address:

O: Late Kumar Prem Piyush, Village/Post -
Iwa, Ps - Deepnagar, Pawa, Nalanda,
Pin - 803115



4765 9590 7829

VID : 9115 7424 0889 8840

☎ 1947

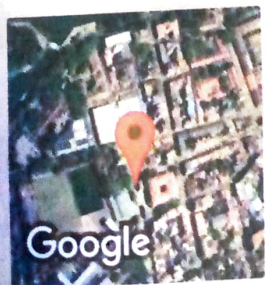
✉ help@uidai.gov.in

🌐 www.uidai.gov.in

Simran Narver




GPS Map Camera



Google

Panaji, Goa, India
B 165, New Municipal Market, Panaji, Goa 403001, India
Lat 15.498448°
Long 73.822357°
28/09/24 09:29 AM GMT +05:30



201, 202, 203, Rizvi Sadan, 2nd Floor, Near Municipal Market, Next to Vaidya Hospital, Panaji - Goa.
Tel.: 0832 2238122 | Email : drashanetravalkar@gmail.com

Cardiology Report

Page 1/2

ASHWINI LABORATORY

Patient / Exam Information

Date of Exam: **28.09.2024**

Patient ID	VS8802280-24-09-28-5	Height
Name	SIMRAN SHARMA 28	Weight
DOB, Age		BSA
Sex	Other	HR

Perf. Phys.	Ref. Phys.	Sonographer
Comment	Indication	

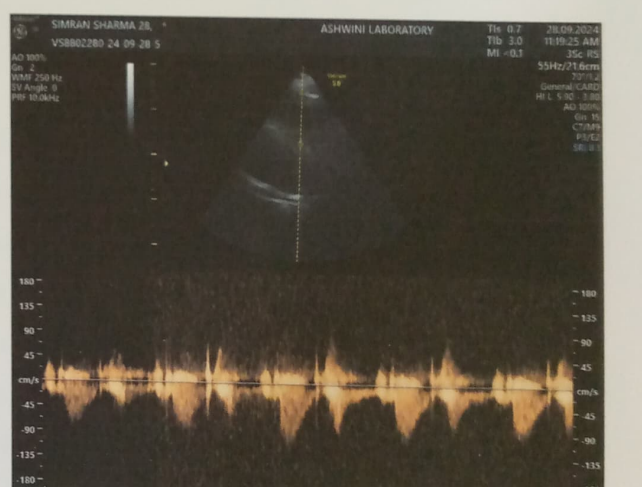
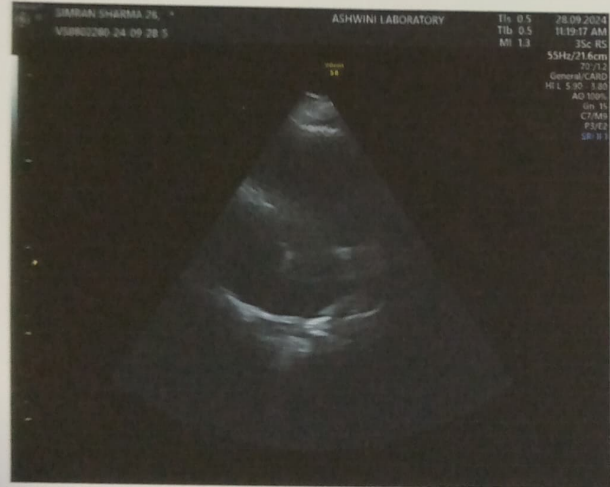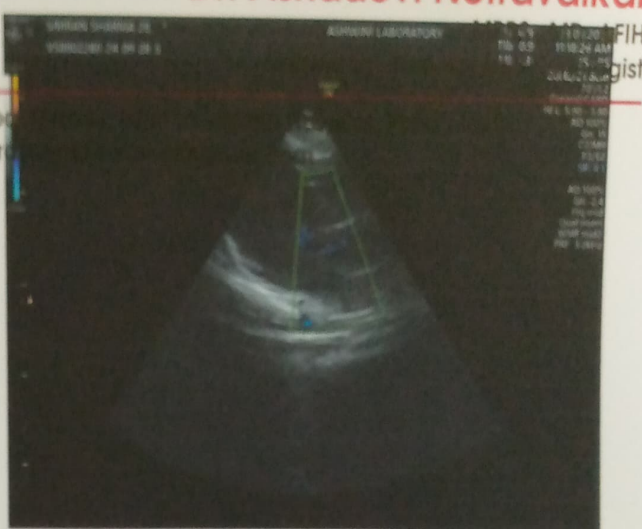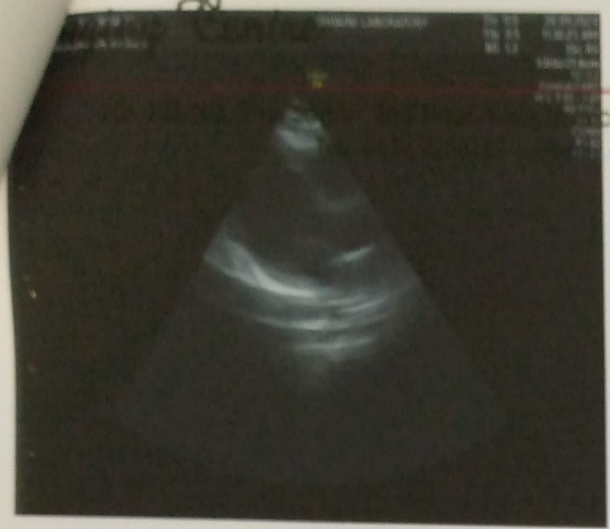M-Mode Measurements	Value	m1	m2	m3	m4	m5	m6	Meth.
AV/LA								
Ao Root Diam.	2.76 cm	2.76						avg.
LA Diam.	3.04 cm	3.04						avg.
Left Ventricle								
IVSd	0.99 cm	0.99						avg.
LVDd	4.08 cm	4.08						avg.
LVPWd	0.88 cm	0.88						avg.
IVSs	2.15 cm	2.15						avg.
LVDs	2.70 cm	2.70						avg.
LVPWs	1.05 cm	1.05						avg.
EDV (Teich)	73.367 ml	73.367						
EDV (Cubed)	67.917 ml	67.917						
ESV (Teich)	27.016 ml	27.016						
ESV (Cubed)	19.683 ml	19.683						
SV (Teich)	46.351 ml	46.351						
SV (Cube)	48.234 ml	48.234						
EF (Teich)	63.18 %	63.18						
EF (Cube)	71.02 %	71.02						
Fract. Short.	33.82 %	33.82						
LV Mass	134.84 g	134.84						

Comment

NORMAL CARDIAC CHAMBERS DIMENSIONS. NORMAL BI VENTRICLE SYSTOLIC FUNCTION. NO REGIONAL WALL MOTION ABNORMALITIES. VALVES ARE NORMAL. AORTIC ROOT IS NORMAL. PERICARDIUM IS NORMAL.

Ashadevi

1/2
28.09.2024 11:21:08 AM



201, 202, 203, Rizvi Sadan, 2nd Floor, Near Municipal Market, Next to Vaidya Hospital, Panaji - Goa.
Tel: 0832 2238122 | Email: drashanetravalkar@gmail.com

NAME: MRS. SIMRAN SHARMA
AGE: 28/YRS
REF BY: DR. SELF

DATE: 01/10/2024
SEX: F

ULTRASONOGRAPHY OF ABDOMEN AND PELVIS

LIVER - It shows mild increased echotexture and normal size. No focal lesions are seen. Intrahepatic biliary and portal radicals appear normal. Length of liver is 13.9cm. PV - 9mm.

PANCREAS - It shows normal echotexture and size. No focal lesions are seen.

GALL BLADDER - It is moderately distended. Sludge ball measuring 8mm is seen. CBD is 2mm.

SPLEEN - It shows normal echotexture. Length of spleen is 12.3cm.

BOTH KIDNEYS show normal echotexture and size. Corticomedullary differentiation is seen well. No calculus is seen. Bilateral mild hydronephrosis is seen. Upper poles are tilted medially. Perirenal space is normal.

Right kidney - measures 10.4cm x 5cms. **Left kidney** - measures 10.6cms x 3.5cms.

Urinary Bladder is well distended. No calculus and mass is seen. Both VUJ are normal. Perivesical space is normal.

UTERUS : It is retroverted and It measures 7.3cms x 5.3cms x 3.8cms.

Myometrium show normal echotexture. No mass is seen. Endometrial thickness is 4mm.

Both ovaries show normal echotexture. 3-4 follicles measuring 4mm-1.6mm are seen in it.

Right ovary - measures 3.4cms x 1.6 cms. **Left ovary** - measures 4.8cms x 1.4cms.

No adnexal mass is seen. No free fluid is seen in pelvis.

Plenty of bowel gases are seen. Visualised appendix measures 2.2cm x 7mm. Tenderness is present. No mass or free fluid is seen in right iliac fossa.

Impression : Mild fatty liver.


Mild splenomegaly.

Sludge ball in GB.

Mild bilateral hydronephrosis.

? Appendicitis - to correlate with lab tests.

With regards,


DR. ASHADEVI NETRAVALKAR, MD
RADIOLOGIST

DR. ASHADEVI NETRAVALKAR
MBBS., MD, AFIH
Consultant Radiologist
2nd Floor, Rizvi Sadan Panaji
Tel: 0832-2238122 / 9822125224

201, 202, 203, Rizvi Sadan, 2nd Floor, Near Municipal Market, Next to Valdyia Hospital, Panaji - Goa.
Tel. 0832 2238122 | Email drashanetravalkar@gmail.com

NAME: MRS. SIMRAN SHARMA
AGE: 28/YRS
REF BY: DR. SELF

DATE: 28/09/2024
SEX: F

X-RAY CHEST--- PA VIEW

Lung fields are clear.

Both costophrenic angles are clear.


Cardiac size is normal.

Both domes of diaphragm are normal.

Rib cage is normal.

Impression: Normal study.

With regards,



DR. ASHADEVI NETRAVALKAR, MD
RADIOLOGIST

DR. ASHADEVI NETRAVALKAR

MBBS., MD, AFIH

Consultant Radiologist

2nd Floor, Rizvi Sadan Panaji
Tel: 0832-2238122 / 9822125274

Dr. Netravalkar's Imaging Centre

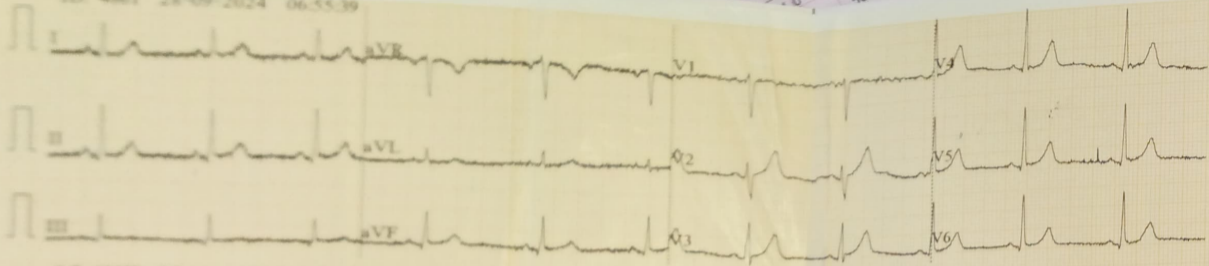
Dr. Ashadevi Netravalkar
MBBS., MD, AFIH
Consultant Radiologist & Sonologist

Name : SIMRAN SHARMA
Age : 28 M/F F Date : 28.01.24
Investigation : DCG
Ref. by Dr. :

201,202,203, Rizvi Sadan, 2nd Floor, Near Municipal Market,
Next to Vaidya Hospital, Panaji - Goa.
Tel.: 0832 2238122 | Email : drashanetravalkar@gmail.com

Timing : 8.00 am to 1.00 pm | 4.00 pm to 7.00 pm

ID: 4861 28-09-2024 06:55:39




0.5-100Hz 25mm/s 10mm/mV ♡67 V1.0 SEMIP V1.7

ID: 4861

Female mmHg
28 Years cm kg

Suman Bhang

HR	:	67	bpm
P	:	77	ms
PR	:	111	ms
QRS	:	78	ms
QT/QTc	:	368/391	ms
P-QRST	:	45.51.47	"
RV5SV1	:	1.4940.884	mV



ECG Normal
[Signature]

DR. SIGN.