


Name	: Ms. TAMANNA YADAV	MR No	: UH038304
Age/Gender	: 26 Y/F	Visit ID	: OP050200
Admitting Doctor	:	Sample Collected on	: 20-06-2024 08:40
Lab ID No	: LAB067108	Sample Received on	:
		Report Released on	: 20-06-2024 12:40

## Laboratory Report

### Hematology

<u>Test Description</u>	<u>Result</u>	<u>Units</u>	<u>Ref Range</u>
Sample Type: Whole Blood			
<b>BLOOD GROUP (ABO &amp; RH TYPING)</b>	"A" POSITIVE		
Sample Type: EDTA			
<b>CBC WITH ESR</b>			
HAEMOGLOBIN	12.8 *	gm/dL	13 - 18
TOTAL LEUCOCYTE COUNT	6,800	cell/cum	4000 - 11000
D.L.C = POLYMORPHS	63	%	40 - 75
LYMPHOCYTES	33	%	20 - 45
EOSINOPHILS	03	%	01 - 06
MONOCYTES	01	%	0 - 08
BASOPHILS	00	%	0 - 01
E.S.R (WINTROBE)	18 *	mm/1st	0 - 9
RED BLOOD CELLS	4.9	Millions	3.5 - 5.5
PLATELET COUNT	2.5	lakh/cum	1.5 - 4.5
P.C.V	39.5	%	35 - 50
M.C.V	80.4	fl	80 - 96
M.C.H	26.3 *	pg	27 - 32
M.C.H.C	32.7	%	32 - 36

\*\*\*End of the report\*\*\*



Checked By  
Lab Technician

Verified By



DR. PRIYAVART MEHARWAL  
MBBS, MD  
Pathologist

UMKAL Hospital Pvt. Ltd

A-520, Sushant Lok-I, Gurugram- 122 002  
Ph.: 0124-4 666 555 Mobile : 88600 77501  
Emergency Ph No.: 0124 4100000

Name	: Ms. TAMANNA YADAV	MR No	: UH038304
Age/Gender	: 26 Y/F	Visit ID	: OP050200
Admitting Doctor	:	Sample Collected on	: 20-06-2024 08:40
Lab ID No	: LAB067108	Sample Received on	:
		Report Released on	: 20-06-2024 12:41

### Laboratory Report

#### Biochemistry

<u>Test Description</u>	<u>Result</u>	<u>Units</u>	<u>Ref Range</u>
Sample Type: Serum <b>BLOOD SUGAR - FASTING</b> BLOOD SUGAR FASTING	87.7	mg/dl	70 - 110
Sample Type: Serum <b>BLOOD SUGAR - PP 1465</b> BLOOD SUGAR PP 1465	117.2	mg/dl	70 - 140
Sample Type: Serum <b>S.G.P.T 1475</b> S.G.P.T	26.3	IU/ML	upto - 45
Sample Type: Serum <b>SERUM BILIRUBIN TOTAL 1456</b> S. BILIRUBIN (TOTAL)	0.49	mg/dl	0.1 - 1.2
Sample Type: Serum <b>SERUM CREATININE</b>	0.89	mg/dl	0.6 - 1.2
Sample Type: Serum <b>BUN/SERUM CREATININE RATIO</b>	12.0		10 - 20

\*\*\*End of the report\*\*\*

*[Signature]*

Checked By  
Lab Technician

Verified By

*[Signature]*

Name	: Ms. TAMANNA YADAV	MR No	: UH038304
Age/Gender	: 26 Y/F	Visit ID	: OP050200
Admitting Doctor	:	Sample Collected on	: 20-06-2024 08:40
Lab ID No	: LAB067107	Sample Received on	:
		Report Released on	: 20-06-2024 12:42

## Laboratory Report

### CLINICAL PATHOLOGY

<u>Test Description</u>	<u>Result</u>	<u>Units</u>	<u>Ref Range</u>
Sample Type: Urine			
<b>URINE ROUTINE &amp; MICROSCOPIC 1383</b>			
COLOUR	P.YELLOW		
APPEARANCE	S.TURBID		
SPEC.GRAVITY	1.015		
REACTION	6.0		
ALBUMINE	NIL		
SUGAR	NIL		
KETONE BODIES	NIL		
BLOOD	NIL		
LEUKOCYTES	NIL		
NITRITE	NIL		
UROBILINOGEN	NIL		
MICROSCOPIC EXAM	.		
PUS CELLS	3-4	/HPF	0 - 05
RBC CELLS	NIL	/HPF	0 - 02
EP CELLS	5-6	/HPF	0 - 05
CASTS	NIL		
CRYSTALS	NIL		
BACTERIA	NIL		
OTHER	NIL		

\*\*\*End of the report\*\*\*

  
Checked By  
Lab Technician

Verified By



NAME - Tamanna Yadav AGE - 26 /F DATE : 20.6 .2024

ADDRESS - Apollo

ON EXAMINATION

Height : 160 cm, Weight : 54 kg, Pulse : 81 min, BP: 109 / 77 mmhg.

SYSTEMS

- a) Respiratory - Normal vesicular breath sounds  
- No adventitious sound
- b) Cardio Vascular - S1 S2 normal, No murmur
- c) Central Nervous - Normal
- d) Abdomen - Soft  
Liver/Spleen – Not palpable
- e) Locomotor - Normal

ECG: Normal

X-Ray : Haziness is noted in B/L lower zone likely due to breast shadow .

BIOCHEMICAL ANALYSIS:

E.S.R 18\*  
HEMOGLOBIN 12.8\*  
M.C.H 26.3\*

REMARKS : Medically FIT/UNFIT ✓

**DR. ANUJ GOYAL**  
MBBS, MD (Internal Medicine)  
Regn. No. DMC/R/-23794  
GENERAL PHYSICIAN. Ltd.

20/06/20

Tamara Tamara Yadav / 26y / Female

Pt came for regular annual health check-up.

clt :- NO Gen complaints.

Past Hx :- Not significant.

Personal Hx :- . Veg Diet

ECG = TUNL - (M) Resp.

Family Hx :- . Mother has HTN.

. Father has DM.

Allergic Hx :- Allergic to hot & spicy food.

Obs. Hx :- . LMP = 31/01/20.

. Irregular cycle.

DE :- Pt. is concious & oriented.

PIA :- Soft & non-tender.

Ref :- B/L equal air entry.

CNS :- (M) S.A

CNS :- None

Mrs. Tamma  
26y/F  
Gynae Consultation

Irregular cycle W.P. 31/5/24

no h/o vaginitis ⊕  
no h/o Diabetes/H.T.N.  
No h/o breast or any cancer

M/L x Feb/24  
multiparous

P/A soft  
non tender

P/S - healthy Cx

Adv  
Normal for Gynae  
vis

✓  
Dr. NEERU GUPTA  
MBBS, DNB (OBGY)  
HMC Reg. No. 005536

Tamanna Yadav

F 26yr.

20.6.24.

V 6/6  
6/6

N V 6/6  
N-6

Crowd V 6/6 WM  
WM

L

# CERTIFICATE OF MEDICAL FITNESS

This is to certify that I have conducted the clinical examination

of Tamanna Yadav on 20/6/24

After reviewing the medical history and on clinical examination it has been found that he/she is

	Tick
<ul style="list-style-type: none"><li>• Medically Fit</li></ul>	<input checked="" type="checkbox"/>
<ul style="list-style-type: none"><li>• Fit with restrictions/recommendations</li></ul> <p>Though following restrictions have been revealed, in my opinion, these are not impediments to the job.</p> <p>1.....</p> <p>2.....</p> <p>3.....</p> <p>However the employee should follow the advice/medication that has been communicated to him/her.</p> <p>Review after _____</p>	
<ul style="list-style-type: none"><li>• Currently Unfit.</li></ul> <p>Review after _____ recommended</p>	
<ul style="list-style-type: none"><li>• Unfit</li></ul>	

Dr. DR ANUJ GOYAL  
MBBS, MD (Internal Medicine)  
Medical Registration - DMC/R/23794  
Umkaal Hospital Pvt. Ltd.

*This certificate is not meant for medico-legal purposes*

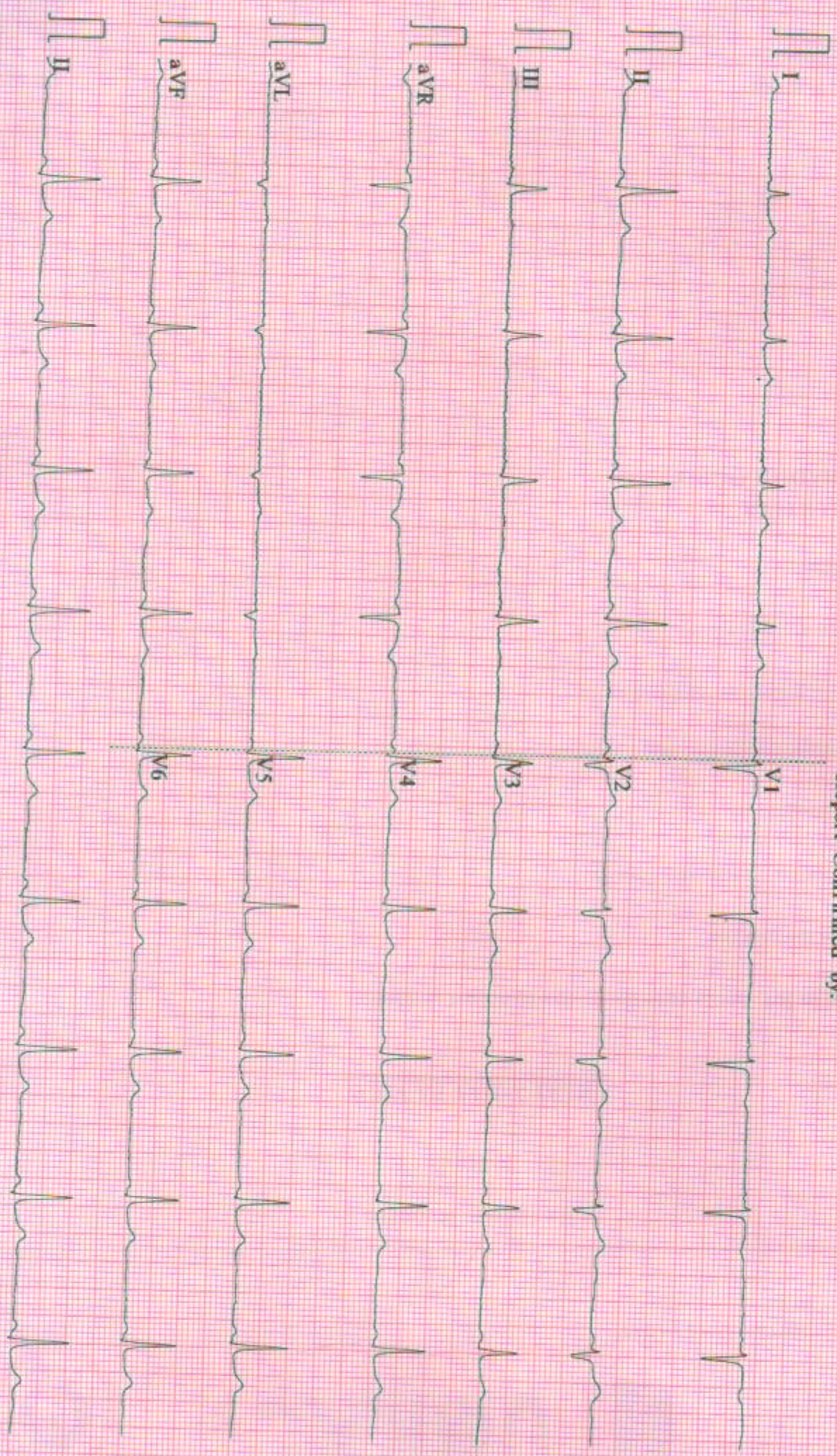


Female 26 Years  
Req. No. :

HR : 56 bpm  
P : 90 ms  
PR : 122 ms  
QRS : 96 ms  
QT/QTcBz : 420/408 ms  
P/QRST : 56/67/47 °  
RV5/SV1 : 0.987/0.762 mV

Diagnosis Information:  
Sinus Bradycardia

Report Confirmed by:



0.67~25Hz ACS0 25mm/s 10mm/mV 2\*5.0s+1r V2.22 SEMIP V1.92 UMKAL HOSPITAL

SP1

Name	: Ms. TAMANNA YADAV	MR No	: UH038304
Age/Gender	: 26 Y/F	Visit ID	: OP050200
Admitting Doctor	:	Order Date	: 20-06-2024 08:27
		Report Date	: 20-06-2024 13:05

**Radiology Report**

**X-Ray**

**CHEST X-RAY PA VIEW**

**Finding -**

**Haziness is noted in B/L lower zone likely due to breast shadow.**

Trachea appears in the midline.

Both hila appear normal in size and density.

Cardiac size appears normal.

Both CP angle and cardiophrenic angle appears normal.

Diaphragm appears normal on both sides.

Visualized rib cage appears normal.

Please correlate clinically

**DR ARUSHI BHARTIYA**  
**CONSULTANT RADIOLOGIST**

Technician

UMKAL Hospital Pvt. Ltd

A-520, Sushant Lok-I, Gurugram- 122 002  
Ph.: 0124-4 666 555 Mobile : 88600 77501  
Emergency Ph No.: 0124 4100000

Verified By

