

DAKSH HOSPITAL

396 - 397, Gandhi Nagar, Scheme No. 8, ALWAR -301001

Ref. No.

Date.....

MEDICAL EXAMINATION REPORT

Mediwheel (BOB)

Name: Mrs Rekha Saini

Age: 36 yrs Sex:Female

Date: 26/10/2024

General Physical Examination

Height	:	154 cm.	Weight	:	53.8 kg
Pulse	:	90 bpm	BP	:	110/70 mm/hg.
Temp.	:	97.2F	Respiration SpO2	:	92 %
BMI	:	22.7			

Systemic Exam:- NORMAL Pallor +Dental Check up :- NORMALEye check-up :- NORMALSkin Check up:- NORMALENT Check up:- NORMALGynae Check up:- 3/30d Mc, Oh-P2 P14 MAD
LMP-5th, 2D-2 1/2 kg Paps smear takenImpression:- MICROCYTIC ANEMIA Hb 8.4, MCV 70.1
TSR 12.0, WBC, GALL STONES, 13.5mmRecommendation:-

- EVALUATION FOR ANEMIA
- SURGEONS OPINION FOR GALL STONES
- BETTER CONTROL OF HYPERTENSION

Dr. Mukesh Kumar Gupta
MD Gen Medicine
Reg. No 5423/16262

डॉ० मुकेश गुप्ता

M.D.F.C.C.S.

फिजिशियन एवं मधुमेह रोग विशेषज्ञ

दक्ष हॉस्पिटल, अलवर

रजि० नं०-5423/16262

Date :- 26/10/2024 Name :- MRS. REKHA SAINI

Refd. :- Dr Mukesh Gupta M.D.

	TEST NAME	RESULT	REFERENCE RANGE
	ESR	15	00 -20 mm/hrs
	Blood Group & Rh Factor	AB ⁺ POSITIVE	
	HbA1C	4.9	4 - 5.6%
	Blood Sugar (F)	82.3	< 70 - 100 mg/dl
	Blood Sugar (PP)	-	< 140 mg/dl
	Urine Sugar (F)	NIL	-
	Urine Sugar (PP)	-	-
LIVER	S.Bilirubin Total	0.85	0.30 - 1.20 mg/dl
	S.Bilirubin Direct	0.20	0.10 - 0.30 mg/dl
	S.Bilirubin Indirect	0.65	0.30 - 0.90 mg/dl
	S.G.O.T.	16	> 37 u/l
	S.G.P.T.	22	> 40 u/l
	S.Alk. Phosp.	202	80 - 306 u/l
	G.G.T.	22	5 -40 u/l
	Total Protein	6.9	6.5 - 8.5 gm/dl
	Albumin	3.6	3.8 - 5.4 gm/dl
	Globulin	3.3	2.3 - 3.5 gm/dl
	A/G Ratio	1.2	-
	AST/ALT Ratio	0.6	-
KIDNEY	Blood Urea	26.5	15 -45 mg/dl
	S.Creatinine	1.0	0.60 - 1.30 mg/dl
	BUN	16.1	6 -24 mg/dl
	S.Uric Acid	5.1	M 3.1 - 7.0, F 2.5 - 5.6 mg/dl
	BUN/Creatinine Ratio	16.4	-
LIPID PROFILE	Total Cholesterol	145.0	Up to 200 mg/dl
	S.HDL	42.0	30 - 70 mg/dl
	S.LDL	66.0	Up to 170 mg/dl
	S.VLDL	37.0	5.0 - 40 mg/dl
	S. Triglycerides	135.0	Up to 170 mg/dl
	LDL/HDL Ratio	1.5	-
	Total Cholesterol/ HDL Ratio	3.4	-
THYROID	T3	104.0 ⁶⁰	40 - 181 ng/dl
	T4	7.38 ^{5.4}	4.6 - 10.5 µg/dl
	TSH	12.0	0.30 - 5.0 mlu/l
	URINE EXAMINATION		Microscopic Examination:
General/Chemical Examination:			RBC Absent
	Colour	Pale Yellow	WBC 1-2
	Reaction	Acidic	Epithelial Cells 3-4
	Specific Gravity	QNS	Cast Absent
	Appearance	Clear	Crystal Absent
	Albumin	TRACE	Spermatozoa Absent
	Sugar	Nil	Amorphous Sediments Absent
			Other Absent
X-RAY CHEST		NORMAL STUDY	

Dr. R.S. GUPTA
MD (Pathology) (MAHE)

Reg. No. 7924/19778

TECHNOLOGIST

All investigations have their own limitations regarding the sensitivity & specificity of individual assay procedures, isolated laboratory investigations never confirm the final diagnosis of the disease. They only help in arriving at a diagnosis in conjunction with clinical presentation and other related investigations. Report is not valid for medico-legal purpose subject to ALWAR jurisdiction only.

Date :- 26/10/2024

Name :- Mrs. Rekha Saini

Refd. :- Dr Mukesh Gupta MD

Age & Sex :- 36Yrs/ Female

CYTO-PATHOLOGY

PAP SMEAR

1. Specimen type	Received two conventional smears.
2. Specimen adequacy	Smears are satisfactory for evaluation.
3. Microscopic finding	Smears are moderately cellular comprises of predominantly intermediate with mature superficial squamous epithelial cells arranged in clusters & scattered singly.
4. Inflammation	Not seen
5. Bacilli	Not seen
6. Endocervical cells	Not seen
7. Koilocytic changes	Not seen
8. Trichomonas	Not seen
9. Dysplasia	Nil
10. Neoplasia	Nil
11. Endometrial cells	Nil

Impression:- Negative for intraepithelial lesion or malignancy


Dr. R.S. GUPTA
MD (Pathology) (MAHE)
RMC No. 7924/19778

Doctor


TECHNOLOGIST



दक्ष हॉस्पिटल

396, गाँधी नगर स्कीम नं.8, अलवर (राज०) ☎ 0144-2703340

Sonography / 2D Echo Cardiography / Doppler Report

NAME :- MRS REKHA/F/36 YRS

26-Oct-24

BOB HEALTH CHECKUP

U.S.G. OF ABDOMEN & PELVIS

LIVER

Liver is normal in size shape with normal echo-texture. Intra hepatic biliary radicals Are not dilated. No evidence of focal or diffuse lesion.

GALL BLADDER

Gall bladder is well distended, visualized lumen has 13.5 mm stone near neck. CBD normal.

PANCREAS

Pancreas is normal in size, shape & echo-texture. No evidence of focal or diffuse lesion. MPD not dilated.

SPLEEN

8.5 cm normal in size with normal shape & echo- texture. Spleen vein is normal. No evidence of focal or diffuse lesion

KIDNEY

Both kidneys are normal size shape and echo- texture.

URINARY BLADDER

UB is well distended, visualized lumen appear clear.

UTERUS:

Uterus is **retroverted** normal in size with homogenous echo-texture. Endometrial 10 mm in thickness & echo genicity

OVARIES:

Both ovaries are normal size, shape & echo-texture.

Advice- follow up/ hormonal study review at higher center for confirmation

Please correlate clinically. USG accuracy is 95 % due to technical limitations as well as inaccuracies inherent in the laboratory and statistical analysis biological process.

This report is not valid for medico-legal cases



DR. MUKESH GUPTA
SONOLOGIST
Dr. Mukesh Kumar Gupta
Physician & Sonologist
RM 5423/16262



"भ्रूण लिंग परीक्षण की शिकायत

104 टोल फ्री सेवा पर भी की

जा सकती है।

भ्रूण लिंग परीक्षण की शिकायत 104 टोल फ्री सेवा पर भी की जा सकती है।



दक्ष हॉस्पिटल

396, गाँधी नगर स्कीम नं.8, अलवर (राज०) ☎ 0144-2703340

Sonography / 2D Echo Cardiography / Doppler Report

2D/ ECHO REPORT

Name: - Mrs REKHA

Age: - 36 Yrs

Date: - 26-Oct-24

Reg. No.: - Alw/2009/04

BOB health checkup

PROCEDURES:

M-MODE/2D/DOPPLER/COLOR/CONTRAST B.A.S. M²

MEASUREMENT:		DOPPLER:	
AOD	20	NORMAL (20- 37mm)	NORMAL (cm/sec.)
LA	18	(19- 40mm)	MV 0.8 (0.8- 1.3) MR No
AVO	14	(12- 25mm)	AV 1.3 (1.2- 1.8) AR No
RVDd.	13.6	(03- 09mm)	TV 0.6 (0.3- 0.8) TR No
			PV 0.8 (0.7- 1.1) PR No
LVDd	43	(37- 56mm)	MITRAL VALVE-
LVDs	25	(22- 40mm)	AML Normal
IVS d	6.5	(06- 12mm)	PML Normal
IVS s	11.6		
PWd	3	(05- 10mm)	AORTIC VALVE Normal
LV FUNCTION		TV & PV are normal.	
M- E- S Separation	<0.9cm		
Minor	24.42%		
LV Ejection Fraction	73%	65 +/- 12%	

MITRAL E>A

LV WALL MOTION: NO RWMA

ALL CARDIAC CHAMBERS ARE NORMAL

ALL VALVES ARE NORMAL

NO CLOT, VEGETATION, PERICARDIAL EFFUSION

Adv: - Follow up/ review at higher center for confirmation

Note:- Please Correlate clinically. Due to technical limitations as well as inaccuracies inherent in the laboratory and statistical analysis of biological process. Diagnostic accuracy of ECHO is up to 95% only.
Report is not valid for medico-legal purpose.


Dr. Mukesh Gupta
Physician & Sonologist
RM 5423/16262



"भ्रूण लिंग परीक्षण की शिकायत
104 टोल फ्री सेवा पर भी की
जघन लिंग परीक्षण की शिकायत 104 टोल फ्री सेवा पर भी की जा सकती है।

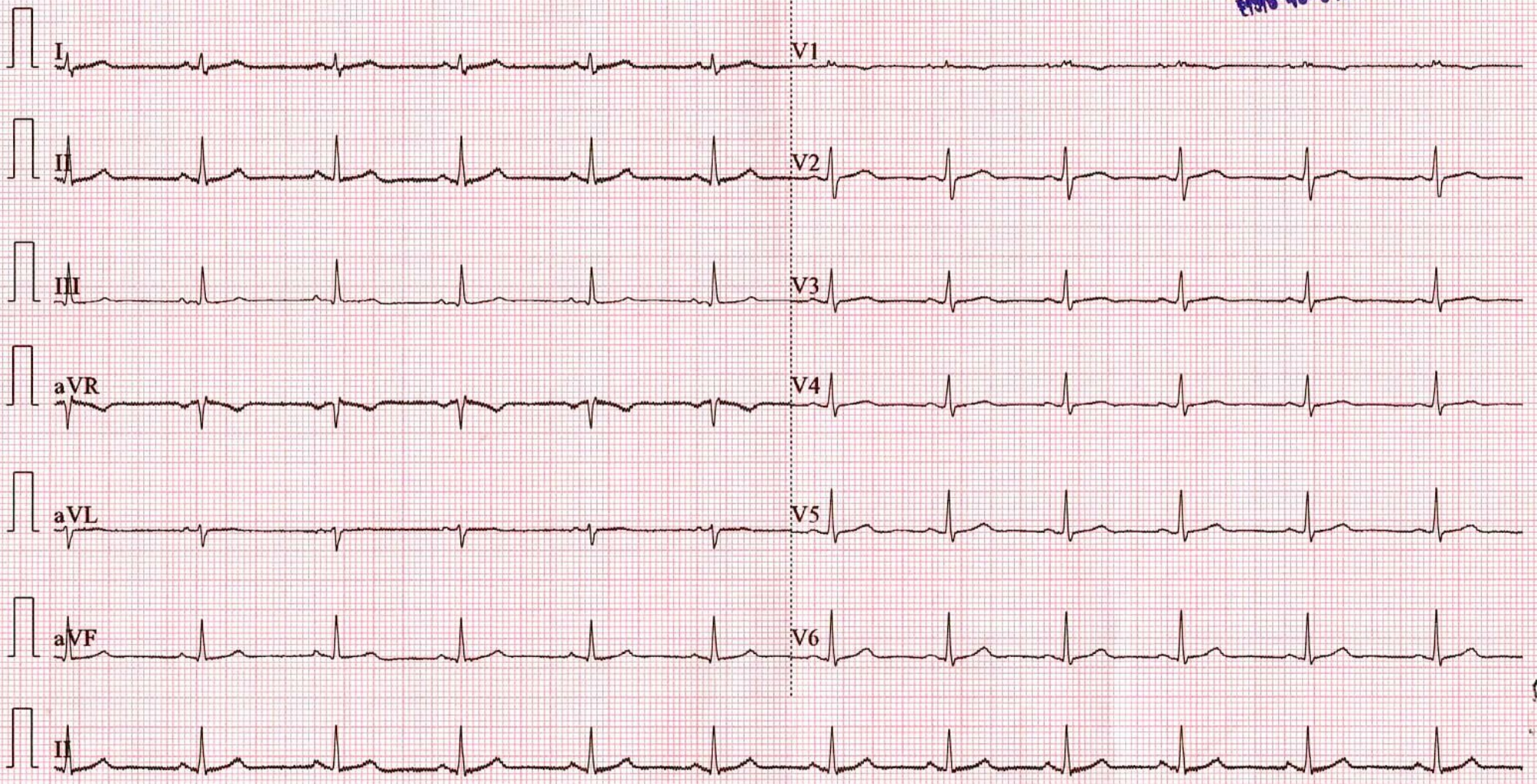
ID: 7
MRS. REKHA SAINI
Female 36Years

HR : 70 bpm
P : 100 ms
PR : 134 ms
QRS : 78 ms
QT/QTc : 358/389 ms
P/QRS/T : 49/84/49 °
RV5/SV1 : 0.732/0.000 mV

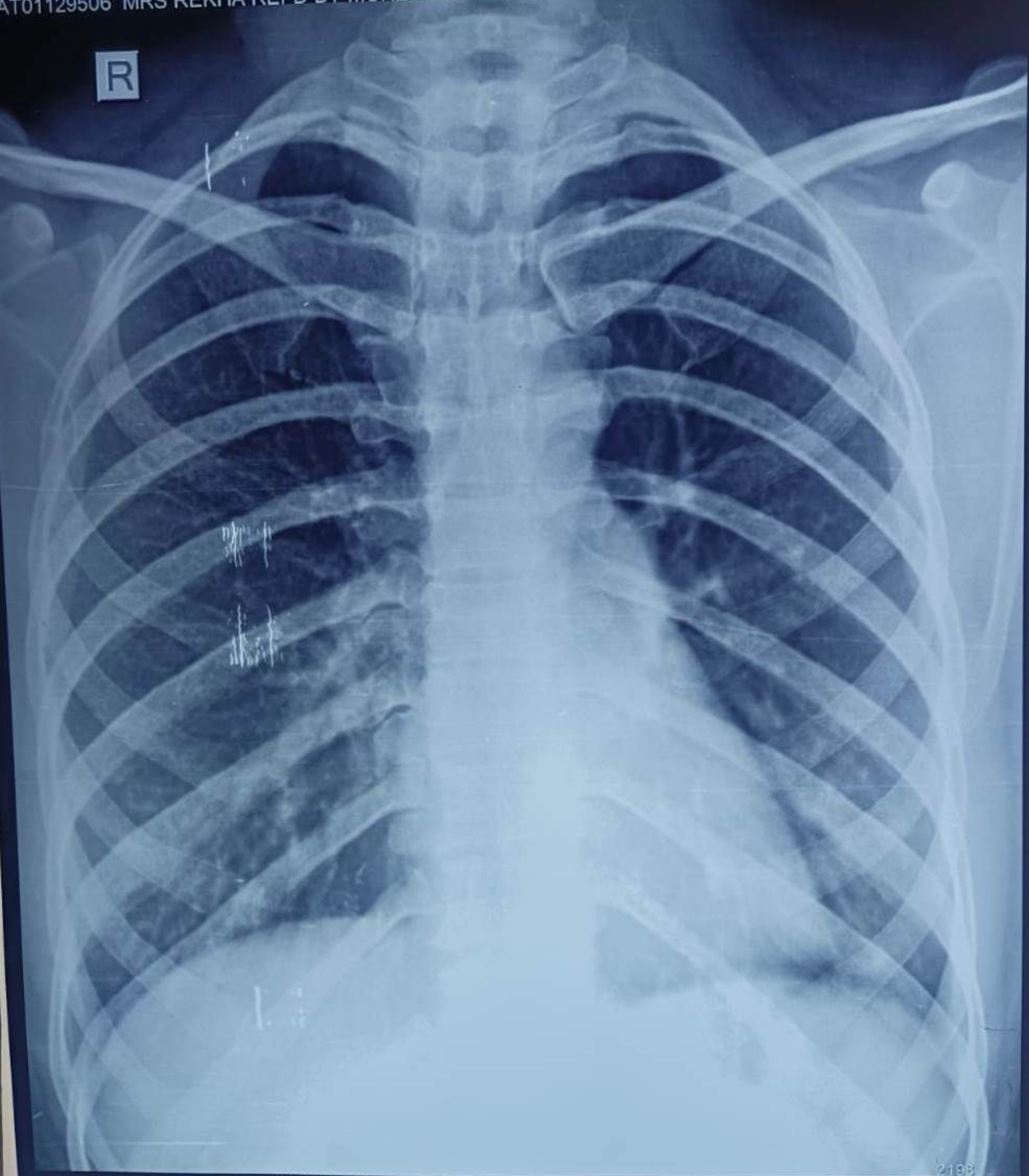
Diagnosis Information:
Sinus Rhythm
Low Voltage(Chest Leads)

Dr. Pankaj Gupta
डॉ० पंकज गुप्ता
M.P.F.C.C.S.
मिडिसिन्स एवं मधुमेह रोग विशेषज्ञ
श्री लक्ष्मि हॉस्पिटल, अलावर
संज्ञा नं०-3423/16262

Report Confirmed by:



R



2198