



PANACEA HOSPITAL

B 36/44 F.K KABIR NAGAR, DURGAKUND
TOLLFREE NO-18001233070. Whatsapp No - 8795832852
www.piire.org
panaceaquery@gmail.com|panceahospitalit@gmail.com



OP Slip

Print Date : 09-Mar-2024 09:51AM



UHID No :- UD-23240006698 **OP No** :- OP-23240020563 **OP Date** :- 09 Mar 2024 9:49AM
Patient Name :- Mr BRAJESH NANDAN **Age/Sex** :- ~~46 Y/M~~ 34/M **Mobile No** :- 8507865465
Father :- SUBHASH PRASAD SINHA **Department** :- GENERAL MEDICINE
Pay Type :- Cash **Consultant** :- Dr Pallavi Mishra (MBBS,MD,MBBS)
Token No :- NOR. - 6 **Paid/Bal** :- 0.00 /30.00
Patient Type :- Normal
Address :- 33 ROAD NO 13 RAJENDRA NAGAR PATMA SADAR-800016,BIHAR

BP :- 100/90 **Rx**
 height :- 173
 Weight (kg) :- 67
 BMI :- 22.38

▲ HTN
 T2DM

Rx

CH - 94
 NC - 36
 WC - 91
 PR - 102
 SP02 - 98
 PEPR - (250)

Adv
 PFT
 for

DR. Pallavi Mishra
 MBBS, MD(GENERAL MEDICINE)
 MCI Reg. No.52033

Printed By : Ms. Renuka
 Created By : Ms. Renuka



PANACEA HOSPITAL

B 36/44 F.K KABIR NAGAR, DURGAKUND
TOLLFREE NO-18001233070. Whatsapp No - 8795832852
www.piire.org
panaceaquery@gmail.com|panaceahospital@gmail.com



OP Slip

Print Date : 09-Mar-2024 09:52AM



UHID No :- UD-23240006698 **OP No** :- OP-23240020563 **OP Date** :- 09 Mar 2024 9:49AM
Patient Name :- Mr BRAJESH NANDAN **Age/Sex** :- 34 Y/Male **Mobile No** :- 8507865465
Father :- SUBHASH PRASAD SINHA **Department** :- DENTAL
Pay Type :- Cash **Consultant** :- Dr SHRUTI MISHRA (AA)
Token No :- NOR. - 4 **Paid/Bal** :- 0.00 /30.00
Patient Type :- Normal
Address :- 33 ROAD NO 13 RAJENDRA NAGAR PATMA SADAR-800016, BIHAR

BP :-
height :-
Weight (kg) :-
BMI :-

Rx Patient came for routine dental checkup.

p/c - stains / calculus

o/c - proximal cavities

r/c - required scaling / polishing

Printed By : Ms. Renuka
Created By : Ms. Renuka


Dr. SHRUTI MISHRA
 BDS, (DENTIST)
 MCI Reg. No. (A-09784)



PANACEA HOSPITAL

B 36/44 F.K KABIR NAGAR, DURGAKUND
TOLLFREE NO-18001233070. Whatsapp No - 8795832852
www.piire.org
panaceaquery@gmail.com|panaceahospital@gmail.com



OP Slip

Print Date : 09-Mar-2024 09:51AM



UHID No :- UD-23240006698 **OP No** :- OP-23240020563 **OP Date** :- 09 Mar 2024 9:49AM
Patient Name :- Mr BRAJESH NANDAN **Age/Sex** :- ³⁴ Y/Male **Mobile No** :- 8507865465
Father :- SUBHASH PRASAD SINHA **Department** :- OPHTHALMOLOGY
Pay Type :- Cash **Consultant** :- Dr Santosh Verma (MBBS,MS)
Token No :- NOR. - 4 **Paid/Bal** :- 0.00 /30.00
Patient Type :- Normal
Address :- 33 ROAD NO 13 RAJENDRA NAGAR PATMA SADAR-800016,BIHAR

BP :-
height :-
Weight (kg) :-
BMI :-

Rx
 VAK 60 --- 6/6 ✗
 6/9 --- 6/6 ✗
 New NG ✗
 NG ✗

A- Locally BLE
 1- In Lubstone ultra- QSD
 0500

Printed By : Ms. Renuka
Created By : Ms. Renuka

Dr. SANTOSH VERMA
 MBBS, MS (Ophthalmologist)
 MCI Reg. No. 09-34837 1 of 1



PANACEA HOSPITAL

B 36/44 F.K KABIR NAGAR, DURGAKUND
TOLLFREE NO-18001233070. Whatsapp No - 8795832852
www.piire.org
panaceaquery@gmail.com|panaceahospitalit@gmail.com



OP Slip

Print Date : 09-Mar-2024 09:50AM



UHID No :- UD-23240006698 OP No :- OP-23240020563 OP Date :- 09 Mar 2024 9:49AM
 Patient Name :- Mr BRAJESH NANDAN Age/Sex :- ³⁴ Y/Male Mobile No :- 8507865465
 Father :- SUBHASH PRASAD SINHA Department :- DERMATOLOGY
 Pay Type :- Cash Consultant :- Dr DR ASHUTOSH MISHRA (MBBS,MD)
 Token No :- NOR. - 5 Paid/Bal :- 0.00 /30.00
 Patient Type :- Normal
 Address :- 33 ROAD NO 13 RAJENDRA NAGAR PATMA SADAR-800016,BIHAR

BP :-
 height :-
 Weight (kg) :-
 BMI :-

Rx

Rx
 . Calamin lotion →
 . B: larku 20mg tab o/d → x 10
 . Xpen soap

20/03/24



Printed By : Ms. Renuka
Created By : Ms. Renuka

Facilities:

All clinical Biomedical & Hematology Investigations including Bone Marrow Examination
 VPT, Podiascan & Complete Foot Care (First Time in Purvanchal)
 All Hormonal Investigation by Chemiluminescent Method
 Visceral Fat by (AB-140) Ambulatory BP Monitoring
 CGMS & Insulin Pump Available
 PFT, 2D-ECHO (Color Doppler), Holter, TMT, Cardiac-3 available
 VIA, VILI, Colposcopy available
 Special Endocrinological Investigation Protocols.

ISO 9001:2008 Certified

Mobile: 9389994334, 9554572190, 9453837595

**Panacea Pathology****Clinical Reference Lab**

Persistence, Preparedness and Precision
 EQAS (CMC Vellore Attached) & IQAS System
 पूर्वांचल की सर्वोत्तम गुणवत्ता वाली पैथोलॉजी

UHID No :- UD-23240006698 **Booking No/Date** :- 177 / 09-Mar-2024 05:50 PM
Patient Name :- Mr BRAJESH NANDAN **Age/Sex** :- 34 Y/M
Father :- SUBHASH PRASAD SINHA **OP No** :- OP-23240020563
Address :- 33 ROAD NO 13 RAJENDRA NAGAR **Mobile No** :- 8507865465
 PATMA SADAR-800016, BIHAR
Consultant :- Dr Pallavi Mishra (MBBS,MD)

Investigations	Observations	Biological Ref. Interval	Unit
----------------	--------------	--------------------------	------

HAEMATOLOGY**CBC**

HAEMOGLOBIN <i>DefaultMethod / test Machine</i>	14.9	13.00 - 16.00	gm/dl
TLC <i>Methology / Carm</i>	8,200	4000.00 - 11000.00	Cells/cumm.
DLC DIFFERENTIAL LEUCOCYTE COUNT			
NEUTROPHILS	60	40.00 - 75.00	%
LYMPHOCYTES	35	20.00 - 45.00	%
EOSINOPHILS	02	1.00 - 6.00	%
MONOCYTES	03	2.00 - 10.00	%
BASOPHILS	00	<1-2	%
PLATELET COUNT	3.12	1.50 - 4.10	lacs /cumm
PCV	43.6	33.00 - 42.00	%
RBC <i>Methology / Carm</i>	4.76	4.50 - 5.50	million/cumm
MCV(MEAN CELL VOLUME)	95.0	83.00 - 101.00	fl
MCH(MEAN CELL HAEMOGLOBIN)	29.3	27.00 - 32.00	pg
MCHC	34.2	31.50 - 35.00	gm%

URINE EXAMINATION**URINE ROUTINE EXAMINATION**

Lab Technician

Umesh
 Consulting Pathologist
 DR. UMESH KUMAR
 MBBS, MD (PATHOLOGY)
 MCI Registered
 M.D., Pathology

Timing : 24/7 hrs

This Report is not valid for medico legal purpose

Note: These tests have technical limitations. Clinico-pathological interpretation is necessary. In case of any disparity test may be repeated immediately.

Address : 36/44 FK Kabir Nagar, Durgakund, Varanasi – 221005

Email: dramishra@gmail.com, drpallaviojha@gmail.com Website: panaceahospital.org

Facilities:

All clinical Biomedical & Hematology Investigations including Bone Marrow Examination
VPT, Podiascan & Complete Foot Care (First Time in Purvanchal)
All Hormonal Investigation by Chemiluminescent Method
Visceral Fat by (AB-140) Ambulatory BP Monitoring
CGMS & Insulin Pump Available
PFT, 2D-ECHO (Color Doppler), Holter, TMT, Cardiac-3 available
VIA, VILI, Colposcopy available
Special Endocrinological Investigation Protocols.

ISO 9001:2008 Certified
Mobile: 9389994334, 9554572190, 9453837595



Panacea Pathology

Clinical Reference Lab

Persistence, Preparedness and Precision
EQAS (CMC Vellore Attached) & IQAS System
पूर्वांचल की सर्वोत्तम गुणवत्ता वाली पैथोलॉजी


UHID No :- UD-23240006698 **Booking No/Date** :- 177 / 09-Mar-2024 05:50 PM
Patient Name :- Mr BRAJESH NANDAN **Age/Sex** :- 34 Y/M
Father :- SUBHASH PRASAD SINHA **OP No** :- OP-23240020563
Address :- 33 ROAD NO 13 RAJENDRA NAGAR **Mobile No** :- 8507865465
PATMA SADAR-800016, BIHAR
Consultant :- Dr Pallavi Mishra (MBBS,MD)

Investigations	Observations	Biological Ref. Interval	Unit
<u>PHYSICAL EXAMINATION</u>			
QUANTITY	25		ml
COLOR <i>Methology</i>	STRAW	CLEAR YELLOW	
APPEARANCE <i>DefaultMethod</i>	CLEAR	CLEAR	
<u>CHEMICAL EXAMINATION</u>			
SPECIFIC GRAVITY	1.020	1.01 - 1.03	
PH	5.5	4.60 - 8.00	
GLUCOSE	NIL	60.00 - 100.00	mg/dl
PROTEIN-	NIL		
<u>MICROSCOPIC EXAMINATION</u>			
PUS CELLS	01-02	2.00 - 3.00	/HPF
RBCS (RED BLOOD CELLS)	NIL	4.50 - 5.50	/HPF
EPITHELIAL CELLS	NIL		/HPF
CASTS	ABSENT	ABSENT	
CRYSTALS	ABSENT	ABSENT	

HAEMATOLOGY

ESR 12.0 0.00 - 15.00 mm at 1 hr

BLOOD GROUP ABO & RH FACTOR


Consulting Pathologist
DR. UMESH KUMAR
M.D. (General Pathology)
M.C.L. Reg. No. 11412
M.D., Pathology

Lab Technician

Timing : 24/7 hrs

This Report is not valid for medico legal purpose

Note: These tests have technical limitations. Clinico-pathological interpretation is necessary. In case of any disparity test may be repeated immediately.

Address : 36/44 FK Kabir Nagar, Durgakund, Varanasi – 221005

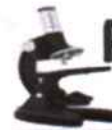Email: dramishra@gmail.com, drpallaviojha@gmail.com Website: panaceahospital.org

Facilities:

All clinical Biomedical & Hematology Investigations including Bone Marrow Examination
VPT, Podiascan & Complete Foot Care (First Time in Purvanchal)
All Hormonal Investigation by Chemiluminescent Method
Visceral Fat by (AB-140) Ambulatory BP Monitoring
CGMS & Insulin Pump Available
PFT, 2D-ECHO (Color Doppler), Holter, TMT, Cardiac-3 available
VIA, VILI, Colposcopy available
Special Endocrinological Investigation Protocols.

ISO 9001:2008 Certified

Mobile: 9389994334, 9554572190, 9453837595

**Panacea Pathology****Clinical Reference Lab**

Persistence, Preparedness and Precision
EQAS (CMC Vellore Attached) & IQAS System
पूर्वांचल की सर्वोत्तम गुणवत्ता वाली पैथोलॉजी

UHID No :- UD-23240006698 **Booking No/Date** :- 177 / 09-Mar-2024 05:50 PM
Patient Name :- Mr BRAJESH NANDAN **Age/Sex** :- 34 Y/M
Father :- SUBHASH PRASAD SINHA **OP No** :- OP-23240020563
Address :- 33 ROAD NO 13 RAJENDRA NAGAR **Mobile No** :- 8507865465
PATMA SADAR-800016, BIHAR
Consultant :- Dr Pallavi Mishra (MBBS,MD)

Investigations	Observations	Biological Ref. Interval	Unit
BLOOD GROUP	"O"		
RH FACTOR	POSITIVE		
HBA1C -(BY GOLD STANDARD METHOD :HPLC)	9.4	Normal: 4.0 - 5.4 Prediabetic : 5.5 -6.3 Diabetes mellitus := 6.4	%

BIOCHEMISTRY**LIPID PROFILE**

TOTAL CHOLESTROL	164.0	Desirable : - < 200 mg/dL Borderline: - 200 - 239 mg/dL High : - > 240mg/dL	mg/dl
TRIGLYCERIDES	159.0	35.00 - 160.00	mg/dl
HDL CHOLESTROL	39.0	35.30 - 79.50	mg/dl
LDL CHOLESTROL	93.2	<130	mg/dl
VLDL	31.80	<40	mg/dl
CHOLESTROL/ HDL RATIO	4.21	<3.0 LOW RISK, 3.0-5.0 AVG RISK, >5.0 HIGH RISK	ratio
LDL/HDL RATIO	2.39	<3	ratio
BUN	10.0	7.00 - 21.00	mg/dl
S.CREATININE	0.84	0.60 - 1.40	mg/dl
URIC ACID			
URIC ACID	3.92	3.60 - 7.70	mg/dl

Lab Technician

Consulting Pathologist
DR. UMESH KUMAR
MBBS (PATHOLOGIST)
M.D., Pathology

Timing : 24/7 hrs

This Report is not valid for medico legal purpose

Note: These tests have technical limitations. Clinico-pathological interpretation is necessary. In case of any disparity test may be repeated immediately.

Address : 36/44 FK Kabir Nagar, Durgakund, Varanasi - 221005

Email: dramishra@gmail.com, drpallaviojha@gmail.com Website: panaceahospital.org

Facilities:

All clinical Biomedical & Hematology Investigations including Bone Marrow Examination VPT, Podiascan & Complete Foot Care (First Time in Purvanchal) All Hormonal Investigation by Chemiluminescent Method Visceral Fat by (AB-140) Ambulatory BP Monitoring CGMS & Insulin Pump Available PFT, 2D-ECHO (Color Doppler), Holter, TMT, Cardiac-3 available VIA, VILI, Colposcopy available Special Endocrinological Investigation Protocols.

ISO 9001:2008 Certified
Mobile: 9389994334, 9554572190, 9453837595



Panacea Pathology

Clinical Reference Lab

Persistence, Preparedness and Precision
EQAS (CMC Vellore Attached) & IQAS System
पूर्वांचल की सर्वोत्तम गुणवत्ता वाली पैथोलॉजी

UHID No :- UD-23240006698
Patient Name :- Mr BRAJESH NANDAN
Father :- SUBHASH PRASAD SINHA
Address :- 33 ROAD NO 13 RAJENDRA NAGAR
PATMA SADAR-800016, BIHAR
Consultant :- Dr Pallavi Mishra (MBBS,MD)

Booking No/Date :- 177 / 09-Mar-2024 05:50 PM
Age/Sex :- 34 Y/M
OP No :- OP-23240020563
Mobile No :- 8507865465

Investigations	Observations	Biological Ref. Interval	Unit
YGGT	19.0	10.00 - 50.00	U/L
LFT (LIVER FUNCTION TESTS)			
TOTAL BILIRUBIN	0.68	0.00 - 1.20	mg/dl
DIRECT BILIRUBIN	0.28	0.00 - 0.30	
INDIRECT BILIRUBIN	0.40	0.20 - 0.70	mg/dl
SGOT	23.0	2.00 - 31.00	U/L
SGPT	26.0	10.00 - 45.00	U/L
ALKALINE PHOSPHATASE	83.0	25.00 - 140.00	U/L
TOTAL PROTIENS	7.24	6.60 - 8.70	g/dl
ALBUMIN	4.20	3.50 - 5.20	gm%
GLOBULIN	3.04	1.50 - 3.60	gms/dl
A/G RATIO	1.38	2:1	RATIO

IMMUNOLOGY

PSA, TOTAL	0.72	0.00 - 4.00	ng/ml
THYROID PROFILE (T3,T4,TSH)			
T3	0.88	0.60 - 1.81	ng/ml
T4	6.2	4.50 - 10.90	ug/dl

Lab Technician

Timing : 24/7 hrs

This Report is not valid for medico legal purpose

Consulting Pathologist
Dr. Umesh Kumar
MBBS, MD (PATHOLOGIST)
M.D. Reg. No. 41413

Note: These tests have technical limitations. Clinico-pathological interpretation is necessary. In case of any disparity test may be repeated immediately.

Address : 36/44 FK Kabir Nagar, Durgakund, Varanasi – 221005

Email: dramishra@gmail.com, drpallaviojha@gmail.com Website: panaceahospital.org

Facilities:

All clinical Biomedical & Hematology Investigations
 including Bone Marrow Examination
 VPT, Podiascan & Complete Foot Care (First Time in Purvanchal)
 All Hormonal Investigation by Chemiluminescent Method
 Visceral Fat by (AB-140) Ambulatory BP Monitoring
 CGMS & Insulin Pump Available
 PFT, 2D-ECHO (Color Doppler), Holter, TMT, Cardiac-3 available
 VIA, VILI, Colposcopy available
 Special Endocrinological Investigation Protocols.

ISO 9001:2008 Certified
 Mobile: 9389994334, 9554572190, 9453837595



Panacea Pathology

Clinical Reference Lab

Persistence, Preparedness and Precision
 EQAS (CMC Vellore Attached) & IQAS System
 पूर्वांचल की सर्वोत्तम गुणवत्ता वाली पैथोलॉजी

UHID No	:- UD-23240006698	Booking No/Date	:- 177 / 09-Mar-2024 05:50 PM
Patient Name	:- Mr BRAJESH NANDAN	Age/Sex	:- 34 Y/M
Father	:- SUBHASH PRASAD SINHA	OP No	:- OP-23240020563
Address	:- 33 ROAD NO 13 RAJENDRA NAGAR PATMA SADAR-800016, BIHAR	Mobile No	:- 8507865465
Consultant	:- Dr Pallavi Mishra (MBBS,MD)		

Investigations	Observations	Biological Ref. Interval	Unit
TSH	1.12	0.39 - 6.10	uIU/mL

PARASITOLOGY

STOOL ROUTINE

GROSS EXAMINATON

COLOR <i>Methology</i>	YELLOW	CLEAR YELLOW	
CONSISTANCY	NORMAL		
BLOOD	ABSENT		
MUCUS	ABSENT		
<u>MICROSCOPIC EXAMINATON</u>			
OVA OR EGGS OF HELMINTHS	ABSENT		
CYST OF PROTOZOA	ABSENT		
PUS CELLS	02-03	2.00 - 3.00	/HPF
RBC <i>Methology / Carm</i>	NIL	4.50 - 5.50	million/cumm

* END OF REPORT *

Lab Technician

Consulting Pathologist
 DR. UMESH KUMAR
 MBBS, MD (PATHOLOGIST)
 MCh, Reg. Pathology

Timing : 24/7 hrs

This Report is not valid for medico legal purpose

Note: These tests have technical limitations. Clinico-pathological interpretation is necessary. In case of any disparity test may be repeated immediately.

Address : 36/44 FK Kabir Nagar, Durgakund, Varanasi – 221005

Email: dramishra@gmail.com, drpallaviojha@gmail.com Website: panaceahospital.org



PANACEA HOSPITAL



A shelter for many hearts A Home for many lives

(An ISO 9001:2008 Certified Organisation)
Lab Attached with CMC Under EQAS Scheme

Dept. of Radiodiagnosis - 32 Slice CT Scan, 3D/4D USG, 2D ECHO, Colour Doppler, Intervention Procedures, Digital X-Ray

PATIENT'S NAME	: BRAJESH NANDAN	AGE ³⁴ Y/SEX:M
REF. BY	: Dr. ASHUTOSH MISHRA(MD)	DATE:09/03/2024

X-RAY CHEST (PA VIEW)

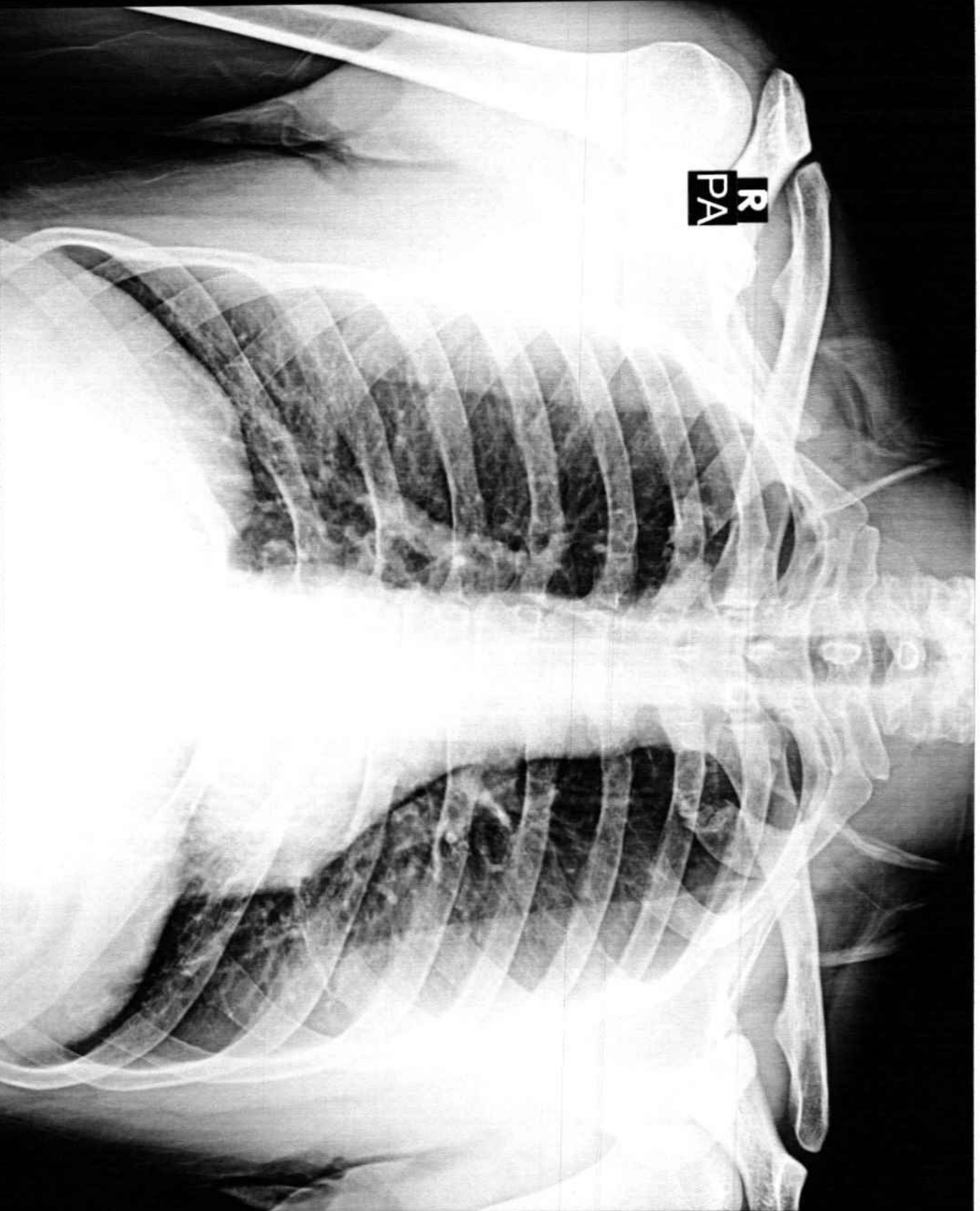
- Bilateral lung fields appear normal.
- Trachea and mediastinum appear normal in position.
- Both hila appear normal in size and are symmetrical.
- Transverse cardiac diameter is within normal limits.
- Great vessels appear normal
- Both CP angles appear clear. Normal position and contour diaphragms noted.
- Bony rib cage and soft tissue shadows appear normal.

IMPRESSION

- **No obvious abnormality noted in the chest radiograph.**

Thanks for reference.

Radiologist
Dr. Rahul Kumar Tiwari
MBBS, MD (Radio Diagonosis)
Reg. No. 57557



BRAJESH NANDAN Y/M 6698 M CHEST P.A. 09-Mar-24 10:35 AM

PANACEA HOSPITAL, KABIR NAGAR, DURGAKUND, VARANASI



PANACEA HOSPITAL



A shelter for many hearts A Home for many lives

(An ISO 9001:2008 Certified Organisation)
Lab Attached with CMC Under EQAS Scheme

Dept. of Radiodiagnosis - 32 Slice CT Scan, 3D/4D USG, 2D ECHO, Colour Doppler, Intervention Procedures, Digital X-Ray

NAME: BRAJESH NANDAN
REF.DR. DR.ASHUTOSH MISHRA(MD)

AGE/SEX: 34 YRS/MALE
DATE: 09/03/2024

ULTRA SOUND WHOLE ABDOMEN REPORT

Liver: Normal in size(11.9cm), shape & echogenicity. Intra & extra hepatic biliary Radicals & Vascular structures are normal. Margins are smooth and regular.

Gall bladder: Normally distended with echo free lumen.

Portal vein: Normal in course and caliber.

CBD diameter: Visualized part normal in course & caliber.

Pancreas: Normal in size, shape & echogenicity. Margins are smooth & regular. No diffuse/ focal lesion seen. Pancreatic duct not visualized.

Spleen: Normal in size, shape & echogenicity. Margins are smooth & regular. No diffuse / focal lesion seen. Splenic vessels at hilum is normal.

Kidney: Both normal in size, shape echogenicity & position. Cortical-medullary differentiation is maintained. Pelvicalyceal system normal. No evidence of any calculus/mass lesion seen. No hydronephrosis/ hydroureter seen. No suprarenal mass lesion.

Urinary bladder: Normally distended with normal wall thickness. No echogenic foci lumen or diverticula seen. Both VUJ appears normal. No evidence of calculus / mass lesion seen.

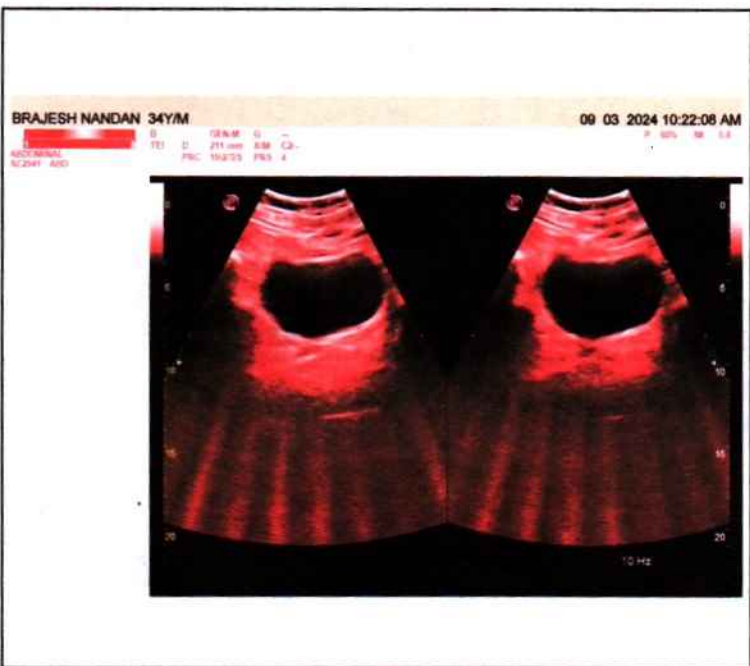
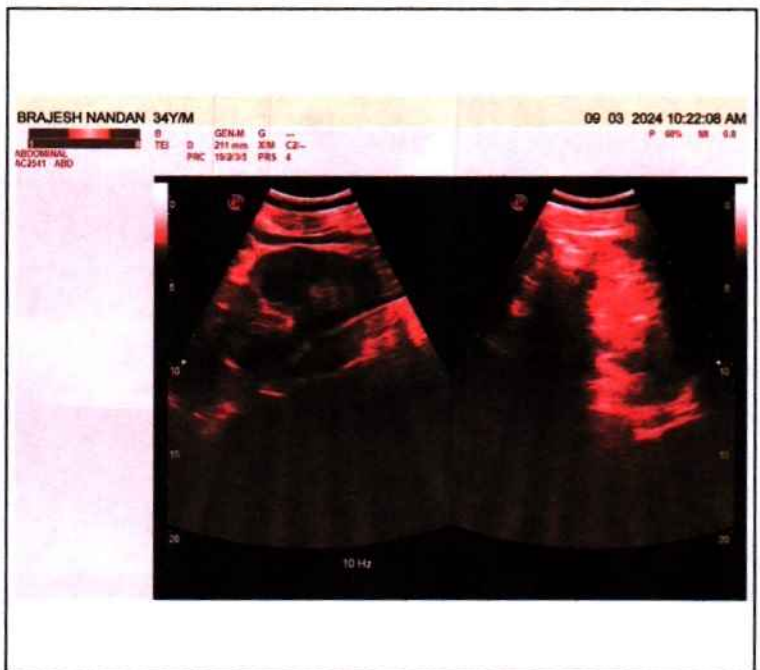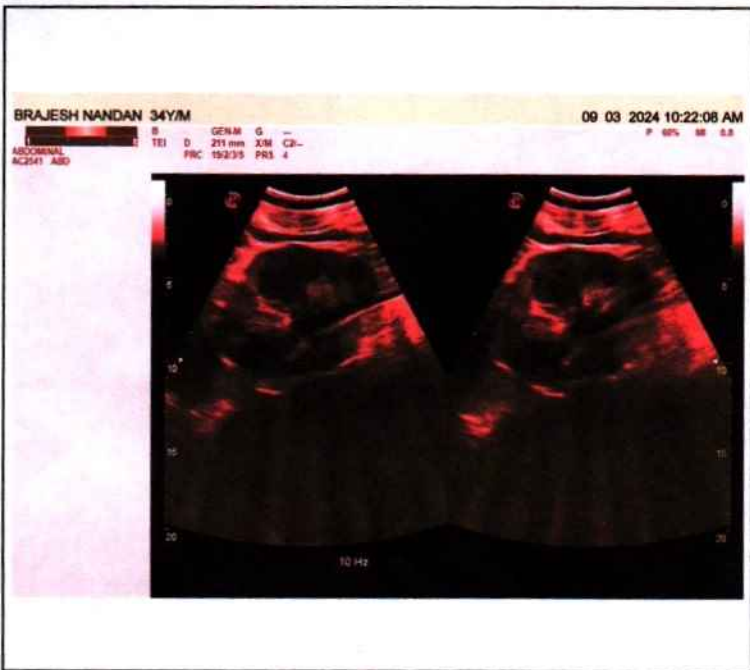
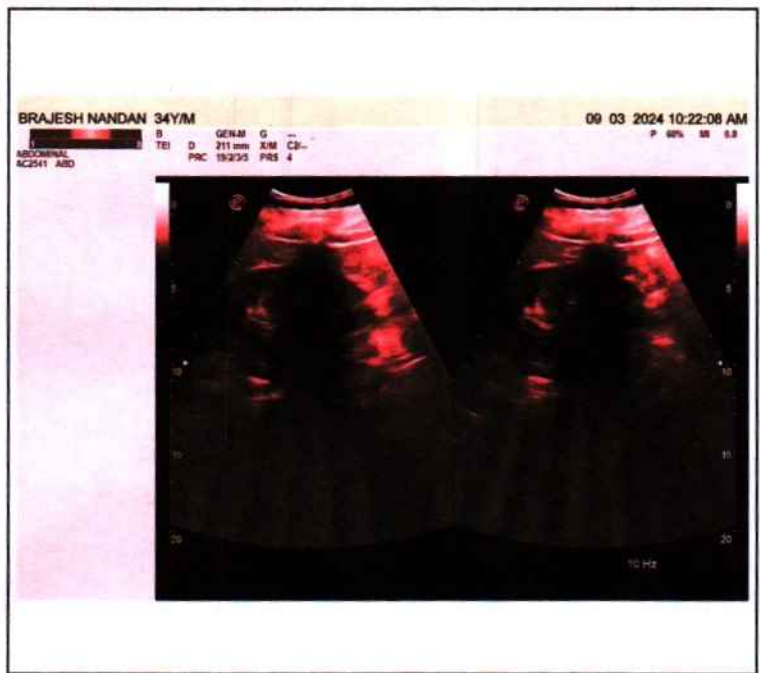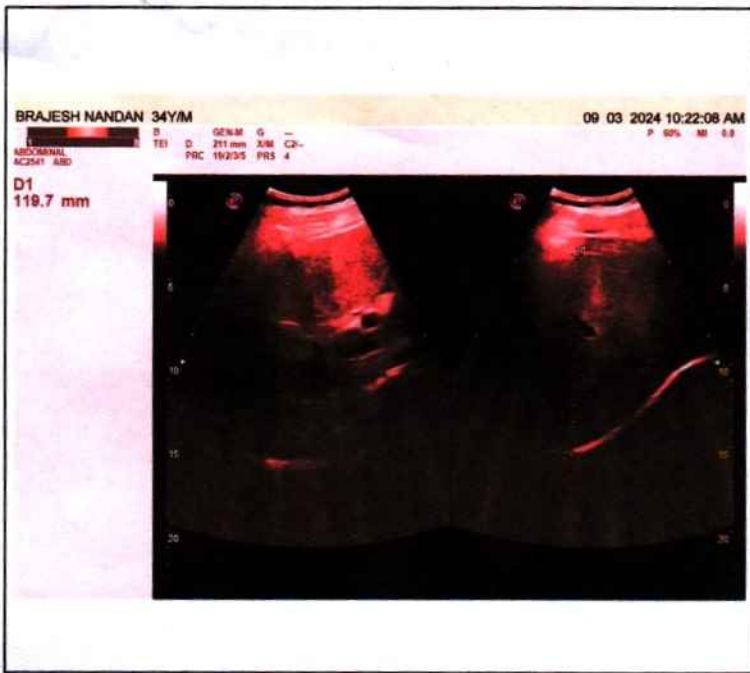
Prostate: Normal in size, shape & echogenicity.

Others: No free fluid in peritoneal cavity.
No free fluid in bilateral pleural cavity.
No evidence of significantly enlarged retroperitoneal/ mesenteric lymph nodes noted.

IMPRESSION: - **NO OBVIOUS SONOLOGICAL ABNORMALITY SEEN.**

Please correlate clinically and further investigations.


Radiologist
Dr. Rahul Kumar Tiwari
MBBS, MD (Radio Diagonosis)
Reg. No. 57557





PANACEA HOSPITAL



A shelter for many hearts A Home for many lives
(An ISO 9001:2008 Certified Organisation)
Lab Attached with CMC Under EQAS Scheme

Dept. of Radiodiagnosis - 32 Slice CT Scan, 3D/4D USG, 2D ECHO, Colour Doppler, Intervention Procedures, Digital X-Ray

PATIENT'S NAME : BRAJESH NANDAN **AGE/SEX: 34 Y/M**
REF. BY : Dr. ASHUTOSH MISHRA (MD) **Saturday, March 09, 2024**

Echo - Cardiography

MITRAL VALVE Doppler	AML - normal morphology MV Flow - E - 0.5 A-0.5 E/A=1.15	PML - normal morphology MVA - 3.0 cm ² Mitral Regurgitation - No
TRICUSPID VALVE Doppler	Normal TV Flow -No	Tricuspid Regurgitation -No
PULMONARY VALVE Doppler	Normal PV Flow -No	Pulmonary Regurgitation - No
AORTIC VALVE Doppler	Trileaflet-No AV Flow - no	Aortic Regurgitation - no
MEASUREMENT	Aorta - 27.4 (20-38) mm IVS ed - 8.0 (6 -12) mm LVID ed -38.8 (35 - 55) mm LVPW ed - 11.4 (6 -12) mm OA - 7 (> 5) mm	LA - 28.6 (24-32) mm IVS es -14.8 (6 - 12) mm LVID es - 26.8 (24 - 40) mm LVPW es -14.8 (6 -12) mm EPSS - 4 (< 9) mm

CONCLUSION All cardiac chamber dimensions are WNL
No valvular abnormalities
Good LV systolic function present Modified Simpson's method (4C, 2C) (LVEF=61%)
No diastolic dysfunction present (E/A = 1.15)
No RWMA
No pericardial effusion
Intact IAS / IV
No PAH
No intra cardiac mass /thrombus /vegetation

IMPRESSION **Normal Echocardiogram**

Nishi Mishra
Nishi Mishra
Physician Assistant
(DURE)

Pallavi Mishra
Dr. Pallavi Mishra
MBBS, MD (Gen Med) Lucknow
MBBS, MD (GENERAL MEDICINE)
Non Invasive cardiologist
Women Cardiologist
MCI Reg. No. 52033
Diabetocardiologist

Disclaimer: This report is not valid for Madicolegal or Judicial Purpose. Radiological diagnosis is solely interpretation of images produced by tissue & may not be always conclusive.

Address : B36/44 B4 Kabir Nagar (Near Sanjay Shiksha Niketan), Durgakund, Varanasi
Mobile : 9554572190 / 9453837595 / Recpn, 9389994334
Email : dramishra@gmail.com, drpallaviojha@gmail.com, Website : www.piire.org

