

Name : Mr. HARISHA D K

Age: 39 Y

UHID:CANN.0000124496

Sex: M

Address : DODDAHARAVE VILLAGGE 2ND BLOCK BYLAKUPPE
POST



Plan : ARCOFEMI MEDIWHEEL MALE AHC CREDIT PAN
INDIA OP AGREEMENT

OP Number:CELEOPV333753

Bill No :CELE-OCR-54375

Date : 26.01.2024 09:35

Sno	Service Type/ServiceName	Department
1	ARCOFEMI - MEDIWHEEL - FULL BODY ANNUAL PLUS MALE - 2D ECHO - PAN INDIA - FY2324	
1	GAMMA GLUTAMYL TRANSFERASE (GGT)	
2	D ECHO -12	
3	LIVER FUNCTION TEST (LFT) -11	
4	GLUCOSE, FASTING	
5	HEMOGRAM + PERIPHERAL SMEAR	
6	DIET CONSULTATION	
7	COMPLETE URINE EXAMINATION <i>pending</i>	
8	URINE GLUCOSE (POST PRANDIAL)	
9	PERIPHERAL SMEAR	
10	ECG	
11	RENAL PROFILE/RENAL FUNCTION TEST (RFT/KFT) -13	
12	DENTAL CONSULTATION -15	
13	GLUCOSE, POST PRANDIAL (PP), 2 HOURS (POST MEAL)	
14	URINE GLUCOSE (FASTING)	
15	HbA1c, GLYCATED HEMOGLOBIN	
16	X-RAY CHEST PA -09	
17	ENT CONSULTATION	
18	FITNESS BY GENERAL PHYSICIAN -06	
19	BLOOD GROUP ABO AND RH FACTOR <i>pending</i>	
20	LIPID PROFILE	
21	BODY MASS INDEX (BMI)	
22	OPHTHAL BY GENERAL PHYSICIAN -05	
23	ULTRASOUND - WHOLE ABDOMEN	
24	THYROID PROFILE (TOTAL T3, TOTAL T4, TSH) -08	

DATE:

NAME:

AGE/SEX:

UHID:

CHIEF COMPLAINTS:

PAST/FAMILY HISTORY:

ALLERGIES:

GENERAL EXAMINATION:

PULSE: 106	BP: 133/87	TEMP:	RR:
HT: 166	WT: 73.2	WAIST: 98	BMI: 26.5

HIP: 103

Vision	Rt	Lt	With Correction
DISTANT	6/6	6/6	-
NEAR	N6	N6	-
COLOUR	N	N	normal

SYSTEMIC EXAMINATION

Chest:

Cvs:

P/A:

IMPRESSION:

FINAL RECOMMENDATION:

GENERAL PHYSICIAN

NAME:	Mr. HARISHA D K
AGE / SEX:	39YRS/ MALE
DATE:	26/01/2024
REFERRED BY:	ARCOFEMI HEALTHCARE

ABDOMINAL ULTRASONOGRAPHY REPORT

LIVER: appear normal in size and echogenicity. No focal lesion seen. The intra hepatic biliary and portal venous radicals are normal. Portal vein and CBD is normal

GALL BLADDER: moderately distended and appears normal. No abnormal wall thickening / pericholecystic fluid seen.

PANCREAS: Normal to the extent visualized.

SPLEEN: normal in size and echo texture. No focal lesion noted.

KIDNEYS: Both kidneys are normal in size and echo texture. Normal cortico-medullary differentiation is maintained. No calculus / hydronephrosis on both sides.

PELVIC ORGANS:

Urinary bladder is moderately distended and appears normal.

Prostate appear normal in size and echogenicity.

No free fluid in the abdomen and pelvis.

IMPRESSION:

- *No definitive sonological abnormality seen in present scan.*

*To correlate clinically & with other investigations.
Not for medico-legal purpose*



DR. VIGNESH K

CONSULTANT RADIOLOGIST

Apollo Health and Lifestyle Limited

(CIN - U85110TG2000PLC115819)

Regd. Office: 1-10-60/62, Ashoka Raghupathi Chambers, 5th Floor, Begumpet, Hyderabad, Telangana - 500 016.

Ph No: 040-4904 7777, Fax No: 4904 7744 | Email ID: enquiry@apollohl.com | www.apollohl.com

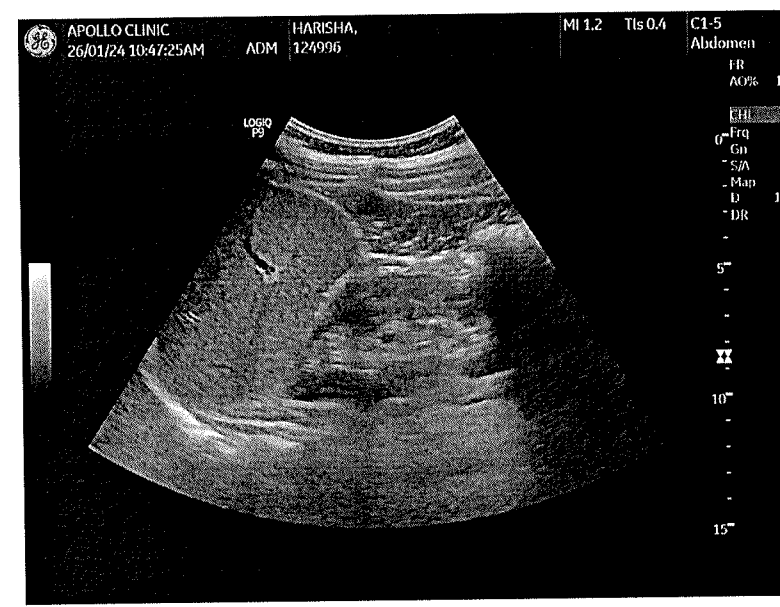
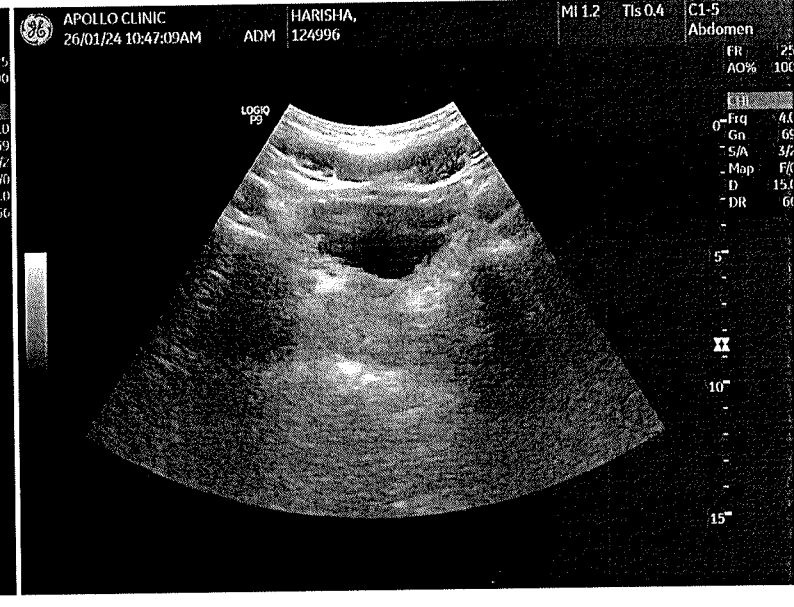
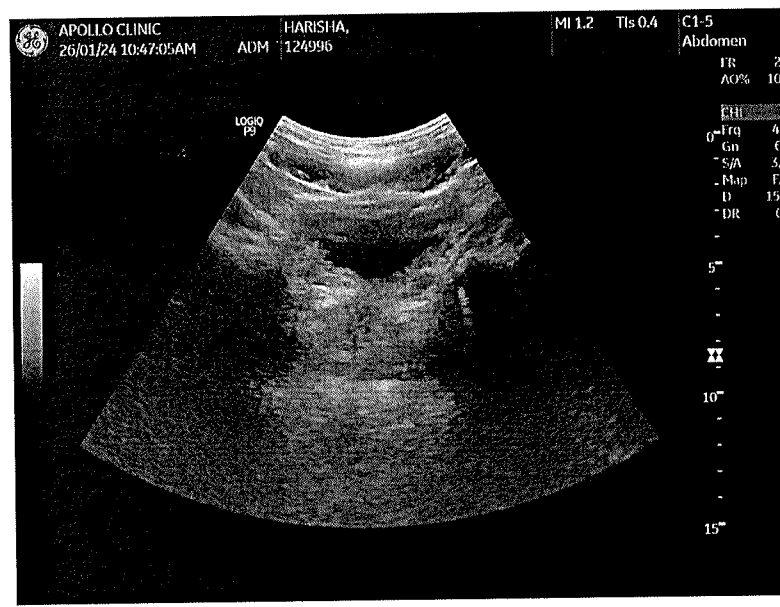
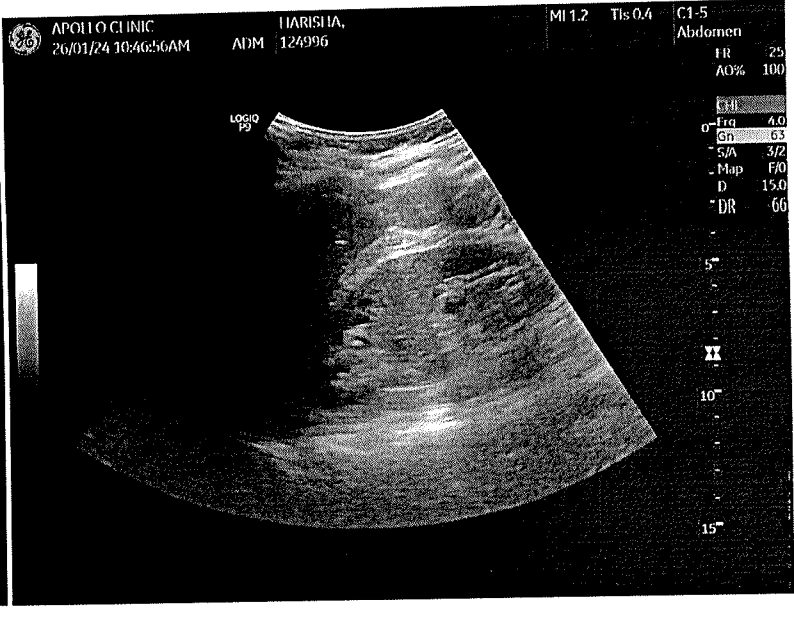
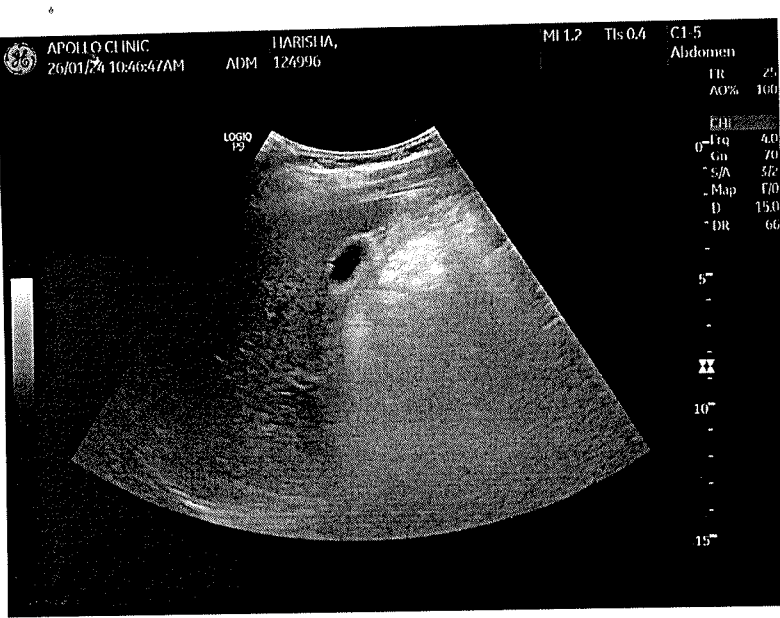
APOLLO CLINICS NETWORK KARNATAKA

Bangalore (Basavanagudi | Bellandur | Electronic City | Fraser Town | HSR Layout | Indira Nagar | JP Nagar | Kundalahalli | Koramangala | Sarjapur Road) **Mysore** (VV Mohalla)

Online appointments: www.apolloclinic.com

TO BOOK AN APPOINTMENT

 **1860 500 7788**



2-D ECHO-CARDIOGRAPHY DOPPLER & COLOUR DOPPLER REPORT

NAME : MR HARISHA D K

DATE : 26/01/2024

AGE/SEX:39Y / M

REF ;ARCOFEMI

UHID:124496

*** MEASUREMENTS & FLOW VELOCITIES AS DEPICTED IN IMAGES OVERLEAF.

SUB OPTIMAL ECHO WINDOW

1. NORMAL VALVES.
2. NORMAL FLOW ACROSS ALL VALVES.
3. NO MR/ AR/ TR.
4. NORMAL GREAT VESSELS.
5. NORMAL SYSTEMIC VEINS & AT LEAST 3 PULMONARY VEINS SEEN DRAINING INTO LA.
6. NORMAL SIZED CHAMBERS.
7. NO REGIONAL WALL MOTION ABNORMALITIES.
8. INTACT SEPTAE (IVS & IAS).
9. GOOD LV & RV SYSTOLIC FUNCTION.LVEF 60%
10. PERICARDIUM : NORMAL
11. NO OBVIOUS VEGETATION / CLOTS.



DR. DAYANAND YALIGAR

Cardiologist

To correlate with clinical findings & other relevant investigations .

Apollo Health and Lifestyle Limited

(CIN - U85110TG2000PLC115819)

Regd. Office: 1-10-60/62, Ashoka Raghupathi Chambers, 5th Floor, Begumpet, Hyderabad, Telangana - 500 016.

Ph No: 040-4904 7777, Fax No: 4904 7744 | Email ID: enquiry@apollohl.com | www.apollohl.com

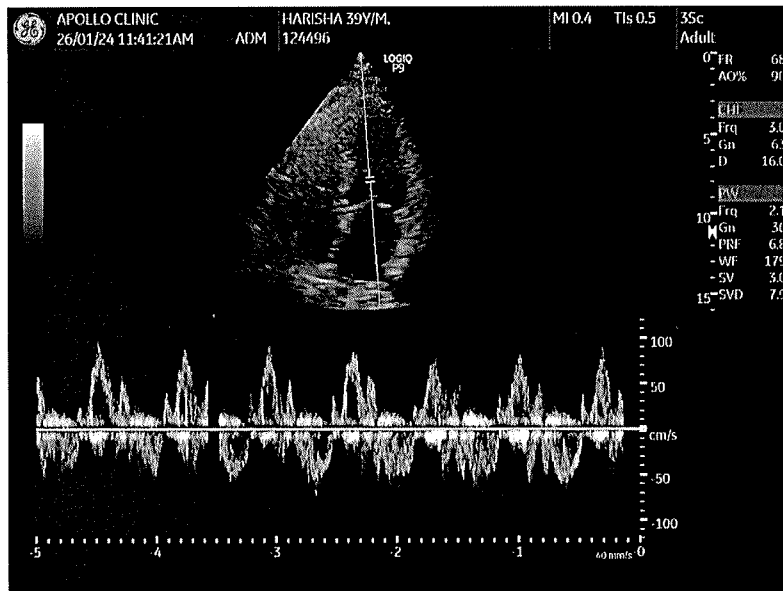
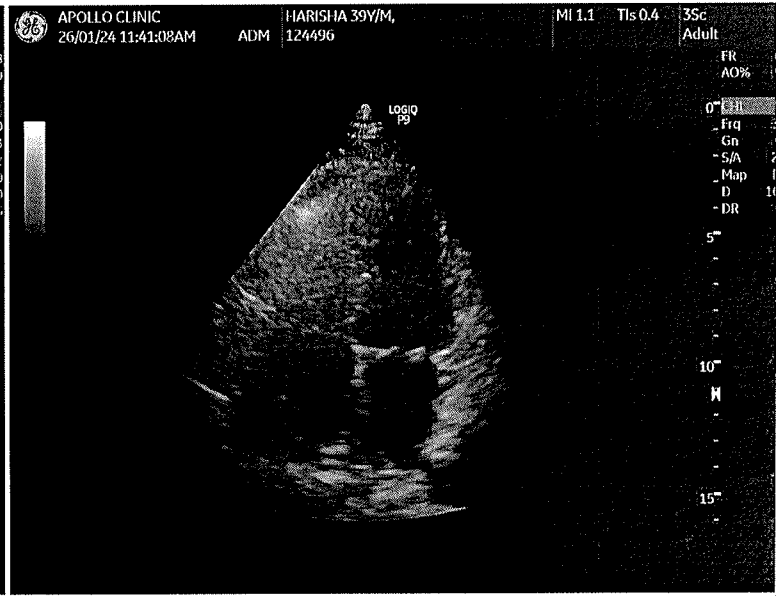
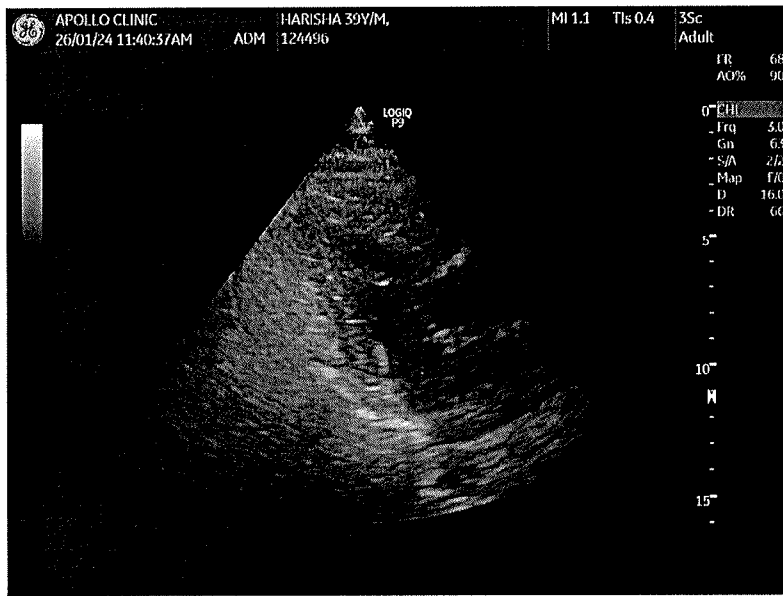
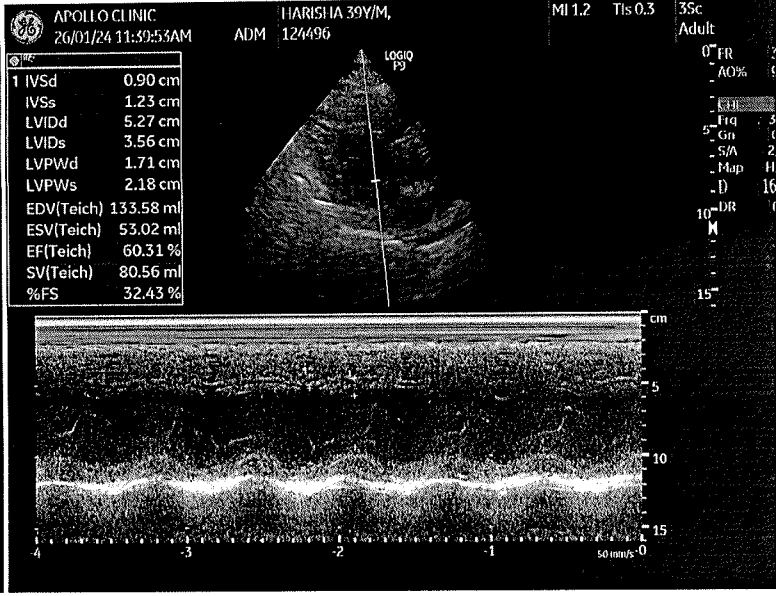
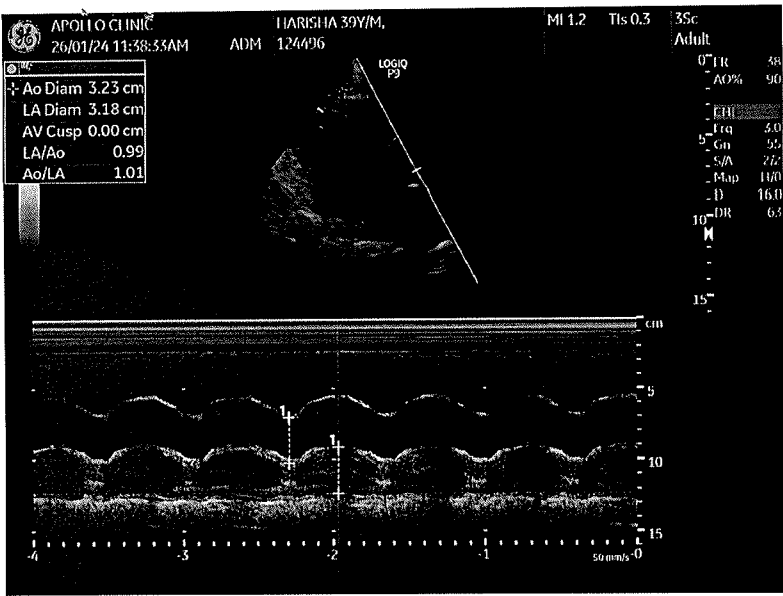
APOLLO CLINICS NETWORK KARNATAKA

Bangalore (Basavanagudi | Bellandur | Electronic City | Fraser Town | HSR Layout | Indira Nagar | JP Nagar | Kundalahalli | Koramangala | Sarjapur Road) **Mysore** (VV Mohalla)

Online appointments: www.apolloclinic.com

TO BOOK AN APPOINTMENT

 **1860 500 7788**



Patient Name : Mr. HARISHA D K
UHID : CANN.0000124496
Reported on : 26-01-2024 16:29
Adm/Consult Doctor :

Age : 39 Y M
OP Visit No : CELEOPV333753
Printed on : 26-01-2024 16:29
Ref Doctor : SELF

DEPARTMENT OF RADIOLOGY

X-RAY CHEST PA

Both lung fields and hila are normal .

No obvious active pleuro-parenchymal lesion seen .

Both costophrenic and cardiophrenic angles are clear .

Both diaphragms are normal in position and contour .


Thoracic wall and soft tissues appear normal.

CONCLUSION :

No obvious abnormality seen

Printed on:26-01-2024 16:29

---End of the Report---



Dr. VIGNESH K
MBBS, MD Radio-Diagnosis
Radiology

Apollo Health and Lifestyle Limited

(CIN - U85110TG2000PLC115819)

Regd. Office: 1-10-60/62, Ashoka Raghupathi Chambers, 5th Floor, Begumpet, Hyderabad, Telangana - 500 016.

Ph No: 040-4904 7777, Fax No: 4904 7744 | Email ID: enquiry@apollohl.com | www.apollohl.com

APOLLO CLINICS NETWORK KARNATAKA

Bangalore (Basavanagudi | Bellandur | Electronic City | Fraser Town | HSR Layout | Indira Nagar | JP Nagar | Kundalahalli | Koramangala | Sarjapur Road) **Mysore** (VV Mohalla)

Online appointments: www.apolloclinic.com

TO BOOK AN APPOINTMENT

 **1860 500 7788**

Authorized by
Yogesh

Dr. Yogesh Kothari
MD, DNB, FESC, FEP
Reg No- KMC, 44065

Interpretation

Sinus Rhythm Regular
Normal Axis

Measurements

HR : 97 BPM
PR : 170 ms
PD : 138 ms
QRS : 107 ms
QRS Axis : 75 deg
QT/QTc : 346/440 ms

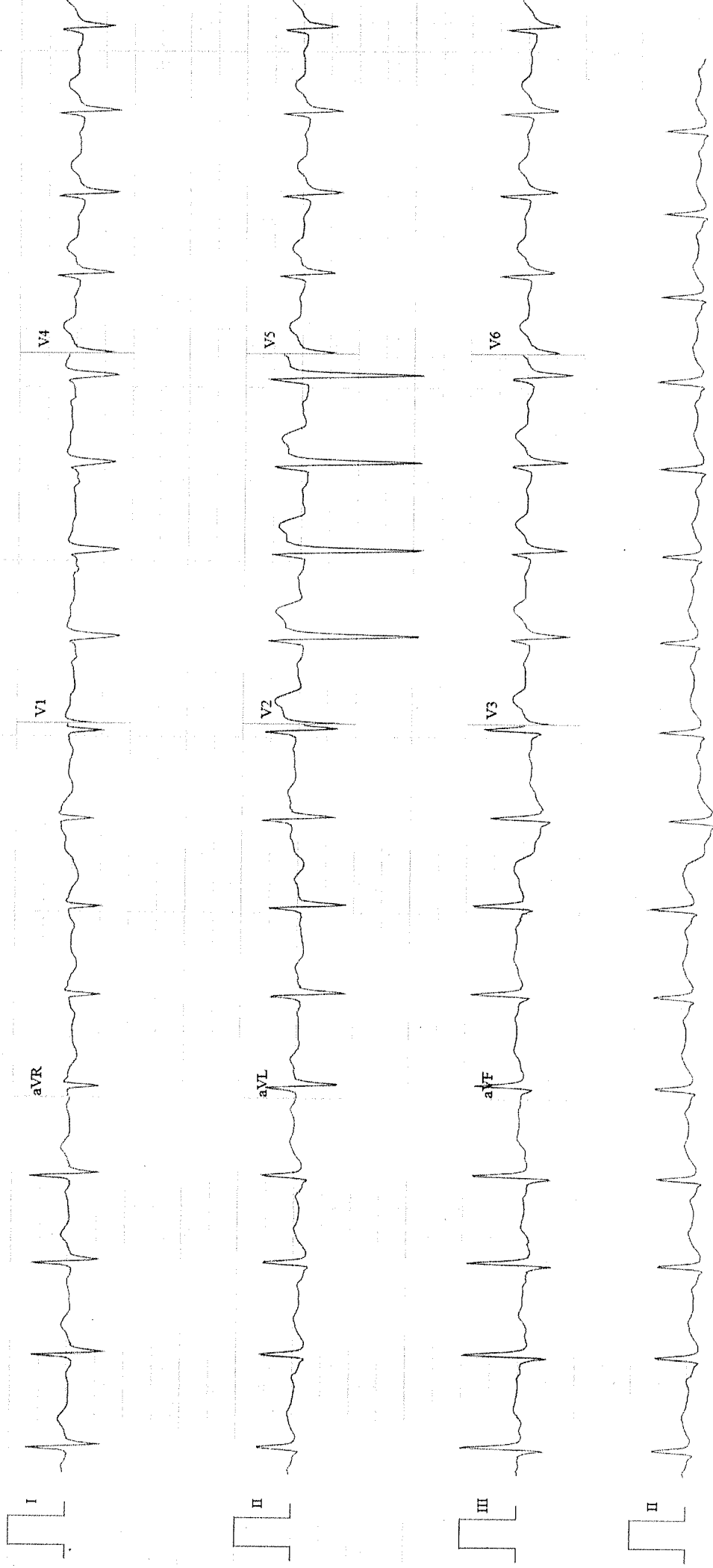
Vitals

Symptoms

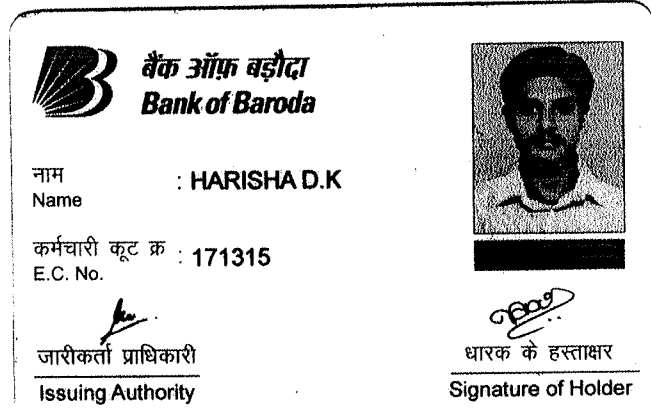

Pre-Existing Medical Conditions

Date: IST: 2024-01-26 11:57:19
Personal Details
UHID: 00XHEIPU6S80X5C
PatientID: 124496
Name: Mr. Harisha D k
Age: 39
Gender: Male
Mobile: 7795779663

This trace is generated by **KardiaScreen: Cloud-Connected, Portable, Digital, 6-12 Lead Scalable ECG Platform from IMEDRIX**



Speed: 25 mm/sec F: 0.05 - 40 Hz Limb: 10 mm/mV Chest: 10 mm/mV
Disclaimer: Analysis in this report is based on ECG alone and should be used as an adjunct to clinical history and should not be interpreted by a qualified physician. Normal ECG does not rule out heart disease. Abnormal ECG does not always mean severe heart disease. Contraindications & warnings based on available data. Limit of resolution is 100µV.



**Fwd: Health Check up Booking Confirmed Request(bobE6529),Package Code-
PKG10000366, Beneficiary Code-246982**

harish dk <harishadk001@gmail.com>

Fri 2024-01-26 9:27 AM

To: Electronic City <ecity@apolloclinic.com>

----- Forwarded message -----

From: **Mediwheel** <wellness@mediwheel.in>

Date: Thu, Jan 25, 2024, 2:45 PM

Subject: Health Check up Booking Confirmed Request(bobE6529),Package Code-
PKG10000366, Beneficiary Code-246982

To: <harishadk001@gmail.com>

Cc: <customercare@mediwheel.in>

011-41195959

Dear **Harisha D K**,

We are pleased to confirm your health checkup booking request with the following details.

Booking Date : 25-01-2024
Hospital Package Name : Mediwheel Full Body Annual Plus
Patient Package Name : Mediwheel Full Body Health Checkup Male Below 40
Name of Diagnostic/Hospital : Apollo Clinic
Address of Diagnostic/Hospital : Apollo Clinic, 323/100, Opp.Ajmera infinity Apartment, Neeladri Nagar, Electronic city Phase -1, Electronic city - 560100
City : Bangalore
State :
Pincode : 560100
Appointment Date : 26-01-2024
Confirmation Status : Booking Confirmed
Preferred Time : 8:30am
Booking Status : Booking Confirmed