

Patient Name : Mr.SREEJITH M H	Collected : 09/Nov/2024 09:47AM
Age/Gender : 34 Y 5 M 18 D/M	Received : 09/Nov/2024 11:59AM
UHID/MR No : CIND.0000173155	Reported : 09/Nov/2024 03:02PM
Visit ID : CINDOPV244842	Status : Final Report
Ref Doctor : Self	Sponsor Name : ARCOFEMI HEALTHCARE LIMITED
Emp/Auth/TPA ID : 22S36983	

DEPARTMENT OF HAEMATOLOGY

ARCOFEMI - MEDIWHEEL - FULL BODY ANNUAL PLUS MALE - 2D ECHO - PAN INDIA - FY2324

PLATELETS: appear adequate in number.

HEMOPARASITES: negative

IMPRESSION: MICROCYTIC HYPOCHROMIC BLOOD PICTURE

Note: Kindly evaluate for incipient iron deficiency status/hemoglobinopathy.

Dr. Vidya Aniket Gore
M.B.B.S,M.D(Pathology)
Consultant Pathologist

Dr Priya Murthy
M.B.B.S,M.D(Pathology)
Consultant Pathologist



Patient Name : Mr.SREEJITH M H	Collected : 09/Nov/2024 09:47AM
Age/Gender : 34 Y 5 M 18 D/M	Received : 09/Nov/2024 11:59AM
UHID/MR No : CIND.0000173155	Reported : 09/Nov/2024 02:57PM
Visit ID : CINDOPV244842	Status : Final Report
Ref Doctor : Self	Sponsor Name : ARCOFEMI HEALTHCARE LIMITED
Emp/Auth/TPA ID : 22S36983	


DEPARTMENT OF HAEMATOLOGY

ARCOFEMI - MEDIWHEEL - FULL BODY ANNUAL PLUS MALE - 2D ECHO - PAN INDIA - FY2324

Test Name	Result	Unit	Bio. Ref. Interval	Method
BLOOD GROUP ABO AND RH FACTOR , WHOLE BLOOD EDTA				
BLOOD GROUP TYPE	B			Microplate Hemagglutination
Rh TYPE	Positive			Microplate Hemagglutination



Dr. Vidya Aniket Gore
M.B.B.S,M.D(Pathology)
Consultant Pathologist



Dr Priya Murthy
M.B.B.S,M.D(Pathology)
Consultant Pathologist



Patient Name : Mr.SREEJITH M H	Collected : 09/Nov/2024 09:47AM
Age/Gender : 34 Y 5 M 18 D/M	Received : 09/Nov/2024 03:16PM
UHID/MR No : CIND.0000173155	Reported : 09/Nov/2024 03:40PM
Visit ID : CINDOPV244842	Status : Final Report
Ref Doctor : Self	Sponsor Name : ARCOFEMI HEALTHCARE LIMITED
Emp/Auth/TPA ID : 22S36983	

DEPARTMENT OF CLINICAL PATHOLOGY

ARCOFEMI - MEDIWHEEL - FULL BODY ANNUAL PLUS MALE - 2D ECHO - PAN INDIA - FY2324


Test Name	Result	Unit	Bio. Ref. Interval	Method
COMPLETE URINE EXAMINATION (CUE) , URINE				
PHYSICAL EXAMINATION				
COLOUR	YELLOW		PALE YELLOW	Visual
TRANSPARENCY	CLEAR		CLEAR	Physical Measurement
pH	5.5		5-7.5	Double Indicator
SP. GRAVITY	1.025		1.002-1.030	Bromothymol Blue
BIOCHEMICAL EXAMINATION				
URINE PROTEIN	NEGATIVE		NEGATIVE	Protein Error Of Indicator
GLUCOSE	NEGATIVE		NEGATIVE	Glucose Oxidase
URINE BILIRUBIN	NEGATIVE		NEGATIVE	Azo Coupling Reaction
URINE KETONES (RANDOM)	NEGATIVE		NEGATIVE	Sodium Nitro Prusside
UROBILINOGEN	NORMAL		NORMAL	Modified Ehrlich Reaction
NITRITE	NEGATIVE		NEGATIVE	Diazotization
LEUCOCYTE ESTERASE	NEGATIVE		NEGATIVE	Leucocyte Esterase
CENTRIFUGED SEDIMENT WET MOUNT AND MICROSCOPY				
PUS CELLS	2-3	/hpf	0-5	Microscopy
EPITHELIAL CELLS	1-2	/hpf	<10	Microscopy
RBC	NIL	/hpf	0-2	Microscopy
CASTS	NIL		0-2 Hyaline Cast	Microscopy
CRYSTALS	ABSENT		ABSENT	Microscopy

Comment:

All urine samples are checked for adequacy and suitability before examination. All abnormal chemical examination are rechecked and verified by manual methods. Microscopy findings are reported as an average of 10 high power fields.



Dr. Vidya Aniket Gore
M.B.B.S,M.D(Pathology)
Consultant Pathologist



Dr Priya Murthy
M.B.B.S,M.D(Pathology)
Consultant Pathologist




Patient Name : Mr.SREEJITH M H	Collected : 09/Nov/2024 09:47AM
Age/Gender : 34 Y 5 M 18 D/M	Received : 09/Nov/2024 05:50PM
UHID/MR No : CIND.0000173155	Reported : 09/Nov/2024 06:47PM
Visit ID : CINDOPV244842	Status : Final Report
Ref Doctor : Self	Sponsor Name : ARCOFEMI HEALTHCARE LIMITED
Emp/Auth/TPA ID : 22S36983	

DEPARTMENT OF CLINICAL PATHOLOGY

ARCOFEMI - MEDIWHEEL - FULL BODY ANNUAL PLUS MALE - 2D ECHO - PAN INDIA - FY2324

Test Name	Result	Unit	Bio. Ref. Interval	Method
URINE GLUCOSE(POST PRANDIAL)	NEGATIVE		NEGATIVE	GOD-POD



Dr. Rajalakshmi D
M.B.B.S,M.D
Consultant Pathologist



Dr. Vidya Aniket Gore
M.B.B.S,M.D(Pathology)
Consultant Pathologist



Patient Name : Mr.SREEJITH M H	Collected : 09/Nov/2024 09:47AM
Age/Gender : 34 Y 5 M 18 D/M	Received : 09/Nov/2024 03:16PM
UHID/MR No : CIND.0000173155	Reported : 09/Nov/2024 03:40PM
Visit ID : CINDOPV244842	Status : Final Report
Ref Doctor : Self	Sponsor Name : ARCOFEMI HEALTHCARE LIMITED
Emp/Auth/TPA ID : 22S36983	

DEPARTMENT OF CLINICAL PATHOLOGY

ARCOFEMI - MEDIWHEEL - FULL BODY ANNUAL PLUS MALE - 2D ECHO - PAN INDIA - FY2324


Test Name	Result	Unit	Bio. Ref. Interval	Method
URINE GLUCOSE(FASTING)	NEGATIVE		NEGATIVE	GOD-POD

*** End Of Report ***

Result/s to Follow:
PERIPHERAL SMEAR



Dr. Vidya Aniket Gore
M.B.B.S,M.D(Pathology)
Consultant Pathologist



Dr Priya Murthy
M.B.B.S,M.D(Pathology)
Consultant Pathologist



Patient Name	: Mr. Sreejith M H	Age	: 34Yrs 5Mths 19Days
UHID	: CIND.0000173155	OP Visit No.	: CINDOPV244842
Printed On	: 09-11-2024 08:47 AM	Advised/Pres Doctor	: --
Department	: Radiology	Qualification	: --
Referred By	: Self	Registration No.	: --
Employer Id	: 22S36983		

DEPARTMENT OF RADIOLOGY

ULTRASOUND ABDOMEN AND PELVIS

LIVER: Appears normal in size, shape and echopattern. No focal parenchymal lesions identified. No evidence of intra/extrahepatic biliary tree dilatation noted. Portal vein appears to be of normal size.

GALLBLADDER: Moderately distended. No definite calculi identified. No evidence of abnormal wall thickening noted.

SPLEEN: Appears normal in size, shape and echopattern. No focal parenchymal lesions identified.

PANCREAS: Obscured by bowel gas. However, the visualized portion appear normal.

KIDNEYS: Both kidneys appear normal in size, shape and echopattern. Corticomedullary differentiation appears maintained. No evidence of calculi or hydronephrosis on either side.

URINARY BLADDER: Distended and appears normal. No evidence of abnormal wall thickening noted.

PROSTATE: Prostate is normal in size and echo-pattern.

No free fluid or lymphadenopathy is seen.

IMPRESSION:

NO SIGNIFICANT SONOGRAPHIC ABNORMALITY DETECTED.

---End Of The Report---



Dr.DHANALAKSHMI B
MBBS, DMRD
29543
Radiology

Patient Name	: Mr. Sreejith M H	Age	: 34Yrs 5Mths 19Days
UHID	: CIND.0000173155	OP Visit No.	: CINDOPV244842
Printed On	: 09-11-2024 11:59 AM	Advised/Pres Doctor	: --
Department	: Radiology	Qualification	: --
Referred By	: Self	Registration No.	: --
Employer Id	: 22S36983		

DEPARTMENT OF RADIOLOGY

X-RAY CHEST PA VIEW

Both lung fields and hila are normal .

No obvious active pleuro-parenchymal lesion seen .

Both costophrenic and cardiophrenic angles are clear .

Both diaphragms are normal in position and contour .

Thoracic wall and soft tissues appear normal.

CONCLUSION :

No obvious abnormality seen

For clinical correlation.

---End Of The Report---



Dr.DHANALAKSHMI B
MBBS, DMRD
29543
Radiology

Patient Name	: Mr. Sreejith M H	Age	: 34Yrs 5Mths 21Days
UHID	: CIND.0000173155	OP Visit No.	: CINDOPV244842
Printed On	: 11-11-2024 11:48 AM	Advised/Pres Doctor	: --
Department	: Cardiology	Qualification	: --
Referred By	: Self	Registration No.	: --
Employer Id	: 22S36983		

DEPARTMENT OF CARDIOLOGY

M mode and doppler measurements:

CM CM M/sec

AO: 2.2 IVS(D): 0.8 MV: E Vel: 1.0 A Vel : 0.5

LA: 2.5 LVIDD(D): 3.8 AV Peak: 0.7

LVPW(D): 0.8 PV peak: 0.9

IVS(S): 1.1

LVID(S): 2.6

LVPW(S): 1.2

LVEF: 60%

Descriptive findings:

Left Ventricle Normal

Right Ventricle: Normal

Left Atrium: Normal

Right Atrium: Normal

Mitral Valve: Normal

Aortic Valve: Normal

Tricuspid Valve: Normal

IAS: Normal

IVS:	Normal
Pericardium:	Normal
IVC:	Normal
Others	---

IMPRESSION :

Normal cardiac chamber and valves
No Regional wall motion abnormality
Normal PA pressure
No clot/vegetation/pericardial effusion
Normal LV systolic function - LVEF= 60%


DR JAGADEESH H V MD,DM
CONSULTANT CARDIOLOGIST

---End Of The Report---



Dr.JAGADEESH H V

MBBS, MD, DM
86848
Cardiology



Patient Name	: Mr. Sreejith M H	Age	: 34Yrs 5Mths 22Days
UHID	: CIND.0000173155	OP Visit No.	: CINDOPV244842
Printed On	: 12-11-2024 09:35 AM	Advised/Pres Doctor	: --
Department	: Cardiology	Qualification	: --
Referred By	: Self	Registration No.	: --
Employer Id	: 22S36983		

DEPARTMENT OF CARDIOLOGY

ECG

Observation :-

1. Normal Sinus Rhythm.
2. Heart rate is Normal
3. No pathological Q wave or ST-T changes seen.
4. Normal P,QRS,T waves and axis.
5. No evidence of chamber, hypertrophy or enlargement seen.

Impression:-

NORMAL RESTING ECG.

NOTE:-KINDLY TAKE A PHOTOCOPY OF THE GRAPH FOR FUTURE REFERENCE IF NEEDED

---End Of The Report---



Dr.M SUDHAKAR RAO
MBBS, MD, DM (Cardio)
000018
Cardiology

Mr. Deepith MHI
34y/m

Height : 168cm	Weight : 86.5kg	BMI :	Waist Circum : 100cm
Temp : 97°F	Pulse : 89bpm	Resp : 18cpm	B.P : 120/78 mmHg

General Examination / Allergies
History

Clinical Diagnosis & Management Plan

Follow up date:

Doctor Signature

OPHTHAL PRESCRIPTION

PATIENT NAME: Srujith MGH

DATE: 17/3/55

UHID NO: 173155

AGE: 34y

OPTOMETRIST NAME:

GENDER: M

This is to certify that I have examined

years and findings of his/her eye examination are as follows,

	RIGHT EYE				LEFT EYE			
	SPH	CYL	AXIS	BCVA	SPH	CYL	AXIS	BCVA
Distance	-2.00	-3.00	180	6/6	-2.50	-2.25	180	6/6
Add								

PD - RE: _____ - LE: _____ -

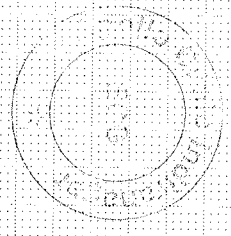
Colour Vision: Normal

Remarks: For Glasses only

R - 2.00 - 3.00 x 1
L - 1.75 - 2.00 x 166

Apollo clinic Indiranagar

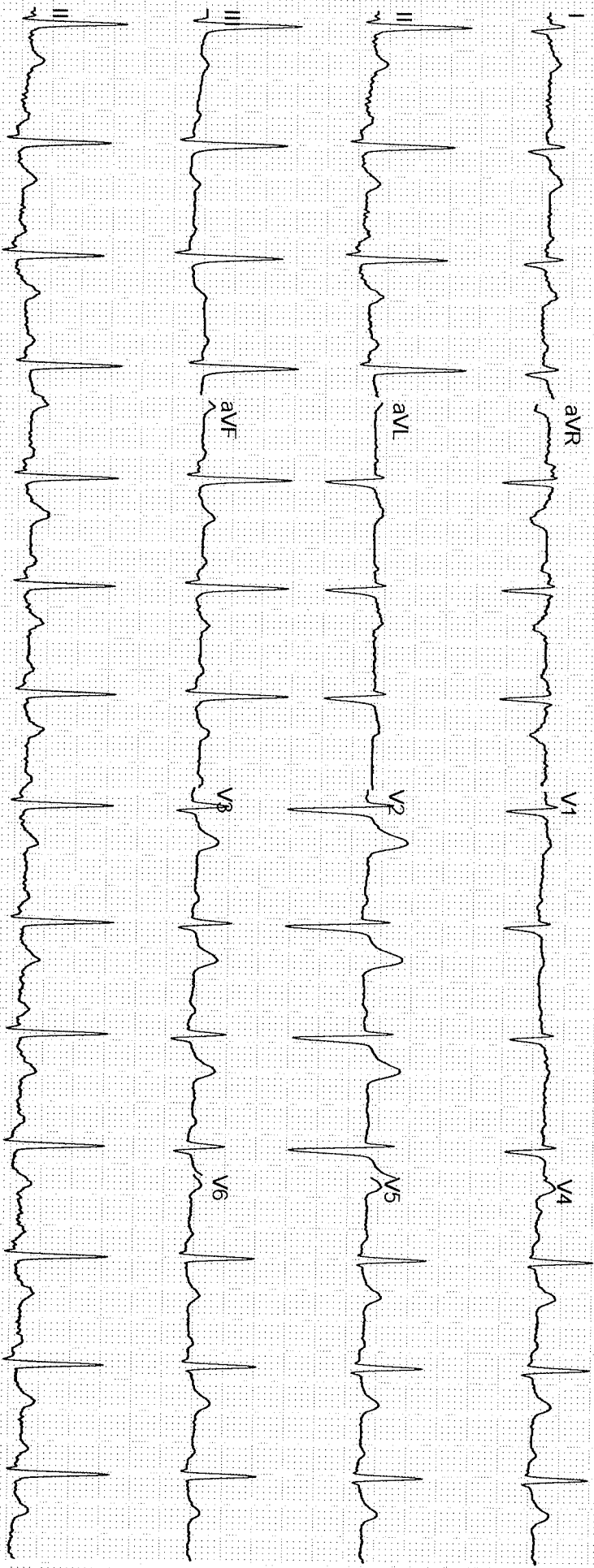
QRS	90 ms
QT/QTcBaz	364 / 430 ms
PR	158 ms
P	96 ms
RR/PP	718 / 714 ms
P/QRS/T	58 / 87 / 43 degrees



Handwritten signature

Technician:
Ordering Ph:
Referring Ph:
Attending Ph:

Handwritten signature



NAME: Mr. Sreejith M H	AGE/SEX: 34Y/M	OP NUMBER: 173155
Ref By : SELF	DATE: 09-11-2024	

M mode and doppler measurements:

CM	CM	M/sec	
AO: 2.2	IVS(D): 0.8	MV: E Vel: 1.0	A Vel : 0.5
LA: 2.5	LVIDD(D): 3.8	AV Peak: 0.7	
	LVPW(D): 0.8	PV peak: 0.9	
	IVS(S): 1.1		
	LVID(S): 2.6		
	LVPW(S): 1.2		
	LVEF: 60%		

Descriptive findings:


Left Ventricle	Normal
Right Ventricle:	Normal
Left Atrium:	Normal
Right Atrium:	Normal
Mitral Valve:	Normal
Aortic Valve:	Normal
Tricuspid Valve:	Normal
IAS:	Normal
IVS:	Normal
Pericardium:	Normal
IVC:	Normal
Others	---

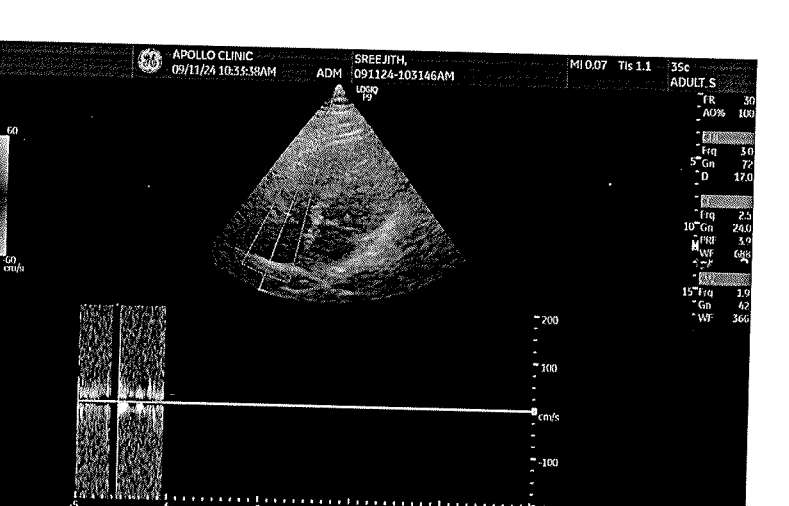
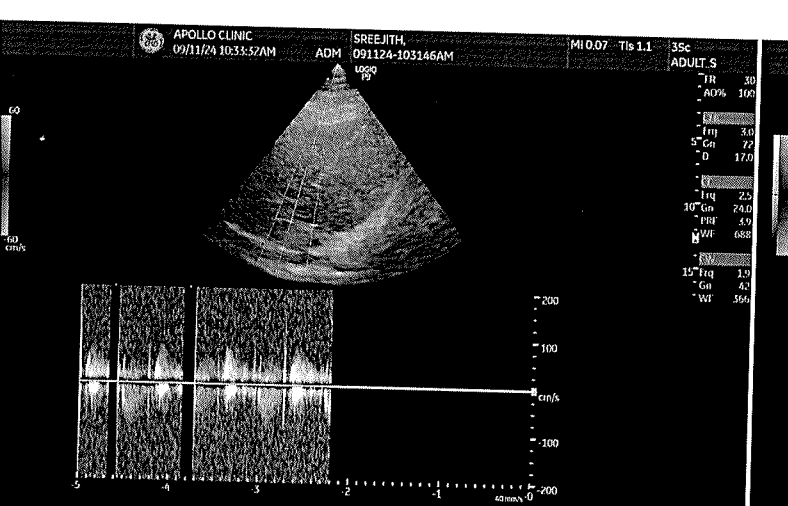
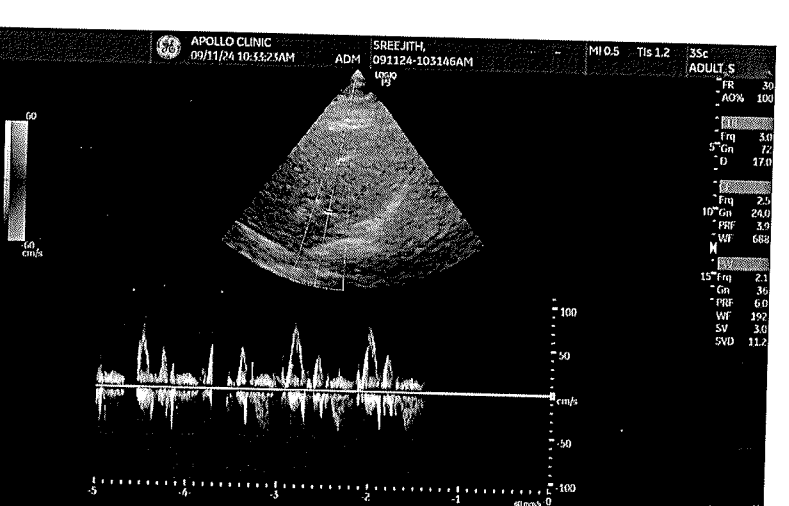
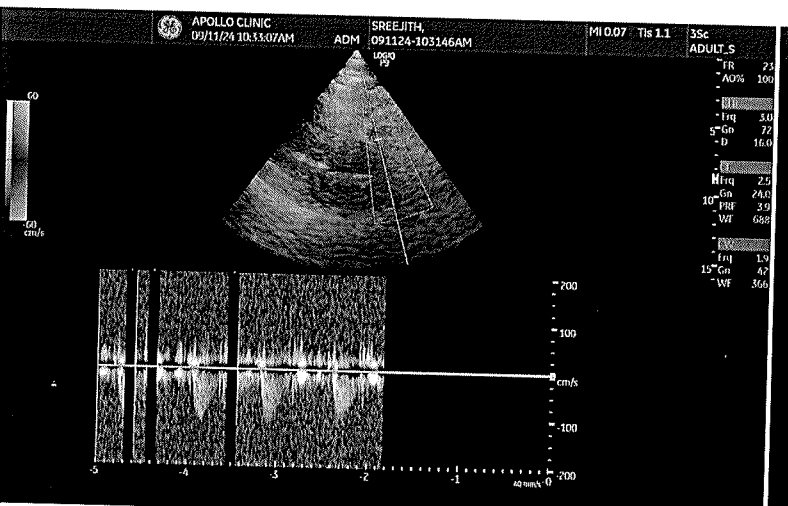
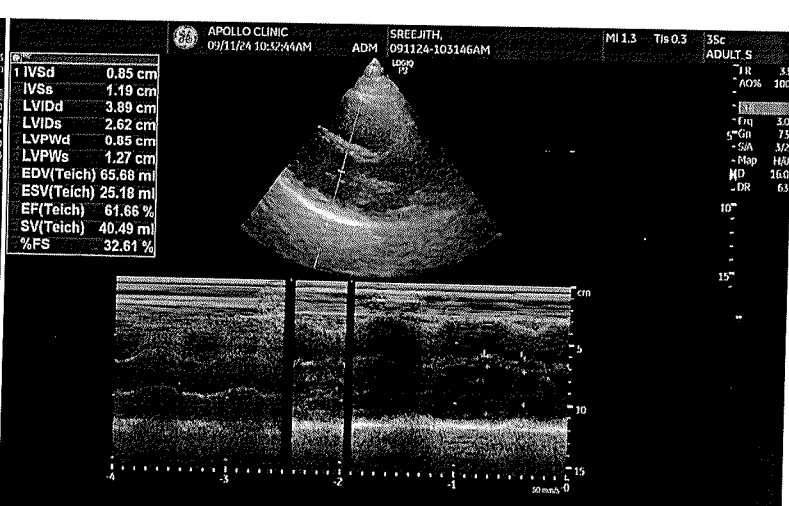
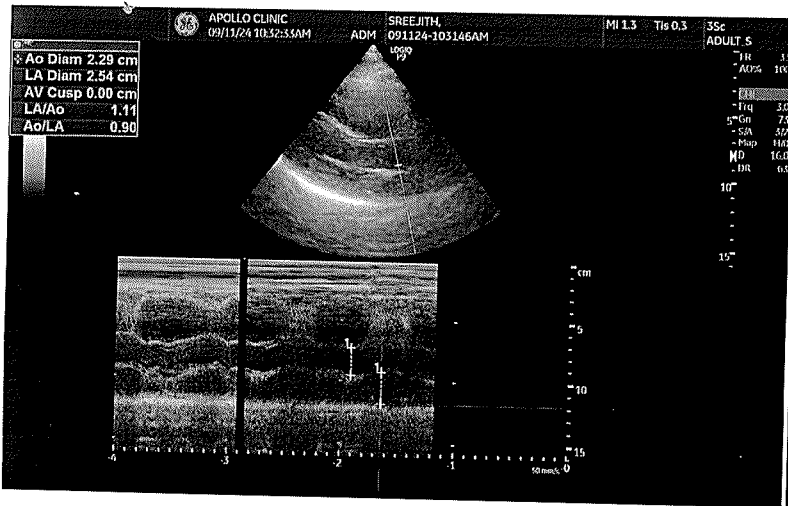
IMPRESSION :

- Normal cardiac chamber and valves**
- No Regional wall motion abnormality**
- Normal PA pressure**
- No clot/vegetation/pericardial effusion**
- Normal LV systolic function - LVEF= 60%**

DR JAGADEESH H V MD,DM

CONSULTANT CARDIOLOGIST





Apollo Clinic

CONSENT FORM

Patient Name: Sreejith M.A Age: 34
UHID Number: 173155 Company Name: Bank of Barod

I Mr/Mrs/Ms Sreejith M.A Employee of BOB
(Company) Want to inform you that I am ~~not~~ interested in getting the consultation on
Tests done which is a part of my routine health check package. 16/11/24.

And I claim the above statement in my full consciousness.

Patient Signature: [Signature] Date: 16-11-2024

Apollo Health and Lifestyle Limited

(CIN - U85110TG2000PLC115819)

Regd. Office: 1-10-60/62, Ashoka Raghupathi Chambers, 5th Floor, Begumpet, Hyderabad, Telangana - 500 016.

Ph No: 040-4904 7777, Fax No: 4904 7744 | Email ID: enquiry@apollohl.com | www.apollohl.com

APOLLO CLINICS NETWORK KARNATAKA

Bangalore (Basavanagudi | Bellandur | Electronic City | Fraser Town | HSR Layout | Indira Nagar | JP Nagar | Kundalahalli | Koramangala | Sarjapur Road) **Mysore** (VV Mohalla)

TO BOOK AN APPOINTMENT



Dear SREEJITH M H,

Greetings from Apollo Clinics,

Your corporate health check appointment is confirmed at **INDIRANAGAR clinic** on **2024-11-09** at **08:45-09:00**.

Payment Mode	
Corporate Name	ARCOFEMI HEALTHCARE LIMITED
Agreement Name	[ARCOFEMI MEDIWHEEL MALE AHC CREDIT PAN INDIA OP AGREEMENT]
Package Name	[ARCOFEMI - MEDIWHEEL - FULL BODY ANNUAL PLUS MALE - 2D ECHO - PAN INDIA - FY2324]



भारत सरकार
Government of India

Issue Date: 04/05/2012



Sreejith, M H
DOB : 22/05/1990
Male



आधार पहचान का प्रमाण है, नागरिकता का नहीं।
Aadhaar is a proof of identity, not of citizenship.



मेरा आधार, मेरी पहचान
6144 6366 1463