



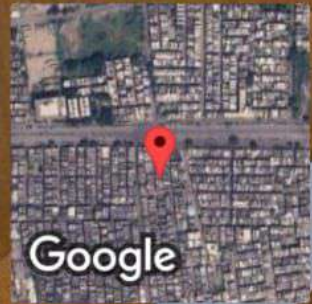
नीरामय ट्रस्ट जनरल हॉस्पिटल
&
प्रसूतिगृह

આ પણ જાણો
NIRAMAY TRUST GENERAL HOSPITAL & PRASUTIGRUH




 **GPS Map Camera**

Surat, Gujarat, India
A78, Keshar Bhawani Society, Maharana Pratap Nagar, Godadara, Surat, Gujarat
395012, India
Lat 21.17484°
Long 72.873818°
07/09/24 09:39 AM GMT +05:30





बैंक ऑफ़ बड़ौदा
Bank of Baroda




नाम मधुकर सिंह


Name Madhukar Singh

कर्मचारी कूट संख्या

E C Number 84575


जारीकर्ता प्राधिकारी
Issuing Authority




धारक के हस्ताक्षर
Holder's Signature



भारत सरकार

GOVERNMENT OF INDIA



मधुकर सिंह

Madhukar Singh

जन्म वर्ष / Year of Birth : 1985

पुरुष / Male



3437 7471 2837

आधार — आम आदमी का अधिकार



भारतीय विशिष्ट पहचान प्राधिकरण

UNIQUE IDENTIFICATION AUTHORITY OF INDIA

पता: S/O डी.डी.सिंह, मंगल भवन,
प्लॉट नं. ४, नियर सत्यार्थी धाम, आदिल
नगर, कल्याणपुर, लखनऊ, उत्तर परदेश,
226022

Address: S/O D.D.Singh,
MANGAL BHAWAN, PLAT NO. 4,
NEAR SATYARTHI DHAM, ADIL
NAGAR, Kalyanpur, Lucknow,
Uttar Pradesh, 226022



1947
1800 180 1947



help@uidai.gov.in

WWW

www.uidai.gov.in



P.O. Box No.1947,
Bengaluru-560 001

HAEMOGRAM PROFILE

TEST	RESULT	UNIT	METHOD	REFERENCE INTERVAL
<u>BLOOD COUNTS & INDICES</u>				
Haemoglobin	↓ : 13.30	(93 %gm%		13.5 - 17.0 gm%
Total RBC	↓ : 4.49	mill/cmm		4.6 - 6.2 mill/cmm
PCV	↓ : 39.00	%		40 - 54 %
MCV	: 86.85	fL		80 - 96 fL
MCH	: 29.62	pg		27 - 31 pg
MCHC	: 34.10	%		32 - 36 %
RDW	: 12.10	%		10 - 15 %
Total WBC	: 6,300	/cmm		4,000 - 11,000/cmm
Platelet Count	: 1,72,000	/cmm		1.5 - 4.0 Lac/cmm.
<u>DIFFERENTIAL LEUCOCYTES COUNT</u>				
Band Cells	: 00	%		00 - 06 %
Neutrophils	: 61	%		55 - 70 %
Lymphocytes	: 29	%		20 - 40 %
Eosinophils	: 05	%		01 - 06 %
Monocytes	: 05	%		02 - 08 %
Basophils	: 00	%		00 - 01 %
<u>ABSOLUTE COUNTS</u>				
Neutrophils	: 3843	/μL		2000 - 7000 /μL
Lymphocytes	: 1827	/μL		800 - 4000 /μL
Eosinophils	: 315	/μL		20 - 500 /μL
Monocytes	: 315	/μL		120 - 1200 /μL
Platelet In Smear	: ADEQUATE			
<u>ERYTHROCYTES SEDIMENTATION RATE</u>				
ESR After 1st Hour	↑ : 8	mm	Westergren	01 - 07 mm

(Done on Fully Automated Cell Counter NIHON KOHDEN CELL TECH ALFA)

End Of Report

Krishna Vaghani

Dr. Krishna Vaghani

M.D.(Pathologist)

Reg No. G - 24342

Investigations have their limitations, Solitary Pathological and other investigations never confirm the final diagnosis of the disease. This only help in diagnosing the disease in correlation to clinical symptoms & other related tests. Please interpret accordingly.

mailforuniversal@gmail.com

Main Branch : 125-126, 1st Floor, La Citadell,
Near Kangaroo Circle, Beside CNG Pump,
Magob, Parvat Patiya, Surat - 395 010.

98253 60243 82001 18966

UNIVERSAL LABORATORY

ESTD : 2013



mailforuniversal1@gmail.com

Mota Varachha Branch : Shop No. 109,
1st Floor, ABC Complex-2, ABC Circle,
Mota Varachha, Surat - 394 101.

79844 42849



Report Of
MADHUKAR SINGH

Date: **07/09/2024** Lab No.: **28** Age/Gender: **39 Yrs./M** Regi. No.:

Referring Dr.:
NIRAMAY TRUST GENERAL HOSPITAL & PRASUTIGRUH.


Info. Code : 9/4400_0_4400_0

BLOOD GLUCOSE ANALYSIS

<u>TEST</u>	<u>RESULT</u>	<u>UNIT</u>	<u>REFERENCE INTERVAL</u>
<u>FASTING</u>			
Blood Glucose	: 84.0	mg/dl	70 - 110 mg/dl
Urine Glucose	: NIL		
Urine Acetone	: NIL		
<u>POST-PRANDIAL (PPBS)</u>			
Blood Glucose	: 120.0	mg/dl	up to 140 mg/dl
Urine Glucose	: NIL		
Urine Acetone	: NIL		

(Done on Automated Random Access Biochemistry Analyzer RX - 50)

End Of Report




Dr. Krishna Vaghani

M.D.(Pathologist)

Reg No. G - 24342

Investigations have their limitations, Solitary Pathological and other investigations never confirm the final diagnosis of the disease. This only help in diagnosing the disease in correlation to clinical symptoms & other related tests. Please interpret accordingly.

 mailforuniversal@gmail.com

 Main Branch : 125-126, 1st Floor, La Citadell,
Near Kangaroo Circle, Beside CNG Pump,
Magob, Parvat Patiya, Surat - 395 010.

 98253 60243  82001 18966


UNIVERSAL LABORATORY

ESTD : 2013



 mailforuniversal1@gmail.com

 Mota Varachha Branch : Shop No. 109,
1st Floor, ABC Complex-2, ABC Circle,
Mota Varachha, Surat - 394 101.

 79844 42849

LIPID PROFILE

TEST	RESULT	UNIT	REFERENCE INTERVAL
Total Lipid (Calculated)	: 589	mg/dL	350 - 750 mg/dL
Serum Cholesterol	: 186.0	mg/dL	130 - 200 mg/dL
Serum Triglyceride	: 124.0	mg/dL	<150 : Normal
HDL Cholesterol	: 40.0	mg/dL	30 - 70 mg/dL
LDL Cholesterol	: 121.2	mg/dL	Upto 150 mg/dL
CHOL./HDL Chol. Ratio	: 4.65	: 1	Less than 5
LDL Chol/HDL Chol Ratio	: 3.03	: 1	Less than 3.5
VLDL (Calculated)	: 24.80	mg/dL	Upto 30 mg/dL
Non HDL Cholesterol (Calculated)	: 146.00	mg/dL	

Interpretation Based On New N.C.E.P. Guidelines

Test	Result (mg/dL)	Interpretation
CHOLESTEROL	< 200	Desirable
	200 - 239	Borderline
	> = 240	High
TRIGLYCERIDES	< 170	Normal
	170 - 199	Borderline
	> 200	High
LDL CHOLESTEROL	< 100	Desirable
	100 - 129	Sub-Optional
	130 - 159	Borderline High
HDL CHOLESTEROL	> 160	High
	< 35	Low
	> 60	High

(Done on Automated Random Access Biochemistry Analyzer RX - 50)

End Of Report

Krishna

Dr. Krishna Vaghani

M.D.(Pathologist)

Reg No. G - 24342

Investigations have their limitations, Solitary Pathological and other investigations never confirm the final diagnosis of the disease. This only help in diagnosing the disease in correlation to clinical symptoms & other related tests. Please interpret accordingly.

mailforuniversal@gmail.com

Main Branch : 125-126, 1st Floor, La Citadell,
Near Kangaroo Circle, Beside CNG Pump,
Magob, Parvat Patiya, Surat - 395 010.

98253 60243 82001 18966

UNIVERSAL LABORATORY

ESTD : 2013



mailforuniversal1@gmail.com

Mota Varachha Branch : Shop No. 109,
1st Floor, ABC Complex-2, ABC Circle,
Mota Varachha, Surat - 394 101.

79844 42849



Report Of
MADHUKAR SINGH

Date: **07/09/2024** Lab No: **28** Age/Gender: **39 Yrs./M** Regi. No.

Referring Dr.: **NIRAMAY TRUST GENERAL HOSPITAL & PRASUTIGRUH.**

Info. Code : 9/4400_0_4400_0

Hb A1C REPORT

TEST	RESULT	UNIT	REFERENCE INTERVAL
Hb A1C - Glycated Hb Glycated Haemoglobin	: 5.4	%	Non Diabetic : 4.3 - 6.3 % Good Control : 6.4 - 7.5 % Moderate Control : 7.5 - 9.0 % Poor Control : 9.0 % & Above
Avg. Blood Glucose Level	: 115	mg/dL	
Estimated Average Glucose eAG	: 108	mg%	

Notes :

Average Blood Glucose		Hemoglobin A1c%
421	-	14 %
385	-	13 %
350	-	12 %
314	-	11 %
278	-	10 %
243	-	09 %
207	-	08 %
171	-	07 %
136	-	06 %
100	-	05 %
065	-	04 %

End Of Report



Krishna Vaghani

Dr. Krishna Vaghani
M.D.(Pathologist)
Reg No. G - 24342

Investigations have their limitations, Solitary Pathological and other investigations never confirm the final diagnosis of the disease. This only help in diagnosing the disease in correlation to clinical symptoms & other related tests. Please interpret accordingly.

mailforuniversal@gmail.com

Main Branch : 125-126, 1st Floor, La Citadell,
Near Kangaroo Circle, Beside CNG Pump,
Magob, Parvat Patiya, Surat - 395 010.

98253 60243 82001 18966

UNIVERSAL LABORATORY
ESTD : 2013



mailforuniversal1@gmail.com

Mota Varachha Branch : Shop No. 109,
1st Floor, ABC Complex-2, ABC Circle,
Mota Varachha, Surat - 394 101.

79844 42849

LIVER FUNCTION TEST

<u>TEST</u>	<u>RESULT</u>	<u>UNIT</u>	<u>REFERENCE INTERVAL</u>
<u>S. BILIRUBIN</u>			
Total	: 0.70	mg/dl	0 - 1.0 mg/dl
Direct	: 0.30	mg/dl	up to 0.3 mg/dl
Indirect	: 0.40	mg/dl	0.1 - 1.0 mg/dl
S. Alk. Phosphatase	: 102	U/L	Adult : up to 290 U/L Children: up to 1200 U/L
S.G.P.T.	: 28	U/L	10 - 40 U/L
S.G.O.T.	: 35	IU/L	up to 40 IU/L
<u>SERUM PROTEIN</u>			
Total Protein	: 7.40	g/dl	6.0 - 8.2 gm/dl
Albumin	: 4.60	g/dl	3.5 - 5.0 g/dl
Globulin	: 2.80	g/dl	2.3 - 3.5 g/dl
A.G. Ratio	: 1.6		2.5 - 1.2 : 1
S. Australia Antigen (HBs Ag)	: TEST IS NEGATIVE		Negative
Kit Used	: HEPACARD		
Bile Salts	: NIL		
Bile Pigments	: NIL		
<u>PROTHROMBIN TIME</u>			
Patient's P. T.	: 15.00	sec	
Control's P. T.	: 14.00	sec	
ISI	: 1.05		
P. Index	: 93.33	%	
P.Ratio	: 1.07		
INR	: 1.08		

(Done on Automated Random Access Biochemistry Analyzer RX - 50)

End Of Report

Krishna Vaghani

Dr. Krishna Vaghani
M.D.(Pathologist)
Reg No. G - 24342

Investigations have their limitations, Solitary Pathological and other investigations never confirm the final diagnosis of the disease. This only help in diagnosing the disease in correlation to clinical symptoms & other related tests. Please interpret accordingly.

mailforuniversal@gmail.com

Main Branch : 125-126, 1st Floor, La Citadell,
Near Kangaroo Circle, Beside CNG Pump,
Magob, Parvat Patiya, Surat - 395 010.

98253 60243 82001 18966

UNIVERSAL LABORATORY

ESTD : 2013



mailforuniversal1@gmail.com

Mota Varachha Branch : Shop No. 109,
1st Floor, ABC Complex-2, ABC Circle,
Mota Varachha, Surat - 394 101.

79844 42849



RENAL FUNCTION TEST

<u>TEST</u>	<u>RESULT</u>	<u>UNIT</u>	<u>METHOD</u>	<u>REFERENCE INTERVAL</u>
Blood Urea	: 28.60	mg/dl	DRY CHEMISTRY	10 - 50 mg / dl
Blood Urea Nitrogen	: 9.53	mg/dl		3.30 - 18.70 mg/dl
Serum Creatinine	: 1.12	mg/dl	DRYCHEMISTRY	0.6 - 1.4 mg %
Serum Sodium	: 138.00	mmol/L	I.S.E.	135-145 mmol/L
Serum Potassium	: 4.96	mmol/L	I.S.E.	3.50 - 5.10 mmol/L
Serum Chloride	: 102.00	mmol/L	I.S.E.	96 - 110 mmol/L
Serum Uric Acid	: 4.50	mg/dl		3.40 - 7.00 mg/dl
Serum Calcium	: 9.00	mg/dl	Dry Chemistry	8.5 - 10.5 mg/dl

Done on Fully Automated Random Access Biochemistry Analyzer; Mspa Nano.

End Of Report

Krishna


Dr. Krishna Vaghani



M.D.(Pathologist)

Reg No. G - 24342

Investigations have their limitations, Solitary Pathological and other investigations never confirm the final diagnosis of the disease. This only help in diagnosing the disease in correlation to clinical symptoms & other related tests. Please interpret accordingly.

 mailforuniversal@gmail.com

 Main Branch : 125-126, 1st Floor, La Citadell,
Near Kangaroo Circle, Beside CNG Pump,
Magob, Parvat Patiya, Surat - 395 010.

 98253 60243  82001 18966


UNIVERSAL LABORATORY

ESTD : 2013



 mailforuniversal1@gmail.com

 Mota Varachha Branch : Shop No. 109,
1st Floor, ABC Complex-2, ABC Circle,
Mota Varachha, Surat - 394 101.

 79844 42849



THYROID FUNCTION TEST


TEST	RESULT	UNIT	METHOD	REFERENCE INTERVAL
Total Triiodothyronine(T3)	: 1.28	ng/ml	eCLIA	0.6-2.02 ng/ml
Total Thyroxine(T4)	: 10.20	ug/dl	eCLIA	5.13-14.06 ug/dl
Thyroid Stimulating Hormone (TSH)	: 1.236	uIU/ml	eCLIA	0.27-5.25 uIU/ml

NORMAL VALUES

Age	T3 ng/ml	T4 ug/dl	T.S.H. uIU/ml
01 - 12 Month	1.05 - 2.80	7.8 - 16.5	New Born : 1.3-19.0 3 Days : 1.1-17.0 10 weeks : 0.6-10.0 14 months: 0.4-7.0
01 - 05 Yrs	1.05 - 2.69	7.3 - 15.0	0.4-6.0
05 - 10 Yrs	0.94 - 2.41	6.04 - 13.3	0.25-5.25
10 - 15 Yrs	0.83 - 2.13	5.60 - 11.7	0.25-5.25
15 - 20 Yrs	0.80 - 2.00	4.20 - 11.8	0.25-5.25
> 20 Yrs	0.79 - 1.58	4.00 - 11.0	0.25-5.25

Done on Fully Automated Fluorescent Enzyme Immunoassay: TOSOH AIA 360; Japan.

End Of Report



Dr. Krishna Vaghani

M.D.(Pathologist)

Reg No. G - 24342

Investigations have their limitations, Solitary Pathological and other investigations never confirm the final diagnosis of the disease. This only help in diagnosing the disease in correlation to clinical symptoms & other related tests. Please interpret accordingly.



Dr. Tinish Nanavati Date :- 21/9/21

Patient Name :- Madhukar Simon

Weight :- 76 300 kg

Age :- 39 48 M

B.P. :- 120/70 0

Height 155

Dr. Tinish Nanavati

M.D. (Medicine)

Consultant Physician, Intensivist,
Diabetologist and Cardiologist.

કન્સલ્ટન્ટ ફિઝિશિયન, ઇન્ટેન્સિવિસ્ટ
& હિટીસ્ટોર રોસપેશિયન્ટ

Rx

To whom see ever, it may concern.

Dr. Parul Parmar

MB, DGO (Obs & Gynec)

Senior Gynaecologist

(Fellowship in Infertility &

Laparoscopy & IUI Expert

સીનિયર ઓબસ્ટ્રીસિયન ગાયનેકોલોજિસ્ટ

This is to Inform you that pt name

Dr. Madhukar Singh age 39/M. was

Dr. Jignesh Savsaviya

M.S. (Surgeon) FMAS, FIAGES, FISCP

Consultant General, Laparoscopic

& Gastrointestinal Surgeon

જનરલ, લેપ્રોસ્કોપીક અને ગેસ્ટ્રોઇન્ટેસ્ટલ સર્જન

examined by me and his all systemic

Examination. R-S, C.V.S, P/A & CNS

System are normal. pt is physically fit.

Dr. Mayur Kalsariya

M.D. (Pediatrics)

(Consultant Pediatrician

& Neonatologist)

કન્સલ્ટન્ટ પેડિયાટ્રિસિયન અને ન્યોનેટોલોજિસ્ટ

Dr. Mahesh Ladumor

M.S. (Orthopaedics)

Orthopaedics Surgeon

Knee & Hip Replacement

Arthroscopy Specialist

ઓર્થોપેડિક સર્જન (કર્ન) ક્ષીરકોષ્ટિક અને ઇન્ડિવિડ્યુઅલ પ્રોથીસિસ સ્પેશિયલિસ્ટ

Tinish Nanavati
Dr. Tinish Nanavati
M.D. (Medicine)
Reg. No.: G-30362

Dr. Bhushan Dodia

M.S., M.Ch. (Urology)

Consultant Urologist, Andrologist

& Laparoscopic Surgeon

Dr. Haresh Balar

M.D. (Radiologist)



Dr. Date :- 21/1/24

Patient Name :- MR. DHANUJI S. SURESH

Weight :- 76.300 kg

Age :- 39 YRS / MLE

B.P. :- 120/70 mmHg

HEALTHY - 155

Dr. Tinish Nanavati

M.D. (Medicine)
Consultant Physician, Intensivist,
Diabetologist and Cardiologist.
અભ્યાસકેન્દ્ર: કાર્ડિયોલોજીસ્ટ, ઇન્ટેન્સિવિસ્ટ
& ડાયાબીટોલોજિસ્ટ

Rx

Dietician consultation.

Dr. Parul Parmar

MB, DGO (Obs & Gynec)
Senior Gynaecologist
(Fellowship in Infertility &
Laparoscopy & IUI Expert
સીડીએન અને પ્રસુતિના નિષ્ણક

સવારે વહેલી સમય:- 10am, 1-2 hr સમય.

સવારે 7:00am:- બેસનું નિદાન, માન,

મિથાન જણાવ, 1-2 ગાંધારા પાન,

મહાદેવ વાગે ૧ કૂલ.

Dr. Jignesh Savsaviya

M.S. (Surgeon) FMAS, FIAGES, FISC
Consultant General, Laparoscopic
& Gastrointestinal Surgeon
જનરલ, લેપ્રોસ્કોપી અને ગેસ્ટ્રોઇન્ટેસ્ટિનલ સર્જન

10am:- 1 સર્જન, 2-3 ગાંધારા પાન.

12 pm :- ભાંજન, ડાહીસ (ફાલ, ડાહીસ,

ચાંચાં etc).

3 pm :- વીળ થી, 10-15 min સમય.

7pm :- બેસનું જણાવ. ચીરડી, ડાહીસ, ડાહીસ.

Dr. Mayur Kalsariya

M.D. (Pediatrics)
(Consultant Pediatrician
& Neonatologist)
બાલકોના વૈજ્ઞ અને ન્યોનેટોલોજી નિષ્ણક

Dr. Mahesh Ladumor

M.S. (Orthopaedics)
Orthopaedics Surgeon
Knee & Hip Replacement
Arthroscopy Specialist
ઓર્થોપેડી સર્જન (સર્જન)

Dr. Bhushan Dodia

M.S., M.Ch. (Urology)
Consultant Urologist, Andrologist
& Laparoscopic Surgeon

Dr. Haresh Balar

M.D. (Radiologist)



Dr. Date :- 21/9/24

Patient Name :- MADHUKESHVAR SORATHI

Weight :- 76.300 kg.

Age :- 39 yr / male

B.P. :- 120/90 mm/Hg

HEART - 105.

Dr. Tinish Nanavati

M.D. (Medicine)

Consultant Physician, Intensivist,
Diabetologist and Cardiologist.
અભ્યાસકારક ફિઝિશિયન, ઇન્ટેન્સિવ-કાર્ડિયોલોજિસ્ટ
& ડિયાબીટીસ સ્પેશિયાલિસ્ટ

Rx

are checkup consultation

Dr. Parul Parmar

MB, DGO (Obs & Gynec)

Senior Gynaecologist
(Fellowship in Infertility &
Laparoscopy & IUI Expert
અભ્યાસકારક અને પ્રજ્ઞાશીલ મિત્રાઈ

lung distance vision - normal

scat distance vision - normal,

medicall Genitor અર્થે ચકાસણી

ની ફરતે.

1) 22 ન વચ્ચે. જુલાઈ પેન્ડીંગ રાખેલ.

Dr. Jignesh Savsaviya

M.S. (Surgeon) FMAS, FIAGES, FISCP

Consultant General, Laparoscopic
& Gastrointestinal Surgeon
જનરલ, લેપ્રોસ્કોપીક અને ગેસ્ટ્રોઇન્ટેસ્ટલ સર્જન

Dr. Mayur Kalsariya

M.D. (Pediatrics)

(Consultant Pediatrician
& Neonatologist)

બાલકોના વૈજ્ઞાનિક અને ન્યૂનેટોલોજિસ્ટ

Dr. Mahesh Ladumor

M.S. (Orthopaedics)

Orthopaedics Surgeon

Knee & Hip Replacement

Arthroscopy Specialist

ઝાડાના ડોરોના મિત્રાઈ (સર્જન)

Dr. Bhushan Dodia

M.S., M.Ch. (Urology)

Consultant Urologist, Andrologist
& Laparoscopic Surgeon

Dr. Haresh Balar

M.D. (Radiologist)





NIRAMAY TRUST GENERAL HOSPITAL & PRASUTIGRUH
Reg No. 1-4271 - Surat

NIRAMAY TRUST GENERAL HOSPITAL & PRASUTIGRUH



Dr. Date :- 21/9/24

Patient Name :- MADHUKAR SAWANI.

Weight :- 76.300 kg

Age :- 39 years male

B.P. :- 120/70 mmHg

Height - 155

Dr. Tinish Nanavati

M.D. (Medicine)
Consultant Physician, Intensivist,
Diabetologist and Cardiologist.
કર્ણાટક ડિપાર્ટમેન્ટ, કાર્ડિયો-સર્વાઈક્યુલેટરી
& ડિપાર્ટમેન્ટ સ્પેશિયાલિસ્ટ

Rx

Dental consultation

Dr. Parul Parmar

MB, DGO (Obs & Gynec)
Senior Gynaecologist
(Fellowship in Infertility &
Laparoscopy & IUI Expert
સ્ત્રીરોગ અને પ્રસુતિના નિષ્ણક

upper teeth - normal

lower teeth - normal

gum - normal.

Dr. Jignesh Savsaviya

M.S. (Surgeon) FMAS, FIAGES, FISC
Consultant General, Laparoscopic
& Gastrointestinal Surgeon
જનરલ, લેપ્રોસ્કોપીક અને ગેસ્ટ્રોઇન્ટેસ્ટલ સર્જન

no any teeth problem.

⇒ કમ્પ્લેટ ડાઇન ડાયગ્નોસિસ ઓફ ડાઇન્ટલ
પ્રોબ્લેમ.

Dr. Mayur Kalsariya

M.D. (Pediatrics)
(Consultant Pediatrician
& Neonatologist)
બાલકોની સંભાળ અને નવજાતકોના નિષ્ણક

આઈજીએ, ડાયગ્નોસિસ, ડાયગ્નોસિસ ઓફ ડાઇન્ટલ
પ્રોબ્લેમ ઓફ ડાઇન્ટલ પ્રોબ્લેમ.

Dr. Mahesh Ladumor

M.S. (Orthopaedics)
Orthopaedics Surgeon
Knee & Hip Replacement
Arthroscopy Specialist
ઔષ્ઠિક રોગોના નિષ્ણક (સર્જન)

Dr. Bhushan Dodia

M.S., M.Ch. (Urology)
Consultant Urologist, Andrologist
& Laparoscopic Surgeon

Dr. Haresh Balar

M.D. (Radiologist)



42,76,77,78, Kesharbhavani Soc, Part-A, Opp. Dhur Park, Godadara Naher Road, Godadara, Surat. 395012

✉ niramaygeneralhospital@gmail.com

Mo. 99799 85570



NIRAMAY TRUST GENERAL HOSPITAL & PRASUTIGRUH
Reg No. E-8775 - Surat

NIRAMAY TRUST GENERAL HOSPITAL & PRASUTIGRUH



Dr. Ronak Modi Date :- 7/9/24

Patient Name :- madhukar singh

Weight :-

Age :-

B.P. :-

Dr. Tinish Nanavati

M.D. (Medicine)

Consultant Physician, Intensivist,

Diabetologist and Cardiologist.

કન્સલ્ટન્ટ ફિઝિશિયન, ઇન્ટેન્સિવિસ્ટ

& ડિયાબીટીસ સ્પેશિયાલિસ્ટ

Dr. Parul Parmar

MB, DGO (Obs & Gynec)

Senior Gynaecologist

(Fellowship in Infertility &

Laparoscopy & IUI Expert

સીનિયર ઓબ્સ્ટ્રીટ્રિશિયન

Dr. Jignesh Savsaviya

M.S. (Surgeon) FMAS, FIAGES, FISCP

Consultant General, Laparoscopic

& Gastrointestinal Surgeon

જનરલ, લેપ્રોસ્કોપિક અને ગેસ્ટ્રોઇન્ટેસ્ટિનલ સર્જન

Dr. Mayur Kalsariya

M.D. (Pediatrics)

(Consultant Pediatrician

& Neonatologist)

કન્સલ્ટન્ટ પેડિયાટ્રિશિયન

Dr. Mahesh Ladumor

M.S. (Orthopaedics)

Orthopaedics Surgeon

Knee & Hip Replacement

Arthroscopy Specialist

ઓર્થોપેડિક સર્જન (સર્જન)

Dr. Bhushan Dodia

M.S., M.Ch. (Urology)

Consultant Urologist, Andrologist

& Laparoscopic Surgeon

Dr. Haresh Balar

M.D. (Radiologist)

Rx 2 DEchoCardiography

Good LV systolic function
LVEF 60-1.

NO RWMA at rest

Normal diastolic function

NO MR

Normal aortic valve

NO TR. Normal PA pressure

IVC 10mm, Collapsing

NO clot, NO vegetation

NO pericardial effusion.

Normal aortic root

Conclusion

• Good LV systolic function

• LVEF 60-1.

• NO RWMA at rest



42,76,77,78, Kesharbhavani Soc, Part-A, Opp. Dhur Park, Godadara Naher Road, Godadara, Surat. 395012

✉ niramaygeneralhospital@gmail.com

Mo. 99799 85570

નીરામય જનરલ હોસ્પિટલ & પ્રસુતિગૃહ

42,76,77,78, કેશરભવાની સોસાયટી, વિભાગ-A, ધુવપાર્ક ની સામે, ગોડાદરા નહેર રોડ, ગોડાદરા, સુરત. Mo. 99799 85570

Name:- _____ Date:- _____

Rx

Patient Name	: MADHUKAR SINGH	Age / Sex	: 39/M
Ref. Doctor	: NIRAMAY TRUST HOSPITAL AND PRASUTI GRUH	Date	: 07/09/2024

USG : ABDOMEN

Liver is normal in size and with coarse echo texture. Surface is smooth and regular. No evidence of focal solid or cystic lesion seen. Intrahepatic biliary radicles are normal. Right and left portal veins, hepatic veins are normal. **Main portal vein** is normal in calibre.

Gall bladder is well distended and shows normal wall thickness. No evidence of calculus noted.

Pancreas is normal in size, shape and echo texture.

Spleen is normal size, shape and echo texture.

Both kidneys appear normal in size with homogenous echo pattern

Right kidney: 119x47 mm. Left kidney: 113x61 mm.

Approx 14x14mm size simple renal cortical cyst with calcification seen at mid pole of left kidney.

No evidence of calculus, hydronephrosis or hydroureter seen on either side.

CMD is preserved in both kidneys. No signs of renal abscess seen on any side.

Urinary bladder is partially distended and shows normal wall thickness. Lumen is echo free.

Prostate appears normal in size, shape and echo pattern.

Small and large bowel loops are unremarkable.

No evidence of abnormal bowel wall thickening or dilatation seen.

No evidence of mesenteric or retroperitoneal lymphadenopathy seen.

No evidence of ascites seen.

IMPRESSION:

- Grade II fatty liver.
- Left renal small simple renal cortical cyst with calcification.

Thank you for the reference.



DR. HARESH BALAR
CONSULTANT RADIOLOGIST

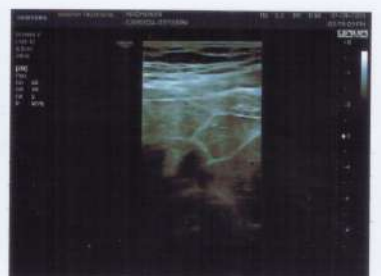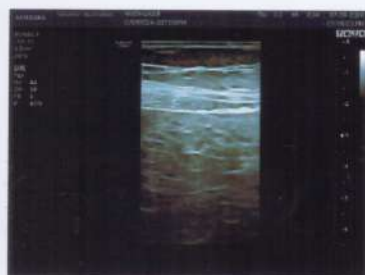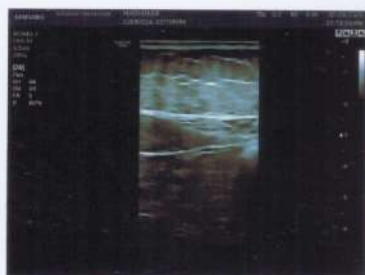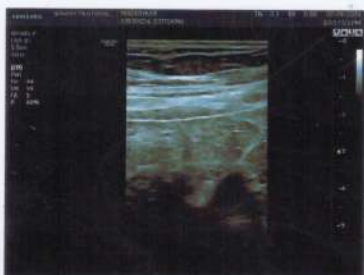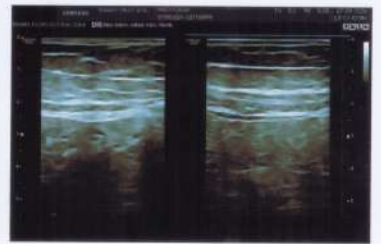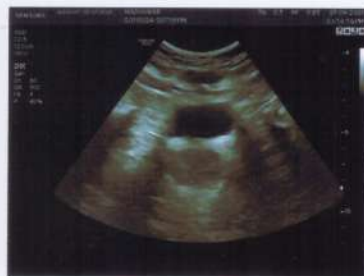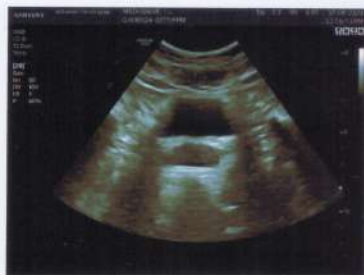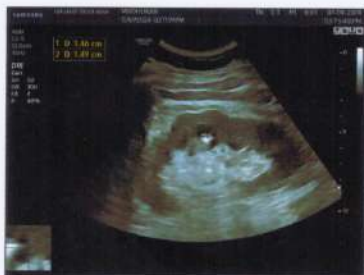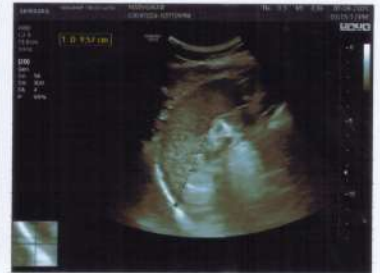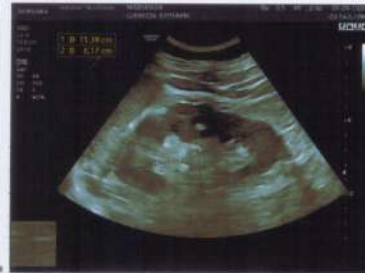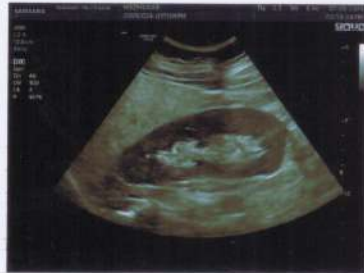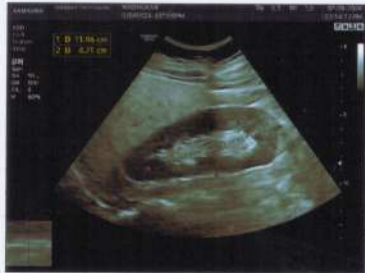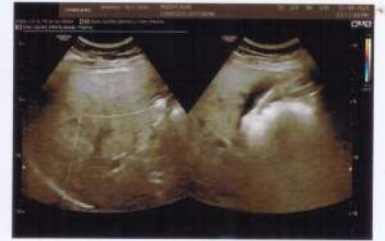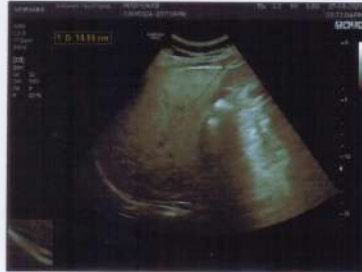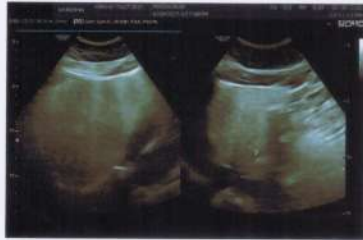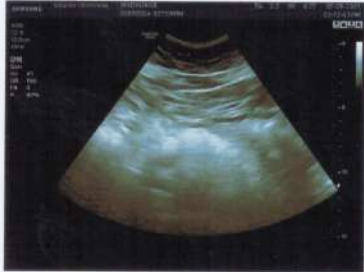Dr. Haresh N. Balar
M.D. (Radiologist)
Reg. No.: G-0596

Patient

ID 07092024-031159PM
Name MADHUKAR
Birth Date
Gender Male

Exam

Accession #
Exam Date 07-09-2024
Description
Operator



નીરામય જનરલ હોસ્પિટલ & પ્રસુતિગૃહ

42,76,77,78, કેશરભવાની સોસાયટી, વિભાગ-A, ઘુવપાર્ક ની સામે, ગોડાદરા નહેર રોડ, ગોડાદરા, સુરત. Mo. 99799 85570

Name:- _____ Date:- _____

Rx

Patient Name	: MADHUKAR SINGH	Age / SeX	: 39/M
Ref. Doctor	: NIRAMAY TRUST GENERAL HOSPITAL AND PRASUTI GRUH	Date	: 07/09/2024

CHEST RADIOGRAPH(PA VIEW)

Both lung fields appears clear.

Trachea is central in position.

Costophrenic angles are clear.

Cardio thoracic ratio is normal.

Mediastinal and hilar regions are normal.

Both diaphragmatic domes are well visualized and normal.

Visualized skeleton and soft tissues around thoracic cage appear normal.


IMPRESSION :

- No significant abnormality seen.

Please correlate clinically.

Report with thanks,




DR. HARESH BALAR
CONSULTANT RADIOLOGIST

Dr. Haresh N. Balar
M.D. (Radiologist)
Reg. No.:- G-0596

PA

MADHUKAR SINGH, 39 Y M, 07/09/2024 CHEST
NIRAMAY TRUST GENERAL HOSPITAL & PRASUTIGRUH

AUTO 10mm/mV

I

10mm/mV

aVR

10mm/mV

V1

II

aVL

V2

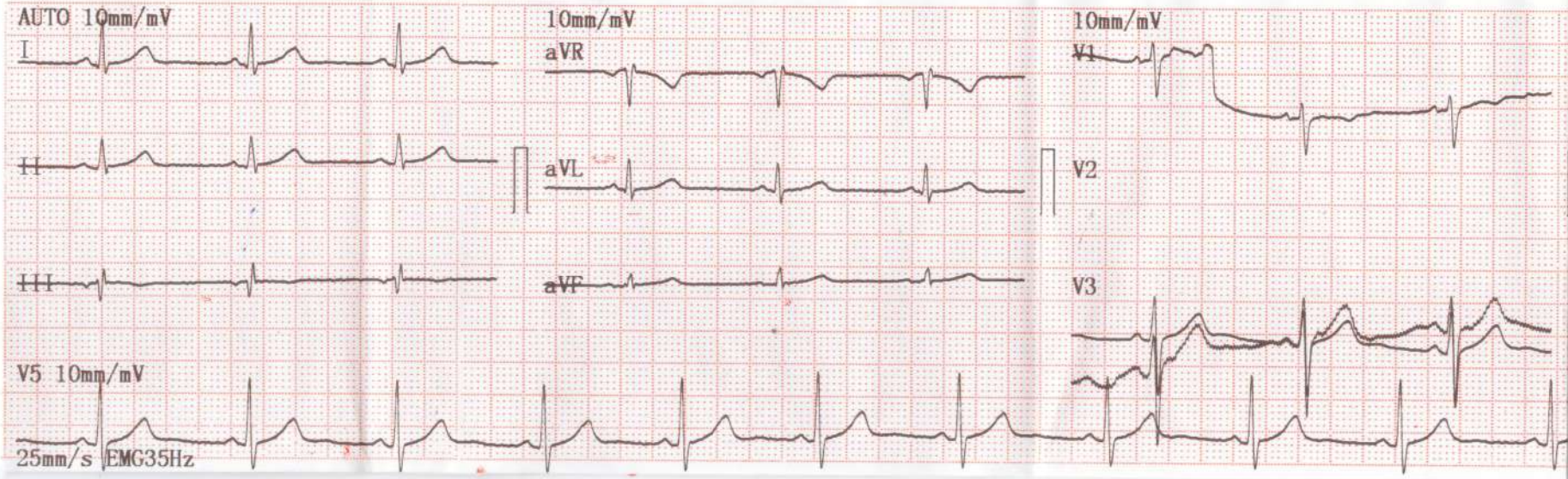
III

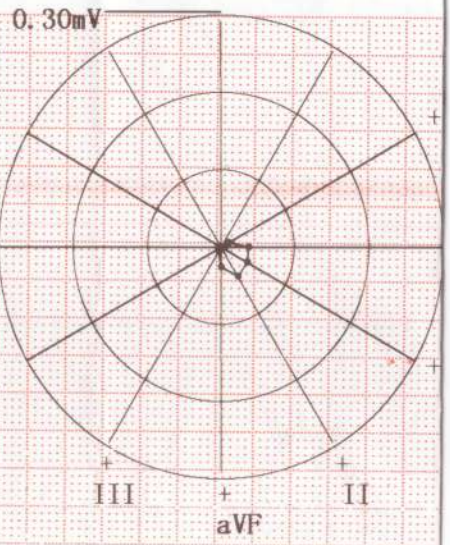
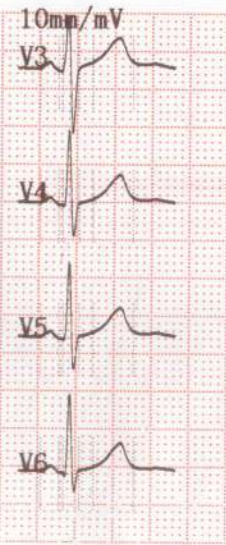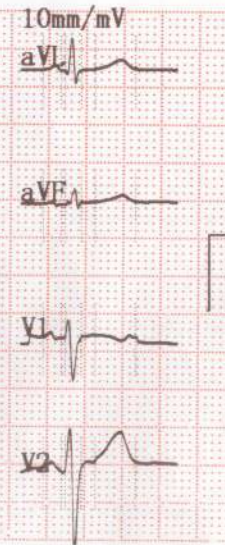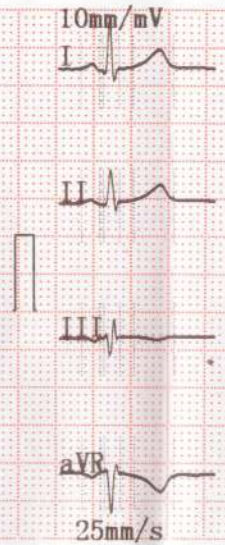
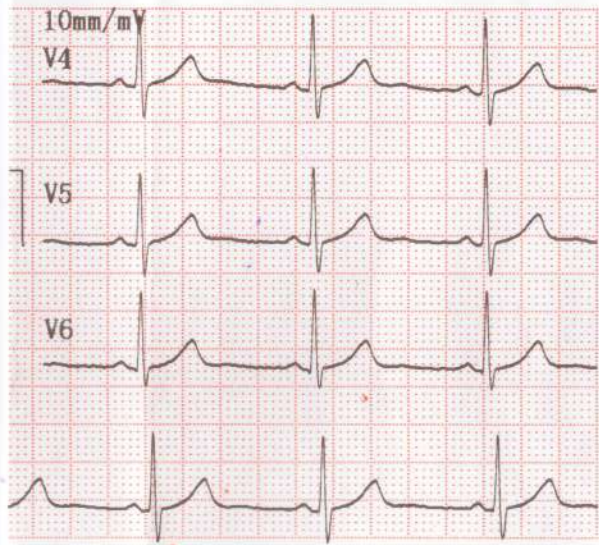
aVF

V3

V5 10mm/mV

25mm/s EMC35Hz

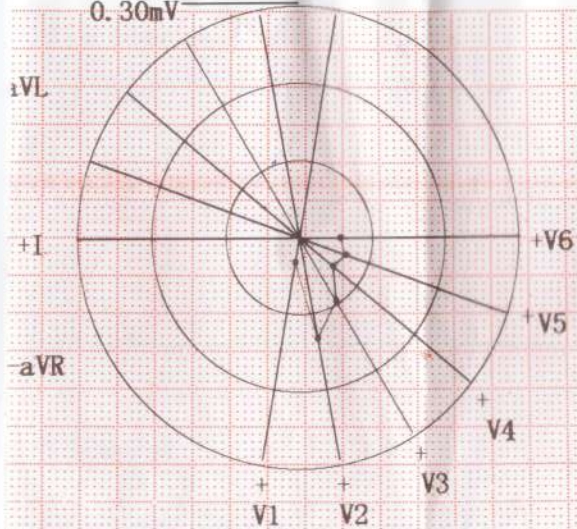




0.30mV

2024-09-07 10:05:17

<< Conclusions >>



aVL : 0.01 mV	ID : 22E32846
I : 0.04 mV	Name : madhukar singh
aVR : 0.04 mV	Sex : male
II : 0.05 mV	Age : 39
aVF : 0.03 mV	Height : 155 cm
III : 0.01 mV	Weight : 76 kg
	SYS : 120 mmHg
	DIA : 80 mmHg
V6 : 0.06 mV	HR : 66 bpm
V5 : 0.07 mV	PR Interval : 124 ms
V4 : 0.06 mV	P Duration : 100 ms
V3 : 0.10 mV	QRS Duration : 88 ms
V2 : 0.14 mV	T Duration : 218 ms
V1 : 0.03 mV	QT/QTc : 384/402 ms
	P/QRS/T Axis : 9.1/26.0/28.0 deg
	R(V5)/S(V1) : 1.00/0.56 mV
	R(V5)+S(V1) : 1.56 mV

Normal Sinus Rhythm.
Longitudinal Left axis deviation.



Dr. Tirth Nanavati
M.D. (Medicine)
Reg. No: G-30362

Physician

