

Patient Name : Mr. Shashank Mittal

Age/Gender : 35 Y/M

UHID/MR No. : CSAR.0000136796

OP Visit No : CSAROPV323706

Sample Collected on :

Reported on : 09-01-2024 19:19

LRN# : RAD2204099

Specimen :

Ref Doctor : SELF

Emp/Auth/TPA ID : 8130275421

DEPARTMENT OF RADIOLOGY

X-RAY CHEST PA

- Trachea central.
- Mediastinum is central.
- Cardiac silhouette appear normal.
- For visualized lung fields appear normal.
- Bilateral hilum appear normal.
- CP angles are clear.

IMPRESSION : No obvious gross abnormality noted in the x-ray.

DR. RAMESH G
CONSULTANT RADIOLOGIST

ADVICE : Higher imaging techniques to be done, if clinically needed, depending on the clinical condition of the patient for further evaluation.



Patient Name : Mr. Shashank Mittal

Age/Gender : 35 Y/M

| | | | |
|----------------------------|-----------------------|--------------------|--------------------|
| Patient Name | : Mr. Shashank Mittal | Age/Gender | : 35 Y/M |
| UHID/MR No. | : CSAR.0000136796 | OP Visit No | : CSAROPV323706 |
| Sample Collected on | : | Reported on | : 09-01-2024 19:01 |
| LRN# | : RAD2204099 | Specimen | : |
| Ref Doctor | : SELF | | |
| Emp/Auth/TPA ID | : 8130275421 | | |

DEPARTMENT OF RADIOLOGY

ULTRASOUND - WHOLE ABDOMEN

LIVER : Normal in size & increase in echotexture. No focal lesion seen. No intra hepatic biliary duct dilatation. Portal & hepatic veins appears normal. CBD is not dilated.

GALL BLADDER :Minimally distended. No intraluminal calculi seen. Wall thickness is normal.

PANCREAS : Obscured by bowel gas. However the visualized parts of the pancreas appear grossly normal. Para-Aortic areas could not be seen.

SPLEEN : Normal in size and echotexture normal. No focal / diffuse lesions.

KIDNEYS : RIGHT KIDNEY : 9.4 x 1.2 cms, LEFT KIDNEY : 9.1 x 1.2 cms, normal parenchymal thickness. Both kidneys are normal in size and echotexture.

No calculi. No pelvicalyceal dilatation on both sides. Corticomedullary differentiation is well maintained.

URINARY BLADDER : Moderately distended. No intraluminal calculi/mass lesion seen.

PROSTATE : Normal in size & echotexture. (Volume : 9.2 cc).

IMPRESSION : Grade - I Fatty Liver.

DR. B M SESHADRI MDRD
CONSULTANT RADIOLOGIST

(The sonography findings should always be considered in correlation with the clinical and other investigation findings where applicable).It is only a professional opinion.Not valid for medico-legal purpose) Higher imaging techniques to be done, depending on the condition of the patient, if clinically needed.

6

Name : Mr. Shashank Mittal Age: 35 Y
 Address : sjp Sex: M
 Plan : ARCOFEMI MEDIWHEEL MALE AHC CREDIT PAN INDIA OP AGREEMENT
 UHID:CSAR.0000136796
 CSAR.0000136796
 OP Number:CSAROPV323706
 Bill No :CSAR-OCR-43775
 Date : 09.01.2024 08:29

| Sno | Service Type/ServiceName | Department |
|-------------------------------------|--|-----------------------|
| 1 | ARCOFEMI - MEDIWHEEL - FULL BODY ANNUAL PLUS MALE - 2D ECHO - PAN INDIA - FY2324 | |
| <input checked="" type="checkbox"/> | GAMMA GLUTAMYL TRANSFERASE (GGT) | |
| <input checked="" type="checkbox"/> | 2D ECHO - 18 | 10:30 to 11:00 |
| <input checked="" type="checkbox"/> | LIVER FUNCTION TEST (LFT) | |
| <input checked="" type="checkbox"/> | GLUCOSE, FASTING - 8 | |
| <input checked="" type="checkbox"/> | HEMOGRAM + PERIPHERAL SMEAR | |
| | DIET CONSULTATION | |
| <input checked="" type="checkbox"/> | COMPLETE URINE EXAMINATION | |
| <input checked="" type="checkbox"/> | URINE GLUCOSE (POST PRANDIAL) | |
| <input checked="" type="checkbox"/> | PERIPHERAL SMEAR | |
| <input checked="" type="checkbox"/> | ECG - 10 | |
| <input checked="" type="checkbox"/> | RENAL PROFILE/RENAL FUNCTION TEST (RFT/KFT) | |
| <input checked="" type="checkbox"/> | DENTAL CONSULTATION - 15 | |
| <input checked="" type="checkbox"/> | GLUCOSE, POST PRANDIAL (PP), 2 HOURS (POST MEAL) - 8 | |
| <input checked="" type="checkbox"/> | URINE GLUCOSE (FASTING) | |
| <input checked="" type="checkbox"/> | HbA1c, GLYCATED HEMOGLOBIN | |
| <input checked="" type="checkbox"/> | X-RAY CHEST PA - 9 | |
| | ENT CONSULTATION - 3 | Not done |
| | FITNESS BY GENERAL PHYSICIAN | |
| <input checked="" type="checkbox"/> | BLOOD GROUP ABO AND RH FACTOR | |
| <input checked="" type="checkbox"/> | LIPID PROFILE | |
| <input checked="" type="checkbox"/> | BODY MASS INDEX (BMI) - 10 | |
| | OPHTHAL BY GENERAL PHYSICIAN | |
| <input checked="" type="checkbox"/> | ULTRASOUND - WHOLE ABDOMEN - 18 | Eye ideal |
| <input checked="" type="checkbox"/> | THYROID PROFILE (TOTAL T3, TOTAL T4, TSH) | 9:15 2 liter water |

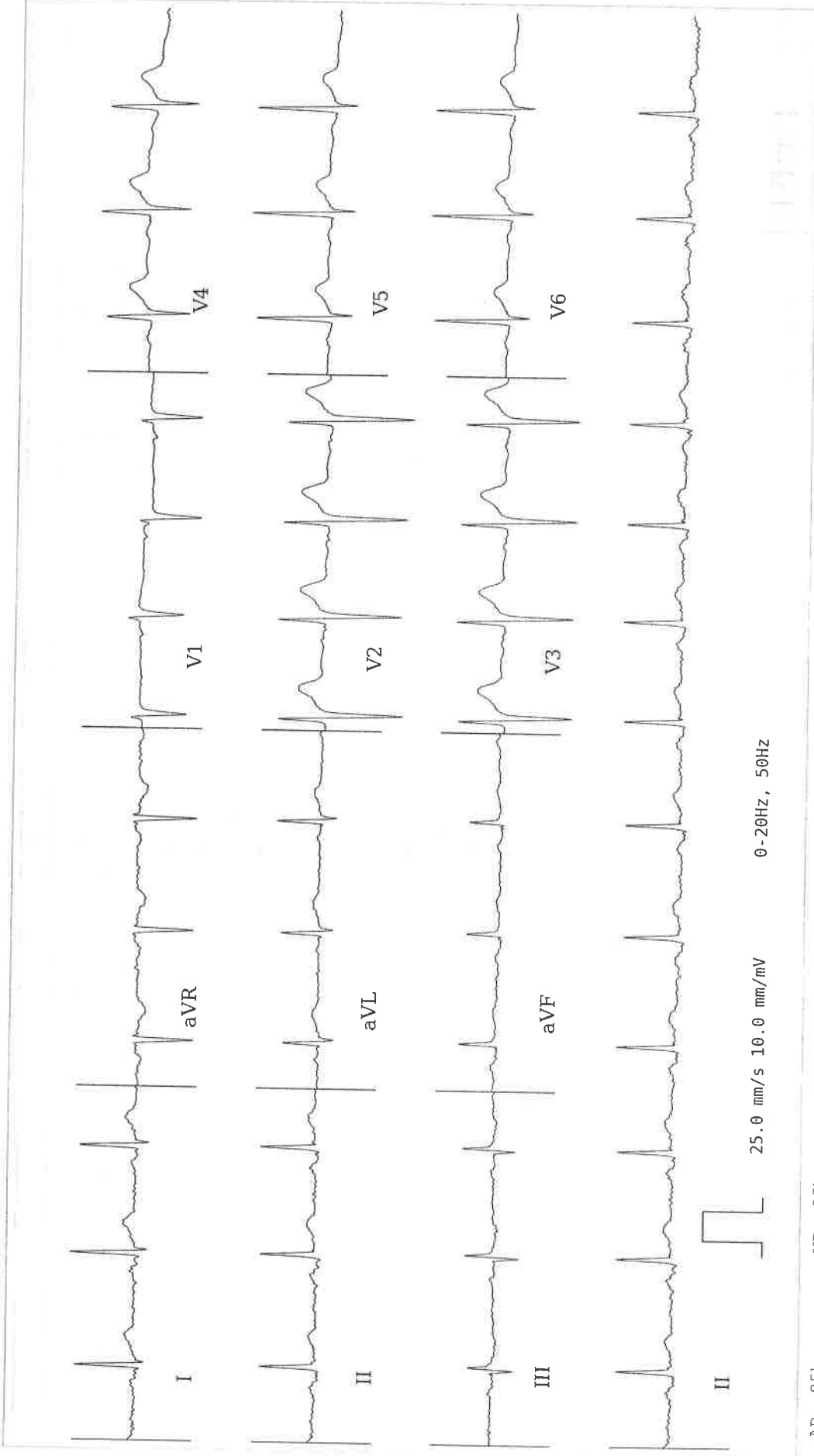
wt - 85.4 kg
 Ht - 169cm
 BP - 126/89mmHg
 P - 87b/min
 BMI - 29.9 kg/m²



Apollo Clinic, Kaikondrahalli

Age / Gender: 35/Male
Patient ID: SHASHANK

Date and Time: 9th Jan 24 11:48 AM



AR: 85bpm VR: 85bpm QRSD: 84ms QT: 340ms QTcB: 404ms PRI: 154ms P-R-T: 44° 36° 17°

ECG Within Normal Limits: Sinus Rhythm. Please correlate clinically.

REPORTED BY

Kunja A. D. D.

Dr. Vishwanath. A

Disclaimer: Analysis in this report is based on ECG alone and should only be used as an adjunct to clinical history, symptoms and results of other invasive and non-invasive tests and must be interpreted by a qualified physician.

2D, TISSUE AND COLOR DOPPLER ECHOCARDIOGRAPHY REPORT



| | | | | |
|---------------|---------------------------|---------------|------------------------|--|
| NAME | MR.SHASHANK MITTAL | | DATE:09/01/2024 | |
| AGE | 35 YEARS | GENDER | MALE | |
| REF BY | DR. SUMANJITA BORA | ID | 136796 | |

MEASUREMENTS

| Vital Signs and Body Measurements | | | | | | | | | |
|------------------------------------|-----|-----|----------|--------|--|------------------|---------|---------|----------------|
| HR | bpm | B.P | mmHg | Height | mm | Weight | kg | BSA | m ² |
| M - Mode (Parasternal view) | | | | | Conventional and Tissue Doppler | | | | |
| AO | 28 | mm | LVID - d | 44 | mm | Mitral Valve | E : 0.7 | A : 0.7 | m/sec |
| LA | 37 | mm | LVID - s | 27 | mm | Aortic Valve | 1.1 | - | m/sec |
| | | | IVS - d | 11 | mm | Pulmonary Valve | 0.7 | - | m/sec |
| | | | PW - d | 11 | mm | E' Septal (TDI) | 0.11 | - | mm/sec |
| | | | EF- | 60 | % | E' Lateral (TDI) | 0.12 | - | mm/sec |

DESCRIPTIVE FINDINGS: Technically Adequate Study. Normal sinus rhythm During Study

| | |
|----------------------------|---|
| RIGHT ATRIUM | Normal in Size |
| LEFT ATRIUM | Normal in Size |
| RIGHT VENTRICLE | Normal in Size Tapse > 18mm |
| LEFT VENTRICLE | Normal in Size |
| WALL MOTION ANALYSIS | No RWMA |
| TRICUSPID VALVE | Normal, PASP= 10 mmHg, Trivial TR |
| MITRAL VALVE | Normal |
| PULMONIC VALVE | Normal |
| AORTIC VALVE | Normal |
| IAS & IVS | Intact |
| AORTA | Normal in Size |
| SYSTEMIC & PULMONARY VEINS | Normally Draining |
| IVC | Normal |
| PERICARDIUM | Normal |
| OTHERS | No Intra Cardiac Thrombus, Tumour or Vegetation |

IMPRESSION:

Cardiac Chambers & valves are normal
 Normal PAP
 No RWMA
 Normal Left Ventricular Systolic Function (LVEF-60 %)
 No clot/ vegetation/pericardial effusion

**Dr. SUMANJITA BORA, MBBS AMC.PGDCC(Cardiology)
 CONSULTANT CARDIOLOGIST**

Apollo Health and Lifestyle Limited

(CIN - U85110TG2000PLC115819)
 Regd. Office: 1-10-60/62, Ashoka Raghupathi Chambers, 5th Floor, Begumpet, Hyderabad, Telangana - 500 016.
 Ph No: 040-4904 7777, Fax No: 4904 7744 | Email ID: enquiry@apollohl.com | www.apollohl.com

APOLLO CLINICS NETWORK KARNATAKA

Bangalore (Basavanagudi | Bellandur | Electronic City | Fraser Town | HSR Layout | Indira Nagar | JP Nagar | Kundalahalli | Koramangala | Sarjapur Road) **Mysore** (VV Mohalla)

Online appointments: www.apolloclinic.com

TO BOOK AN APPOINTMENT

1860 500 7788

open



Shashank Mittal

Lead - Software Engineer
OPEN0859

+91 875020069 Emergency Contact No.

+91 8130275421 Chinkal Agrawal

A +ve

Open Financial Technologies Pvt. Ltd.

www.open.in

Fwd: Health Check up Booking Confirmed Request(bobS4702),Package Code-PKG10000366, Beneficiary Code-297951

Chinkal Garg <chinkalgrg1721@gmail.com>

Tue 09-01-2024 08:31

To: Sarjapur Apolloclinic <sarjapur@apolloclinic.com>

----- Forwarded message -----

From: **Mediwheel** <wellness@mediwheel.in>

Date: Mon, Jan 8, 2024, 6:01 PM

Subject: Health Check up Booking Confirmed Request(bobS4702),Package Code-PKG10000366, Beneficiary Code-297951

To: <chinkalgrg1721@gmail.com>

Cc: <customercare@mediwheel.in>

011-41195959

Dear **Chinkal Agrawal**,

We are pleased to confirm your health checkup booking request with the following details.

Booking Date : 08-01-2024

Hospital Package Name : Mediwheel Full Body Annual Plus

Patient Package Name : Mediwheel Full Body Health Checkup Male Below 40

Name of Diagnostic/Hospital : Apollo Clinic

Address of Diagnostic/Hospital- : Apollo Clinic, #769, GYR Chambers, Opp South Indian Bank, Kaikondanahalli, Sarjapur Road -560034

City : Bangalore

State :

Pincode : 560034

Appointment Date : 09-01-2024

Confirmation Status : Booking Confirmed

Preferred Time : 8:00am-8:00am

Booking Status : Booking Confirmed

| Member Information | | |
|--------------------|---------|--------|
| Booked Member Name | Age | Gender |
| Shashank Mittal | 35 year | Male |

Note - Please note to not pay any amount .

Instructions to undergo Health Check:

- Please ensure you are on complete fasting for 10-To-12-Hours prior to check.
- During fasting time do not take any kind of medication, alcohol, cigarettes, tobacco or any other liquids (except Water) in the morning.