

Name	: Deeksha sankhla	Age	: 28Yrs. / F
Thanks To	: Mediwheel wellness	Date	: 12/1/2024

ULTRASOUND STUDY OF WHOLE ABDOMEN

LIVER:

Liver is normal in size, shape & echotexture. No focal mass lesion is seen. Intra hepatic biliary radicles are normal. Portal vein is normal in caliber.

GALL BLADDER :

Gall bladder is contracted. C.B.D. appears normal.

PANCREAS :

Pancreas is normal in size, shape & echotexture. No focal mass lesion is seen.

SPLEEN :

Spleen is normal in size, shape & echotexture. No focal mass lesion is seen.

BOTH KIDNEYS :

Both kidneys are normal in size, shape & echotexture. Renal parenchyma appears normal. No evidence of hydronephrosis, calculus or cortical scarring is seen in either kidney.

Right kidney measures : 10.1x4.1 cms.

Left kidney measures : 9.6 x 4.2 cms.

URINARY BLADDER :

Urinary bladder is well distended and appears normal in contour. The wall thickness appears normal.

UTERUS :

Uterus is AVAF, normal in size, shape and echotexture. It measures 6.0 x 4.5 x 3.8 cms. Endometrial appears normal and measures 6.3 mm.

BOTH OVARIES :

Both ovaries are normal in size, shape and echotexture.

Right ovary measures: 3.0 x 1.7 cms.

Left ovary measures: 3.5 x 1.4 cms.

No obvious abdominal lymphadenopathy is seen.

No free fluid is seen in peritoneal cavity.

OPINION:

- No significant abnormality is seen.

Dr Bharat Jain

Dr Bharat Jain
MD (Radio-Diagnosis)
Consultant Radiologist

(This report is not valid for any Medico-legal purpose)

ENCL:- PCPNDT Registration Certificate is printed on the back side of this report.

2-B, Ground Floor, Court Choraha, Main Road Tehsil Ke Samne, Udaipur 313001 (Raj.)

Mob. : 7229961115, 7229970005, 7229901188

(24 x 7 Customer Service) Email : Kshipralabsudaipur@gmail.com



Name	: Deeksha Sankhla	Age	: 28Yrs. / F
Thanks To	: Health checkup	Date	: 13/01/2024

Echocardiography Final Interpretation

1. No RWMA, Normal LV systolic function, LVEF – 65%
2. Normal Cardiac chamber dimensions
3. Normal LV Diastolic Function.
4. No MR/TR, Normal PASP.
5. No clot/mass/PE pathology.
6. IVC Normal

M-Mode/2-D Description:

- **Left Ventricle:** It is normal sized.
- **Left Atrium:** It is normal sized.
- **Right Atrium:** It is normal sized.
- **Right Ventricle:** It is normal sized. RV systolic function is normal.
- **Aortic Valve:** It appears normal.
- **Mitral Valve:** It appears normal.
- **Tricuspid Valve:** It appears normal.
- **Pulmonic Valve:** It appears normal.
- **Main Pulmonary artery & its branches:** Appear normal.
- **Pericardium:** There is no pericardial effusion.

Doppler Analysis:

- **Pulmonic Regurgitation** : Nil
- **Mitral Regurgitation** : Nil
- **Aortic Regurgitation** : Nil
- **Tricuspid Regurgitation** : Nil
- **Diastolic Parameters** :

Echocardiography

Measurements (mm):

	Observed values	Normal values
Aortic root diameter	22	20-36 (22mm/M ²)
Aortic valve opening		15-26
Left atrium size	23	19-40

	End Diastole	End Systole	Normal Values
Left ventricle size	37	23	(ED=37-56:Es=22-40)
Interventricular septum	10	15	(ED=6-12)
Posterior wall thickness	08	12	(ED=5-10)

LV Ejection Fraction (%)	65%	55%-80%
HR		

Maximum Velocity across valve (cm/s)

Pulmonary	86	Aortic	117

Mitral Inflow Pattern		Normal values
E/A	91/53	1-25
DT		160-200ms
PHT		
PVs:PVd		PVs>PVd



Consultant Radiologist

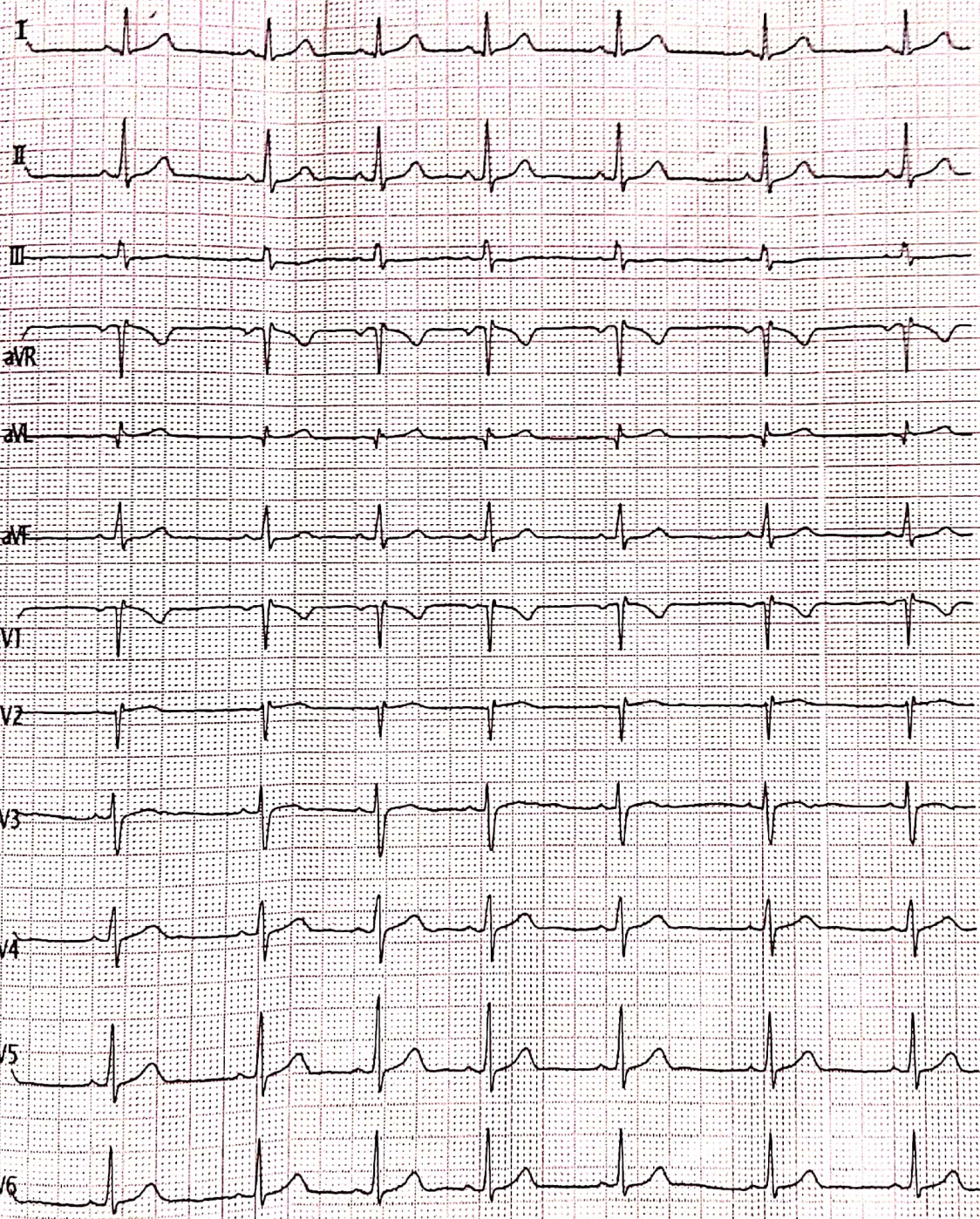
2-B, Ground Floor, Court Choraha, Main Road Tehsil Ke Samne, Udaipur 313001 (Raj.)

Mob. : 7229961115, 7229970005, 7229901188

(24 x 7 Customer Service) Email : Kshipralabsudaipur@gmail.com



10mm/mV



Vent. Rate (BPM) : 71

ECG Analysis Result:

PR Int. (ms) : 129

ECG Sinus Arrhythmia

P/QRS/T Int. (ms) : 94 92 178

ECG rS Pattern in V1/V2

QT/QTc Int. (ms) : 369 405

*** Borderline Abnormal ECG ***

P/QRS/T Axis (Deg) : 40 52 40

RV1/SV5 Amp. (mV) : 0.02 0.28

RV5/SV1 Amp. (mV) : 0.96 0.70

V2-33 Technician

Note: Unconfirmed Report. Need to Review

ST LEVEL (mV)

I	II	III	aVR	aVL	aVF
+0.02	+0.01	+0.00	-0.01	+0.01	+0.00
V1	V2	V3	V4	V5	V6
+0.00	+0.02	+0.03	+0.03	+0.01	+0.01



DEEKSHA JI (C) AR 775510089144 F 28Y

/55 cm/Kg 55/55 mm

MER-MEDICAL EXAMINATION REPORT

DATE OF EXAMINATION	13/01/2024
NAME	DIKSHA SANKHLA
AGE	28YRS /FEMALE
HEIGHT	155 CM
WEIGHT	52 KG
BP	126 / 78
ECG	NORMAL
X-RAY	NORMAL
PRESENT AILMENTS	NO
DETAILS OF PAST AUMENTS (IF AY)	NO
COMMENTS/ADVICE :SHE/HE IS PHYSICALLY FIT	YES



Signature With Stamp Of Medical Examiner



Name	: Deeksha Sankhla	Age	: 28Yrs. / F
Thanks To	: Health checkup	Date	: 13/01/2024

X-RAY CHEST (PA VIEW)

Both lung fields appear normal.

No e/o Koch's lesion or consolidation seen.

Both CP angles appear clear.


Both domes of diaphragm appear normal.

Heart size and aorta are within normal limits.

Bony thorax under vision appears normal.

Both hila appear normal.

Consultant Radiologist



(This report is not valid for any Medico-legal purpose)

2-B, Ground Floor, Court Choraha, Main Road Tehsil Ke Samne, Udaipur 313001 (Raj.)

Mob. : 7229961115, 7229970005, 7229901188

(24 x 7 Customer Service) Email : Kshipralabsudaipur@gmail.com

