



TOURUS HOSPITAL

(A Unit of Tourus Medicare Pvt. Ltd.)

208, Saffour 1st Road, G. T. Road, Bangur-208 207

Ph: 0553-248773, 248774, 248777, 8011300008 • E-mail: tourushospital@gmail.com



M/19/24

2 DECHO

SARICA
YADAV

Normal size LALV, RA IRV


• NO RWMA

• NO METRIAR

• NO PE / Apical clot

• IVC w 12mm
collapsing > 70%
clap

• LVER - 60%



ECG report



Confirm and sign:

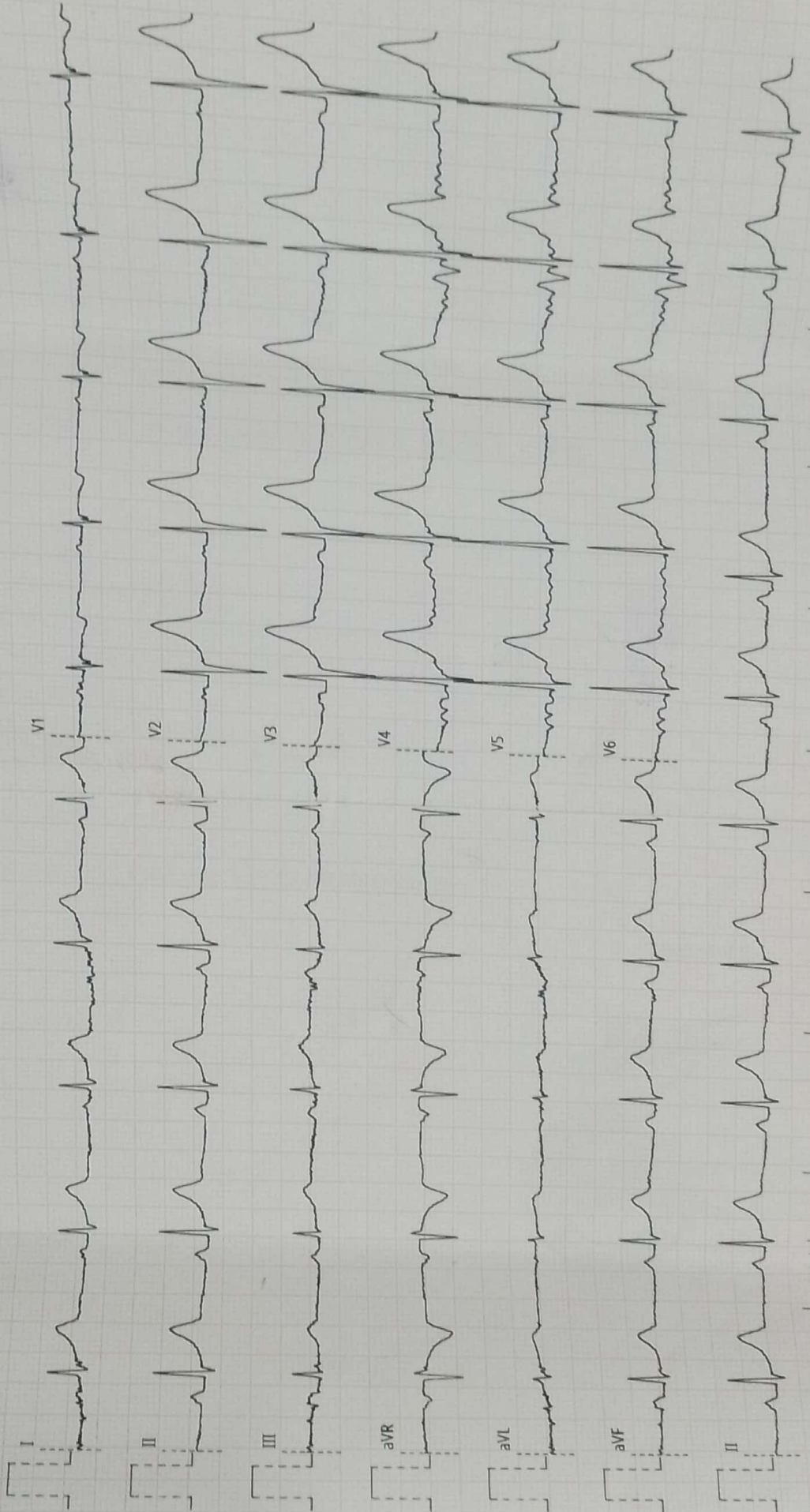
<<Interpretations>>

Sinus arrhythmia

— Interpretation made without knowing patient's gender/age —

Normal ECG

ID : 20240919103510
Name : Sarika
Gender: F
Age : 24 Years
Dept :
Bed No :
HR : 61 bpm
PR : 164 ms
QRS : 76 ms
QT/QTc : 428/430 ms
P/QRS/T : 74/66/53 °
RV5/SV1 : 1.630/0.347 mv
RV5+SV1 : 1.977 mv



0.3Hz - 35Hz - AC 50Hz 25mm/s 10mm/mv 1.0.25 Simultaneous

Examination time: 2024-09-19 10:35:10



Affiliated with CGHS / CAPF
TOURUS HOSPITAL

(A Unit of Taurus Medicare Pvt. Ltd.)

208, Safipur 1st Ramadevi, G. T. Road, Kanpur-208 007

Ph.: 0512-2400779, 2400774, 2400737, 8601955058 • E-mail: tourushospital@gmail.com



<i>Patient Name</i>	SARIKA YADAV	<i>Patient ID</i>	190924-3
<i>Age/D.O.B</i>	24 YRS	<i>Gender</i>	F
<i>Ref Doctor</i>	SELF	<i>Date</i>	19 Sep 24

XRAY RADIOGRAPH CHEST - PA

Observations

Trachea is in the midline.
Both the costophrenic angles are clear.
Hemidiaphragms are normal in position and contour.
Cardiothoracic ratio is within normal limits.
Both the lung fields are clear.
Bony thorax under view is unremarkable.
Hilar shadows appear normal.

Impression

Radiograph chest does not reveal any significant abnormality.

Reported By,



TSMC - TSMC/FMR/30641



RAJNI HOSPITAL



A Unit of Shrimati Rajani Dwivedi Charitable Society
1518/5, Daheli Sujapur, By Pass Road, Kanpur-208013
(Near Koyla Nagar Police Chowki)
GST NO:- 09AARTS9188A1ZR



Helpline No.:

+91 -8004991414

+91 -8004991515

+91 -8004991616

+91 -8933048215

Web : www.rajnihospitalin

Email : rajnihospitalknp@gmail.com

Patient Name : Mrs. SARIKA YADAV
Referred by : Dr. SELF
Investigation : USG Whole Abdomen

Age : 24years/F

Date : 19/09/2024

Liver:

- Liver is normal in size (126mm) and echogenicity. No focal or diffuse lesion seen. Hepatic veins appear normal. No dilation of intrahepatic biliary ducts is seen.

Gall bladder:

- Gall bladder is normal in size and show echo free lumen. Wall thickness is within normal limit. No calculus is seen in GB.

Portal vein:

- Normal in size (mm) and shows normal appearance.

C.B.D.:

- Normal in size (mm) and shows normal caliber.

Pancreas:

- Pancreas is normal in size. No calcification or mass lesion seen.

Spleen:

- Spleen is normal in size. Splenic vein appears normal. No mass lesion or calcification seen.

Right kidney:

- Normal in size (104x47mm) seen in respective renal areas.
- Cortico - medullary differentiation appears to be normal.
- No calculus or mass lesion seen. No hydronephrosis is seen.





RAJNI HOSPITAL



A Unit of Shrimati Rajani Dwivedi Charitable Society
1518/5, Daheli Sujapur, By Pass Road, Kanpur-208013
(Near Koyla Nagar Police Chowki)
GST NO:- 09AARTS9188A1ZR

Helpline No.:

+91 -8004991414

+91 -8004991515

+91 -8004991616

+91 -8933048215

Web : www.rajnihospitalin

Email : rajnihospitalknp@gmail.com

Left kidney:

- Normal in size (108x56mm) seen in respective renal areas.
- Cortico - medullary differentiation appears to be normal.
- No calculus or mass lesion seen. No hydronephrosis is seen.

Ureter:

- Both ureters are normal.

Urinary bladder:

- Normal in size & shape, Wall thickness is normal limit.
- No calculus or mass lesion seen.

Uterus:

- Anteverted with normal in size (74x46x32mm) and morphology. Endometrial cavity is within normal limit. Cervix shows normal sonography. No focal mass lesion noted.

Ovaries/ Adnexa:

- Both ovaries are normal.
- Right ovary measure (mm). Left ovary measure (mm).

Peritoneum/Retroperitoneum:

- Bowel inflammation loops with gas seen in whole abdomen.
- No free fluid seen with cul-de-sac. No lymphadenopathy is seen.

Impression:

➤ BOWEL INFLAMMATION LOOPS WITH GAS

ADV: Please correlate clinically.





TAURUS HOSPITAL



Phone
0512 -2400779
0512 -2400774
0512 -2400737
8601955058

(A Unit of Taurus Medicare Pvt. Ltd.)

208, Safipur 1st Ramadevi G. T. Road, Kanpur-208 007

Pathology Report

Lab. No. : 1070	Date : 2024-09-19 11:09:43.
Patient Name : Miss. SARIKA YADAV	Guardian Name :
Age/Sex : 24 Years/Female	Address : KANPUR,
Referred By : SELF	
0	

Test Name	Observed Values	Unit	Normal Values
-----------	-----------------	------	---------------

Blood Chemistry

KFT

CRET	0.61	mg/dl	0.60 - 1.20 mg/dl
UREA	24.26	mg/dl	15.00 - 45.00 mg/dl
BUN	11.10	mg/dl	5.00 - 25.00 mg/dl
UAC	4.65	mg/dl	2.50 - 7.50 mg/dl

Haematology

CBC (Complete Blood Counts)

HB	11.30	mg/dl	10.10 - 15.50 mg/dl
TLC	6500	/CU MM	4000-11000
DLC		%	
NEUTROPHILL	59	%	40.0-80.0
LYMPHOCYTE	33	%	20.0-40.0
MONOCYTE	04	%	2.0-10.0
EOSINOPHILL	04	%	1.0-6.0
BASOPHILL		%	2.00 - 2.00 %
RBC	4.35	U/L	4.7-7.1
PCV	40.3	%	36.0-46.0
MCV	92.8	FL	83.0-101.0
MCH	25.9	%	11-20
MCHC	28.0	g/dl	31.5-34.5
PLatelet count	2.14	lakh/cum	1.50-4.0
RDW-CV	14.6	%	11.6-14.0

Serology

Blood Group ABO+ Rh "B" POSITIVE

Dr. Vishakha Pal
MBBS,DCP(PATH)



TAURUS HOSPITAL



Phone
0512 -2400779
0512 -2400774
0512 -2400737
8601955058

(A Unit of Taurus Medicare Pvt. Ltd.)

208. Safipur 1st Ramadevi G. T. Road, Kanpur-208 007

Pathology Report

Lab. No. : 1070	Date : 2024-09-19 11:09:43
Patient Name : Miss. SARIKA YADAV	Guardian Name :
Age/Sex : 24 Years/Female	Address : KANPUR,
Referred By : SELF	
0	

Test Name	Observed Values	Unit	Normal Values
Biochemistry			
Lipid Profile (With Direct - HDL & L)			
Cholestrol	171.00	mg/dl	0.00 - 200.00 mg/dl
triglycerides	46.00	mg/dl	0.00 - 150.00 mg/dl
HDL	66.00	mg/dl	35.00 - 80.00 mg/dl
LDL	79.00	mg/dl	0.00 - 130.00 mg/dl
VLDL	21.0	mg/dl	2.00-30.00
Cholesterol/HDL Ratio	2.59	.	<4.00
LDL/HDL cholesterol Ratio	1.19	.	<3.50
HDL/LDL Cholesterol Ratio	0.83	.	<3.50

Blood Chemistry			
L.F.T.			
BILI TOTAL	0.55	mg/dl	0-2.0 mg/dl
BILI DIRECT	0.12	mg/dl	0-0.20 mg/dl
BILI (IND)	0.43	mg/dl	0.20-0.60mg/dl
SGPT(ALT)	26.30	IU/L	up- 34 U/L
SGOT	24.12	IU/L	up-31 IU/L
ALP(ALKALINE PHOSPHATASE)	65.20	IU/L	54-369 IU/L
TOTAL PROTEIN	6.18	g/dl	6.4-8.3 g/dl
ALBUMIN(ALB)	3.29	g/dl	3.5-4.6 g/dl

Dr. Vishakha Pal
MBBS,DCP(PATH)



TAURUS HOSPITAL

(A Unit of Taurus Medicare Pvt. Ltd.)

208. Safipur 1st Ramadevi G. T. Road, Kanpur-208 007



Phone
0512 -2400779
0512 -2400774
0512 -2400737
8601955058

Pathology Report

Lab. No. : 1070	Date : 2024-09-19 11:09:43.
Patient Name : Miss. SARIKA YADAV	Guardian Name :
Age/Sex : 24 Years/Female	Address : KANPUR,
Referred By : SELF	
0	

Test Name	Observed Values	Unit	Normal Values
Biochemistry			
Random Blood Sugar	101.0	mg/dl	70 to 140 mg/dl
Clinical			
URINE R/M			
Colour	straw	.	
Appearance	clear	.	
Specific Gravity	1.015	.	1.005-1.030
Ph	5.0	.	4.5-8.0
Protien	Nil	.	Nil
Glucose	Nil	.	Nil
Pus Cells	2-3	/hpf	0-5
Epithelial Cells	1-2	/hpf	0-5
RBC	Nil	/hpf	Nil
Casts	Not Seen	.	Not Seen
Crystals	Not Seen	.	Not Seen
Hormones & Related Test			
T3, T4 (Total) & TSH 3rd Generation			
T3	2.41	.	1.30-3.10nmol/L
T4	96.31	.	66.00-181.00nmol/L
TSH	3.62	.	0.45-4.50MIU/L

Dr. Vishakha Pal
MBBS,DCP(PATH)