



### Out Patient Record

NABH No.1  
Patient Name : Mrs. JYOTHI L  
Age / Sex : 45 Years / Female  
Spouse / Father Name : SHAILESH D S  
Address : KORMANGALA , , Bengaluru Urban,  
Karnataka, INDIA,  
UHID : UHJA24008244  
OP NO/Reg Dt : 18-11-2024 08:42 AM  
Department :  
Referred By :  
Consultant : Dr. Ashmitha Padma MBBS, MD  
(GENERAL MEDICINE), PGDCC, FEM  
KMC No. : 02M1087

#### Complaints / Findings / Observations :

HT - 138/80  
wt - 53.3 kg

SpO<sub>2</sub> : 99.1

HR : 85 bts/min

#### Investigations:

BP : 127/86 mmHg

#### Treatment / Care of Plan / Provisional Diagnosis :

#### Follow Up Advice :

Signature of the Doctor



NABH



No.1



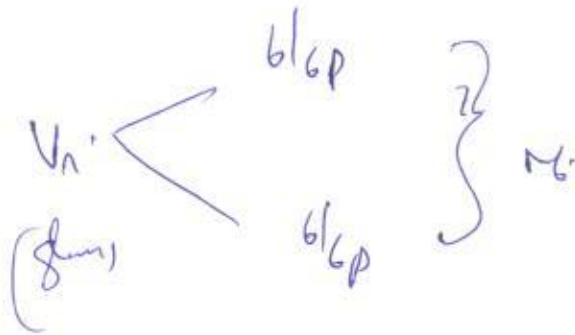
**UNITED HOSPITAL**

Care Par Excellence  
Jayanagar, Bangalore

Jyothi. L  
45 Y / female

ophthomology  
18/11/2014

Dr. Shwetha .



Di: ov normal

Fund's ov C/D/E 0.3:1  
(undilated) FFA)

If: ov Rf Eye

Continue same glass



NABH



No.1

Care Par Excellence  
Jayanagar, Bangalore

Patient name :	Mrs. JYOTHI L	Date :	18/11/24	
Age :	45 Years	Sex: FEMALE	UHID :	24008244
Ref by :	CMO	OP/IP :	HEALTH CHECK	

**2D- ECHOCARDIOGRAPHY**  
**M - MODE AND DOPPLER MEASUREMENTS**

(c.m)	(c.m)	(cm/sec)	
AO : 2.6 (2.5-3.7)	LVIDD : 3.5 (3.5-5.5)	MV EV : 0.6	AV : 0.4 MR : NORMAL
LA : 3.3 (1.9-4.0)	LVIDS : 2.4 (2.4-4.2)	AV : 1.1	AR : NORMAL
RA : 1.9 (<4.4)	IVSD : 1.0 (0.6-1.1)	PV : 0.8	PR : NORMAL
RV : 1.5 (<3.5)	IVSS : 0.9 (0.9-1.2)	TV EV : ---	AV : --- TR : TRIVIAL TR, PASP-30mmHg
TAPSE: 1.8 (>1.6)	LVPWD :0.8 (0.6-1.1)	Diastolic Function : NO LVDD	
	LVPWS : 0.9 (0.9-1.2)		
	EF : 60%		

**DESCRIPTIVE FINDINGS**

Left Ventricle	: NORMAL
Right Ventricle	: NORMAL
Left Atrium	: NORMAL
Right Atrium	: NORMAL
Wall motion analysis:	NO RWMA
Mitral Valve	: NORMAL
Aortic Valve	:NORMAL
Tricuspid Valve	: NORMAL
Pulmonary Valve	: NORMAL
IAS	: INTACT
IVS	: INTACT
Pericardium	: NORMAL
Other Findings	: IVC NORMAL

**IMPRESSION :**

NORMAL CHAMBER DIMENSIONS  
 NORMAL LV SYSTOLIC FUNCTION EF : 60%  
 NORMAL LV DIASTOLIC FUNCTION  
 NO PULMONARY ARTERY HYPERTENSION  
 NO REGIONAL WALL MOTION ABNORMALITIES  
 NO CLOTS/ PERICARDIAL EFFUSION /VEGETATION

**DR. RAHUL PATIL**  
 CONSULTANT CARDIOLOGIST

UNITED HOSPITAL (A Unit of United Brothers Healthcare Services Private Limited)

**United Hospital**

No.110 (30), Madhavan Park Circle, 10th Main Rd,

T: 080 4566 6666

E: appointments@unitedhospital.in





NABH



No.1

### DEPARTMENT OF RADIODIAGNOSIS

Name	Jyothi L	Date	18/11/24
Age	45 years	Hospital ID	UHJA24008244
Sex	Female	Ref.	Health check

### BILATERAL SONOMAMMOGRAPHY

#### FINDINGS:

Skin and subcutaneous fat of bilateral breasts appear normal.

Heterogeneous background echotexture is seen in both breasts.

*There is small simple cyst measuring 7 x 5 x 4 mm in right breast at 12 o'clock position.*

No focal solid / other cystic lesions seen.

Ducts appear normal.

No significant lymphnodes noted in bilateral axilla.

#### IMPRESSION:

- Small cyst in right breast at 12 o'clock position. BIRADS 2 - Benign.
- No other significant abnormality detected in this study.



Dr. Elluru Santosh Kumar  
Consultant Radiologist



NABH

No.1

**DEPARTMENT OF RADIODIAGNOSIS**

<b>Name</b>	Jyothi L	<b>Date</b>	18/11/24
<b>Age</b>	45 years	<b>Hospital ID</b>	UHJA24008244
<b>Sex</b>	Female	<b>Ref.</b>	Health check

**ULTRASOUND ABDOMEN AND PELVIS**

**FINDINGS:**

**Liver is enlarged in size (15.2 cms) and shows moderately increased echopattern.** No intra or extra hepatic biliary duct dilatation. No focal lesions. **Portal vein** is normal in size, course and caliber. **CBD** is not dilated.

**Gall bladder** is normal without evidence of calculi, wall thickening or pericholecystic fluid.

**Pancreas** - Visualized part of the pancreatic head and body appears normal in size, contour and echogenicity. Rest of the pancreas is obscured by bowel gas.

**Spleen** is normal in size, shape, contour and echopattern. No evidence of mass or focal lesions.

**Right Kidney** is normal in size (9.7 x 3.1 cms), position, shape and echopattern. Corticomedullary differentiation is maintained. No evidence of calculi or hydronephrosis.

**Left Kidney** is normal in size (10.2 x 3.1 cms), position, shape and echopattern. Corticomedullary differentiation is maintained. No evidence of calculi or hydronephrosis.

**Retroperitoneum-** Visualized aorta appeared normal. No obvious enlarged para-aortic nodes.

**Urinary Bladder** is over distended, normal in contour and wall thickness. No evidence of calculi.

**Uterus** is anteverted and normal in size, measures 7.3 x 3.6 x 4.6 cms. Myometrial echoes are normal. Endometrium measures 6 mm.

**Right ovary** is normal in size and echopattern, measures 3.6 cc.

**Left ovary** is normal in size and echopattern, measures 5.4 cc.

**Both adnexa:** Normal. No mass is seen.

There is no ascites or pleural effusion. Appendix could not be localized. No RIF probe tenderness.

**IMPRESSION:**

- **Mild hepatomegaly with moderate fatty infiltration (Grade II).**
- **No other definite sonological abnormality detected.**

**Dr. Elluru Santosh Kumar**  
Consultant Radiologist

**UNITED HOSPITAL** (A Unit of United Brothers Healthcare)



NABH



No.1



## DEPARTMENT OF RADIODIAGNOSIS

<b>Name</b>	Jyothi L	<b>Date</b>	18/11/24
<b>Age</b>	45 years	<b>Hospital ID</b>	UHJA24008244
<b>Sex</b>	Female	<b>Ref.</b>	Health check

### RADIOGRAPH OF THE CHEST (PA – VIEW)

#### FINDINGS:

Bilateral lung fields are normal.

Bilateral costo-phrenic angles are normal.

Cardia and mediastinal contours are normal.

The bony thorax is grossly normal.

#### IMPRESSION:

- No radiographic abnormality.

**Dr. Elluru Santosh Kumar**  
Consultant Radiologist





NABH



No.1



Care Par Excellence  
Jayanagar, Bangalore

Mrs. Yogesh - L 45y

18/11/24

Dr. Yoga Lakshmi SK  
MBBS, MCh OBG, FMAIS  
Consultant Obstetrician and  
Gynecologist, Laparoscopy  
and IVF Specialist  
KMC Reg. No. 90304

A left hand

2/16 HONI

to h) ov, shj  
for com  
10/10 Product Con - Ardy  
Ma - 8/10  
Ms - 9/10  
Ar - 1/10

1/4  
Lay  
Not tubular  
Not an embryo  
100 - 13/11/24  
Pr 2/24

Stand usage of under Brother  
Any You - So sorry



ID: 24008244

Name: MRS JYOTHI

18-Nov-2024 AM9:59:51

Sex: F      Birth date: /      45 years  
 cm      kg      /      mmHg

Indication:  
 Symptoms:  
 history:  
 bnt. rate

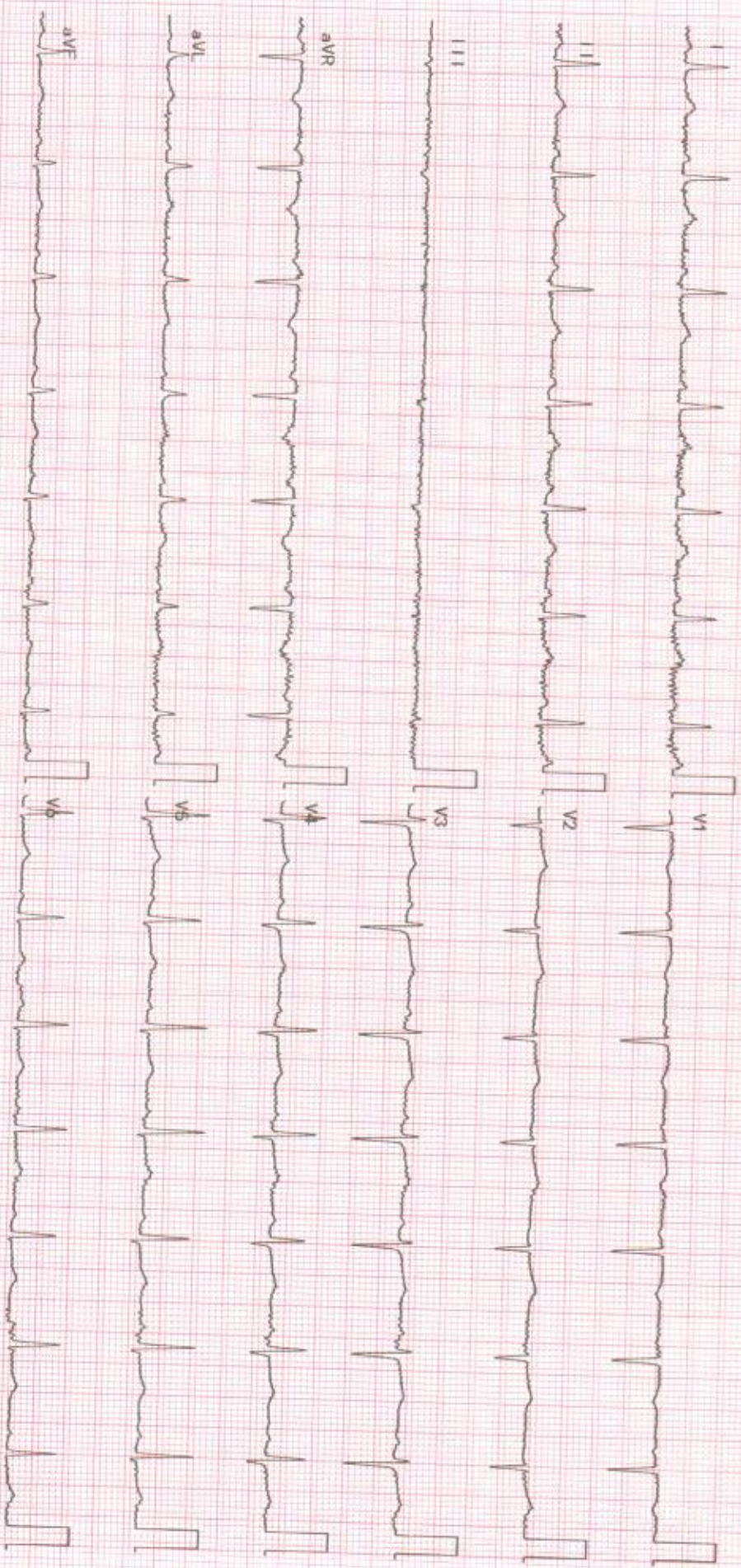
1100 Sinus rhythm  
 0102 ARTIFACT PRESENT  
 9110 \*\* normal ECG \*\*

R int      85 bpm  
 RS dur      140 ms  
 P/QRS/T axis      354 / 396 ms  
 V5/SV1 amp      26 / 23 / 30 mV  
 V5/AV1 amp      1.01 / 0.83 mV  
 V5/AV1 amp      1.84 mV

10 mm/mV    25 mm/s    Filter: H50 D 35 Hz

10 mm/mV

Unconfirmed Report  
 Reviewed by:



2350K 03-08 07-01

Dept.:

Exam: UNITED HOSPITAL