

Mr Rishabh Singh
ID: 4711951

Male

32 Years

14.09.2024 12:27:26

tenet
Indiranagar
Bangalore

61 bpm
- / - mmHg

Normal sinus rhythm with sinus arrhythmia
Normal ECG

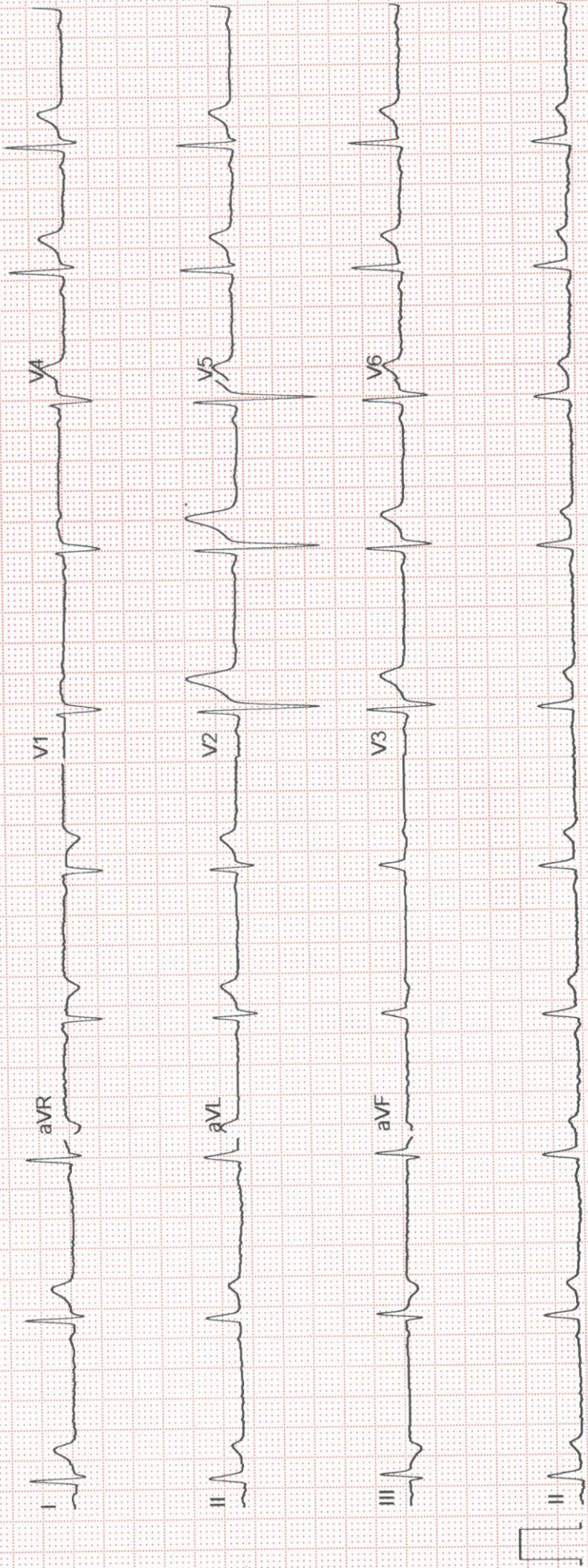
QRS 86 ms
QT/QTcBaz 338 / 340 ms
PR 130 ms
P 84 ms
RR/PP 988 / 983 ms
P/QRS/T 2 / 43 / 1 degrees

Technician
Ordering Ph
Referring Ph
Attending Ph

ACORDAX ECG

[Signature]

Dr MAHADEV SWAMY B
MBBS, MD (Internal Medicine),
DVI Cardiology (IIPMER), FSCM, FICC
Consultant - Interventional Cardiology



Name	MR.RISHABH SINGH	Req NO :4711951
Age & Gender	32Y/MALE	Registered on:14.09.2024
Ref Doctor	CREDIT CLIENTS	Reported on:14.09.2024

2D ECHOCARDIOGRAPHY & COLOUR DOPPLER REPORT

M-mode:

	Value	Normal range
LA dimension	3.4	(1.9 – 4.0 cm)
Aorta	3.1	(2.5 – 3.7 cm)
IVS (d)	1.2	(0.6 – 1.1 cm)
LV PW (d)	1.2	(0.6- 1.1 cm)
LVID (d)	4.2	(3.5 – 5.5 cm)
LVID (s)	2.8	(2.4 – 4.2 cm)
EDV	81	ml
ESV	29	ml
LV EF	62%	50 – 70 %

CHAMBERS:

LEFT ATRIUM: Normal

RIGHT ATRIUM: Normal

LEFT VENTRICLE: Normal

RIGHT VENTRICLE: Normal

VALVES:

MITRAL VALVE: Normal

AORTIC VALVE: Normal

TRICUSPID VALVE: Normal

PULMONARY VALVE: Normal

GREAT ARTERIES:

AORTA: Normal

PULMONARY ARTERY: Normal

Tenet Diagnostics Pvt. Ltd.

CIN: U85110KA2021PTC149219

No.46, 27th Cross, 3rd Main Road, Municipal No. 6A, 7th Block, Jayanagar, Bangalore, Karnataka-560011.

Ph.: +91 98863 48863, 080-49364444 | www.tenetdiagnostics.in | info@tenetmedcorp.com

SEPTAE:
IAS/IVS: Intact

WALL MOTION ABNORMALITIES:

REGIONAL : No RWMA

GLOBAL: Normal

COLOUR DOPPLER:

MITRAL VALVE: TRIVIAL MR , E/A : 1.28

AORTIC VALVE: Normal

TRICUSPID VALVE: TRIVIAL TR, PASP- 31mmHg

PULMONARY VALVE: Normal

CLOT/ VEGETATION: Nil

PERICARDIUM: No effusion

IVC : NORMAL & COLLAPSING

CONCLUSION:

- CONCENTRIC LVH+
- NORMAL VALVES
- NO REGIONAL WALL MOTION ABNORMALITIES
- NORMAL LV SYSTOLIC FUNCTION (EF: 62%)
- IAS INTACT
- NORMAL PA PRESSURE
- NO CLOT/ VEG / PERICARDIAL EFFUSION


Dr. MAHADEV SWAMY B
MBBS, MD, DM Cardiology (JIPMER), FSCAI, FICC
Consultant & Interventional Cardiologist
KMC No 75242

Tenet Diagnostics Pvt. Ltd.

CIN: U85110KA2021PTC149219

No.46, 27th Cross, 3rd Main Road, Municipal No. 6A, 7th Block, Jayanagar, Bangalore, Karnataka-560011.

Ph.: +91 98863 48863, 080-49364444 | www.tenetdiagnostics.in | info@tenetmedcorp.com

32 Years Male

14.09.2024 12:27:26
Inder Nagar
Bangalore

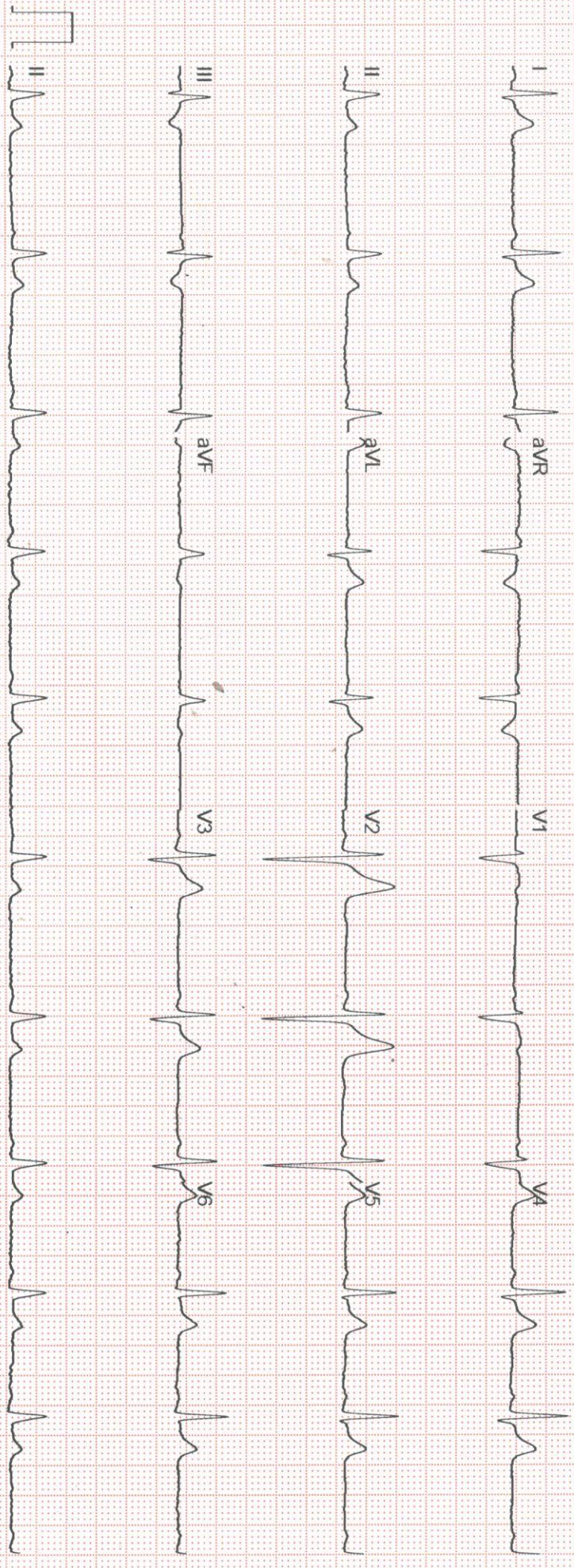
QRS	86 ms
QT/QTcBaz	338 / 340 ms
PR	130 ms
P	84 ms
RR/PP	988 / 983 ms
P/QRS/T	2 / 43 / 1 degrees

Normal sinus rhythm with sinus arrhythmia
Normal ECG

ACDASAK CCG

Technician:
Ordering Ph:
Referring Ph:
Attending Ph:

DR. MAHADEV SWAMY B
MBBS, MD (Internal Medicine),
EM Cardiology (ABIM/ACC), FSCAI, FACC
Consultant - Interventional Cardiology



GE MAC2000 1-1 12SL™ V241

25 mm/s 10 mm/mV

ADS 0.56-20 Hz 50 Hz 4x2.5x3 25 R1

Unconfirmed

1/1

01 bpm
- / - mmHg

-0.38 -4
 -0.38 -0.38 100
 -0.38 -0.38 100
 25H CAT VX
 CALL: 101W: WIX
 (BEE) AD: 13 '00

TENET DIAGNOSTICS

Customer Name	Mr. Disha Singh	Customer ID	BIC 42/1951
Age & Gender	32 yrs / Male	Visit Date	14/9/24

Eye screening

with spectacles / with out spectacles (strike out whichever is not applicable)

	Right eye	Left eye
Near Vision	—	—
Distance Vision	Normal (6)	Normal (6)
Colour Vision	—	—

6/6

observation / comments
 Eye sight is Normal,