



 GPS Map Camera

**Raipur, Chhattisgarh, India**

6J6W+C64, Krishna Nagar, Santoshi Nagar, Raipur, Mathpurena, Chhattisgarh 492001, India

Lat 21.21105°

Long 81.645669°

14/09/24 11:01 AM GMT +05:30



Google



भारतीय विशिष्ट ओळखे प्राधिकरण

भारत सरकार

Unique Identification Authority of India

Government of India

नोंदविण्याचा क्रमांक / Enrollment No.: 2006/31279/18188


To  
मीनल विजयेंद्र गजभिये  
Minal Vijayendra Gajbhiye  
YD Vijayendra Gajbhiye  
Plot No. 1015 Near Corporation School  
Beside Ideal Academy Of Science Ashirwad Nagar  
Ayodhya Nagar  
Ayodhya Nagar  
Nagpur Nagpur  
Maharashtra 440024  
7720033866

11/10/2013

65187905



MD651879050FH




आपला आधार क्रमांक / Your Aadhaar No. :

**2951 6647 6839**


माझे आधार, माझी ओळख



भारत सरकार



मीनल विजयेंद्र गजभिये  
Minal Vijayendra Gajbhiye  
जन्म तारीख / DOB : 02/11/1988  
स्त्री / Female



**2951 6647 6839**

माझे आधार, माझी ओळख



PATIENT NAME .....  
AGE/SEX .....  
REF. BY .....

MRS. MINAL VIJAYENDRA GAJBHIYE  
36 YRS / FEMALE  
MEDIWHEEL

DATE- 14-Sep-24

## **X-RAY CHEST PA VIEW**

### **Observation & Impression**

- Bilateral lung fields are clear.
- Both costophrenic angles are normal.
- Bilateral hila are normal.
- The cardiac shadow is normal.
- The bony thorax is normal.

**IMPRESSION** No significant abnormality is seen.

*Needs clinical correlation & other investigations.*

  
Dr. Hulesh Mandle, MD  
Consultant Radiologist  
BR. HULESH MANDLE  
MBBS, MD  
TGM 223104

Investigations have their limitation, solitary radiological / pathological and other investigations never confirm the final diagnosis of a disease. They only help in diagnosing the disease in correlation to symptom and other related test please interpret accordingly.

**Note-**

1. The report & film are not valid for medico-legal purpose.
2. Please intimate us if any typing mistakes & send the report for correction within 7 days.





PATIENT NAME .....  
AGE/SEX .....  
REF. BY .....

DATE- 14-Sep-24  
MRS. MINAL VIJAYENDRA GAJBHIYE  
36 YRS / FEMALE  
MEDIWHEEL

## USG OF BOTH BREASTS

- Both the breasts parenchyma appears normal in echotexture.
- No obvious mass lesion noted. No calcification is seen.
- Ductal system otherwise appears normal.
- Skin and subcutaneous tissue appears normal.
- Bilateral axillae are clear.

### IMPRESSION:

✂ No significant abnormality detected.

*Needs clinical correlation & other investigations.*



Dr. Hulesh Mandle, MD  
Consultant Radiologist  
MBBS, MD  
CGMC-223/04

*Investigations have their limitation, solitary radiological / pathological and other investigations never confirm the final diagnosis of disease. They only help in diagnosing the disease in correlation to symptom and other related test please interpret accordingly.*

#### Kindly Note:-

- The report and films are not valid for medico – legal purpose.
- Please Intimate us if any typing mistakes and send the report for correction within 7 days.

PATIENT NAME .....  
AGE/SEX .....  
REF. BY .....

DATE- 14-Sep-24  
MRS. MINAL VIJAYENDRA GAJBHIYE  
36 YRS / FEMALE  
MEDIWHEEL

## COLOUR DOPPLER ECHOCARDIOGRAPHY

PROCEDURES: M-MODE/2D/DOPPLER/COLOUR/CONTRAST.

### MEASUREMENTS:

AO	~	2.5 CMS
LA	~	3.3 CMS.
LVDd	~	3.9 CMS.
LVDs	~	2.2 CMS.
IVSd	~	0.9 CMS.
LVPWd	~	0.9 CMS.

### DOPPLER

E	~	1.1 M/SEC.
A	~	0.8 M/SEC.
AO	~	1.8 M/SEC.

- NORMAL LV AND RV SIZE AND FUNCTION.
- NORMAL PERICARDIUM. NO PERICARDIAL EFFUSION.
- NORMAL PA & AORTA.

### OPINION: -

- ☞ NORMAL CHAMBER SIZE.
- ☞ NO RWMA.
- ☞ GOOD LV SYSTOLIC FUNCTION.
- ☞ JERKY SEPTAL MOTION.
- ☞ EF 55%
- ☞ NO CLOT/MASS



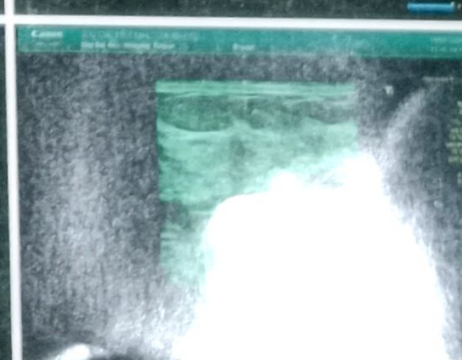
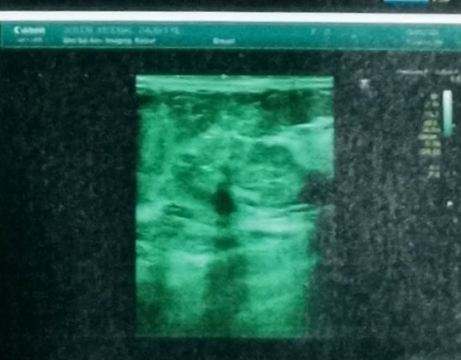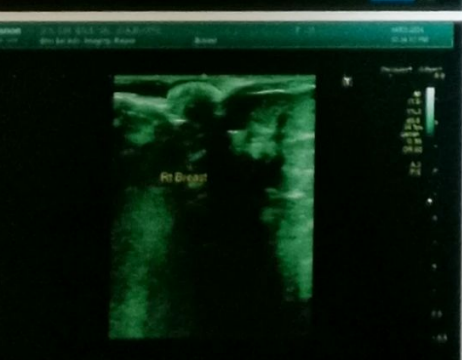
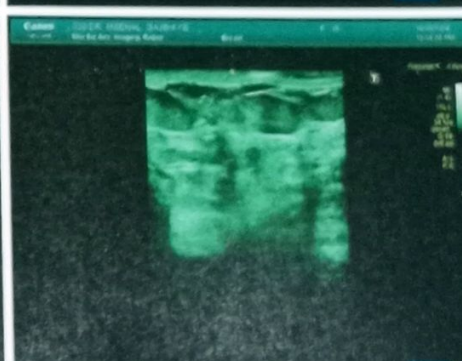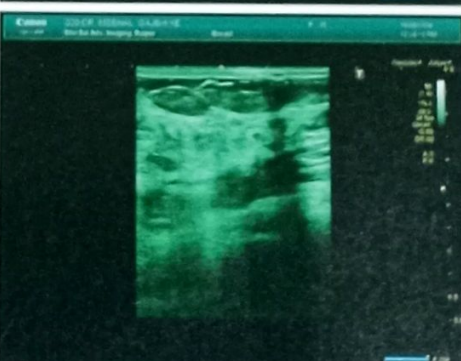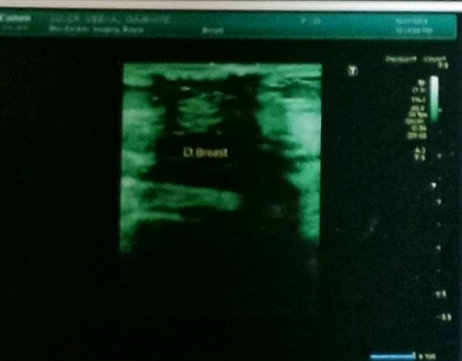
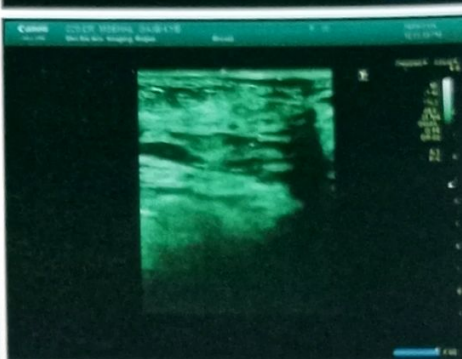
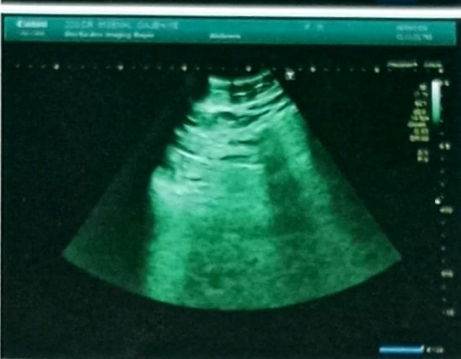
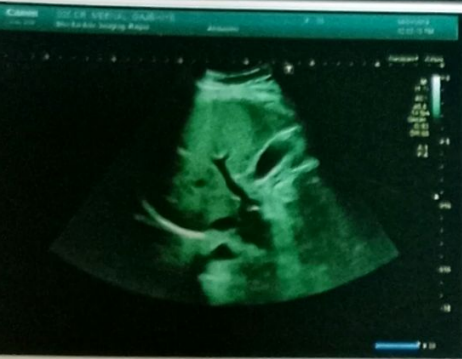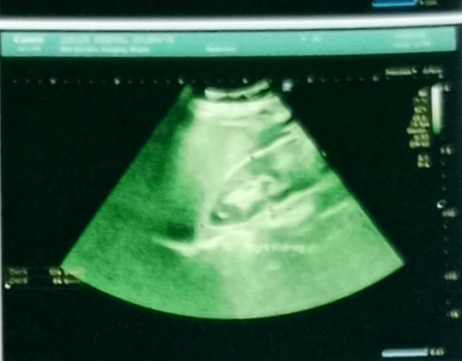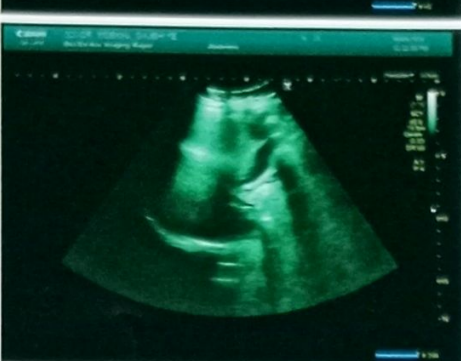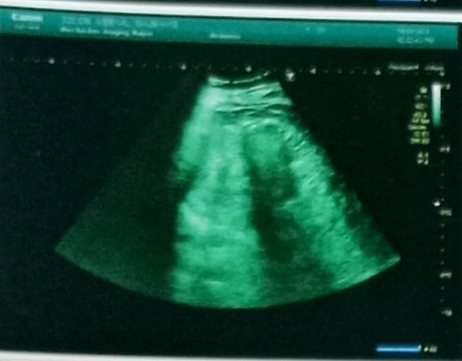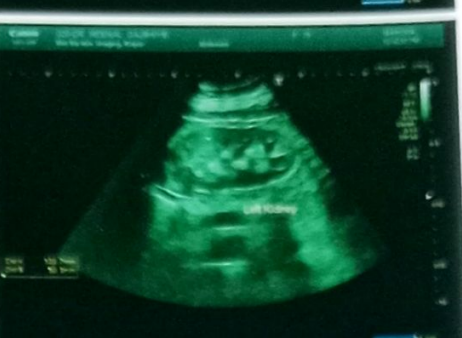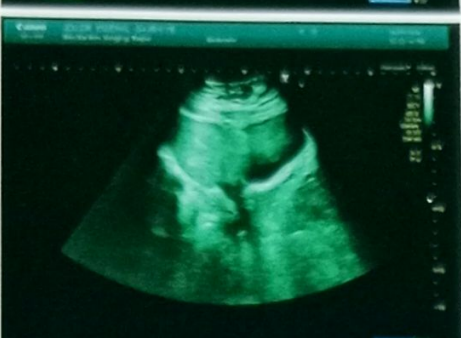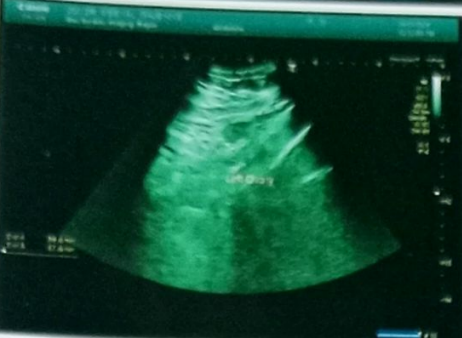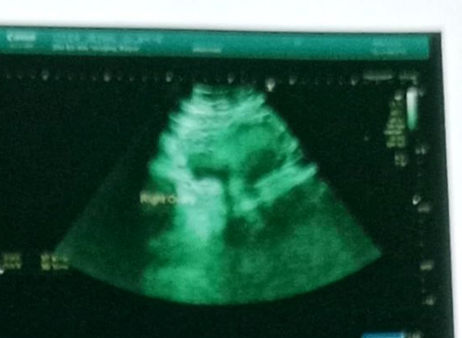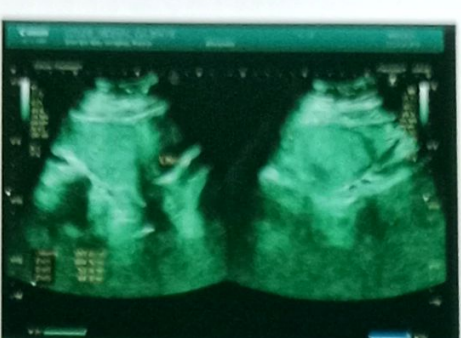
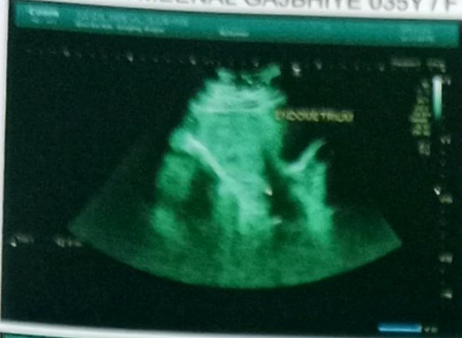DR. SAWAN AGRAWAL  
(MBBS, MD, DNB Cardiology)

Diagnostic Center  
Krishna Nagar,  
Near Vihar Gali, Santoshi Nagar,  
Raipur (C.G.) 492004

Investigations have their limitation, solitary radiological / pathological and other investigations never confirm the final diagnosis of disease. They only help in diagnosing the disease in correlation to symptom and other related test please interpret accordingly.



14 Sep 2024 Study : Abdomen  
Name : DR MEENAL GAJBHIYE 035Y / F





PATIENT NAME .....  
AGE/SEX .....  
REF. BY .....

MRS. MINAL VIJAYENDRA GAJBHIYE  
36 YRS / FEMALE  
MEDIWHEEL

DATE- 14-Sep-24

## SONOGRAPHY OF THE ABDOMEN + PELVIS

PROCEDURE DONE BY ULTRASOUND MACHINE Canon Apilo a450 (4D COLOR DOPPLER)

LIVER	:	The liver is normal in size, shape & contour with normal echotexture. No evidence of any Focal lesion or mass seen. The intrahepatic biliary ducts are normal. The CBD is normal in course, caliber & contour. Hepatic & portal vein appear normal in morphology.
GALL BLADDER	:	well distended & shows normal wall thickness. No obvious intraluminal calculus.
PANCREAS	:	appears normal in size, shape & echo pattern. Pancreatic duct appears normal.
SPLEEN	:	Spleen is normal size, shape and position. No focal lesion seen.
KIDNEY	:	Right kidney measures ~ 10.4 x 4.4 cm Left kidney measures ~ 12.2 x 5.0 cm Both Kidneys are normal size, shape and position. Renal parenchymal echogenicities are normal. No evidence of any calculus or pelvicalyceal dilation.
URINARY BLADDER:		UB is well distended with normal wall thickness. No evidence of mass /calculus.
UTERUS	:	<b>Anteverted bulky uterus &amp; measuring 10.4 x 5.2 x 6.6 cm &amp; vol-193.0 cc</b> Centrally situated endometrium is normal (1.2 mm). Myometrium is normal.
OVARY	:	Right ovary measures ~ 3.7 x 3.0 cm. Left ovary measures ~ 3.9 x 1.7 cm. Both ovaries are normal in size, shape and echotexture.
RETRO PERITONEUM	:	No evidence of lymphadenopathy / mass.
FREE FLUID	:	No free fluid seen in abdomen & peritoneal cavity.

### IMPRESSION :

- Bulky uterus.

Needs clinical correlation & other investigations.



Dr. Hulesh Mandale, MD  
Consultant Radiologist  
M.B.B.S. M.D.  
CGMC-223104

### Kindly Note:-

- The report and films are not valid for medico - legal purpose.
- Please Intimate us if any typing mistakes and send the report for correction within 7 days.
- कृपया अगली बार जांच के लिए आने पर पुराना रिपोर्ट साथ में लावे ।

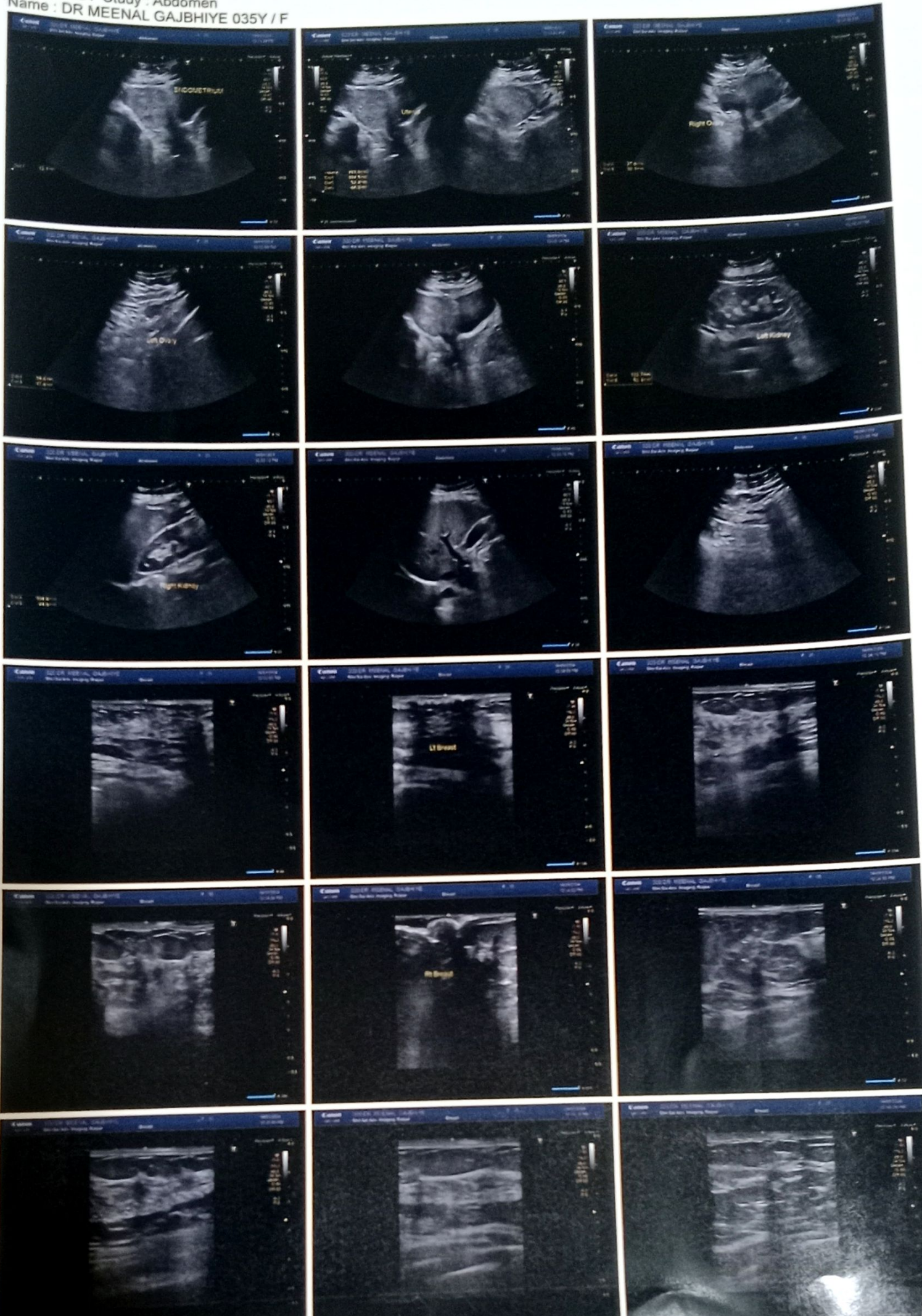सही जाँच ही सही ईलाज का आधार है

mail : shrisaimaging@gmail.com, Website : www.shrisaidiagnostic.com



# SHRI SAI ADVANCE IMAGING & DAIGNOSTIC CENTER, SANTOSHI NAGA R

14 Sep 2024 Study : Abdomen  
Name : DR MEENAL GAJBHIYE 035Y / F





A Unit of Diagnostic Care with Trust



# श्री साई एडवांस इमेजिंग एंड डायग्नोस्टिक सेंटर

PVT.LTD.

हर जीवन  अमूल्य है

पुराना धमतरी रोड, सब्जी बाजार के सामने,  
संतोषी नगर, रायपुर (छ.ग.) ☎ 0771-4023900


CT Scan | 4D Color USG | Digital X-Ray | Advance Pathology | 2D Echo / E.C.G. / TMT / E.E.G. / OPG / SPIRO

Date:- 14-09-2024

Dear Diagnostic Center,

Due to a lack of time, we will only be unable to complete the following tests for the packages: Eye, Dental, Pap Semer and consultation. We kindly request that the center skip the remaining tests.

Thank you for your understanding.

  
Mural Gajbhiye

सही जाँच ही सही ईलाज का आधार है...

shrisaiimaging@gmail.com, Website : www.shrisaidiagnostic.com



Patient:

MRS. DR. MINAL GAJBHIY

35 year / F

..... cm / ..... kg

HR 71/min

P 52

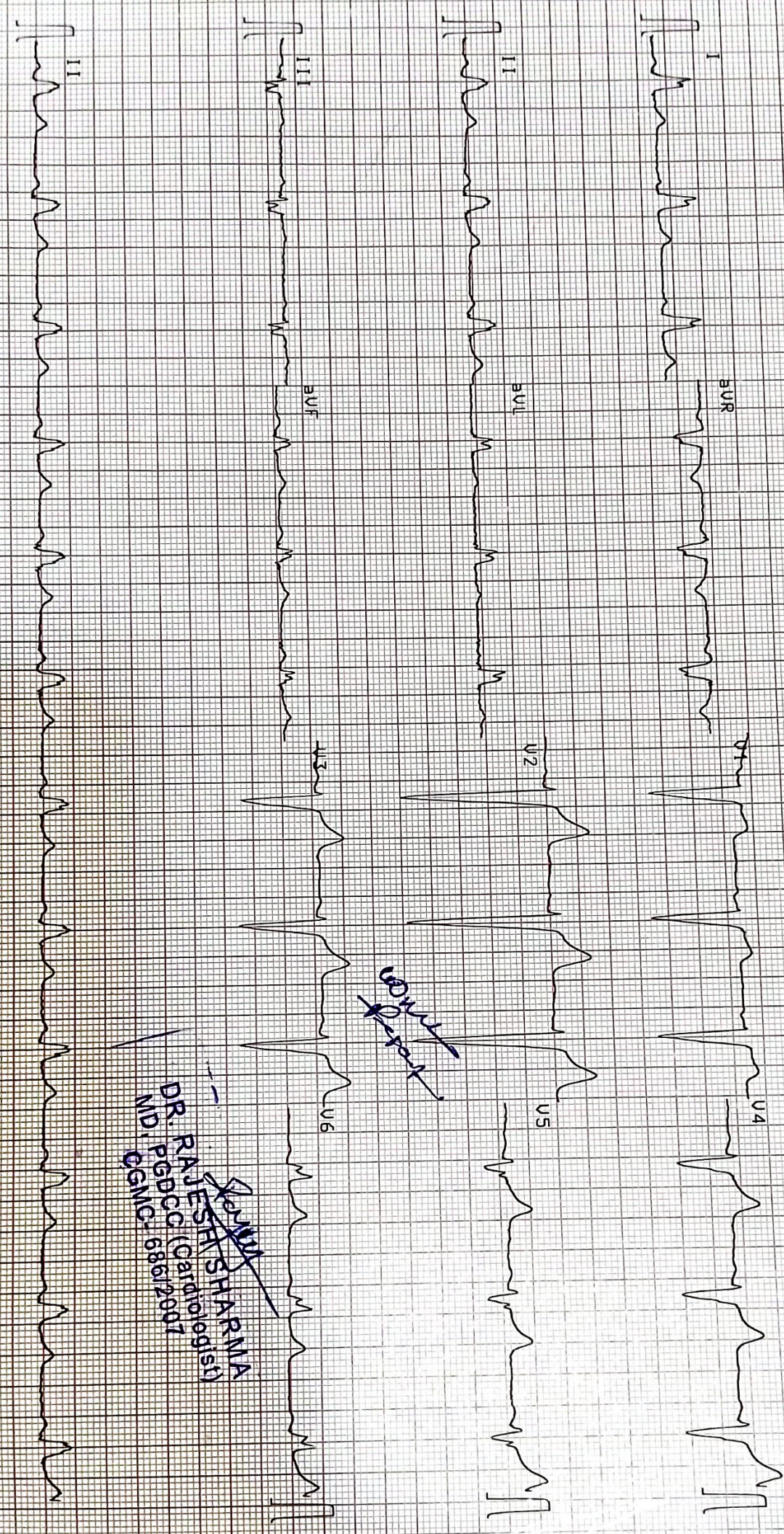
LEFT BUNDLE BRANCH BLOCK

UNCONFIRMED REPORT

Intervals:		P (II)	
RR	841 ms	QRS	20
P	120 ms	T	42
PR	152 ms	P (II)	0.10 mV
QRS	126 ms	S (V1)	-1.51 mV
QT	406 ms	R (V5)	0.17 mV
QTc	446 ms	Sokol.	2.98 mV

10 mm/mV

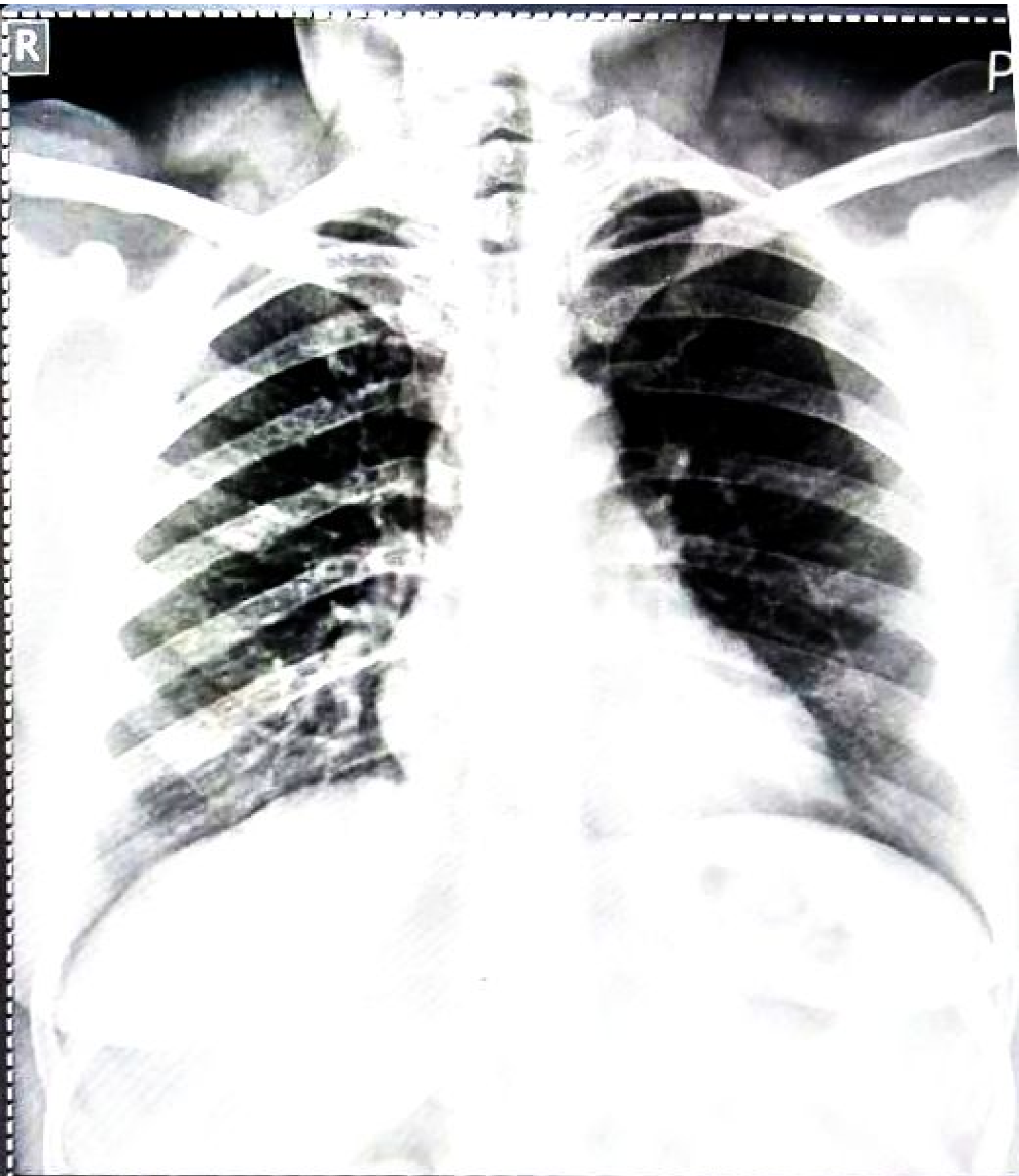10 mm/mV



~~SHARMA~~  
**DR. RAJESH SHARMA**  
 (Cardiologist)  
 MD, PGDCC (Cardiologist)  
 MD, CGMC - 686/2007

75 mm/s F50 50F 50F 1R=558=24 22.56.43 QT=220ms V1 V2 V3 V4 V5 V6 4.14 CM





R

P