












Aadhaar Card.pdf



  <p>भारतीय विशिष्ट पहचान प्राधिकरण भारत सरकार Unique Identification Authority of India Government of India</p> <p>नामांकन क्रमांक/ Enrolment No.: XXXX/XXXXX/XXXXX</p> <p>To अतुल रघुवंशी Atul Raghuvanshi S/O: Vijendra Pratap Singh DHAURAHARA Kadipur Chaubeypur Varanasi Uttar Pradesh-221104</p> <p>Download Date: 17/02/2018 Generation Date: 11/02/2018</p> <p>Signature Not Verified</p>  <p>आपका आधार क्रमांक / Your Aadhaar No. : 5199 2859 2905 मेरा आधार, मेरी पहचान</p>	  <p>सूचना</p> <ul style="list-style-type: none"> ■ आधार पहचान का प्रमाण है, नागरिकता का नहीं। ■ पहचान का प्रमाण ऑनलाइन ऑथेंटिकेशन द्वारा प्राप्त करें। ■ यह एक इलेक्ट्रॉनिक प्रक्रिया द्वारा बना हुआ पत्र है। <p>INFORMATION</p> <ul style="list-style-type: none"> ■ Aadhaar is a proof of identity, not of citizenship. ■ To establish identity, authenticate online. ■ This is electronically generated letter. <div style="border: 1px solid black; padding: 5px;"> <ul style="list-style-type: none"> ■ आधार देश भर में मान्य है। ■ आधार भविष्य में सरकारी और गैर-सरकारी सेवाओं का लाभ उठाने में उपयोगी होगा। ■ Aadhaar is valid throughout the country. ■ Aadhaar will be helpful in availing Government and Non-Government services in future. </div>
 <p>भारत सरकार Government of India</p>  <p>अतुल रघुवंशी Atul Raghuvanshi जन्म तिथि/DOB: 01/07/1987 पुरुष/ MALE</p>  <p>5199 2859 2905 मेरा आधार, मेरी पहचान</p>	 <p>भारतीय विशिष्ट पहचान प्राधिकरण Unique Identification Authority of India</p> <p>Address: S/O: Vijendra Pratap Singh, DHAURAHARA, Kadipur, Varanasi, Uttar Pradesh, 221104,</p> <p>पता: S/O: विजेंद्र प्रताप सिंह, धौरहरा, कादपूर, वाराणसी, उत्तर प्रदेश, 221104,</p> <p>5199 2859 2905</p>





PANACEA HOSPITAL

B 36/44 F.K KABIR NAGAR, DURGAKUND
TOLLFREE NO-18001233070. Whatsapp No - 8795832852
www.piire.org
panaceaquery@gmail.com|panaceahospital@gmail.com



OP Slip

Print Date : 22-Feb-2024 10:45AM



UHID No	:- UD-23240006341	OP No	:- OP-23240019417	OP Date	:- 22 Feb 2024 10:44AM
Patient Name	:- Mr ATUL RAGHUVANSHI	Age/Sex	:- 36 Y/Male	Mobile No	:- 8726300729
Father	:- VIJENDRA PRATAP SINGH	Department	:- GENERAL MEDICINE		
Pay Type	:- Cr	Consultant	:- Dr Pallavi Mishra (MBBS,MD,MBBS)		
Token No	:- NOR. - 2	Paid/Bal	:- 0.00 /1030.00		
Patient Type	:- Normal				
Address	:- DHAURAHARA KADIPUR CHAUBEYPUR - 221104,varanasi				

BP :- 100/70
 height :- 171
 Weight (kg) :- 73
 BMI :- 24.96

Rx

CH - 100
 WC - 90
 NC - 38
 PR - 90
 SPO2 - 98
 PEF - 300

Q.
 Pow ROS < 5g / day
 Q. Function of fiber to fitness on

1/1 month
 DR. Pallavi Misra
 MBBS, MD (GENERAL MEDICINE)
 MCI Reg. No. 52033

Printed By : Mr Siddhant Dwivedi
 Created By : Mr Siddhant Dwivedi



PANACEA HOSPITAL

B 36/44 F.K KABIR NAGAR, DURGAKUND
TOLLFREE NO-18001233070. Whatsapp No - 8795832852
www.piire.org
panaceaquery@gmail.com|panaceahospitalit@gmail.com



OP Slip

Print Date : 22-Feb-2024 10:47AM



UHID No :- UD-23240006341	OP No :- OP-23240019420	OP Date :- 22 Feb 2024 10:46AM
Patient Name :- Mr ATUL RAGHUVANSHI	Age/Sex :- 36 Y/Male	Mobile No :- 8726300729
Father :- VIJENDRA PRATAP SINGH	Department :- OPHTHALMOLOGY	
Pay Type :- Cr	Consultant :- Dr SANTOSH VERMA (MBBS,MS)	
Token No :- NOR. - 4	Paid :- 0.00	
Patient Type :- Normal		
Address :- DHAURAHARA KADIPUR CHAUBEYPUR - 221104, varanasi		

BP :- 100/70
height :- 171
Weight (kg) :- 73
BMI :- 24.96

CH - 100
WC - 90
NL - 38
PR - 90
SPD₂ - 98
PEFR - 300

Rx

VA { 6/6 - 7/7
6/6 - 7/7

Near { N6
N6.

Locally BIE

1-6. Lubstone ultra-QID
OTUO

Printed By : Mr Siddhant Dwivedi
Created By : Mr Siddhant Dwivedi

Dr. SANTOSH VERMA
MBBS, MS (Ophthalmologist)
MCI Reg. No. 09-34327



PANACEA HOSPITAL

B 36/44 F.K KABIR NAGAR, DURGAKUND
TOLLFREE NO-18001233070. Whatsapp No - 8795832852
www.piiire.org
panaceaquery@gmail.com|panaceahospitalit@gmail.com



OP Slip

Print Date : 22-Feb-2024 10:46AM



UHID No	:- UD-23240006341	OP No	:- OP-23240019418	OP Date	:- 22 Feb 2024 10:45AM
Patient Name	:- Mr ATUL RAGHUVANSHI	Age/Sex	:- 36 Y/Male	Mobile No	:- 8726300729
Father	:- VIJENDRA PRATAP SINGH	Department	:- DENTAL		
Pay Type	:- Cr	Consultant	:- Dr SHRUTI MISHRA (AA)		
Token No	:- NOR. - 2	Paid	:- 0.00		
Patient Type	:- Normal				
Address	:- DHAURAHARA KADIPUR CHAUBEYPUR - 221104, varanasi				

BP :- 100/70
height :- 171
Weight (kg) :- 73
BMI :- 24.96

CH - 100
WC - 90
NI - 38
PR - 90
SPO2 - 98
PEFR - 300

Rx

C/C => patient complain of pain in upper left back tooth.

O/E => grossly decayed \bar{c} 26

Missing tooth \bar{c} 25

Stain/calculus - +++/+++

PD/TA => F
Scaling & Polishing
FPD \bar{c} 34, 35, 36
RUG \bar{c} 26

Printed By : Mr Siddhant Dwivedi
Created By : Mr Siddhant Dwivedi

Shruti
Dr. SHRUTI MISHRA
BDS, (DENTIST)
MCI Reg. No. (A-09784)



PANACEA HOSPITAL

B 36/44 F.K KABIR NAGAR, DURGAKUND
TOLLFREE NO-18001233070. Whatsapp No - 8795832852
www.piire.org
panaceaquery@gmail.com|panaceahospitalit@gmail.com



OP Slip

Print Date : 22-Feb-2024 10:46AM



UHID No :- UD-23240006341	OP No :- OP-23240019419	OP Date :- 22 Feb 2024 10:46AM
Patient Name :- Mr ATUL RAGHUVANSHI	Age/Sex :- 36 Y/Male	Mobile No :- 8726300729
Father :- VIJENDRA PRATAP SINGH	Department :- DERMATOLOGY	
Pay Type :- Cr	Consultant :- Dr RAVI BHUSHAN (MBBS,MD)	
Token No :- NOR. - 2	Paid/Bal :- 0.00 /1000.00	
Patient Type :- Normal		
Address :- DHAURAHARA KADIPUR CHAUBEYPUR - 221104, varanasi		

BP :- 100/70
height :- 171
Weight (kg) :- 73
BMI :- 24.96

CH - 106
WC - 50
HC - 38
PR - 50
SPO₂ - 98
PEFR - 300

PRP therapy

Rx

SIBL Register

AGA

+ eczema

R
1 Tab Redemix Plus
1 tab (ATC)

1 Mometasone SR salt
1 ml LABD 17

1 Ketogen 1% 2 Shampoo x2 month
twice daily

1 Tab Levocet 20mg OD
(ATC)

1 Mometasone cream
(ATC)

1 Hydrex lotion
(ATC)

1 Harveer soap

Printed By : Mr Siddhant Dwivedi
Created By : Mr Siddhant Dwivedi



Facilities:

All clinical Biomedical & Hematology Investigations including Bone Marrow Examination
 VPT, Podiascan & Complete Foot Care (First Time in Purvanchal)
 All Hormonal Investigation by Chemiluminescent Method
 Visceral Fat by (AB-140) Ambulatory BP Monitoring
 CGMS & Insulin Pump Available
 PFT, 2D-ECHO (Color Doppler), Holter, TMT, Cardiac-3 available
 VIA, VILI, Colposcopy available
 Special Endocrinological Investigation Protocols.

ISO 9001:2008 Certified
 Mobile: 9389994334, 9554572190, 9453837595



Panacea Pathology

Clinical Reference Lab

Persistence, Preparedness and Precision
 EQAS (CMC Vellore Attached) & IQAS System
 पूर्वांचल की सर्वोत्तम गुणवत्ता वाली पैथोलॉजी

UHID No :- UD-23240006341
Patient Name :- Mr ATUL RAGHUVANSHI
Father :- VIJENDRA PRATAP SINGH
Address :- DHAURAHARA KADIPUR CHAUBEYPUR 221104 , varanasi
Consultant :- Dr Pallavi Mishra (MBBS,MD)

Booking No/Date :- 31 / 22-Feb-2024 12:08 PM
Age/Sex :- 36 Y/M
OP No :- OP-23240019420
Mobile No :- 8726300729

Investigations	Observations	Biological Ref. Interval	Unit
----------------	--------------	--------------------------	------

HAEMATOLOGY

Investigations	Observations	Biological Ref. Interval	Unit
CBC			
HAEMOGLOBIN <i>DefaultMethod / test Machine</i>	13.7	13.00 - 16.00	gm/dl
TLC <i>Methology / Carm</i>	4,300	4000.00 - 11000.00	Cells/cumm.
DLC DIFFERENTIAL LEUCOCYTE COUNT			
NEUTROPHILS	60	40.00 - 75.00	%
LYMPHOCYTES	33	20.00 - 45.00	%
EOSINOPHILS	04	1.00 - 6.00	%
MONOCYTES	03	2.00 - 10.00	%
BASOPHILS	00	<1-2	%
PLATELET COUNT	1.13	1.50 - 4.10	lacs /cumm
PCV	44.0	33.00 - 42.00	%
RBC <i>Methology / Carm</i>	4.57	4.50 - 5.50	million/cumm
MCV(MEAN CELL VOLUME)	96.3	83.00 - 101.00	fl
MCH(MEAN CELL HAEMOGLOBIN)	30.0	27.00 - 32.00	pg
MCHC	31.2	31.50 - 35.00	gm%
RDW-CV	14.1	11.00 - 16.00	%
RDW-SD	55.4	37.00 - 57.00	fl

Consulting Pathologist
DR. UMESH KUMAR
 MBBS, MD (PATHOLOGIST)
 MCI Reg. No. 41473

Lab Technician

Timing : 24/7 hrs

This Report is not valid for medico legal purpose

Note: These tests have technical limitations. Clinico-pathological interpretation is necessary. In case of any disparity test may be repeated immediately.

Facilities:

All clinical Biomedical & Hematology Investigations including Bone Marrow Examination
 VPT, Podiascan & Complete Foot Care (First Time in Purvanchal)
 All Hormonal Investigation by Chemiluminescent Method
 Visceral Fat by (AB-140) Ambulatory BP Monitoring
 CGMS & Insulin Pump Available
 PFT, 2D-ECHO (Color Doppler), Holter, TMT, Cardiac-3 available
 VIA, VILI, Colposcopy available
 Special Endocrinological Investigation Protocols.

ISO 9001:2008 Certified
 Mobile: 9389994334, 9554572190, 9453837595



Panacea Pathology

Clinical Reference Lab

Persistence, Preparedness and Precision
 EQAS (CMC Vellore Attached) & IQAS System
 पूर्वांचल की सर्वोत्तम गुणवत्ता वाली पैथोलॉजी

UHID No :- UD-23240006341 **Booking No/Date** :- 31 / 22-Feb-2024 12:08 PM
Patient Name :- Mr ATUL RAGHUVANSHI **Age/Sex** :- 36 Y/M
Father :- VIJENDRA PRATAP SINGH **OP No** :- OP-23240019420
Address :- DHAURAHARA KADIPUR CHAUBEYPUR **Mobile No** :- 8726300729
 221104 , varanasi
Consultant :- Dr Pallavi Mishra (MBBS,MD)

Investigations Observations Biological Ref Interval Unit

URINE EXAMINATION

URINE ROUTINE EXAMINATION

PHYSICAL EXAMINATION

QUANTITY 25 ml

COLOR STRAW CLEAR YELLOW
Methology

APPEARANCE CLEAR CLEAR
DefaultMethod

CHEMICAL EXAMINATION

SPECIFIC GRAVITY 1.015 1.01 - 1.03

PH 6.0 4.60 - 8.00

GLUCOSE NIL 60.00 - 100.00 mg/dl

PROTEIN- NIL

MICROSCOPIC EXAMINATION

PUS CELLS NIL 2.00 - 3.00 /HPF

RBCS (RED BLOOD CELLS) NIL 4.50 - 5.50 /HPF

EPITHELIAL CELLS 01-02 /HPF

CASTS ABSENT ABSENT

CRYSTALS ABSENT ABSENT

Consulting Pathologist

DR. UMESH KUMAR
 MBBS, MD (PATHOLOGIST)
 MCI Reg. No. 41473

Lab Technician

Timing : 24/7 hrs

This Report is not valid for medico legal purpose

Note: These tests have technical limitations. Clinico-pathological interpretation is necessary. In case of any disparity test may be repeated immediately.

Facilities:

All clinical Biomedical & Hematology Investigations including Bone Marrow Examination
 VPT, Podiascan & Complete Foot Care (First Time in Purvanchal)
 All Hormonal Investigation by Chemiluminescent Method
 Visceral Fat by (AB-140) Ambulatory BP Monitoring
 CGMS & Insulin Pump Available
 PFT, 2D-ECHO (Color Doppler), Holter, TMT, Cardiac-3 available
 VIA, VILI, Colposcopy available
 Special Endocrinological Investigation Protocols.

ISO 9001:2008 Certified
 Mobile: 9389994334, 9554572190, 9453837595



Panacea Pathology

Clinical Reference Lab

Persistence, Preparedness and Precision
 EQAS (CMC Vellore Attached) & IQAS System
 पूर्वांचल की सर्वोत्तम गुणवत्ता वाली पैथोलॉजी

UHID No :- UD-23240006341 **Booking No/Date** :- 31 / 22-Feb-2024 12:08 PM
Patient Name :- Mr ATUL RAGHUVANSHI **Age/Sex** :- 36 Y/M
Father :- VIJENDRA PRATAP SINGH **OP No** :- OP-23240019420
Address :- DHAURAHARA KADIPUR CHAUBEYPUR **Mobile No** :- 8726300729
 221104, varanasi
Consultant :- Dr Pallavi Mishra (MBBS,MD)

Investigations	Observations	Biological Ref. Interval	Unit
HAEMATOLOGY			
ESR	18.0	0.00 - 15.00	mm at 1 hr
BLOOD GROUP ABO & RH FACTOR			
BLOOD GROUP	"A"		
RH FACTOR	POSITIVE		
HBA1C -(BY GOLD STANDARD METHOD :HPLC)	5.3	Normal: 4.0 - 5.4 Prediabetic : 5.5 -6.3 Diabetes mellitus := 6.4	%
BIOCHEMISTRY			
BLOOD SUGAR FASTING			
GLUCOSE	98.0	60.00 - 100.00	mg/dl
PRE-DIABETICS(IMPAIRED FASTING TOLER)	-	100.00 - 125.00	mg/dl
DIABETICS	-	upto 126	mg/dl
TARGET IN DM	-	80.00 - 130.00	mg/dl
BIOCHEMISTRY			
PPBS(POST PRANDIAL BLOOD SUGAR)			
POST PRANDIAL BLOOD GLUCOSE(2 HR AFTER MEAL)	102.0	110.00 - 150.00	mg/dl
IGT(2 HR 75GM GLUCOSE)	-	140.00 - 199.00	mg/dl
DIABETES	-	upto200	mg/dl

Umesh Kumar

Consulting Pathologist
DR. UMESH KUMAR
 MBBS,MD (PATHOLOGIST)
 MDV Reg. No. 41413

Lab Technician

Timing : 24/7 hrs

This Report is not valid for medico legal purpose

Note: These tests have technical limitations. Clinico-pathological interpretation is necessary. In case of any disparity test may be repeated immediately.

Facilities:

All clinical Biomedical & Hematology Investigations including Bone Marrow Examination
 VPT, Podiascan & Complete Foot Care (First Time in Purvanchal)
 All Hormonal Investigation by Chemiluminescent Method
 Visceral Fat by (AB-140) Ambulatory BP Monitoring
 CGMS & Insulin Pump Available
 PFT, 2D-ECHO (Color Doppler), Holter, TMT, Cardiac-3 available
 VIA, VILI, Colposcopy available
 Special Endocrinological Investigation Protocols.

ISO 9001:2008 Certified

Mobile: 9389994334, 9554572190, 9453837595

**Panacea Pathology****Clinical Reference Lab**

Persistence, Preparedness and Precision
 EQAS (CMC Vellore Attached) & IQAS System
 पूर्वांचल की सर्वोत्तम गुणवत्ता वाली पैथोलॉजी

UHID No :- UD-23240006341 **Booking No/Date** :- 31 / 22-Feb-2024 12:08 PM
Patient Name :- Mr ATUL RAGHUVANSHI **Age/Sex** :- 36 Y/M
Father :- VIJENDRA PRATAP SINGH **OP No** :- OP-23240019420
Address :- DHAURAHARA KADIPUR CHAUBEYPUR **Mobile No** :- 8726300729
 221104, varanasi
Consultant :- Dr Pallavi Mishra (MBBS,MD)

Investigations	Observations	Biological Ref. Interval	Unit
TARGET IN DM	-	80.00 - 130.00	mg/dl
BIOCHEMISTRY			
LIPID PROFILE			
TOTAL CHOLESTROL	129.0	Desirable : - < 200 mg/dL Borderline: - 200 - 239 mg/dL High : - > 240mg/dL	mg/dl
TRIGLYCERIDES	133.0	35.00 - 160.00	mg/dl
HDL CHOLESTROL	37.0	35.30 - 79.50	mg/dl
LDL CHOLESTROL	65.4	< 130	mg/dl
VLDL	26.60	< 40	mg/dl
CHOLESTROL/ HDL RATIO	3.49	< 3.0 LOW RISK, 3.0-5.0 AVG RISK, > 5.0 HIGH RISK	ratio
LDL/HDL RATIO	1.77	< 3	ratio
LFT (LIVER FUNCTION TESTS)			
TOTAL BILIRUBIN	0.47	0.00 - 1.20	mg/dl
DIRECT BILIRUBIN	0.12	0.00 - 0.30	
INDIRECT BILIRUBIN	0.35	0.20 - 0.70	mg/dl
SGOT	23.0	2.00 - 31.00	U/L
SGPT	26.0	10.00 - 45.00	U/L

Lab Technician

Consulting Pathologist

DR. UMESH KUMAR
 MBBS, MD (PATHOLOGIST)
 MCI Reg. No. 41413

Timing : 24/7 hrs

This Report is not valid for medico legal purpose

Note: These tests have technical limitations. Clinico-pathological interpretation is necessary. In case of any disparity test may be repeated immediately.

Facilities:

All clinical Biomedical & Hematology Investigations including Bone Marrow Examination
 VPT, Podiascan & Complete Foot Care (First Time in Purvanchal)
 All Hormonal Investigation by Chemiluminescent Method
 Visceral Fat by (AB-140) Ambulatory BP Monitoring
 CGMS & Insulin Pump Available
 PFT, 2D-ECHO (Color Doppler), Holter, TMT, Cardiac-3 available
 VIA, VILI, Colposcopy available
 Special Endocrinological Investigation Protocols.

ISO 9001:2008 Certified
 Mobile: 9389994334, 9554572190, 9453837595



Panacea Pathology

Clinical Reference Lab

Persistence, Preparedness and Precision.
 EQAS (CMC Vellore Attached) & IQAS System
 पूर्वांचल की सर्वोत्तम गुणवत्ता वाली पैथोलॉजी

UHID No :- UD-23240006341 **Booking No/Date** :- 31 / 22-Feb-2024 12:08 PM
Patient Name :- Mr ATUL RAGHUVANSHI **Age/Sex** :- 36 Y/M
Father :- VIJENDRA PRATAP SINGH **OP No** :- OP-23240019420
Address :- DHAURAHARA KADIPUR CHAUBEYPUR **Mobile No** :- 8726300729
 221104 , varanasi
Consultant :- Dr Pallavi Mishra (MBBS,MD)

Investigations	Observations	Biological Ref. Interval	Unit
ALKALINE PHOSPHATASE	97.0	25.00 - 140.00	U/L
TOTAL PROTIENS	6.9	6.60 - 8.70	g/dl
ALBUMIN	3.8	3.50 - 5.20	gm%
GLOBULIN	3.1	1.50 - 3.60	gms/dl
A/G RATIO	1.22	2:1	RATIO
S.CREATININE	1.33	0.60 - 1.40	mg/dl
BLOOD UREA NITROGEN	12.0	6.00 - 21.00	mg/dl
URIC ACID			
URIC ACID	4.98	3.60 - 7.70	mg/dl
YGGT	18.0	10.00 - 50.00	U/L
<u>IMMUNOLOGY</u>			
THYROID PROFILE (T3,T4,TSH)			
T3	0.98	0.60 - 1.81	ng/ml
T4	6.8	4.50 - 10.90	ug/dl
TSH	1.15	0.39 - 6.10	uIU/mL

PARASITOLOGY

STOOL ROUTINE

Lab Technician

Consulting Pathologist
DR. UMESH KUMAR
 MBBS, MD (PATHOLOGIST)
 MDI Reg. No. 41413

Timing : 24/7 hrs

This Report is not valid for medico legal purpose

Note: These tests have technical limitations. Clinico-pathological interpretation is necessary. In case of any disparity test may be repeated immediately.

Facilities:

All clinical Biomedical & Hematology Investigations including Bone Marrow Examination
 VPT, Podiascan & Complete Foot Care (First Time in Purvanchal)
 All Hormonal Investigation by Chemiluminescent Method
 Visceral Fat by (AB-140) Ambulatory BP Monitoring
 CGMS & Insulin Pump Available
 PFT, 2D-ECHO (Color Doppler), Holter, TMT, Cardiac-3 available
 VIA, VILI, Colposcopy available
 Special Endocrinological Investigation Protocols.

ISO 9001:2008 Certified
 Mobile: 9389994334, 9554572190, 9453837595



Panacea Pathology

Clinical Reference Lab

Persistence, Preparedness and Precision
 EQAS (CMC Vellore Attached) & IQAS System
 पूर्वांचल की सर्वोत्तम गुणवत्ता वाली पैथोलॉजी

UHID No :- UD-23240006341
Patient Name :- Mr ATUL RAGHUVANSHI
Father :- VIJENDRA PRATAP SINGH
Address :- DHAURAHARA KADIPUR CHAUBEYPUR
 221104 , varanasi
Consultant :- Dr Pallavi Mishra (MBBS,MD)

Booking No/Date :- 31 / 22-Feb-2024 12:08 PM
Age/Sex :- 36 Y/M
OP No :- OP-23240019420
Mobile No :- 8726300729

Investigations	Observations	Biological Ref. Interval	Unit
GROSS EXAMINATON			
COLOR <i>Methology</i>	YELLOW	CLEAR YELLOW	
CONSISTANCY	NORMAL		
BLOOD	ABSENT		
MUCUS	ABSENT		
MICROSCOPIC EXAMINATON			
OVA OR EGGS OF HELMINTHS	ABSENT		
CYST OF PROTOZOA	ABSENT		
VEG. FORMS OF PROTOZOA	ABSENT		
PUS CELLS	04-05	2.00 - 3.00	/HPF
RBC <i>Methology / Carm</i>	NIL	4.50 - 5.50	million/cumm

* END OF REPORT *

Consulting Pathologist
DR. UMESH KUMAR
 MBBS,MD (PATHOLOGIST)
 MCh Reg. No. 41415

Lab Technician

Timing : 24/7 hrs

This Report is not valid for medico legal purpose

Note: These tests have technical limitations. Clinico-pathological interpretation is necessary. In case of any disparity test may be repeated immediately.



PANACEA HOSPITAL



A shelter for many hearts A Home for many lives
(An ISO 9001:2008 Certified Organisation)
Lab Attached with CMC Under EQAS Scheme

Dept. of Radiodiagnosis - 32 Slice CT Scan, 3D/4D USG, 2D ECHO, Colour Doppler, Intervention Procedures, Digital X-Ray

PATIENT'S NAME : ATUL RAGHUVANSHI **AGE/SEX: 36 Y/M**
REF. BY : Dr. ASHUTOSH MISHRA (MD) **Thursday, February 22, 2024**

Echo - Cardiography

MITRAL VALVE Doppler	AML - normal morphology MV Flow - E - 0.5 A-0.4 E/A=1.20	PML - normal morphology MVA - 3.0 cm ² Mitral Regurgitation - No
TRICUSPID VALVE Doppler	Normal TV Flow -No	Tricuspid Regurgitation -No
PULMONARY VALVE Doppler	Normal PV Flow -No	Pulmonary Regurgitation - No
AORTIC VALVE Doppler	Trileaflet-No AV Flow - no	Aortic Regurgitation - no
MEASUREMENT	Aorta - 30.3 (20-38) mm IVS ed - 9.1 (6-12) mm LVID ed -42.8 (35 - 55) mm LVPW ed - 12.6 (6-12) mm OA - 7 (> 5) mm	LA - 28.0 (24-32) mm IVS es -13.7 (6-12) mm LVID es - 30.3 (24 - 40) mm LVPW es -16.6 (6-12) mm EPSS - 4 (< 9) mm

CONCLUSION All cardiac chamber dimensions are WNL
No valvular abnormalities
Good LV systolic function present Modified Simpson's method (4C, 2C) (LVEF=57%)
No diastolic dysfunction present (E/A = 1.20)
No RWMA
No pericardial effusion
Intact IAS / IV
No PAH
No intra cardiac mass /thrombus /vegetation

IMPRESSION **Normal Echocardiogram**

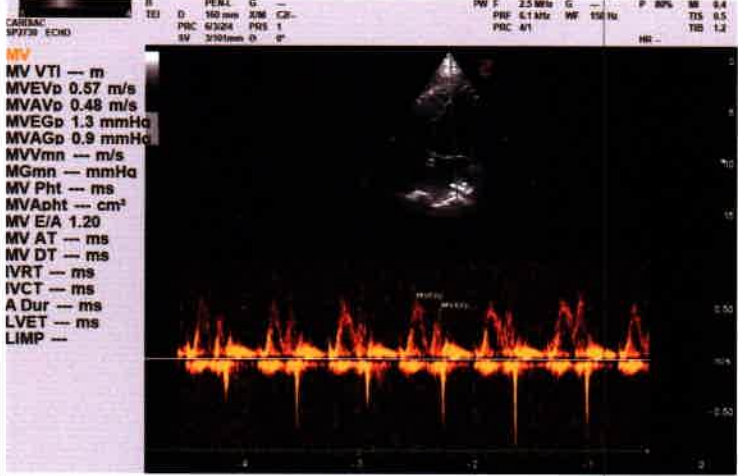
Niraj Mishra
Physician Assistant
(PURE)

Dr. Pallavi Mishra
DR. Pallavi Mishra
MBBS, MD(GENERAL MEDICINE)
MCI Reg. No: 2033
Diabeto cardiologist

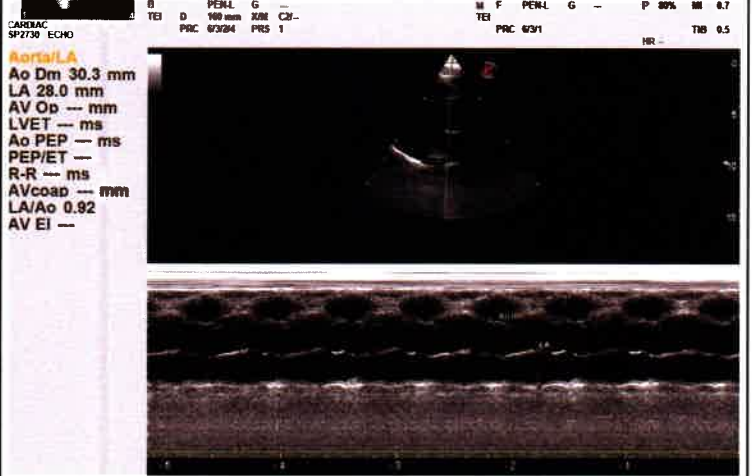
Disclaimer: This report is not valid for Madicolegal or Judicial Purpose. Radiological diagnosis is solely interpretation of images produced by tissue & may not be always conclusive.

Address : B36/44 B4 Kabir Nagar (Near Sanjay Shiksha Niketan), Durgakund, Varanasi
Mobile : 9554572190 / 9453837595 / Recpn, 9389994334
Email : dramishra@gmail.com, drpallaviojha@gmail.com, Website : www.piire.org

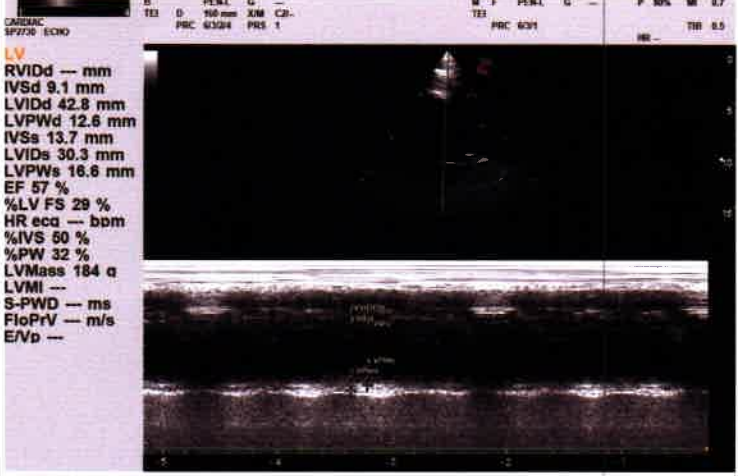
ATUL RAGHUVANSHI 36Y/M 22 02 2024 03:21:16 PM



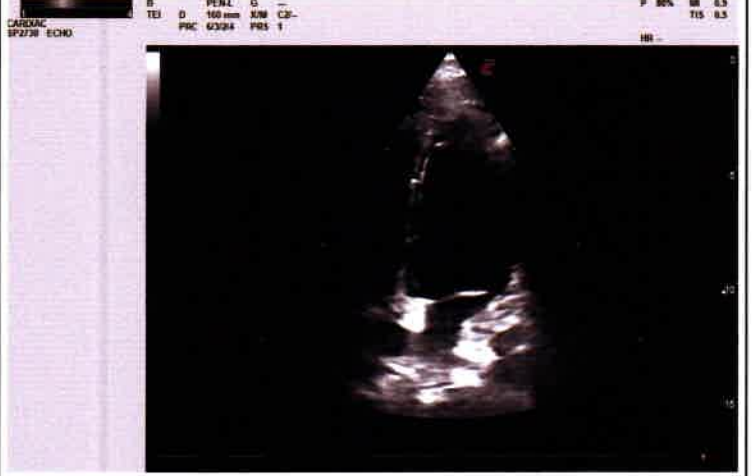ATUL RAGHUVANSHI 36Y/M 22 02 2024 03:21:16 PM



ATUL RAGHUVANSHI 36Y/M 22 02 2024 03:21:16 PM



ATUL RAGHUVANSHI 36Y/M 22 02 2024 03:21:16 PM





Call Now - 1800-123-3070

PANACEA HOSPITAL



A shelter for many hearts A Home for many lives

(An ISO 9001:2008 Certified Organisation)

Lab Attached with CMC Under EQAS Scheme

Dept. of Radiodiagnosis - 32 Slice CT Scan, 3D/4D USG, 2D ECHO, Colour Doppler, Intervention Procedures, Digital X-Ray

PATIENT'S NAME :	ATUL RAGHUVANSHI	AGE/SEX: 36Y/M
REF. BY :	Dr. ASHUTOSH MISHRA(MD)	DATE: 22/02/2024

X-RAY CHEST (PA VIEW)

- Bilateral lung fields appear normal.
- Trachea and mediastinum appear normal in position.
- Both hila appear normal in size and are symmetrical.
- Transverse cardiac diameter is within normal limits.
- Great vessels appear normal
- Both CP angles appear clear. Normal position and contour diaphragms noted.
- Bony rib cage and soft tissue shadows appear normal.

IMPRESSION

- **No obvious abnormality noted in the chest radiograph.**

Dr. Rahul Kumar Tiwari
MBBS (Radio Diagonosis)
Reg. No. 57557

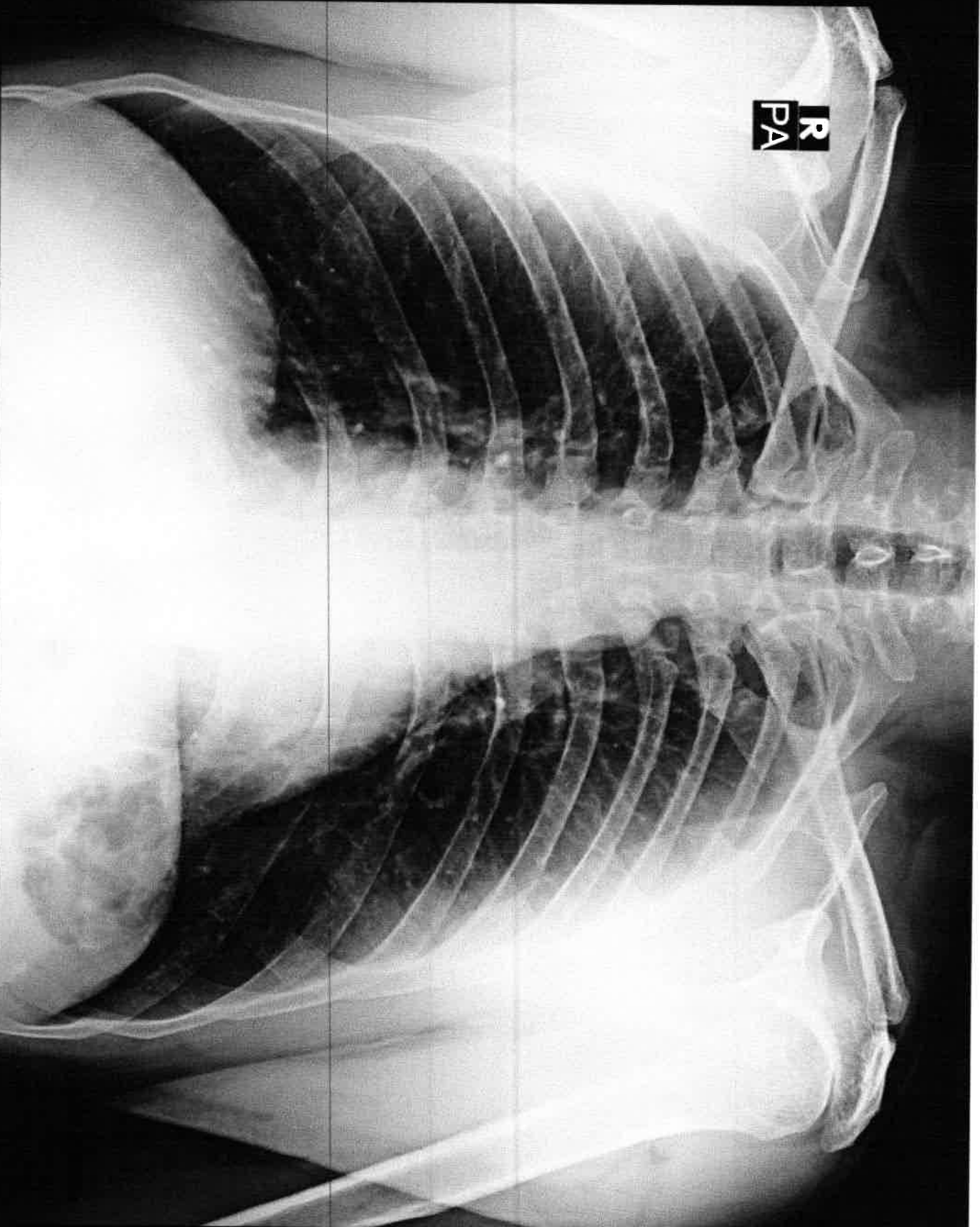
Thanks for reference.

Disclaimer: This report is not valid for Madicolegal or Judicial Purpose. Radiological diagnosis is solely interpretation of images produced by tissue & may not be always conclusive.

Address : B36/44 B4 Kabir Nagar (Near Sanjay Shiksha Niketan), Durgakund, Varanasi

Mobile : 9554572190 / 9453837595 / Recpn, 9389994334

Email : dramishra@gmail.com, drpallaviojha@gmail.com, Website : www.piire.org



ATUL RAGHUVANSHI 36Y/M 6341 M CHEST P.A. 22-Feb-24 11:13 AM

PANACEA HOSPITAL, KABIR NAGAR, DURGAKUND, VARANASI



Call Now - 1800-123-3070

PANACEA HOSPITAL



A shelter for many hearts A Home for many lives
(An ISO 9001:2008 Certified Organisation)
Lab Attached with CMC Under EQAS Scheme

Dept. of Radiodiagnosis - 32 Slice CT Scan, 3D/4D USG, 2D ECHO, Colour Doppler, Intervention Procedures, Digital X-Ray

NAME: ATUL RAGHUVANSI
REF.DR. DR.ASHUTOSH MISHRA(MD)

AGE/SEX: 36 YRS/MALE
DATE: 22/02/2024

ULTRA SOUND WHOLE ABDOMEN REPORT

Liver: Normal in size, shape & echogenicity. Intra & extra hepatic biliary Radicals & Vascular structures are normal. Margins are smooth and regular.

Gall bladder: Normally distended with echo free lumen.

Portal vein: Normal in course and caliber.

CBD diameter: Visualized part normal in course & caliber.

Pancreas: Normal in size, shape & echogenicity. Margins are smooth & regular. No diffuse/ focal lesion seen. Pancreatic duct not visualized.

Spleen: Normal in size, shape & echogenicity. Margins are smooth & regular.
No diffuse / focal lesion seen. Splenic vessels at hilum is normal.

Kidney: Both normal in size, shape echogenicity & position. Cortical-medullary differentiation is maintained. Pelvicalyceal system normal. No evidence of any calculus/mass lesion seen
No hydronephrosis/ hydroureter seen. No suprarenal mass lesion.

Urinary bladder: Normally distended with normal wall thickness. No echogenic foci lumen or diverticula seen.
Both VUJ appears normal. No evidence of calculus / mass lesion seen.

Prostate: Normal in size 2.6X3.5X3.2mm Vol 15.6ml, shape & echogenicity..

Others: No free fluid in peritoneal cavity.
No free fluid in bilateral pleural cavity.
No evidence of significantly enlarged retroperitoneal/ mesenteric lymph nodes noted.

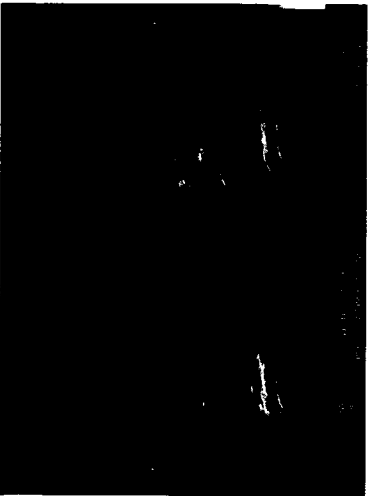
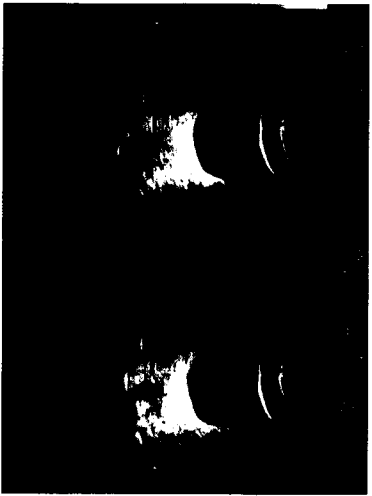
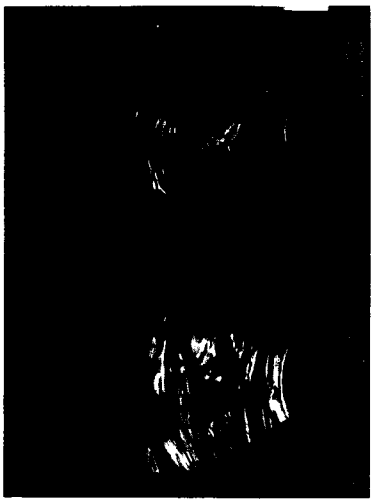
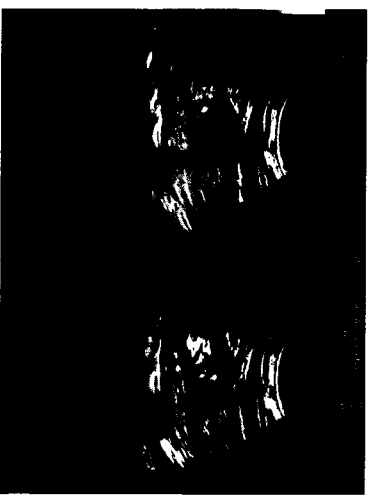



IMPRESSION: - NO OBVIOUS SONOLOGICAL ABNORMALITY SEEN.

Please correlate clinically and further investigations.

Dr. Rahul Kumar Tiwari
MBBS, MD (Radiology)
Reg. No. 57557

Disclaimer: This report is not valid for Madicolegal or Judicial Purpose. Radiological diagnosis is solely interpretation of images produced by tissue & may not be always conclusive.

Address : B36/44 B4 Kabir Nagar (Near Sanjay Shiksha Niketan), Durgakund, Varanasi
Mobile : 9554572190 / 9453837595 / Recpn, 9389994334
Email : dramishra@gmail.com, drpallaviojha@gmail.com, Website : www.piire.org



2024-02-22 11:17

<< Conclusions >>

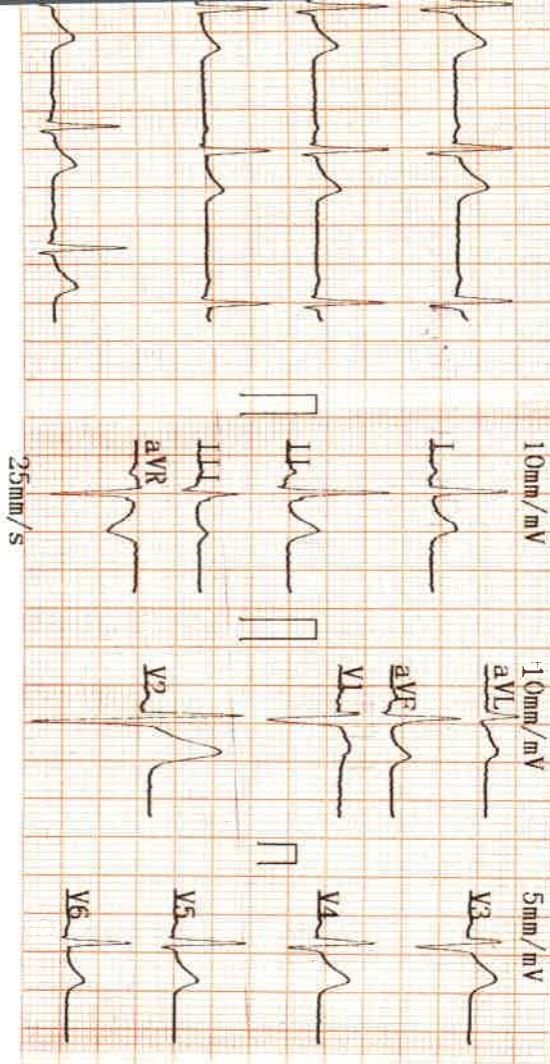
Normal Sinus Rhythm;
Cardiac electric axis normal.

Weight: 73 kg **Report need physician confirm**

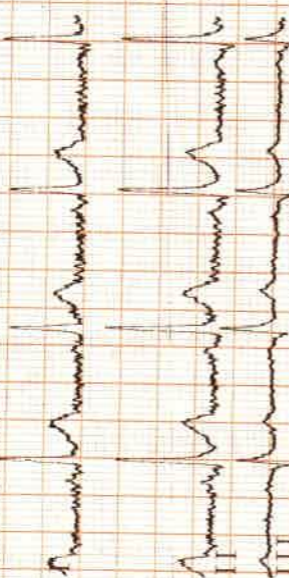
ID :
 Name : Atul Raghuvanshi
 Sex : m
 Height : 171
 SYS :
 DIA :
 HR : 86 bpm
 PR Interval : 139 ms
 P Duration : 95 ms
 QRS Duration : 79 ms
 T Duration : 168 ms
 QT/QTc : 305/365 ms
 P/QRS/T Axis : 73.5/48.1/45.0 deg
 R (V5) / S (V1) : 1.91/0.94 mV
 R (V5) + S (V1) : 2.85 mV

DR. PATEL MISRA
 MBBS, MD (GENERAL MEDICINE)
 MCI Reg. No. 52033

Physician

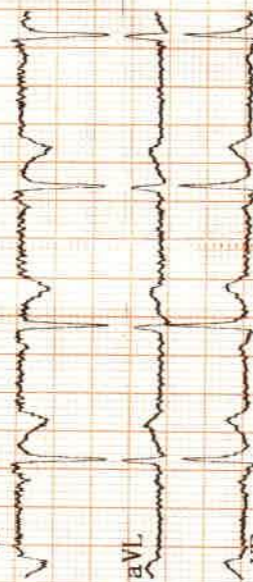

AUTO 10mm/mV



10mm/mV

aVR

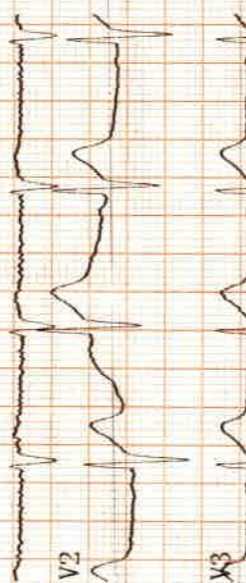

aVL

aVF

5mm/mV

V1

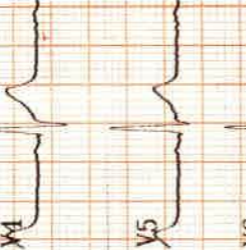

V2

V3

5mm/mV

V4



V5

V6

5mm/mV

V5



25mm/s AC50HZ

aceea Hospital

A Shelter For Many Hearts

Home For Many Lives

ates Care Organization




करण
RATION

आई.पी.डी. पंजिकरण
I.P.D. REGISTRATION

विलिंग काउंटर
CASH COUNTER

COMPLAINT /
SUGGESTION

 GPS Map Camera

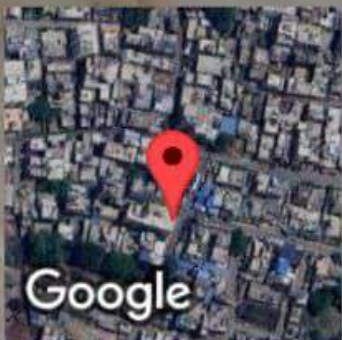
Varanasi, Uttar Pradesh, India

44-B3, Durgakund, Bhelupur, Varanasi, Uttar Pradesh 221001, India

Lat 25.289234°

Long 82.99338°

22/02/24 10:26 AM GMT +05:30



Google