

Patient Name : Mrs.NAGMA MANSOORI
Age/Gender : 31 Y 3 M 28 D/F
UHID/MR No : RIND.0000017848
Visit ID : RINDOPV19490
Ref Doctor : Dr.SELF
Emp/Auth/TPA ID : 22S37524

Collected : 05/Nov/2024 10:28AM
Received : 05/Nov/2024 10:46AM
Reported : 05/Nov/2024 12:06PM
Status : Final Report
Sponsor Name : ARCOFEMI HEALTHCARE LIMITED

DEPARTMENT OF HAEMATOLOGY

PERIPHERAL SMEAR , WHOLE BLOOD EDTA

RBCs ARE NORMOCYTIC NORMOCHROMIC.
TLC , DLC WITHIN NORMAL LIMIT. NO IMMATURE CELLS ARE SEEN.
PLATELETS ARE ADEQUATE.
NO HEMOPARASITES SEEN



Dr.Kritika Jain
M.B.B.S,M.D(Pathology)
Consultant Pathologist

SIN No:BED240244344

This test has been performed at Apollo Health and Lifestyle Ltd/Lab

Apollo Health and Lifestyle Limited

(CIN - U05110TG2000PLC115819)

Corporate Office: 7-1-617/A, 7th Floor, Imperial Towers, Ameerpet, Hyderabad-500016, Telangana

Ph No: 040-4904 7777 | www.apollohl.com | Email ID:enquiry@apollohl.com



Patient Name : Mrs.NAGMA MANSOORI	Collected : 05/Nov/2024 10:28AM
Age/Gender : 31 Y 3 M 28 D/F	Received : 05/Nov/2024 10:46AM
UHID/MR No : RIND.0000017848	Reported : 05/Nov/2024 12:06PM
Visit ID : RINDOPV19490	Status : Final Report
Ref Doctor : Dr.SELF	Sponsor Name : ARCOFEMI HEALTHCARE LIMITED
Emp/Auth/TPA ID : 22S37524	

DEPARTMENT OF HAEMATOLOGY

ARCOFEMI - MEDIWHEEL - FULL BODY HEALTH ANNUAL PLUS CHECK - FEMALE - 2D ECHO - PAN INDIA - FY2324

Test Name	Result	Unit	Bio. Ref. Interval	Method
HEMOGRAM , WHOLE BLOOD EDTA				
HAEMOGLOBIN	13.9	g/dL	12-15	Spectrophotometer
PCV	43.00	%	36-46	Electronic pulse & Calculation
RBC COUNT	5.06	Million/cu.mm	3.8-4.8	Electrical Impedence
MCV	85	fL	83-101	Calculated
MCH	27.5	pg	27-32	Calculated
MCHC	32.4	g/dL	31.5-34.5	Calculated
R.D.W	14.5	%	11.6-14	Calculated
TOTAL LEUCOCYTE COUNT (TLC)	9,500	cells/cu.mm	4000-10000	Electrical Impedence
DIFFERENTIAL LEUCOCYTIC COUNT (DLC)				
NEUTROPHILS	70	%	40-80	Electrical Impedence
LYMPHOCYTES	25	%	20-40	Electrical Impedence
EOSINOPHILS	01	%	1-6	Electrical Impedence
MONOCYTES	04	%	2-10	Electrical Impedence
BASOPHILS	00	%	<1-2	Electrical Impedence
ABSOLUTE LEUCOCYTE COUNT				
NEUTROPHILS	6650	Cells/cu.mm	2000-7000	Calculated
LYMPHOCYTES	2375	Cells/cu.mm	1000-3000	Calculated
EOSINOPHILS	95	Cells/cu.mm	20-500	Calculated
MONOCYTES	380	Cells/cu.mm	200-1000	Calculated
Neutrophil lymphocyte ratio (NLR)	2.8		0.78- 3.53	Calculated
PLATELET COUNT	218000	cells/cu.mm	150000-410000	Electrical impedence
ERYTHROCYTE SEDIMENTATION RATE (ESR)	8	mm at the end of 1 hour	0-20	Modified Westergren
PERIPHERAL SMEAR				

RBCs ARE NORMOCYTIC NORMOCHROMIC.
TLC , DLC WITHIN NORMAL LIMIT. NO IMMATURE CELLS ARE SEEN.
PLATELETS ARE ADEQUATE.
NO HEMOPARASITES SEEN



Dr. Kritika Jain
M.B.B.S,M.D(Pathology)
Consultant Pathologist



Patient Name : Mrs.NAGMA MANSOORI	Collected : 05/Nov/2024 10:28AM
Age/Gender : 31 Y 3 M 28 D/F	Received : 05/Nov/2024 10:46AM
UHID/MR No : RIND.0000017848	Reported : 05/Nov/2024 04:59PM
Visit ID : RINDOPV19490	Status : Final Report
Ref Doctor : Dr.SELF	Sponsor Name : ARCOFEMI HEALTHCARE LIMITED
Emp/Auth/TPA ID : 22S37524	

DEPARTMENT OF HAEMATOLOGY

ARCOFEMI - MEDIWHEEL - FULL BODY HEALTH ANNUAL PLUS CHECK - FEMALE - 2D ECHO - PAN INDIA - FY2324

Test Name	Result	Unit	Bio. Ref. Interval	Method
BLOOD GROUP ABO AND RH FACTOR , WHOLE BLOOD EDTA				
BLOOD GROUP TYPE	O			Forward & Reverse Grouping with Slide/Tube Aggluti
Rh TYPE	POSITIVE			Forward & Reverse Grouping with Slide/Tube Agglutination




Dr. Kritika Jain
M.B.B.S, M.D (Pathology)
Consultant Pathologist

SIN No: BED240244344

This test has been performed at Apollo Health and Lifestyle Ltd/Lab

Apollo Health and Lifestyle Limited

(CIN - U85110TG2000PLC115819)

Corporate Office: 7-1-617/A, 7th Floor, Imperial Towers, Ameerpet, Hyderabad-500016, Telangana

Ph No: 040-4904 7777 | www.apollohl.com | Email ID: enquiry@apollohl.com



Patient Name : Mrs.NAGMA MANSOORI	Collected : 05/Nov/2024 12:52PM
Age/Gender : 31 Y 3 M 28 D/F	Received : 05/Nov/2024 01:13PM
UHID/MR No : RIND.0000017848	Reported : 05/Nov/2024 02:46PM
Visit ID : RINDOPV19490	Status : Final Report
Ref Doctor : Dr.SELF	Sponsor Name : ARCOFEMI HEALTHCARE LIMITED
Emp/Auth/TPA ID : 22S37524	

DEPARTMENT OF BIOCHEMISTRY

ARCOFEMI - MEDIWHEEL - FULL BODY HEALTH ANNUAL PLUS CHECK - FEMALE - 2D ECHO - PAN INDIA - FY2324

Test Name	Result	Unit	Bio. Ref. Interval	Method
GLUCOSE, FASTING , NAF PLASMA	98	mg/dL	70-100	GOD - POD

Comment:

As per American Diabetes Guidelines, 2023

Fasting Glucose Values in mg/dL	Interpretation
70-100 mg/dL	Normal
100-125 mg/dL	Prediabetes
≥126 mg/dL	Diabetes
<70 mg/dL	Hypoglycemia


Note:

- 1.The diagnosis of Diabetes requires a fasting plasma glucose of > or = 126 mg/dL and/or a random / 2 hr post glucose value of > or = 200 mg/dL on at least 2 occasions.
2. Very high glucose levels (>450 mg/dL in adults) may result in Diabetic Ketoacidosis & is considered critical.

Test Name	Result	Unit	Bio. Ref. Interval	Method
GLUCOSE, POST PRANDIAL (PP), 2 HOURS , SODIUM FLUORIDE PLASMA (2 HR)	145	mg/dl	70-140	GOD, POD

Comment:

It is recommended that FBS and PPBS should be interpreted with respect to their Biological reference ranges and not with each other.
Conditions which may lead to lower postprandial glucose levels as compared to fasting glucose levels may be due to reactive hypoglycemia, dietary meal content, duration or timing of sampling after food digestion and absorption, medications such as insulin preparations, sulfonylureas, amylin analogues, or conditions such as overproduction of insulin.



Dr.Kritika Jain
M.B.B.S,M.D(Pathology)
Consultant Pathologist



Patient Name : Mrs.NAGMA MANSOORI	Collected : 05/Nov/2024 10:28AM
Age/Gender : 31 Y 3 M 28 D/F	Received : 05/Nov/2024 04:11PM
UHID/MR No : RIND.0000017848	Reported : 05/Nov/2024 06:48PM
Visit ID : RINDOPV19490	Status : Final Report
Ref Doctor : Dr.SELF	Sponsor Name : ARCOFEMI HEALTHCARE LIMITED
Emp/Auth/TPA ID : 22S37524	

DEPARTMENT OF BIOCHEMISTRY

ARCOFEMI - MEDIWHEEL - FULL BODY HEALTH ANNUAL PLUS CHECK - FEMALE - 2D ECHO - PAN INDIA - FY2324

Test Name	Result	Unit	Bio. Ref. Interval	Method
HBA1C (GLYCATED HEMOGLOBIN) , WHOLE BLOOD EDTA				
HBA1C, GLYCATED HEMOGLOBIN	5.1	%		HPLC
ESTIMATED AVERAGE GLUCOSE (eAG)	100	mg/dL		Calculated

Comment:

Reference Range as per American Diabetes Association (ADA) 2023 Guidelines:

REFERENCE GROUP	HBA1C %
NON DIABETIC	<5.7
PREDIABETES	5.7 – 6.4
DIABETES	≥ 6.5
DIABETICS	
EXCELLENT CONTROL	6 – 7
FAIR TO GOOD CONTROL	7 – 8
UNSATISFACTORY CONTROL	8 – 10
POOR CONTROL	>10

Note: Dietary preparation or fasting is not required.

- HbA1C is recommended by American Diabetes Association for Diagnosing Diabetes and monitoring Glycemic Control by American Diabetes Association guidelines 2023.
- Trends in HbA1C values is a better indicator of Glycemic control than a single test.
- Low HbA1C in Non-Diabetic patients are associated with Anemia (Iron Deficiency/Hemolytic), Liver Disorders, Chronic Kidney Disease. Clinical Correlation is advised in interpretation of low Values.
- Falsely low HbA1c (below 4%) may be observed in patients with clinical conditions that shorten erythrocyte life span or decrease mean erythrocyte age. HbA1c may not accurately reflect glycemic control when clinical conditions that affect erythrocyte survival are present.
- In cases of Interference of Hemoglobin variants in HbA1C, alternative methods (Fructosamine) estimation is recommended for Glycemic Control
 - A: HbF >25%
 - B: Homozygous Hemoglobinopathy.
 (Hb Electrophoresis is recommended method for detection of Hemoglobinopathy)



Dr. Tanish Mandal
M.B.B.S, M.D (Pathology)
Consultant Pathologist
SIN No: EDT240093841



Patient Name : Mrs.NAGMA MANSOORI	Collected : 05/Nov/2024 10:28AM
Age/Gender : 31 Y 3 M 28 D/F	Received : 05/Nov/2024 10:44AM
UHID/MR No : RIND.0000017848	Reported : 05/Nov/2024 12:04PM
Visit ID : RINDOPV19490	Status : Final Report
Ref Doctor : Dr.SELF	Sponsor Name : ARCOFEMI HEALTHCARE LIMITED
Emp/Auth/TPA ID : 22S37524	

DEPARTMENT OF BIOCHEMISTRY


ARCOFEMI - MEDIWHEEL - FULL BODY HEALTH ANNUAL PLUS CHECK - FEMALE - 2D ECHO - PAN INDIA - FY2324

Test Name	Result	Unit	Bio. Ref. Interval	Method
LIPID PROFILE , SERUM				
TOTAL CHOLESTEROL	157	mg/dL	<200	CHE/CHO/POD
TRIGLYCERIDES	139	mg/dL	<150	Enzymatic
HDL CHOLESTEROL	36	mg/dL	40-60	CHOD
NON-HDL CHOLESTEROL	122	mg/dL	<130	Calculated
LDL CHOLESTEROL	93.76	mg/dL	<100	Calculated
VLDL CHOLESTEROL	27.88	mg/dL	<30	Calculated
CHOL / HDL RATIO	4.42		0-4.97	Calculated
ATHEROGENIC INDEX (AIP)	0.23		<0.11	Calculated

Comment:

Reference Interval as per National Cholesterol Education Program (NCEP) Adult Treatment Panel III Report.

	Desirable	Borderline High	High	Very High
TOTAL CHOLESTEROL	< 200	200 - 239	≥ 240	
TRIGLYCERIDES	<150	150 - 199	200 - 499	≥ 500
LDL	Optimal < 100 Near Optimal 100-129	130 - 159	160 - 189	≥ 190
HDL	≥ 60			
NON-HDL CHOLESTEROL	Optimal <130; Above Optimal 130-159	160-189	190-219	>220



Dr. Kritika Jain
M.B.B.S, M.D (Pathology)
Consultant Pathologist



SIN No: SE04841928

This test has been performed at Apollo Health and Lifestyle Ltd/Lab

Apollo Health and Lifestyle Limited

(CIN - U85110TG2000PLC115819)

Corporate Office: 7-1-617/A, 7th Floor, Imperial Towers, Ameerpet, Hyderabad-500016, Telangana

Ph No: 040-4904 7777 | www.apollohl.com | Email ID: enquiry@apollohl.com

Patient Name : Mrs.NAGMA MANSOORI	Collected : 05/Nov/2024 10:28AM
Age/Gender : 31 Y 3 M 28 D/F	Received : 05/Nov/2024 10:44AM
UHID/MR No : RIND.0000017848	Reported : 05/Nov/2024 12:04PM
Visit ID : RINDOPV19490	Status : Final Report
Ref Doctor : Dr.SELF	Sponsor Name : ARCOFEMI HEALTHCARE LIMITED
Emp/Auth/TPA ID : 22S37524	

DEPARTMENT OF BIOCHEMISTRY

ARCOFEMI - MEDIWHEEL - FULL BODY HEALTH ANNUAL PLUS CHECK - FEMALE - 2D ECHO - PAN INDIA - FY2324

Test Name	Result	Unit	Bio. Ref. Interval	Method
LIVER FUNCTION TEST (LFT) , SERUM				
BILIRUBIN, TOTAL	0.49	mg/dL	0.20-1.20	Colorimetric
BILIRUBIN CONJUGATED (DIRECT)	0.19	mg/dl	0-0.2	Diazotized sulfanilic acid
BILIRUBIN (INDIRECT)	0.30	mg/dL	0.0-1.1	Dual Wavelength
ALANINE AMINOTRANSFERASE (ALT/SGPT)	39.52	U/L	9-52	UV with P-5-P
ASPARTATE AMINOTRANSFERASE (AST/SGOT)	27.3	U/L	14-36	UV with P-5-P
AST (SGOT) / ALT (SGPT) RATIO (DE RITIS)	0.7		<1.15	Calculated
ALKALINE PHOSPHATASE	122.33	U/L	38-126	p-nitrophenyl phosphate
PROTEIN, TOTAL	6.94	g/dL	6.3-8.2	Biuret
ALBUMIN	4.68	g/dL	3.5 - 5	Bromocresol Green
GLOBULIN	2.26	g/dL	2.0-3.5	Calculated
A/G RATIO	2.07		0.9-2.0	Calculated

Comment:

LFT results reflect different aspects of the health of the liver, i.e., hepatocyte integrity (AST & ALT), synthesis and secretion of bile (Bilirubin, ALP), cholestasis (ALP, GGT), protein synthesis (Albumin) Common patterns seen:

1. Hepatocellular Injury:

*AST – Elevated levels can be seen. However, it is not specific to liver and can be raised in cardiac and skeletal injuries.*ALT – Elevated levels indicate hepatocellular damage. It is considered to be most specific lab test for hepatocellular injury. Values also correlate well with increasing BMI. Disproportionate increase in AST, ALT compared with ALP. AST: ALT (ratio) – In case of hepatocellular injury AST: ALT > 1In Alcoholic Liver Disease AST: ALT usually >2. This ratio is also seen to be increased in NAFLD, Wilson's diseases, Cirrhosis, but the increase is usually not >2.

2. Cholestatic Pattern:*ALP – Disproportionate increase in ALP compared with AST, ALT. ALP elevation also seen in pregnancy, impacted by age and sex.*Bilirubin elevated- predominantly direct , To establish the hepatic origin correlation with elevated GGT helps.

3. Synthetic function impairment:*Albumin- Liver disease reduces albumin levels, Correlation with PT (Prothrombin Time) helps.

4. Associated tests for assessment of liver fibrosis - Fibrosis-4 and APRI Index.



Dr. Kritika Jain
M.B.B.S,M.D(Pathology)
Consultant Pathologist



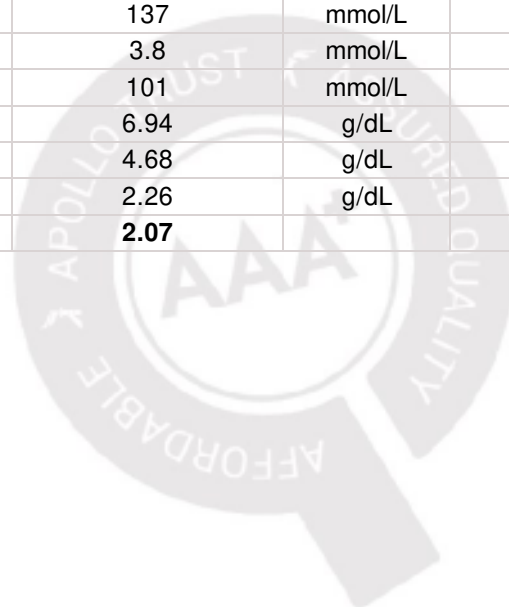
Patient Name : Mrs.NAGMA MANSOORI
Age/Gender : 31 Y 3 M 28 D/F
UHID/MR No : RIND.0000017848
Visit ID : RINDOPV19490
Ref Doctor : Dr.SELF
Emp/Auth/TPA ID : 22S37524

Collected : 05/Nov/2024 10:28AM
Received : 05/Nov/2024 10:44AM
Reported : 05/Nov/2024 12:04PM
Status : Final Report
Sponsor Name : ARCOFEMI HEALTHCARE LIMITED

DEPARTMENT OF BIOCHEMISTRY

ARCOFEMI - MEDIWHEEL - FULL BODY HEALTH ANNUAL PLUS CHECK - FEMALE - 2D ECHO - PAN INDIA - FY2324

Test Name	Result	Unit	Bio. Ref. Interval	Method
RENAL PROFILE/KIDNEY FUNCTION TEST (RFT/KFT) , SERUM				
CREATININE	0.51	mg/dL	0.51-1.04	Enzymatic colorimetric
UREA	14.93	mg/dL	15-36	Urease
BLOOD UREA NITROGEN	7.0	mg/dL	8.0 - 23.0	Calculated
URIC ACID	4.46	mg/dL	2.6-6	Uricase
CALCIUM	10.44	mg/dL	8.4 - 10.2	Arsenazo-III
PHOSPHORUS, INORGANIC	3.51	mg/dL	2.5-4.5	PMA Phenol
SODIUM	137	mmol/L	135-145	Direct ISE
POTASSIUM	3.8	mmol/L	3.5-5.1	Direct ISE
CHLORIDE	101	mmol/L	98 - 107	Direct ISE
PROTEIN, TOTAL	6.94	g/dL	6.3-8.2	Biuret
ALBUMIN	4.68	g/dL	3.5 - 5	Bromocresol Green
GLOBULIN	2.26	g/dL	2.0-3.5	Calculated
A/G RATIO	2.07		0.9-2.0	Calculated




Dr. Kritika Jain
M.B.B.S, M.D (Pathology)
Consultant Pathologist



SIN No: SE04841928

This test has been performed at Apollo Health and Lifestyle Ltd/Lab

Apollo Health and Lifestyle Limited

(CIN - U05110TG2000PLC115819)

Corporate Office: 7-1-617/A, 7th Floor, Imperial Towers, Ameerpet, Hyderabad-500016, Telangana

Ph No: 040-4904 7777 | www.apollohl.com | Email ID: enquiry@apollohl.com

Patient Name : Mrs.NAGMA MANSOORI	Collected : 05/Nov/2024 10:28AM
Age/Gender : 31 Y 3 M 28 D/F	Received : 05/Nov/2024 10:44AM
UHID/MR No : RIND.0000017848	Reported : 05/Nov/2024 12:04PM
Visit ID : RINDOPV19490	Status : Final Report
Ref Doctor : Dr.SELF	Sponsor Name : ARCOFEMI HEALTHCARE LIMITED
Emp/Auth/TPA ID : 22S37524	

DEPARTMENT OF BIOCHEMISTRY

ARCOFEMI - MEDIWHEEL - FULL BODY HEALTH ANNUAL PLUS CHECK - FEMALE - 2D ECHO - PAN INDIA - FY2324

Test Name	Result	Unit	Bio. Ref. Interval	Method
GAMMA GLUTAMYL TRANSPEPTIDASE (GGT) , SERUM	26.13	U/L	12-43	Glycylglycine Nitoranalide




Dr. Kritika Jain
M.B.B.S, M.D (Pathology)
Consultant Pathologist

SIN No: SE04841928

This test has been performed at Apollo Health and Lifestyle Ltd/Lab

Apollo Health and Lifestyle Limited

(CIN - U05110TG2000PLC115819)

Corporate Office: 7-1-617/A, 7th Floor, Imperial Towers, Ameerpet, Hyderabad-500016, Telangana

Ph No: 040-4904 7777 | www.apollohl.com | Email ID: enquiry@apollohl.com



Patient Name : Mrs.NAGMA MANSOORI	Collected : 05/Nov/2024 10:28AM
Age/Gender : 31 Y 3 M 28 D/F	Received : 05/Nov/2024 03:39PM
UHID/MR No : RIND.0000017848	Reported : 05/Nov/2024 05:27PM
Visit ID : RINDOPV19490	Status : Final Report
Ref Doctor : Dr.SELF	Sponsor Name : ARCOFEMI HEALTHCARE LIMITED
Emp/Auth/TPA ID : 22S37524	

DEPARTMENT OF IMMUNOLOGY

ARCOFEMI - MEDIWHEEL - FULL BODY HEALTH ANNUAL PLUS CHECK - FEMALE - 2D ECHO - PAN INDIA - FY2324

Test Name	Result	Unit	Bio. Ref. Interval	Method
THYROID PROFILE TOTAL (T3, T4, TSH) , SERUM				
TRI-IODOTHYRONINE (T3, TOTAL)	1.2	ng/mL	0.87-1.78	CLIA
THYROXINE (T4, TOTAL)	11.56	µg/dL	5.48-14.28	CLIA
THYROID STIMULATING HORMONE (TSH)	3.303	µIU/mL	0.38-5.33	CLIA

Comment:

For pregnant females	Bio Ref Range for TSH in uIU/ml (As per American Thyroid Association)
First trimester	0.1 - 2.5
Second trimester	0.2 – 3.0
Third trimester	0.3 – 3.0

- TSH is a glycoprotein hormone secreted by the anterior pituitary. TSH activates production of T3 (Triiodothyronine) and its prohormone T4 (Thyroxine). Increased blood level of T3 and T4 inhibit production of TSH.
- TSH is elevated in primary hypothyroidism and will be low in primary hyperthyroidism. Elevated or low TSH in the context of normal free thyroxine is often referred to as sub-clinical hypo- or hyperthyroidism respectively.
- Both T4 & T3 provides limited clinical information as both are highly bound to proteins in circulation and reflects mostly inactive hormone. Only a very small fraction of circulating hormone is free and biologically active.
- Significant variations in TSH can occur with circadian rhythm, hormonal status, stress, sleep deprivation, medication & circulating antibodies.

TSH	T3	T4	FT4	Conditions
High	Low	Low	Low	Primary Hypothyroidism, Post Thyroidectomy, Chronic Autoimmune Thyroiditis
High	N	N	N	Subclinical Hypothyroidism, Autoimmune Thyroiditis, Insufficient Hormone Treatment.
N/Low	Low	Low	Low	Secondary and Tertiary Hypothyroidism
Low	High	High	High	Primary Hyperthyroidism, Goitre, Thyroiditis, Drug effects, Early Pregnancy
Low	N	N	N	Subclinical Hyperthyroidism
Low	Low	Low	Low	Central Hypothyroidism, Treatment with Hyperthyroidism
Low	N	High	High	Thyroiditis, Interfering Antibodies
N/Low	High	N	N	T3 Thyrotoxicosis, Non thyroidal causes
High	High	High	High	Pituitary Adenoma; TSHoma/Thyrotropinoma



Dr. Tanish Mandal
M.B.B.S, M.D(Pathology)
Consultant Pathologist
SIN No: SPL24145707



Patient Name : Mrs.NAGMA MANSOORI
Age/Gender : 31 Y 3 M 28 D/F
UHID/MR No : RIND.0000017848
Visit ID : RINDOPV19490
Ref Doctor : Dr.SELF
Emp/Auth/TPA ID : 22S37524

Collected : 05/Nov/2024 10:28AM
Received : 05/Nov/2024 03:39PM
Reported : 05/Nov/2024 05:27PM
Status : Final Report
Sponsor Name : ARCOFEMI HEALTHCARE LIMITED

DEPARTMENT OF IMMUNOLOGY

ARCOFEMI - MEDIWHEEL - FULL BODY HEALTH ANNUAL PLUS CHECK - FEMALE - 2D ECHO - PAN INDIA - FY2324



Dr. Tanish Mandal
M.B.B.S, M.D (Pathology)
Consultant Pathologist
SIN No: SPL24145707



Patient Name : Mrs.NAGMA MANSOORI	Collected : 05/Nov/2024 04:04PM
Age/Gender : 31 Y 3 M 28 D/F	Received : 05/Nov/2024 04:22PM
UHID/MR No : RIND.0000017848	Reported : 05/Nov/2024 04:59PM
Visit ID : RINDOPV19490	Status : Final Report
Ref Doctor : Dr.SELF	Sponsor Name : ARCOFEMI HEALTHCARE LIMITED
Emp/Auth/TPA ID : 22S37524	

DEPARTMENT OF CLINICAL PATHOLOGY

ARCOFEMI - MEDIWHEEL - FULL BODY HEALTH ANNUAL PLUS CHECK - FEMALE - 2D ECHO - PAN INDIA - FY2324

Test Name	Result	Unit	Bio. Ref. Interval	Method
COMPLETE URINE EXAMINATION (CUE) , URINE				
PHYSICAL EXAMINATION				
COLOUR	PALE YELLOW		PALE YELLOW	Visual
TRANSPARENCY	CLEAR		CLEAR	Physical Measurement
pH	6.0		5-7.5	Double Indicator
SP. GRAVITY	1.010		1.002-1.030	Bromothymol Blue
BIOCHEMICAL EXAMINATION				
URINE PROTEIN	NEGATIVE		NEGATIVE	Protein Error Of Indicator
GLUCOSE	NEGATIVE		NEGATIVE	Glucose Oxidase
URINE BILIRUBIN	NEGATIVE		NEGATIVE	Azo Coupling Reaction
URINE KETONES (RANDOM)	NEGATIVE		NEGATIVE	Sodium Nitro Prusside
UROBILINOGEN	NEGATIVE		NORMAL	Modified Ehrlich Reaction
NITRITE	NEGATIVE		NEGATIVE	Diazotization
LEUCOCYTE ESTERASE	NEGATIVE		NEGATIVE	Leucocyte Esterase
CENTRIFUGED SEDIMENT WET MOUNT AND MICROSCOPY				
PUS CELLS	1-2	/hpf	0-5	Microscopy
EPITHELIAL CELLS	2-3	/hpf	<10	Microscopy
RBC	ABSENT	/hpf	0-2	Microscopy
CASTS	NIL		0-2 Hyaline Cast	Microscopy
CRYSTALS	ABSENT		ABSENT	Microscopy

Comment:

All urine samples are checked for adequacy and suitability before examination. All abnormal chemical examination are rechecked and verified by manual methods. Microscopy findings are reported as an average of 10 high power fields.



Dr. Kritika Jain
M.B.B.S, M.D (Pathology)
Consultant Pathologist



SIN No: UR2418851

This test has been performed at Apollo Health and Lifestyle Ltd/Lab

Apollo Health and Lifestyle Limited

(CIN - U85110TG2000PLC115819)

Corporate Office: 7-1-617/A, 7th Floor, Imperial Towers, Ameerpet, Hyderabad-500016, Telangana

Ph No: 040-4904 7777 | www.apollohl.com | Email ID: enquiry@apollohl.com

Patient Name : Mrs.NAGMA MANSOORI	Collected : 05/Nov/2024 04:04PM
Age/Gender : 31 Y 3 M 28 D/F	Received : 05/Nov/2024 04:23PM
UHID/MR No : RIND.0000017848	Reported : 05/Nov/2024 05:00PM
Visit ID : RINDOPV19490	Status : Final Report
Ref Doctor : Dr.SELF	Sponsor Name : ARCOFEMI HEALTHCARE LIMITED
Emp/Auth/TPA ID : 22S37524	

DEPARTMENT OF CLINICAL PATHOLOGY

ARCOFEMI - MEDIWHEEL - FULL BODY HEALTH ANNUAL PLUS CHECK - FEMALE - 2D ECHO - PAN INDIA - FY2324

Test Name	Result	Unit	Bio. Ref. Interval	Method
URINE GLUCOSE(POST PRANDIAL)	NEGATIVE		NEGATIVE	GOD-POD

Test Name	Result	Unit	Bio. Ref. Interval	Method
URINE GLUCOSE(FASTING)	NEGATIVE		NEGATIVE	GOD-POD




Dr. Kritika Jain
M.B.B.S, M.D (Pathology)
Consultant Pathologist

SIN No: UF012149

This test has been performed at Apollo Health and Lifestyle Ltd/Lab

Apollo Health and Lifestyle Limited

(CIN - U85110TG2000PLC115819)

Corporate Office: 7-1-617/A, 7th Floor, Imperial Towers, Ameerpet, Hyderabad-500016, Telangana

Ph No: 040-4904 7777 | www.apollohl.com | Email ID: enquiry@apollohl.com



Patient Name : Mrs.NAGMA MANSOORI	Collected : 05/Nov/2024 10:28AM
Age/Gender : 31 Y 3 M 28 D/F	Received : 05/Nov/2024 03:35PM
UHID/MR No : RIND.0000017848	Reported : 06/Nov/2024 09:05PM
Visit ID : RINDOPV19490	Status : Final Report
Ref Doctor : Dr.SELF	Sponsor Name : ARCOFEMI HEALTHCARE LIMITED
Emp/Auth/TPA ID : 22S37524	

DEPARTMENT OF CYTOLOGY

LBC PAP SMEAR , CERVICAL BRUSH SAMPLE

	CYTOLOGY NO.	L/1736/24
I	SPECIMEN	
a	SPECIMEN ADEQUACY	ADEQUATE
b	SPECIMEN TYPE	LIQUID-BASED PREPARATION (LBC)
	SPECIMEN NATURE/SOURCE	CERVICAL SMEAR
c	ENDOCERVICAL-TRANSFORMATION ZONE	ABSENT
d	COMMENTS	SATISFACTORY FOR EVALUATION
II	MICROSCOPY	Smear shows sheets of superficial, intermediate squamous cells. Also seen budding yeast with acute inflammation.
III	RESULT	
a	EPITHELIAL CELL	
	SQUAMOUS CELL ABNORMALITIES	NOT SEEN
	GLANDULAR CELL ABNORMALITIES	NOT SEEN
b	ORGANISM	FUNGAL ORGANISMS MORPHOLOGICALLY CONSISTENT WITH CANDIDA SPP
c	NON NEOPLASTIC FINDINGS	INFLAMMATORY SMEAR
d	OTHERS	REACTIVE CHANGES ASSOCIATED WITH INFLAMMATION
IV	INTERPRETATION	NEGATIVE FOR INTRAEPITHELIAL LESION OR MALIGNANCY

Pap Test is a screening test for cervical cancer with inherent false negative results. Regular screening and follow-up is recommended (Bethesda-TBS-2014) revised

*** End Of Report ***

Page 14 of 14



Dr Nidhi Sachdev
M.B.B.S,MD(Pathology)
Consultant Pathologist

SIN No:CS085718




Patient Name : Mrs.NAGMA MANSOORI
Age/Gender : 31 Y 3 M 28 D/F
UHID/MR No : RIND.0000017848
Visit ID : RINDOPV19490
Ref Doctor : Dr.SELF
Emp/Auth/TPA ID : 22S37524

Collected : 05/Nov/2024 10:28AM
Received : 05/Nov/2024 03:35PM
Reported : 06/Nov/2024 09:05PM
Status : Final Report
Sponsor Name : ARCOFEMI HEALTHCARE LIMITED

TERMS AND CONDITIONS GOVERNING THIS REPORT

1. Reported results are for information and interpretation of the referring doctor or such other medical professionals, who understand reporting units, reference ranges and limitation of technologies. Laboratories not be responsible for any interpretation whatsoever.
2. It is presumed that the tests performed are, on the specimen / sample being to the patient named or identified and the verifications of particulars have been confirmed by the patient or his / her representative at the point of generation of said specimen.
3. The reported results are restricted to the given specimen only. Results may vary from lab to lab and from time to time for the same parameter for the same patient (within subject biological variation).
4. The patient details along with their results in certain cases like notifiable diseases and as per local regulatory requirements will be communicated to the assigned regulatory bodies.
5. The patient samples can be used as part of internal quality control, test verification, data analysis purposes within the testing scope of the laboratory.
6. This report is not valid for medico legal purposes. It is performed to facilitate medical diagnosis only.



Dr Nidhi Sachdev
M.B.B.S,MD(Pathology)
Consultant Pathologist

SIN No:CS085718





भारत सरकार

Government of India



नगमा मसूरी

NAGMA MANSOORI

जन्म तिथि / DOB : 08/07/1993

लिंग / Gender



5683 4479 3972

आधार - आम आदमी का अधिकार

From: noreply@apolloclinics.info
Sent: 04 November 2024 11:33
To: rukhsad.mansuri@bankofbaroda.com
Cc: fo.indira@apollocradle.com
Subject: Your appointment is confirmed



Dear Nagma Mansoori,

Greetings from Apollo Clinics,

Your corporate health check appointment is confirmed at **Apollo Cradle & Children's Hospital Indirapuram clinic** on **2024-11-05** at **08:00-08:30**.

Payment Mode	
Corporate Name	ARCOFEMI HEALTHCARE LIMITED
Agreement Name	[ARCOFEMI MEDIWHEEL FEMALE AHC CREDIT PAN INDIA OP AGREEMENT]
Package Name	[ARCOFEMI - MEDIWHEEL - FULL BODY HEALTH ANNUAL PLUS CHECK - FEMALE - 2D ECHO - PAN INDIA - FY2324]

"Kindly carry with you relevant documents such as HR issued authorization letter and or appointment confirmation mail and or valid government ID proof and or company ID card and or voucher as per our agreement with your company or sponsor."

Note: Video recording or taking photos inside the clinic premises or during camps is not allowed and would attract legal consequences.

Note: Also once appointment is booked, based on availability of doctors at clinics tests will happen, any pending test will happen based on doctor availability and clinics will be updating the same to customers.



Apollo Cradle CONSENT FORM

Patient Name: NAGMA -MANSOORI Age: 31/F

UHD Number: 17848 Company Name: ARCOFEMI

I Mr/Mrs/Ms NAGMA -MANSOORI Employee of ARCOFEMI

(Company) Want to inform you that I am not interested in getting OPHTHAL & DIET

Tests done which is a part of my routine health check package.

And I claim the above statement in my full consciousness.

Patient Signature:

Date: 05/11/24

CERTIFICATE OF MEDICAL FITNESS

This is to certify that I have conducted the clinical examination

of Miss Nagma on 6/11/24

After reviewing the medical history and on clinical examination it has been found that he/she is

	Tick
<ul style="list-style-type: none"> • Medically Fit 	✓
<ul style="list-style-type: none"> • Fit with restrictions/recommendations <p>Though following restrictions have been revealed, in my opinion, these are not impediments to the job.</p> <p>1.....</p> <p>2.....</p> <p>3.....</p> <p>However the employee should follow the advice/medication that has been communicated to him/her.</p> <p>Review after _____</p>	
<ul style="list-style-type: none"> • Currently Unfit. <p>Review after _____ recommended</p>	
<ul style="list-style-type: none"> • Unfit 	

Dr. SHAILESH KUMAR (Physician)
 Road No. 61
 Apollo Cradle and Children's Hospital
 NH-1, Shakti Khand 2, Indrapuram,
 Ghaziabad, Uttar Pradesh - 201014

Dr. _____
Medical Officer

This certificate is not meant for medico-legal purposes

Address: NH-1, Shakti Khand 2, Indrapuram, Ghaziabad, Uttar Pradesh – 201014.
 Ph No: +91 88106 85179, 1860 500 4424

Apollo Specialty Hospitals Private Limited

(Formerly known as Nova Specialty Hospitals Private Limited) CIN - U85100TG2009PTC098414

Regd Office: #7-1617/A, 615 & 616, 7th Floor, Imperial Towers, Opp: Ameerpet Metro Station, Ameerpet, Hyderabad - 500038.
 Ph No: 040 - 4904 7777, Fax No: 4904 7744 | www.apollocradle.com | Email ID: info.cradle@apollocradle.com

5/11/24.

Nagma. Namrozi
31/F

MH- Reg LMP- 3/10/20
on- P₂ home uses
LD- 5yr

c/o white BPS (+)

P/S CK @ nab cyst (+)
white BPS

LSE done.

- > Adv
T. Foreau 150 mg 1st OD 1st 5 day.
alt day
- Co Floxite 400 mg 1st OD 1st 20 day.
- Remin E report
- Daktel Nano shots weekly * (10)

Date:

Dr. NILOTPAL MISHRA
B.D.S. | M.D.S.
Fellow Head & Neck Oncology
Sr. Consultant Dental
Mobile Number: +91 9625328945, 9667406341



PATIENT NAME:	Ms Nagma Mamoon
UHID:	RIND 0000017848

O/E:-
- oral prophylaxis
- stains / calculus (+)

Adv:-
- Scaling

DR. NILOTPAL MISHRA
BDS, MDS(OMFS)
KSDC 35654A
Doctor Signature
Dr. NILOTPAL MISHRA
BDS, MDS(OMFS)
KSDC 35654A

Address: NH-1, Shakti Khand 2, Indrapuram, Ghaziabad, Uttar Pradesh - 201014.

Ph No: +91 88106 85179, 1860 500 4424

Apollo Specialty Hospitals Private Limited

(Formerly known as Nova Specialty Hospitals Private Limited) CIN - U85100TG2009PTC099414

Regd Office: #7-1617/A, 815 & 816, 7th Floor, Imperial Towers, Opp: Ameerpet Metro Station, Ameerpet, Hyderabad - 500038.

Ph No: 040 - 4804 7777, Fax No: 4904 7744 | www.apollocradle.com | Email ID: info.cradle@apollocradle.com



Date : 05.11.2024
MR NO : RIND0000017848

Name : Mrs. Nagma Mansoori
Age/ Gender : 31 Y / Female

Consultation Timing : 09:14

Department : GENERAL

Doctor :

Registration No :

Qualification :

Apollo
Cradle
& Children's
Hospital

Height : 161 cm.	Weight 60 kg	BMI :	Waist Circum :
Temp : 98.4 F	Pulse	Resp : 42/min	B.P : 130/80 mmHg

General Examination/Allergies
History

Clinical Diagnosis & Management Plan

Follow up date

Doctor Signature

OUR NETWORK: AMRITSAR | BENGALURU | CHENNAI | HYDERABAD | DELHI NCR

Visit us: www.apollocradle.com Write to us: contactus@apollocradle.com

1860 500 4424

www.apollocradle.com

A unit of Apollo Specialty Hospitals Pvt. Ltd.

ID: 17149

05-11-2024 09:55:56

Male Years

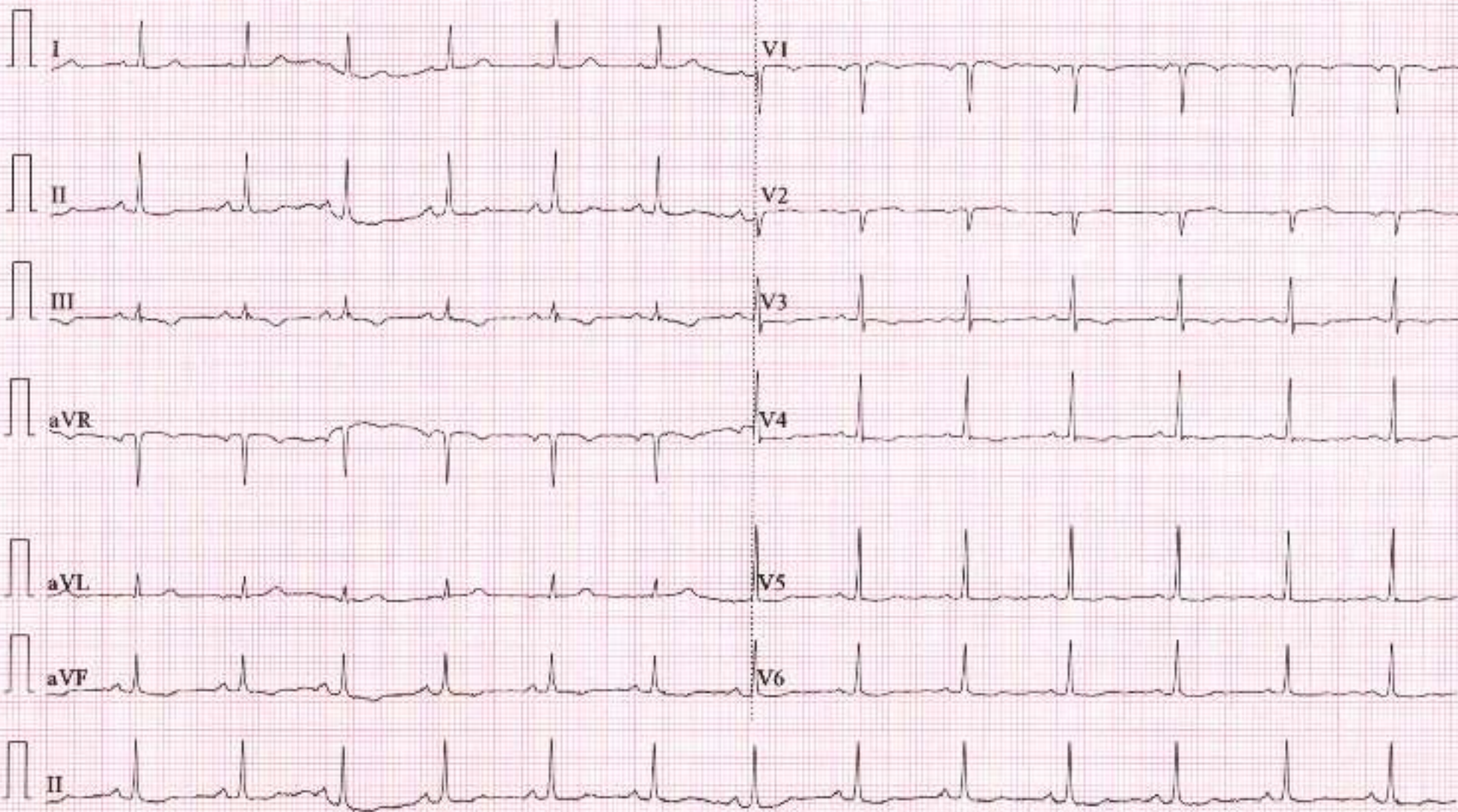
Req. No. :

HR : 80 bpm
P : 94 ms
PR : 152 ms
QRS : 82 ms
QT/QTcBz : 355/412 ms
P/QRS/T : 69/47/ 20 °
RV5/SV1 : 1.270/0.858 mV

Diagnosis Information:



Unconfirmed Report.



KINDLY NOTE: OPHTHAL BY GENERAL TEST PENDING FROM PATIENT SIDE

Patient Name	: Mrs. Nagma Mansoori	Age/Gender	: 31 Y/F
UHID/MR No.	: RIND.0000017848	OP Visit No	: RINDOPV19490
Sample Collected on	:	Reported on	: 05-11-2024 13:14
LRN#	: RAD2431773	Specimen	:
Ref Doctor	: SELF		
Emp/Auth/TPA ID	: 22S37524		

DEPARTMENT OF RADIOLOGY

ULTRASOUND - WHOLE ABDOMEN

LIVER : Liver is mildly enlarged in size (15.5cm) and the parenchymal echotexture shows grade-1 diffuse fatty infiltration. Intra-hepatic biliary radicals are not dilated. Portal vein is normal in course and calibre.

GALL BLADDER : Gall bladder not seen (Past history of operation). Common duct is not dilated.

PANCREAS : Pancreas is normal in size and echopattern.

SPLEEN : Spleen is normal in size, shape and echopattern. No focal lesion seen. Hilum is normal.

KIDNEYS : Both the kidneys are normal in position, shape, size, outline and echotexture. Cortico-medullary differentiation of both kidneys is maintained. Central sinus echoes are compact.

Visualized parts of the retroperitoneum do not reveal any lymphadenopathy.

URINARY BLADDER : Urinary bladder is normal in wall thickness. **Few internal echoes seen in urinary bladder.**

UTERUS : The uterus is normal in size and echotexture. The myometrial echogenicity appears uniform. Endometrium is central and of normal thickness(7.1mm). **10x9.4mm sized small intramural fibroid seen in fundus of uterus and 9x9mm sized seen at anterior wall of body of uterus.**

OVARIES : Both the ovaries appears normal in size and echopattern. No obvious adnexal mass or collection is seen.

No free fluid seen in cul-de-sac.

IMPRESSION:

1. **Hepatomegaly with grade 1 Fatty infiltration of the liver.**
2. **Few internal echoes in urinary bladder - ? concentrated urine / ? cystitis.**
3. **Small intramural uterine fibroids as described above.**

SUGGEST CLINICAL CORRELATION

Patient Name : Mrs. Nagma Mansoori

Age/Gender

: 31 Y/F

(The sonography findings should always be considered in correlation with the clinical and other investigation finding where applicable.) It is only a professional opinion, Not valid for medico legal purpose.

A handwritten signature in black ink, enclosed in a rectangular box. The signature appears to be "SANGEETA AGGARWAL".

Dr. SANGEETA AGGARWAL
MBBS, MD
Radiology

Patient Name	: Mrs. Nagma Mansoori	Age/Gender	: 31 Y/F
UHID/MR No.	: RIND.0000017848	OP Visit No	: RINDOPV19490
Sample Collected on	:	Reported on	: 05-11-2024 12:55
LRN#	: RAD2431773	Specimen	:
Ref Doctor	: SELF		
Emp/Auth/TPA ID	: 22S37524		

DEPARTMENT OF RADIOLOGY

X-RAY CHEST PA

Both the lung fields and hilar shadows appears normal.

There is no obvious active pleuro-parenchymal lesion seen.

Both the costophrenic and cardiophrenic angles are clear.

Cardiac size appears within normal limits.

Both dome of hemidiaphragms are normal in position and contour.

Thoracic wall and soft tissues under view appear normal.

CONCLUSION :

No obvious abnormality seen



Dr. SANGEETA AGGARWAL
MBBS, MD
Radiology

Patient Name : Mrs. Nagma Mansoori Age : 31 Y/F
UHID : RIND.0000017848 OP Visit No : RINDOPV19490
Conducted By: : Dr. SANJIV KUMAR GUPTA Conducted Date : 05-11-2024 13:20
Referred By : SELF

2D-ECHO WITH COLOUR DOPPLER

Dimensions:

Ao (ed)	2.90 CM
LA (es)	2.90 CM
LVID (ed)	3.90 CM
LVID (es)	2.63 CM
IVS (Ed)	0.907 CM
LVPW (Ed)	1.09 CM
EF	65.00%
%FD	33.00%
MITRAL VALVE :	NORMAL
AML	NORMAL
PML	NORMAL
AORTIC VALVE	NORMAL
TRICUSPID VALVE	NORMAL
RIGHT VENTRICLE	NORMAL
INTER ATRIAL SEPTUM	NORMAL
INTER VENTRICULAR SEPTUM	INTACT
AORTA	NORMAL
RIGHT ATRIUM	NORMAL
LEFT ATRIUM	NORMAL
Pulmonary Valve	NORMAL
PERICARDIUM	NORMAL

Patient Name	: Mrs. Nagma Mansoori	Age	: 31 Y/F
UHID	: RIND.0000017848	OP Visit No	: RINDOPV19490
Conducted By:	: Dr. SANJIV KUMAR GUPTA	Conducted Date	: 05-11-2024 13:20
Referred By	: SELF		

NO REGIONAL WALL MOTION ABNORMALITY

NORMAL LEFT VENTRICULAR SYSTOLIC FUNCTION

COLOUR AND DOPPLER STUDIES NORMAL

PWD: A>E AT MITRAL INFLOW NORMAL


VELOCITY ACROSS THE AV NORMAL

IMPRESSION:

GOOD LV/RV FUNCTION

NO MR/NO AR /NO TR/NOPAH.NO CLOT

NO PERICARDIAL EFFUSION.



Dr. SANJIV

Patient Name : Mrs. Nagma Mansoori Age : 31 Y/F
UHID : RIND.0000017848 OP Visit No : RINDOPV19490
Conducted By: : Dr. SANJIV KUMAR GUPTA Conducted Date : 05-11-2024 13:20
Referred By : SELF

KUMAR
GUPTA