

CERTIFICATE OF MEDICAL FITNESS

This is to certify that I have conducted the clinical examination

of Mr Vijay Kade on 11/11/2024

After reviewing the medical history and on clinical examination it has been found that he/she is

	Tick
<ul style="list-style-type: none">• Medically Fit	<input type="checkbox"/>
<ul style="list-style-type: none">• Fit with restrictions/recommendations <p>Though following restrictions have been revealed, in my opinion, these are not impediments to the job.</p> <ol style="list-style-type: none">1. <u>High Sugar, Uncontrolled D.M.</u>2. <u>Dyslipidemia</u>3. <u>Mild Reduction in Sodium levels</u> <p>However the employee should follow the advice/medication that has been communicated to him/her.</p> <p>Review after _____</p>	<input checked="" type="checkbox"/>
<ul style="list-style-type: none">• Currently Unfit. Review after _____ recommended	<input type="checkbox"/>
<ul style="list-style-type: none">• Unfit	<input type="checkbox"/>

Dr. 
Medical Officer
The Apollo Clinic, (Location)

This certificate is not meant for medico-legal purposes

DR. MUSHFIYA BAHRAINWALA
M.B.B.S
Reg. No.: 47527
Apollo Clinic, Kondhwa
NIBM Road, Kondhwa.

Name: Mr. Vijay Dnyandes Korde
Age: 39y
Date: 9/11/2024

Height: 176cm	Weight: 94kg	BMI:	Waist Circum:
Temp:	Pulse:	Resp:	B.P: 130/80/80

General Examination / Allergies History

K/ds: DM 2
Ayurvedic meds
FUE HTN

Clinical Diagnosis & Management Plan

For Acc
No iss. at the moment
O/E: CVS }
 CRS }
 Resp }
 Abd }
Flup & Reports

Follow up date:

Doctor Signature

Apollo Clinic, Wanowrie

*AMBA VATICA, Plot No. B-1, Survey No. 16A/2, Wanowrie, Khondawa Khurd, Taluka Havell, Pune, Pin: 411048 | Phone: (020) 2683 0291/95

Follow us /ApolloClinicIndia /ApolloClinics

BOOK YOUR APPOINTMENT TODAY!

Whatsapp Number : 970 100 3333

Toll Number : 1860 500 7788

Website : www.apolloclinic.com

GE MAC1200 ST KORDE, VIJAY 000138549, APOLLO CLINIC WANOWRTE
Male, 39 Years (06.05.1985)

ASW CE

HR 95 bpm

WNL
[Signature]

DR. MUSHFIYA BAHRAINWALA
M.B.B.S
Reg. No.: 47527
Apollo Clinic Wanowarie
NIBM Road, Kondhwa.

Unconfirmed report.

Interpretation:

normal ECG

< P
< T
< QRS

aVL
0 I

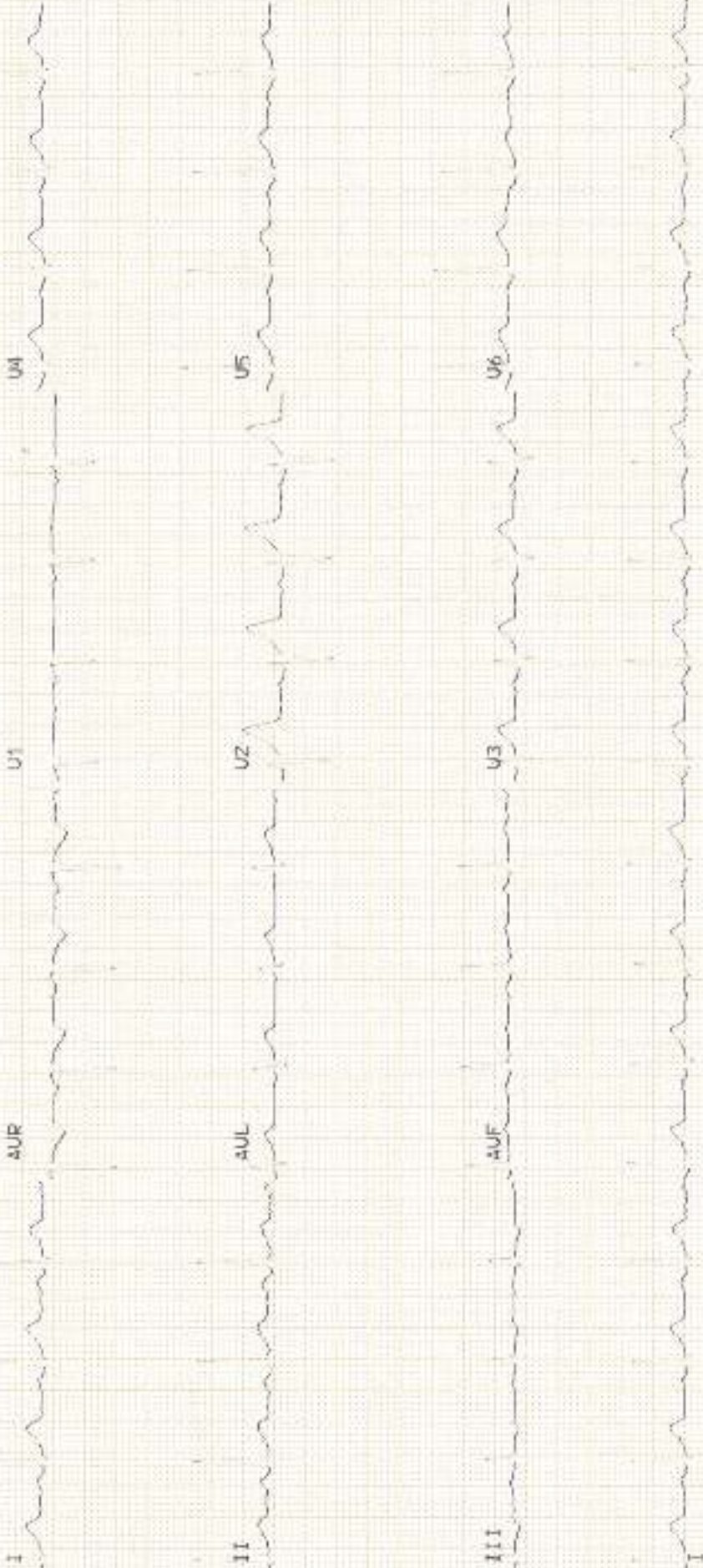
-90

aVR

+90 II

Measurement Results:

QRS	84 ms
QT/QTcB	334 / 421 ms
PR	142 ms
P	114 ms
RR/PP	630 / 630 ms
P/QRS/T	55 / 45 / 15 degrees
QTd/QTcBd	58 / 73 ms
Sokolow	2.0 mV
MK	13



Patient Name	: Mr. Vijay Dnyandeo Korde	Age	: 39Yrs 6Mths 3Days
UHID	: CWAN.0000138548	OP Visit No.	: CWANOPV243182
Printed On	: 09-11-2024 12:41 PM	Advised/Pres Doctor	: --
Department	: Radiology	Qualification	: --
Referred By	: Self	Registration No.	: --
Employee Id	: 22838196		

DEPARTMENT OF RADIOLOGY

CHEST RADIOGRAPH PA VIEW

Both lung fields and hila are normal .

No obvious active pleuro-parenchymal lesion seen .

Both costophrenic and cardiophrenic angles are clear .

Cardiac shadow is normal.

Both diaphragms are normal in position and contour .

Thoracic wall and soft tissues appear normal.

CONCLUSION :

No obvious abnormality seen.

---End Of The Report---



Dr.SATINDER LAMBA
MBBS, DMRE , MD (USAIM)
2004/02/388
Radiology

2D ECHOCARDIOGRAPHY & COLOR DOPPLER STUDY

Name : MR. VIJAY KORDE Age/Sex :39/M Date 09/11/2024.

2D Echo:-

Cardiac chamber dimensions –Normal

Wall motion abnormalities - no RWMA

LV systolic function - Normal, LVEF -60%

LV diastolic function – No LV Diastolic dysfunction.

Cardiac valves -

Mitral valve –Normal, No mitral regurgitation.

Aortic valve – Three thin leaflets, no aortic regurgitation, Aortic PG –09mm Hg

Tricuspid valve –No tricuspid regurgitation.

Pulmonary valve - normal

Septae (IAS/IVS) – intact

Clot/vegetation/Pericardial effusion – No

Great Arteries (Aorta/pulmonary artery) - Normal

IVC - Normal

Measurements -


Aorta	LA	IVS	PWD	LVIDd	LVIDs	LVEF
25	32	10	10	37	30	60%

Conclusion:-

No RWMA, normal LV systolic function, LVEF – 60%

No LV Diastolic dysfunction.

Normal PA pressure.



Dr. Bhushan Bari
DNB Medicine, DNB Cardiology
Consultant and Interventional Cardiologist

Apollo Health and Lifestyle Limited

ICIN - UB5110TG2006PLC115815

Regd. Office: 1-10-60/62, Ashoka Raghupathi Chambers, 5th Floor, Begumpet, Hyderabad, Telangana - 500 016.

Ph No: 040-4904 7777, Fax No: 4904 7744 | Email ID: enquiry@apollohl.com | www.apollohl.com

APOLLO CLINICS NETWORK MAHARASHTRA

Pune (Aundh) | Kharadi | Nigdi Pradhikaran | Viman Nagar | Warowke

Online appointments: www.apolloclinic.com

TO BOOK AN APPOINTMENT

 **1860 500 7788**

Patient Name	: Mr. Vijay Dnyandeo Korde	Age	: 39Yrs 6Mths 3Days
UHID	: CWAN.0000138549	OP Visit No.	: CWANOPV243182
Printed On	: 09-11-2024 01:21 PM	Advised/Pres Doctor	: --
Department	: Radiology	Qualification	: --
Referred By	: Self	Registration No.	: --
Employee Id	: 22538196		

DEPARTMENT OF RADIOLOGY

USG - WHOLE ABDOMEN / PELVIS

Liver appears normal in size and shows bright echotexture. No focal lesion is seen. PV and CBD normal.

No dilatation of the intrahepatic biliary radicals.

Gall bladder is distended. No evidence of calculus. Wall thickness appears normal. No evidence of focal lesion.

Spleen appears normal. No focal lesion seen. Splenic vein appears normal.

Pancreas appears normal in echopattern. No focal mass lesion/calcification. No evidence of peripancreatic free fluid or collection. Pancreatic duct appears normal.

Both the kidneys appear normal in size, shape and echopattern. Cortical thickness and CM differentiation are maintained. No calculus / hydronephrosis seen on either side.

Urinary Bladder is distended and appears normal. No evidence of any wall thickening or abnormality. No evidence of any intrinsic or extrinsic bladder abnormality.

Prostate is normal in size and echo texture. No evidence of necrosis/calcification.

No free fluid / retroperitoneal lymphadenopathy seen.

IMPRESSION:-

Grade I Hepatic steatosis.

No other significant abnormality detected.

Suggest - clinical correlation.

(The sonography findings should always be considered in correlation with the clinical and other investigation finding where applicable.) It is only a professional opinion, Not valid for medico legal purpose.

---End Of The Report---



Dr.SATINDER LAMBHA
MBBS, DMRE , MD (USAIM)
2004/02/386
Radiology

Patient Name : Mr.VIJAY DNYANDEO KORDE	Collected : 09/Nov/2024 01:36PM
Age/Gender : 39 Y 6 M 3 D/M	Received : 09/Nov/2024 03:43PM
UHID/MR No : CWAN.0000138549	Reported : 09/Nov/2024 04:05PM
Visit ID : CWANOPV243182	Status : Final Report
Ref Doctor : Self	Sponsor Name : ARCOFEMI HEALTHCARE LIMITED
Emp/Auth/TPA ID : 22S38196	

DEPARTMENT OF BIOCHEMISTRY

ARCOFEMI - MEDIWHEEL - FULL BODY ANNUAL PLUS MALE - 2D ECHO - PAN INDIA - FY2324

Test Name	Result	Unit	Bio. Ref. Interval	Method
GLUCOSE, POST PRANDIAL (PP), 2 HOURS , SODIUM FLUORIDE PLASMA (2 HR)	350	mg/dL	70-140	HEXOKINASE

Comment:

It is recommended that FBS and PPBS should be interpreted with respect to their Biological reference ranges and not with each other.
 Conditions which may lead to lower postprandial glucose levels as compared to fasting glucose levels may be due to reactive hypoglycemia, dietary meal content, duration or timing of sampling after food digestion and absorption, medications such as insulin preparations, sulfonylureas, amylin analogues, or conditions such as overproduction of insulin.



DR.Sanjay Ingle
 M.B.B.S,M.D(Pathology)
 Consultant Pathologist

SIN No:CWA241100309

This test has been performed at Apollo Health and Lifestyle Ltd- Sadashiv Peth Pune, Diagnostics Lab



Patient Name : Mr.VIJAY DNYANDEO KORDE	Collected : 09/Nov/2024 10:44AM
Age/Gender : 39 Y 6 M 3 D/M	Received : 09/Nov/2024 03:42PM
UHID/MR No : CWAN.0000138549	Reported : 09/Nov/2024 04:36PM
Visit ID : CWANOPV243182	Status : Final Report
Ref Doctor : Self	Sponsor Name : ARCOFEMI HEALTHCARE LIMITED
Emp/Auth/TPA ID : 22S38196	

DEPARTMENT OF BIOCHEMISTRY

ARCOFEMI - MEDIWHEEL - FULL BODY ANNUAL PLUS MALE - 2D ECHO - PAN INDIA - FY2324

Test Name	Result	Unit	Bio. Ref. Interval	Method
HBA1C (GLYCATED HEMOGLOBIN) , WHOLE BLOOD EDTA				
HBA1C, GLYCATED HEMOGLOBIN	9	%		HPLC
ESTIMATED AVERAGE GLUCOSE (eAG)	212	mg/dL		Calculated

Comment:

Reference Range as per American Diabetes Association (ADA) 2023 Guidelines:

REFERENCE GROUP	HBA1C %
NON DIABETIC	<5.7
PREDIABETES	5.7 – 6.4
DIABETES	≥ 6.5
DIABETICS	
EXCELLENT CONTROL	6 – 7
FAIR TO GOOD CONTROL	7 – 8
UNSATISFACTORY CONTROL	8 – 10
POOR CONTROL	>10

Note: Dietary preparation or fasting is not required.

1. HbA1c is recommended by American Diabetes Association for Diagnosing Diabetes and monitoring Glycemic Control by American Diabetes Association guidelines 2023.

2. Trends in HbA1c values is a better indicator of Glycemic control than a single test.

3. Low HbA1c in Non-Diabetic patients are associated with Anemia (Iron Deficiency/Hemolytic), Liver Disorders, Chronic Kidney Disease. Clinical Correlation is advised in interpretation of low Values.

4. Falsely low HbA1c (below 4%) may be observed in patients with clinical conditions that shorten erythrocyte life span or decrease mean erythrocyte age. HbA1c may not accurately reflect glycemic control when clinical conditions that affect erythrocyte survival are present.

5. In cases of Interference of Hemoglobin variants in HbA1c, alternative methods (Fructosamine) estimation is recommended for Glycemic Control

A: HbF >25%

B: Homozygous Hemoglobinopathy.

(Hb Electrophoresis is recommended method for detection of Hemoglobinopathy)

Sneha Shah

Dr Sneha Shah
 MBBS, MD (Pathology)
 Consultant Pathologist

SIN No:CWA241100273

This test has been performed at Apollo Health and Lifestyle Ltd- Sadashiv Peth Pune, Diagnostics Lab



Patient Name : Mr.VIJAY DNYANDEO KORDE	Collected : 09/Nov/2024 10:44AM
Age/Gender : 39 Y 6 M 3 D/M	Received : 09/Nov/2024 05:26PM
UHID/MR No : CWAN.0000138549	Reported : 09/Nov/2024 07:33PM
Visit ID : CWANOPV243182	Status : Final Report
Ref Doctor : Self	Sponsor Name : ARCOFEMI HEALTHCARE LIMITED
Emp/Auth/TPA ID : 22S38196	

DEPARTMENT OF BIOCHEMISTRY

ARCOFEMI - MEDIWHEEL - FULL BODY ANNUAL PLUS MALE - 2D ECHO - PAN INDIA - FY2324

Test Name	Result	Unit	Bio. Ref. Interval	Method
LIPID PROFILE , SERUM				
TOTAL CHOLESTEROL	209	mg/dL	<200	CHO-POD
TRIGLYCERIDES	275	mg/dL	<150	GPO-POD
HDL CHOLESTEROL	41	mg/dL	40-60	Enzymatic Immunoinhibition
NON-HDL CHOLESTEROL	168	mg/dL	<130	Calculated
LDL CHOLESTEROL	113.14	mg/dL	<100	Calculated
VLDL CHOLESTEROL	54.91	mg/dL	<30	Calculated
CHOL / HDL RATIO	5.07		0-4.97	Calculated
ATHEROGENIC INDEX (AIP)	0.46		<0.11	Calculated

Comment:

Reference Interval as per National Cholesterol Education Program (NCEP) Adult Treatment Panel III Report.

	Desirable	Borderline High	High	Very High
TOTAL CHOLESTEROL	< 200	200 - 239	≥ 240	
TRIGLYCERIDES	<150	150 - 199	200 - 499	≥ 500
LDL	Optimal < 100 Near Optimal 100-129	130 - 159	160 - 189	≥ 190
HDL	≥ 60			
NON-HDL CHOLESTEROL	Optimal <130; Above Optimal 130-159	160-189	190-219	>220

Sneha Shah

 Dr Sneha Shah
 MBBS, MD (Pathology)
 Consultant Pathologist

SIN No:CWA241100274

This test has been performed at Apollo Health and Lifestyle Ltd- Sadashiv Peth Pune, Diagnostics Lab



Patient Name : Mr.VIJAY DNYANDEO KORDE	Collected : 09/Nov/2024 10:44AM
Age/Gender : 39 Y 6 M 3 D/M	Received : 09/Nov/2024 05:26PM
UHID/MR No : CWAN.0000138549	Reported : 09/Nov/2024 07:33PM
Visit ID : CWANOPV243182	Status : Final Report
Ref Doctor : Self	Sponsor Name : ARCOFEMI HEALTHCARE LIMITED
Emp/Auth/TPA ID : 22S38196	

DEPARTMENT OF BIOCHEMISTRY

ARCOFEMI - MEDIWHEEL - FULL BODY ANNUAL PLUS MALE - 2D ECHO - PAN INDIA - FY2324

Test Name	Result	Unit	Bio. Ref. Interval	Method
LIVER FUNCTION TEST (LFT) , SERUM				
BILIRUBIN, TOTAL	0.98	mg/dL	0.3-1.2	DPD
BILIRUBIN CONJUGATED (DIRECT)	0.15	mg/dL	<0.2	DPD
BILIRUBIN (INDIRECT)	0.83	mg/dL	0.0-1.1	Dual Wavelength
ALANINE AMINOTRANSFERASE (ALT/SGPT)	38.18	U/L	<50	IFCC
ASPARTATE AMINOTRANSFERASE (AST/SGOT)	26.7	U/L	<50	IFCC
AST (SGOT) / ALT (SGPT) RATIO (DE RITIS)	0.7		<1.15	Calculated
ALKALINE PHOSPHATASE	35.51	U/L	30-120	IFCC
PROTEIN, TOTAL	7.15	g/dL	6.6-8.3	Biuret
ALBUMIN	4.46	g/dL	3.5-5.2	BROMO CRESOL GREEN
GLOBULIN	2.69	g/dL	2.0-3.5	Calculated
A/G RATIO	1.66		0.9-2.0	Calculated

Comment:

LFT results reflect different aspects of the health of the liver, i.e., hepatocyte integrity (AST & ALT), synthesis and secretion of bile (Bilirubin, ALP), cholestasis (ALP, GGT), protein synthesis (Albumin) Common patterns seen:

1. Hepatocellular Injury:

*AST – Elevated levels can be seen. However, it is not specific to liver and can be raised in cardiac and skeletal injuries.*ALT – Elevated levels indicate hepatocellular damage. It is considered to be most specific lab test for hepatocellular injury. Values also correlate well with increasing BMI. Disproportionate increase in AST, ALT compared with ALP. AST: ALT (ratio) – In case of hepatocellular injury AST: ALT > 1 In Alcoholic Liver Disease AST: ALT usually >2. This ratio is also seen to be increased in NAFLD, Wilson’s diseases, Cirrhosis, but the increase is usually not >2.

2. Cholestatic Patten:*ALP – Disproportionate increase in ALP compared with AST, ALT. ALP elevation also seen in pregnancy, impacted by age and sex.*Bilirubin elevated- predominantly direct , To establish the hepatic origin correlation with elevated GGT helps.

3. Synthetic function impairment:*Albumin- Liver disease reduces albumin levels, Correlation with PT (Prothrombin Time) helps.

4. Associated tests for assessment of liver fibrosis - Fibrosis-4 and APRI Index.

Sneha Shah

Dr Sneha Shah
 MBBS, MD (Pathology)
 Consultant Pathologist

SIN No:CWA241100274

This test has been performed at Apollo Health and Lifestyle Ltd- Sadashiv Peth Pune, Diagnostics Lab




Patient Name : Mr.VIJAY DNYANDEO KORDE	Collected : 09/Nov/2024 10:44AM
Age/Gender : 39 Y 6 M 3 D/M	Received : 09/Nov/2024 05:26PM
UHID/MR No : CWAN.0000138549	Reported : 09/Nov/2024 07:33PM
Visit ID : CWANOPV243182	Status : Final Report
Ref Doctor : Self	Sponsor Name : ARCOFEMI HEALTHCARE LIMITED
Emp/Auth/TPA ID : 22S38196	

DEPARTMENT OF BIOCHEMISTRY

ARCOFEMI - MEDIWHEEL - FULL BODY ANNUAL PLUS MALE - 2D ECHO - PAN INDIA - FY2324

Test Name	Result	Unit	Bio. Ref. Interval	Method
GAMMA GLUTAMYL TRANSPEPTIDASE (GGT) , SERUM	26.40	U/L	<55	IFCC

Sneha Shah

Dr Sneha Shah
 MBBS, MD (Pathology)
 Consultant Pathologist
 SIN No:CWA241100274
 This test has been performed at Apollo Health and Lifestyle Ltd- Sadashiv Peth Pune, Diagnostics Lab



Patient Name : Mr.VIJAY DNYANDEO KORDE	Collected : 09/Nov/2024 10:44AM
Age/Gender : 39 Y 6 M 3 D/M	Received : 09/Nov/2024 04:27PM
UHID/MR No : CWAN.0000138549	Reported : 09/Nov/2024 05:24PM
Visit ID : CWANOPV243182	Status : Final Report
Ref Doctor : Self	Sponsor Name : ARCOFEMI HEALTHCARE LIMITED
Emp/Auth/TPA ID : 22S38196	

DEPARTMENT OF IMMUNOLOGY

ARCOFEMI - MEDIWHEEL - FULL BODY ANNUAL PLUS MALE - 2D ECHO - PAN INDIA - FY2324

Test Name	Result	Unit	Bio. Ref. Interval	Method
THYROID PROFILE TOTAL (T3, T4, TSH) , SERUM				
TRI-IODOTHYRONINE (T3, TOTAL)	1.34	ng/mL	0.7-2.04	CLIA
THYROXINE (T4, TOTAL)	11.78	µg/dL	5.48-14.28	CLIA
THYROID STIMULATING HORMONE (TSH)	0.603	µIU/mL	0.34-5.60	CLIA

Comment:

For pregnant females	Bio Ref Range for TSH in uIU/ml (As per American Thyroid Association)
First trimester	0.1 - 2.5
Second trimester	0.2 – 3.0
Third trimester	0.3 – 3.0

1. TSH is a glycoprotein hormone secreted by the anterior pituitary. TSH activates production of T3 (Triiodothyronine) and its prohormone T4 (Thyroxine). Increased blood level of T3 and T4 inhibit production of TSH.
2. TSH is elevated in primary hypothyroidism and will be low in primary hyperthyroidism. Elevated or low TSH in the context of normal free thyroxine is often referred to as sub-clinical hypo- or hyperthyroidism respectively.
3. Both T4 & T3 provides limited clinical information as both are highly bound to proteins in circulation and reflects mostly inactive hormone. Only a very small fraction of circulating hormone is free and biologically active.
4. Significant variations in TSH can occur with circadian rhythm, hormonal status, stress, sleep deprivation, medication & circulating antibodies.

TSH	T3	T4	FT4	Conditions
High	Low	Low	Low	Primary Hypothyroidism, Post Thyroidectomy, Chronic Autoimmune Thyroiditis
High	N	N	N	Subclinical Hypothyroidism, Autoimmune Thyroiditis, Insufficient Hormone Replacement Therapy.
N/Low	Low	Low	Low	Secondary and Tertiary Hypothyroidism
Low	High	High	High	Primary Hyperthyroidism, Goitre, Thyroiditis, Drug effects, Early Pregnancy
Low	N	N	N	Subclinical Hyperthyroidism
Low	Low	Low	Low	Central Hypothyroidism, Treatment with Hyperthyroidism
Low	N	High	High	Thyroiditis, Interfering Antibodies
N/Low	High	N	N	T3 Thyrotoxicosis, Non thyroidal causes

DR.Sanjay Ingle
M.B.B.S,M.D(Pathology)
Consultant Pathologist



SIN No:CWA241100277

This test has been performed at Apollo Health and Lifestyle Ltd- Sadashiv Peth Pune, Diagnostics Lab

Patient Name : Mr.VIJAY DNYANDEO KORDE	Collected : 09/Nov/2024 10:44AM
Age/Gender : 39 Y 6 M 3 D/M	Received : 09/Nov/2024 04:27PM
UHID/MR No : CWAN.0000138549	Reported : 09/Nov/2024 05:24PM
Visit ID : CWANOPV243182	Status : Final Report
Ref Doctor : Self	Sponsor Name : ARCOFEMI HEALTHCARE LIMITED
Emp/Auth/TPA ID : 22S38196	

DEPARTMENT OF IMMUNOLOGY

ARCOFEMI - MEDIWHEEL - FULL BODY ANNUAL PLUS MALE - 2D ECHO - PAN INDIA - FY2324

High	High	High	High	Pituitary Adenoma; TSHoma/Thyrotropinoma
------	------	------	------	--



DR.Sanjay Ingle
M.B.B.S,M.D(Pathology)
Consultant Pathologist

SIN No:CWA241100277

This test has been performed at Apollo Health and Lifestyle Ltd- Sadashiv Peth Pune, Diagnostics Lab



Patient Name : Mr.VIJAY DNYANDEO KORDE	Collected : 09/Nov/2024 10:44AM
Age/Gender : 39 Y 6 M 3 D/M	Received : 09/Nov/2024 04:39PM
UHID/MR No : CWAN.0000138549	Reported : 09/Nov/2024 05:18PM
Visit ID : CWANOPV243182	Status : Final Report
Ref Doctor : Self	Sponsor Name : ARCOFEMI HEALTHCARE LIMITED
Emp/Auth/TPA ID : 22S38196	

DEPARTMENT OF CLINICAL PATHOLOGY

ARCOFEMI - MEDIWHEEL - FULL BODY ANNUAL PLUS MALE - 2D ECHO - PAN INDIA - FY2324

Test Name	Result	Unit	Bio. Ref. Interval	Method
COMPLETE URINE EXAMINATION (CUE) , URINE				
PHYSICAL EXAMINATION				
COLOUR	YELLOW		PALE YELLOW	Scattering of light
TRANSPARENCY	CLEAR		CLEAR	Scattering of light
pH	5.5		5-7.5	Bromothymol Blue
SP. GRAVITY	1.018		1.002-1.030	Bromothymol Blue
BIOCHEMICAL EXAMINATION				
URINE PROTEIN	NEGATIVE		NEGATIVE	PROTEIN ERROR OF INDICATOR
GLUCOSE	POSITIVE++		NEGATIVE	GOD-POD
URINE BILIRUBIN	NEGATIVE		NEGATIVE	Diazonium Salt
URINE KETONES (RANDOM)	NEGATIVE		NEGATIVE	Sodium nitro prusside
UROBILINOGEN	NORMAL		NORMAL (0.1-1.8mg/dl)	Diazonium salt
NITRITE	NEGATIVE		NEGATIVE	Sulfanilic acid
LEUCOCYTE ESTERASE	NEGATIVE		NEGATIVE	Diazonium salt
CENTRIFUGED SEDIMENT WET MOUNT AND MICROSCOPY				
PUS CELLS	1 - 2	/hpf	0-5	Automated Image based microscopy
EPITHELIAL CELLS	0 - 1	/hpf	< 10	Automated Image based microscopy
RBC	0	/hpf	0-2	Automated Image based microscopy
CASTS	NEGATIVE	/lpf	0-2 Hyaline Cast	Automated Image based microscopy
CRYSTALS	NEGATIVE	/hpf	Occasional-Few	Automated Image based microscopy

Comment:

All urine samples are checked for adequacy and suitability before examination. All abnormal chemical examination are rechecked and verified by manual methods. Microscopy findings are reported as an average of 10 high power fields.

Sneha Shah
Dr Sneha Shah
 MBBS, MD (Pathology)
 Consultant Pathologist

SIN No:CWA241100278

This test has been performed at Apollo Health and Lifestyle Ltd- Sadashiv Peth Pune, Diagnostics Lab



Patient Name : Mr.VIJAY DNYANDEO KORDE	Collected : 09/Nov/2024 10:44AM
Age/Gender : 39 Y 6 M 3 D/M	Received : 09/Nov/2024 04:39PM
UHID/MR No : CWAN.0000138549	Reported : 09/Nov/2024 05:18PM
Visit ID : CWANOPV243182	Status : Final Report
Ref Doctor : Self	Sponsor Name : ARCOFEMI HEALTHCARE LIMITED
Emp/Auth/TPA ID : 22S38196	


DEPARTMENT OF CLINICAL PATHOLOGY

ARCOFEMI - MEDIWHEEL - FULL BODY ANNUAL PLUS MALE - 2D ECHO - PAN INDIA - FY2324

Test Name	Result	Unit	Bio. Ref. Interval	Method
URINE GLUCOSE(POST PRANDIAL)	POSITIVE +++		NEGATIVE	GOD-POD

Test Name	Result	Unit	Bio. Ref. Interval	Method
URINE GLUCOSE(FASTING)	POSITIVE +++		NEGATIVE	GOD-POD

*** End Of Report ***

Sneha Shah

Dr Sneha Shah
 MBBS, MD (Pathology)
 Consultant Pathologist

SIN No:CWA241100279

This test has been performed at Apollo Health and Lifestyle Ltd- Sadashiv Peth Pune, Diagnostics Lab



