

Patient Name : MR. BIKASH KUMAR SHIT
Age / Sex : 37Y 5M 25D/Male
IP/Reg.No/UHID : Reg-14261 /UHID14261
Lab No : LA24010350
Referred By : Dr.SAMANVAY HOSPITAL
Bedcategory/Bed :
Mobile No : 9178130971
UHID : UHID14261
Consultant : Mr. Samanvay Hospital
Sponsor : **MEDIWHEEL**
ABHA Address :
Barcode No. : **38039,38040,38041,38042**

Bill No : OPB/1/24/10974
Sample Collected : Nov 9 2024 9:40AM
Sample Received : Nov 9 2024 9:48AM
Report On : Nov 9 2024 11:44AM
Bill Creation Date : Nov 9 2024 9:10AM
Bar Code : 
Reg No : Reg-14261
IPNo :
Passport No. :
Verified On : **Nov 9 2024 12:05PM**
ABHA Num :

Test Name

Results

Units

Biological Reference

MICRO

URINE ANALYSIS

PHYSICAL EXAMINATION

VOLUME : 30 ML
COLOUR : PALE YELLOW
APPEARANCE : CLEAR

CHEMICAL EXAMINATION

PH : 6.5 : 4.5 - 8.0
SPECIFIC GRAVITY : 1.025 : 1.000 - 1.030
PROTEIN : Negative
GLUCOSE : Negative
KETONE : Negative
BLOOD : Negative
UROBILINOGEN : Negative
BILE PIGMENTS : Negative
BILE SALT : Negative
NITRITE : Negative
LEUKOCYTE ESTERASE : Negative

MICROSCOPIC EXAMINATION

PUS CELLS : 2--3 : CELLS/HPF 0 - 5
RBC : NIL : RBC'S/HPF 0 - 2
EPITHELIAL CELLS : 1--2 : OCC/HPF 0 - 5
CASTS : NIL
CRYSTALS : NIL

HPLC

HBA1C/ GLYOCO HB

GLYCOCYLATED HAEMOGLOBIN(HBA1C)(HPLC) : 4.6 : % 4.0 - 6.0



Mrs. Neena Ravi Patel

Dr. Sweta Patel
MD (Pathology)

Prepared by

Verified By

Patient Name : MR. BIKASH KUMAR SHIT
Age / Sex : 37Y 5M 25D/Male
IP/Reg.No/UHID : Reg-14261 /UHID14261
Lab No : LA24010350
Referred By : Dr.SAMANVAY HOSPITAL
Bedcategory/Bed :
Mobile No : 9178130971
UHID : UHID14261
Consultant : Mr. Samanvay Hospital
Sponsor : **MEDIWHEEL**
ABHA Address :
Barcode No. : **38039,38040,38041,38042**

Bill No : OPB/1/24/10974
Sample Collected : Nov 9 2024 9:40AM
Sample Received : Nov 9 2024 9:48AM
Report On : Nov 9 2024 11:44AM
Bill Creation Date : Nov 9 2024 9:10AM
Bar Code : 
Reg No : Reg-14261
IPNo :
Passport No. :
Verified On : **Nov 9 2024 12:05PM**
ABHA Num :

Test Name	Results	Units	Biological Reference
AVERAGE BLOOD SUGAR	85.32	mg/dl	0 - 140.0
BIOCHEMISTRY			
LIPID PROFILE			
CHOLESTROL (TOTAL)(CHOD-PAP)	170.0	mg/dl	0.0 - 200.0 Desirable blood cholesterol : <200 mg/dl Borderline high blood cholesterol : 200-239 mg/dl High blood cholesterol : >239 mg/dl
TRIGLYCERIDE(GPO-METHOD)	102.4	mg/dl	0 - 161.0 NORMAL : <161 MG/DL HIGH : 161-199 MG/DL HYPERTRIGLYCERIDEMIC : 200-499 MG/DL
HDL CHOLESTEROL(DIRECT METHOD)	40.4	mg/dl	35.3 - 79.5
CHOLESTROL (TOTAL)/HDL RATIO(CALCULATED)	4.21		3.30 - 4.40
VLDL	20.48		0 - 30.0
LDL CHOLESTEROL(CALCULATED)	129.6		0 - 130.0
LDL/HDL RATIO	3.21		
CREATININE (BLOOD)(ENZYMATIC)	0.87	mg/dl	0.7 - 1.3
BUN(UREASE-GLDH)	14.20	mg/dl	5.0 - 21.0
URIC ACID	5.1	mg/dl	3.5 - 7.2
BUN CREATININE RATIO(CALCULATED)	16.32	mg/dl	10.0 - 20
UREA(UREASE-GLDH)	30.4	mg/dl	21.0 - 43.0
LIVER FUNCTION TEST			
BILIRUBIN-TOTAL(DIAZO)	0.60	mg/dl	0.00 - 2.0
BILIRUBIN-DIRECT(DIAZO)	0.29	mg/dl	0.00 - 0.4
BILIRUBIN-INDIRECT(DIAZO)	0.31	mg/dl	0.00 - 1.10

Mrs. Neena Ravi Patel

Prepared by



Dr. Sweta Patel
MD (Pathology)

Verified By

Patient Name : MR. BIKASH KUMAR SHIT
Age / Sex : 37Y 5M 25D/Male
IP/Reg.No/UHID : Reg-14261 /UHID14261
Lab No : LA24010350
Referred By : Dr.SAMANVAY HOSPITAL
Bedcategory/Bed :
Mobile No : 9178130971
UHID : UHID14261
Consultant : Mr. Samanvay Hospital
Sponsor : **MEDIWHEEL**
ABHA Address :
Barcode No. : **38039,38040,38041,38042**

Bill No : OPB/1/24/10974
Sample Collected : Nov 9 2024 9:40AM
Sample Received : Nov 9 2024 9:48AM
Report On : Nov 9 2024 11:44AM
Bill Creation Date : Nov 9 2024 9:10AM
Bar Code : 
Reg No : Reg-14261
IPNo :
Passport No. :
Verified On : **Nov 9 2024 12:05PM**
ABHA Num :

Test Name	Results	Units	Biological Reference
-----------	---------	-------	----------------------

SGOT(IFCC WITHOUT PYRIDOXAL PHOSPHATE)	22.0	U/L	0 - 35
SGPT(IFCC WITHOUT PYRIDOXAL PHOSPHATE)	13.5	U/mL	0 - 45
ALKALINE PHOSPHATASE(ALKP04)* (AMP-METHOD)	70.0	U/L	53 - 128
PROTEIN (SERUM)(BIURET)	6.68	g/dl	6.4 - 8.3
ALBUMIN(BCG)	4.39	g/dl	3.5 - 5.2
GLOBULIN(CALCULATED)	↓ 2.29	g/dl	2.3 - 3.7
A/G RATIO(CALCULATED)	1.92	Ratio	1.0 - 2.0
GAMMA GT(GLUPA C METHOD)	30.5	U/L	0.0 - 58.0

IMMUNOLOGY

T3 T4 TSH

TOTAL T3(CHEMILUMINESCENCE / CLIA)	1.01	ng/ml	0.19 - 6.51
TOTAL T4(CHEMILUMINESCENCE / CLIA)	5.36	ug/dl	4.5 - 12.7
TSH(CHEMILUMINESCENCE / CLIA)	↑ 6.78	μIU/mL	0.35 - 4.78

Interpretation :

1. TSH results between 4.5 to 15.0 show considerable physiologic and seasonal variation, suggest clinical correlation or repeat testing with fresh sample.
- 2.TSH results between 0.1 to 0.45 requires correlation with patient age and clinical symptoms. As with increasing age, there are marked changes in thyroid hormone production, metabolism and its action resulting in an increase prevalence of sub-clinical thyroid disease.
3. TSH values may be transiently altered because of non- thyroidal illness like severe infections, liver diseases, renal and heart failure, severe burns, trauma and surgery etc.
- 4.Drugs that decreased TSH values e.g. L-dopa, glucocorticoid. Drugs that increase TSH values e.g .Iodine, Lithium and amiodarone.

BIOCHEMISTRY

FASTING BLOOD GLUCOSE*

FASTING BLOOD GLUCOSE(FBS)(GOD-POD)	94.6	mg/dl	74.0 - 100.0
FASTING URINE GLUCOSE	NIL		

HEMATOLOGY

BLOOD GROUP RH "AB" POSITIVE

CBC WITH ESR



Dr. Sweta Patel
MD (Pathology)
Verified By

Mrs. Neena Ravi Patel

Prepared by

Nr. St. Kabir School, Opp. Raneshwar Temple, Vasna Road, Vadodara-15

Patient Name : MR. BIKASH KUMAR SHIT
Age / Sex : 37Y 5M 25D/Male
IP/Reg.No/UHID : Reg-14261 /UHID14261
Lab No : LA24010350
Referred By : Dr.SAMANVAY HOSPITAL
Bedcategory/Bed :
Mobile No : 9178130971
UHID : UHID14261
Consultant : Mr. Samanvay Hospital
Sponsor : **MEDIWHEEL**
ABHA Address :
Barcode No. : **38039,38040,38041,38042**

Bill No : OPB/1/24/10974
Sample Collected : Nov 9 2024 9:40AM
Sample Received : Nov 9 2024 9:48AM
Report On : Nov 9 2024 11:44AM
Bill Creation Date : Nov 9 2024 9:10AM
Bar Code : 
Reg No : Reg-14261
IPNo :
Passport No. :
Verified On : **Nov 9 2024 12:05PM**
ABHA Num :

Test Name	Results	Units	Biological Reference
RBCS PARAMETER			
HAEMOGLOBIN(SLS METHOD)	↓ 11.8	g/dl	13.0 - 17.0
RBC COUNT(IMPEDENCE)	↓ 4.11	10 ⁶ /uL	4.50 - 5.50
PCV (HEAMATOCRIT)(IMPEDENCE)	↓ 35.9	%	40.0 - 50.0
MCV(CALCULATED)	87.3	fl	80.0 - 100.0
MCH(CALCULATED)	28.7	pg	27.0 - 33.0
MCHC(CALCULATED)	32.9	g/dl	32.0 - 36.0
RDW-CV(PARTICLE COUNTER(CALCULATED))	13.8	%	11.6 - 14.0
RDW-SD(PARTICLE COUNTER(CALCULATED))	44.1	fl	39 - 46
WBCS PARAMETER			
TOTAL COUNT(FLOW CYTOMETRY)	4730	/uL	4000 - 10000
DLC			
NEUTROPHILS(FLOW CYTOMETRY)	54	%	40 - 70
LYMPHOCYTES(FLOW CYTOMETRY)	36	%	20 - 40
MONOCYTES(FLOW CYTOMETRY)	06	%	2 - 8
EOSINOPHILS(FLOW CYTOMETRY)	04	%	1 - 4
BASOPHILS(FLOW CYTOMETRY)	00	%	0.0 - 1.0
ABSOLUTE NEUTROPHIL COUNT(CALCULATED)	2520.0	10 ³ /uL	2000.0 - 7000.0
ABSOLUTE LYMPHOCYTE COUNT(CALCULATED)	1720.0	10 ³ /uL	1000.0 - 3000.0
ABSOLUTE MONOCYTE COUNT(CALCULATED)	260.0	10 ³ /uL	200.0 - 1000.0
ABSOLUTE EOSINOPHIL COUNT(CALCULATED)	210.0	10 ³ /uL	20.0 - 500.0
PLATELETS PARAMETER			
PLATELET COUNT(IMPEDENCE)	↓ 129000	/uL	150000 - 450000
ESR	12	mm/hr	0 - 20

-----End of the Report-----

Mrs. Neena Ravi Patel

Prepared by



Dr. Sweta Patel
MD (Pathology)

Verified By

Nr. St. Kabir School, Opp. Raneshwar Temple, Vasna Road, Vadodara-15

2D ECHOCARDIOGRAPHY AND COLOUR DOPPLER STUDY

NAME : MR.SHIT BIKASHKUMAR

DATE : 09-11-24

AGE/SEX : 37 YRS / M WARD: HCP REF BY : SAMANVAY HOSPITAL

OBSERVATION:

- NORMAL LV SIZE WITH NORMAL LV SYSTOLIC FUNCTION
- LVEF 60%, NO RWMA AT REST
- E/O NORMAL LV DIASTOLIC DYSFUNCTION, NORMAL LA SIZE
- AORTIC VALVE, NO AR, NO AS
- MITRAL VALVE, TRIVIAL MR, NO MS
- TRIVIAL TR, NO PAH, RVSP 25 MMHG
- NORMAL SIZED RA, RV WITH NORMAL RV FUNCTION
- PULMONARY VALVE- NO PR, NO PS, NORMAL SIZED PA & ITS BRANCHES
- IAS, IVS ARE INTACT
- NO INTRACARDIAC CLOT, VEGETATION
- PERICARDIUM NORMAL, NO PERICARDIAL EFFUSION
- IVC NORMAL IN SIZE (15 MM) AND >50% COLLAPSING

MEASUREMENTS:

M MODE: AORTA: 20 MM LA: 27 MM LV DD/DS: 46/29 MM IVS/PW: 10/10 MM
DOPPLER: MV RATIO E/A: 0.8/0.4 M/S AV VMAX: 1.1 M/S PV VMAX: 0.5 M/S

CONCLUSION:

NORMAL LV SIZE AND LV SYSTOLIC FUNCTION

LVEF 60%, NO RWMA AT REST

TRIVIAL MR, TRIVIAL TR, NO PAH

E/O NORMAL LV DIASTOLIC DYSFUNCTION



DR. PAVAN ROY
MD, DM (CARDIOLOGY)
CONSULTANT INTERVENTIONAL CARDIOLOGIST
G-23390
M. No. 938598158

bikash
shit
.....
37 years
..... cm / kg

HR 76/min
P 73 *
QRS 78 *
T 67 *

5.79

Intervals:
RR 789 ms
P 98 ms
PR 116 ms
QRS 92 ms
QT 358 ms
QTc 487 ms

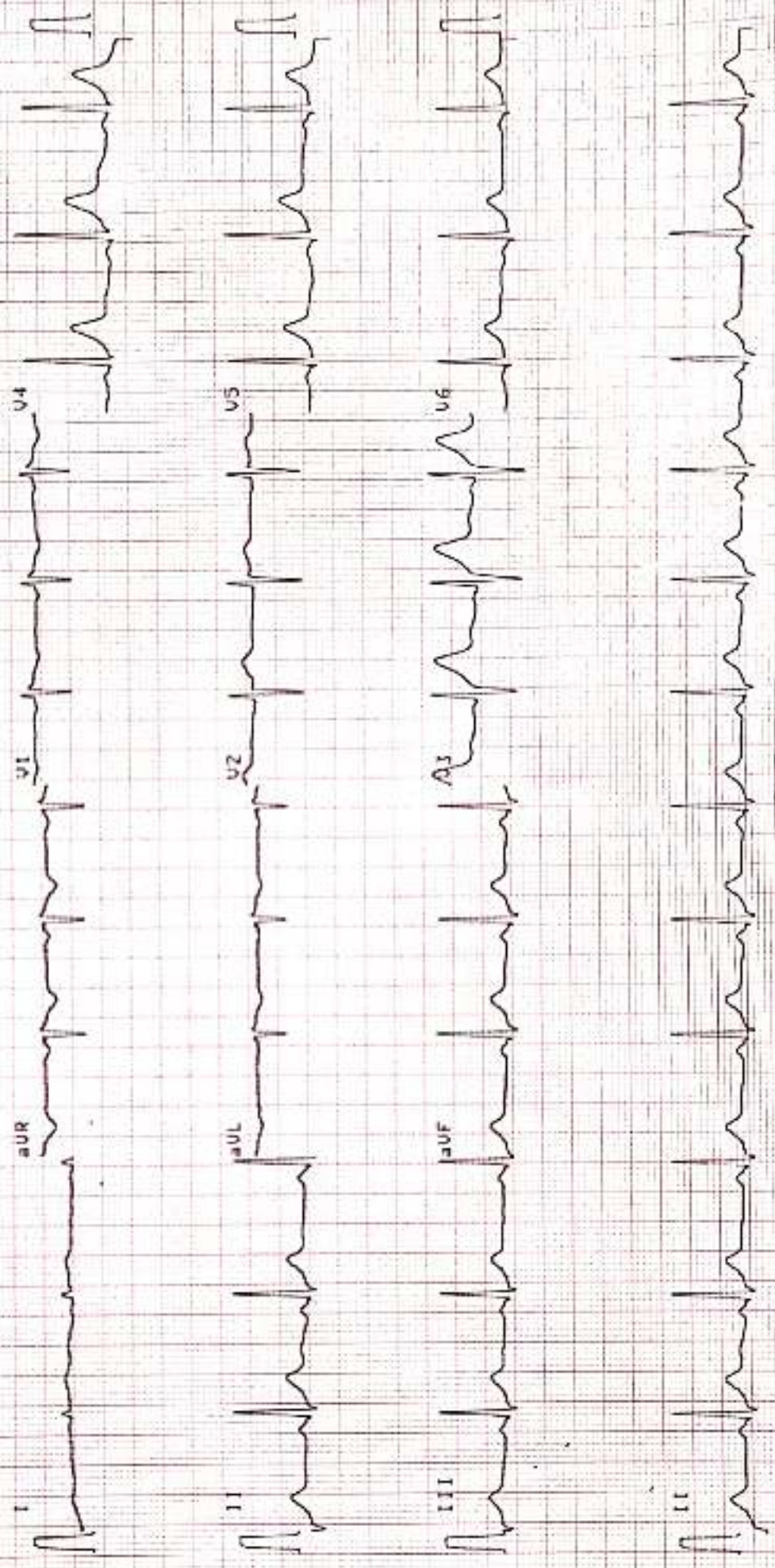
DR. PAVAN ROY
MD, DM (CARDIOLOGY)
CONSULTANT-CARDIOLOGIST
REG. NO. G-23399
M No. 9305000164

UNCONFIRMED REPORT



12 mm/mV

12 mm/mV



12 mm/mV

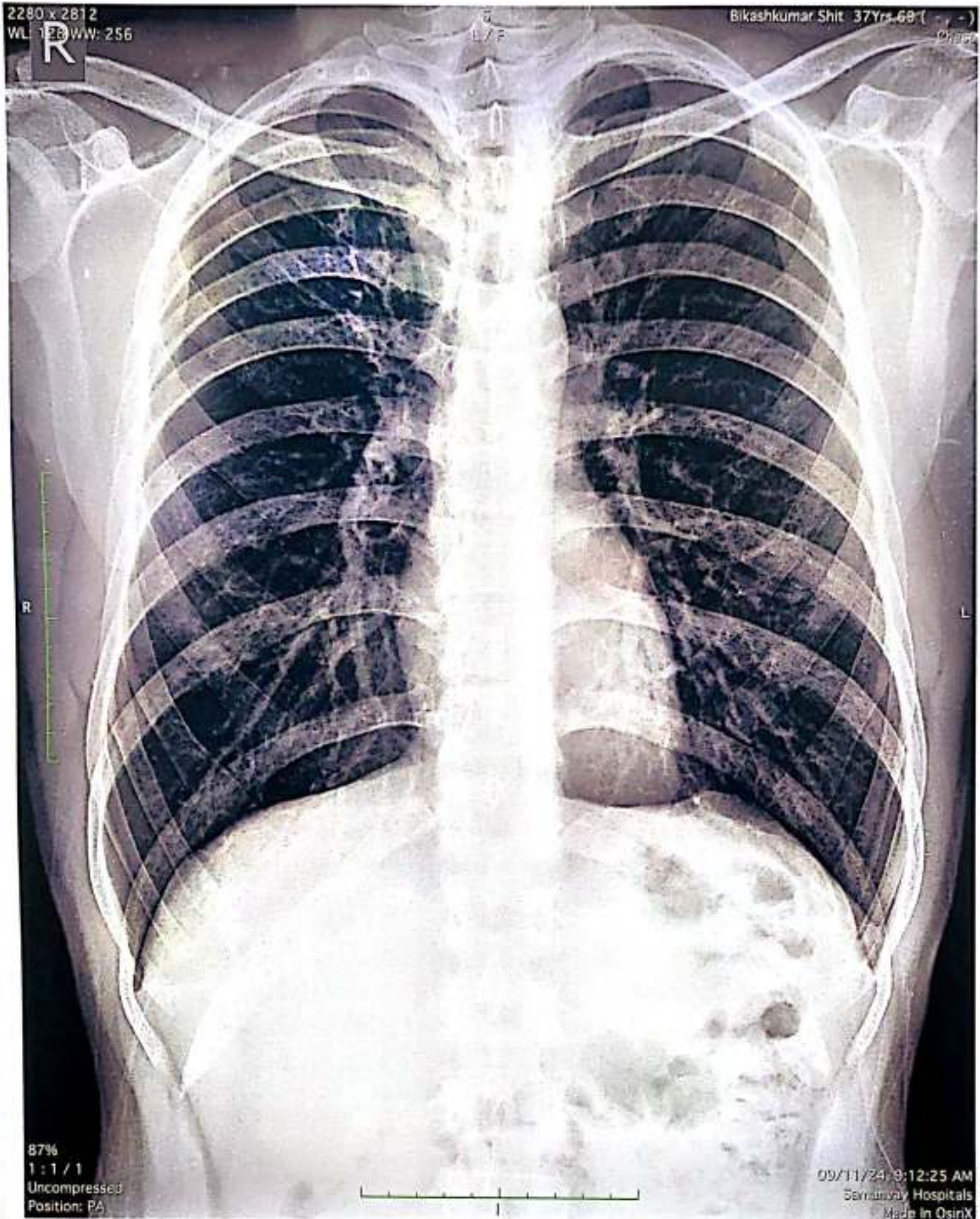Bikashkumar Shit

M/37-y

09-11-26

2280 x 2812
WL: 128 WW: 256

Bikashkumar Shit 37Yrs-69 (-)



R

87%
1:1 / 1
Uncompressed
Position: PA

09/11/24 9:12:25 AM
Samarth Hospitals
Made in OsiriX

BIKASH KUMAR SHIT

M / 37 YEARS

DATE: 09/11/2024

REAL TIME SONOGRAPHY OF THE ABDOMEN & PELVIS

LIVER - It is normal in size (13.2 cm). It shows normal echo pattern. No evidence of solid or cystic focal lesion is seen. The intrahepatic biliary system is normal and shows no dilatation of the radicles. The portal vein, CBD and hepatic veins appear normal.

GALL BLADDER - It is distended and appears normal. No evidence of sludge or calculus is seen. The wall appears normal.

PANCREAS - It is visualized and appears normal.

SPLEEN - It appears normal in size (9.3 cm), normal in shape and echotexture. No focal lesions.

KIDNEYS - . Both the kidneys appear normal in size, shape and show normal corticomedullary differentiation. Normal echogenicity of both kidneys.

Right kidney measures 8.4 X 3.8 cm. Left kidney measures 8.7 X 5.0 cm.

No calculus or hydronephrosis is seen on either side.

Urinary bladder is distended and appears normal. No cystitis or mass lesion noted.

Prostate appears normal in size vol - 10 cc. No focal lesion.

No evidence of any lymphadenopathy or ascites is noted.

No evidence of dilated bowel loops or bowel wall thickening noted.

IMPRESSION:

NO SONOGRAPHIC ABNORMALITY IS DETECTED.



DR. SARJAN VASAVA,
CONSULTANT RADIOLOGIST.

JR SARJAN VASAVA
M.B.B.S., D.M.R.D.
Reg. No. G-26527
SAMANVAY HOSPITALS

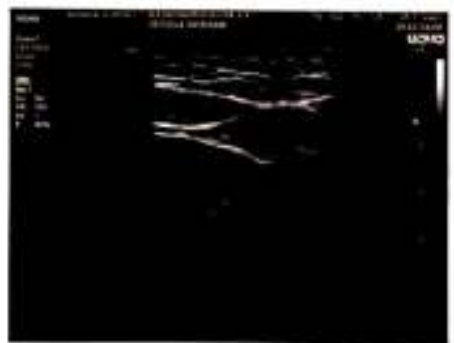
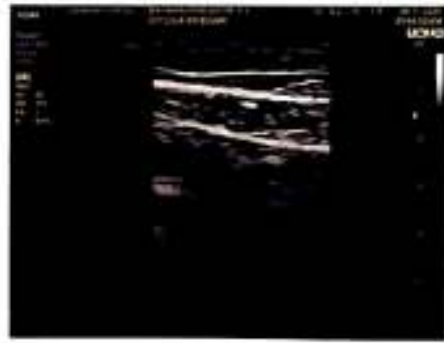
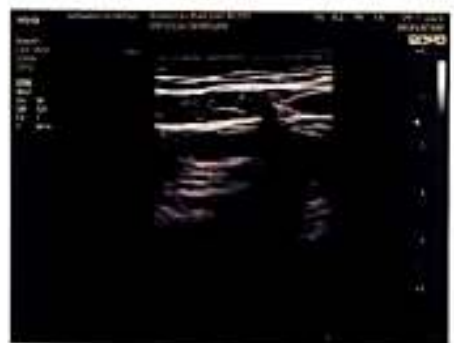
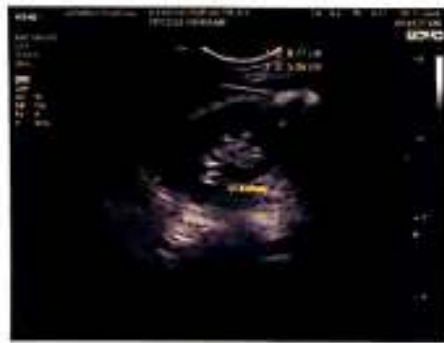
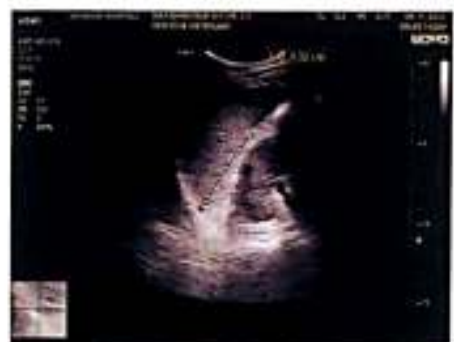
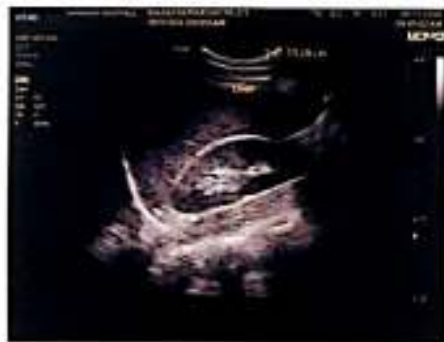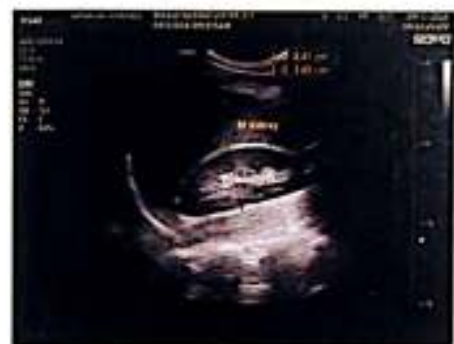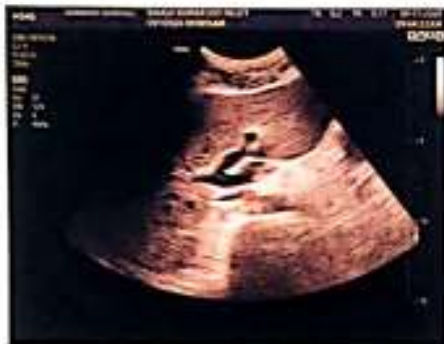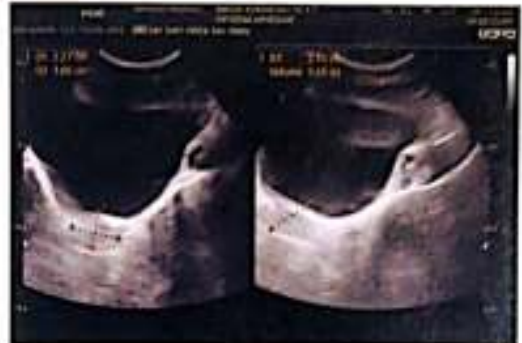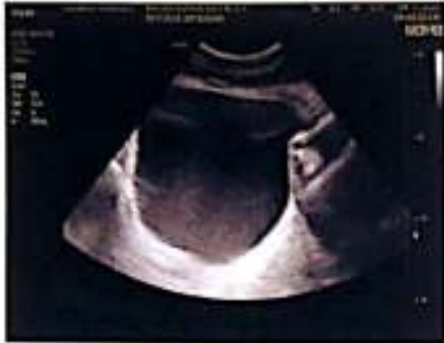Patient

ID 09112024-091855AM
Name BIKASH KUMAR SHIT M/37Y
Birth Date
Gender

Exam

Accession #
Exam Date 09-11-2024
Description
Operator



Patient Name : MR. BIKASH KUMAR SHIT
Age & Sex : 37Y 5M 25D /M
Bill date : 09/11/2024 12:37 PM

Bill No. : OPB/1/24/10974
Reg No. : REG-14261
Sponsor : MEDIWHEEL

X-RAY CHEST PA

Both the lung fields appear normal.
Both costophrenic angles appear clear.
Cardiac silhouette appear normal.
Both hila appears normal.
Mediastinum and aorta appear normal.
Bony thorax appears normal.
No evidence of free gas seen under dome of diaphragm.

COMMENTS:

- **NORMAL BOTH LUNG FIELDS.**
- **NORMAL CARDIAC SIZE.**

Impression :
Conclusion :



Dr. Sarjan Vasava

Radiology

(Reg No-G-26527)

DR SARJAN VASAVA
M.B.S.S., D.M.R.D.
Reg. No. G-26527
SAMANVAY HOSPITALS



EYE CHECK UP

Pt. No.: MR. Shil-Kumar Date: 9/11/24

Name: _____ Age / Sex: _____

	RIGHT EYE	LEFT EYE
DISTANCE : (With / Without Glasses)	6/6	6/6
NEAR VISION : (With / Without Glasses)	N.G	N.G
ANTERIOR SEGMENT :	wnel	wnel
IOP (MM of Hg)	14.0	14.0
FUNDUS :	wnel	wnel
COLOR VISION :	wnel	wnel
CLINICAL IMPRESSION :	—	
ADVICE :	—	

Doctor's Signature : _____



□

COMPREHENSIVE HEALTH CHECK UP

Case No. : # 14261 Date : 9-11-2024

Name : Mr. Bikesh Shit Age/Sex : 37y/M.

MEDICAL HISTORY : Pinio Cancerer Ast could fatigue

PERSONAL HISTORY : _____

Appetite : _____ Smoking : _____

Sleep : _____ H/O Alcohol : _____

Bladder : _____ Lifestyle : _____

Bowel : _____ Exercise : _____

DRUG HISTORY : _____

PAST HISTORY : _____

FAMILY HISTORY : _____

GENERAL PHYSICAL EXAMINATION :

Built and Nourishment :

Height : 162 cm SpO₂ :- 99%

B. P. : 100/70 mm of Hg Weight : 52.6 Kg

Character : _____ Pulse : 78 /Min

Nails : _____ Odema : _____

Tonsils : _____ Skin : _____

Tongue : _____ Sclera : _____

Eat. & Joints : _____ Glands : _____

- ↑ O₂ SH
- Mild thalocystopenia
- ? Constitutional



Adv _____
(20) d } - Tb. Nyrokind-LC
0110

Dental



MR. Bikashkumar shir - 37/M 9-11-2024

o/p : Bleeding on brushing teeth .

o/E : 1) Ch. gene. gingivitis .
2) Stains ++

Adv : 1) Scaling .

