



PANACEA HOSPITAL

B 36/44 F.K KABIR NAGAR, DURGAKUND
TOLLFREE NO-18001233070. Whatsapp No - 8795832852
www.piire.org
panaceaquery@gmail.com|panceahospitalit@gmail.com



OP Slip

Print Date : 18-Mar-2024 09:21AM



UHID No :- UD-23240006917	OP No :- OP-23240021225	OP Date :- 18 Mar 2024 9:20AM
Patient Name :- Mr ROHIT KUMAR	Age/Sex :- 39 Y/Male	Mobile No :- 7355463929
Father :- GAURI SHANKAR THAKUR	Department :- GENERAL MEDICINE	
Pay Type :- Cash	Consultant :- Dr Pallavi Mishra (MBBS,MD,MBBS)	
Token No :- NOR. - 1	Paid/Bal :- 0.00 /30.00	
Patient Type :- Normal		
Address :- THANA TAJPUR MORWA BAZAR BAZAR MORWA SAMASTIPUR - 848121,BIHAR		

BP :- 130/90
 height :- 171
 Weight (kg) :- 73.8
 BMI :-

Rx

NC - 36
 CH - 92
 WC - 98
 SpO2 - 99
 PR - 67
 PEFr - 350

Tab. Telmis 20mg 1 tab
 Dil Cosk (10mg) 1 tab
 Tab. Ezolite plus 1 tab

[Signature]
 DR. Pallavi Misra
 MBBS, MD(GENERAL MEDICINE)
 MCI Reg. No.52033

Printed By : Ms. Renuka
 Created By : Ms. Renuka



PANACEA HOSPITAL

B 36/44 F.K KABIR NAGAR, DURGAKUND
TOLLFREE NO-18001233070. Whatsapp No - 8795832852
www.piire.org
panaceaquery@gmail.com|panceahospitalit@gmail.com



OP Slip

Print Date : 18-Mar-2024 09:21AM



UHID No :- UD-23240006917	OP No :- OP-23240021225	OP Date :- 18 Mar 2024 9:20AM
Patient Name :- Mr ROHIT KUMAR	Age/Sex :- 39 Y/Male	Mobile No :- 7355463929
Father :- GAURI SHANKAR THAKUR	Department :- DERMATOLOGY	
Pay Type :- Cash	Consultant :- Dr DR ASHUTOSH MISHRA (MBBS,MD)	
Token No :- NOR. - 1	Paid/Bal :- 0.00 /30.00	
Patient Type :- Normal		
Address :- THANA TAJPUR MORWA BAZAR BAZAR MORWA SAMASTIPUR - 848121,BIHAR		

BP :-
height :-
Weight (kg) :-
BMI :-

Rx

APC

Rx

- clotted ear wax C!
- Neem soap
- Bilach 20g tabs B.D C. x 10 days
- Can and clean ev → 20 (face)

10 days



Printed By : Ms. Renuka
Created By : Ms. Renuka



PANACEA HOSPITAL

B 36/44 F.K KABIR NAGAR, DURGAKUND
TOLLFREE NO-18001233070. Whatsapp No - 8795832852
www.piire.org
panaceaquery@gmail.com|panceahospitalit@gmail.com



OP Slip

Print Date : 18-Mar-2024 09:20AM



UHID No :- UD-23240006917 **OP No** :- OP-23240021225 **OP Date** :- 18 Mar 2024 9:20AM
Patient Name :- Mr ROHIT KUMAR **Age/Sex** :- 39 Y/Male **Mobile No** :- 7355463929
Father :- GAURI SHANKAR THAKUR **Department** :- DENTAL
Pay Type :- Cash **Consultant** :- Dr SHRUTI MISHRA (AA)
Token No :- NOR. - 1 **Paid/Bal** :- 0.00 /30.00
Patient Type :- Normal
Address :- THANA TAJPUR MORWA BAZAR BAZAR MORWA SAMASTIPUR - 848121, BIHAR

BP :-
height :-
Weight (kg) :-
BMI :-

R_x c/c - patient came for routine dental checkup.
o/c - stains / calculus ++
proximal cavities ++
r/c - required scaling & polishing

shruti
Dr. SHRUTI MISHRA
BDS, (DENTIST)
MCI Reg. No. (A-09784)

Printed By : Ms. Renuka
Created By : Ms. Renuka



PANACEA HOSPITAL

B 36/44 F.K KABIR NAGAR, DURGAKUND
TOLLFREE NO-18001233070. Whatsapp No - 8795832852
www.piire.org
panaceaquery@gmail.com|panceahospitalit@gmail.com



OP Slip

Print Date : 18-Mar-2024 09:22AM



UHID No	:- UD-23240006917	OP No	:- OP-23240021225	OP Date	:- 18 Mar 2024 9:20AM
Patient Name	:- Mr ROHIT KUMAR	Age/Sex	:- 39 Y/Male	Mobile No	:- 7355463929
Father	:- GAURI SHANKAR THAKUR	Department	:- OPHTHALMOLOGY		
Pay Type	:- Cash	Consultant	:- Dr Santosh Verma (MBBS,MS)		
Token No	:- NOR. - 1	Paid/Bal	:- 0.00 /30.00		
Patient Type	:- Normal				
Address	:- THANA TAJPUR MORWA BAZAR BAZAR MORWA SAMASTIPUR - 848121,BIHAR				

BP :-
height :-
Weight (kg) :-
BMI :-

Rx

VA { 6/9 --- NI ✕
6/12' --- 6/6' ✕

Near { NG ✕
NG ✕

of BLE

1. G. Lubstone ultra - QID
oooo

Printed By : Ms. Renuka
Created By : Ms. Renuka

Dr. SANTOSH VERMA
MBBS, MS (Ophthalmologist)
MCI Reg. No. 09-3477

Facilities:

All clinical Biomedical & Hematology Investigations including Bone Marrow Examination
VPT, Podiascan & Complete Foot Care (First Time in Purvanchal)
All Hormonal Investigation by Chemiluminescent Method
Visceral Fat by (AB-140) Ambulatory BP Monitoring
CGMS & Insulin Pump Available
PFT, 2D-ECHO (Color Doppler), Holter, TMT, Cardiac-3 available
VIA, VILI, Colposcopy available
Special Endocrinological Investigation Protocols.

ISO 9001:2008 Certified
Mobile: 9389994334, 9554572190, 9453837595



Panacea Pathology

Clinical Reference Lab

Persistence, Preparedness and Precision
EQAS (CMC Vellore Attached) & IQAS System
पूर्वाचल की सर्वोत्तम गुणवत्ता वाली पैथोलॉजी

UHID No :- UD-23240006917 **Booking No/Date** :- 48 / 18-Mar-2024 12:53 PM
Patient Name :- Mr ROHIT KUMAR **Age/Sex** :- 39 Y/M
Father :- GAURI SHANKAR THAKUR **OP No** :- OP-23240021225
Address :- THANA TAJPUR MORWA BAZAR BAZAR MORWA SAMASTIPUR - 848121 , BIHAR **Mobile No** :- 7355463929
Consultant :- Dr Santosh Verma (MBBS)

Investigations	Observations	Biological Ref. Interval	Unit
HAEMATOLOGY			
CBC			
HAEMOGLOBIN <small>DefaultMethod / test Machine</small>	14.1	13.00 - 16.00	gm/dl
TLC <small>Methology / Carm</small>	6,500	4000.00 - 11000.00	Cells/cumm.
DLC DIFFERENTIAL LEUCOCYTE COUNT			
NEUTROPHILS	58	40.00 - 75.00	%
LYMPHOCYTES	34	20.00 - 45.00	%
EOSINOPHILS	03	1.00 - 6.00	%
MONOCYTES	05	2.00 - 10.00	%
BASOPHILS	00	<1-2	%
PLATELET COUNT	2.05	1.50 - 4.10	lacs /cumm
PCV	44.9	33.00 - 42.00	%
RBC <small>Methology / Carm</small>	4.86	4.50 - 5.50	million/cumm
MCV(MEAN CELL VOLUME)	92.4	83.00 - 101.00	fl
MCH(MEAN CELL HAEMOGLOBIN)	29.1	27.00 - 32.00	pg
MCHC	31.5	31.50 - 35.00	gm%
RDW-CV	12.8	11.00 - 16.00	%
RDW-SD	48.1	37.00 - 57.00	fl

Consulting Pathologist

Dr. Umesh Kumar
DR. UMESH KUMAR
MBBS, MD (PATHOLOGIST)

MCI Reg. No. 41413

Lab Technician

Timing : 24/7 hrs

This Report is not valid for medico legal purpose

Note: These tests have technical limitations. Clinico-pathological interpretation is necessary. In case of any disparity test may be repeated immediately.

Address : 36/44 FK Kabir Nagar, Durgakund, Varanasi – 221005

Email: dramishra@gmail.com, drpallaviojha@gmail.com Website: panaceahospital.org

Facilities:

All clinical Biomedical & Hematology Investigations including Bone Marrow Examination
VPT, Podiascan & Complete Foot Care (First Time in Purvanchal)
All Hormonal Investigation by Chemiluminescent Method
Visceral Fat by (AB-140) Ambulatory BP Monitoring
CGMS & Insulin Pump Available
PFT, 2D-ECHO (Color Doppler), Holter, TMT, Cardiac-3 available
VIA, VILI, Colposcopy available
Special Endocrinological Investigation Protocols.

ISO 9001:2008 Certified
Mobile: 9389994334, 9554572190, 9453837595



Panacea Pathology

Clinical Reference Lab

Persistence, Preparedness and Precision
EQAS (CMC Vellore Attached) & IQAS System
पूर्वांचल की सर्वोत्तम गुणवत्ता वाली पैथोलॉजी

UHID No	:- UD-23240006917	Booking No/Date	:- 48 / 18-Mar-2024 12:53 PM
Patient Name	:- Mr ROHIT KUMAR	Age/Sex	:- 39 Y/M
Father	:- GAURI SHANKAR THAKUR	OP No	:- OP-23240021225
Address	:- THANA TAJPUR MORWA BAZAR BAZAR MORWA SAMASTIPUR - 848121 , BIHAR	Mobile No	:- 7355463929
Consultant	:- Dr Santosh Verma (MBBS)		

Investigations

Observations

Biological Ref. Interval

Unit

URINE EXAMINATION

URINE ROUTINE EXAMINATION

PHYSICAL EXAMINATION

QUANTITY	25		ml
COLOR <i>Methology</i>	STARW	CLEAR YELLOW	
APPEARANCE <i>DefaultMethod</i>	CLEAR	CLEAR	

CHEMICAL EXAMINATION

SPECIFIC GRAVITY	1.020	1.01 - 1.03	
PH	5.5	4.60 - 8.00	
GLUCOSE	NIL	60.00 - 100.00	mg/dl
PROTEIN-	NIL		

MICROSCOPIC EXAMINATION

PUS CELLS	01-02	2.00 - 3.00	/HPF
RBCS (RED BLOOD CELLS)	NIL	4.50 - 5.50	/HPF
EPITHELIAL CELLS	NIL		/HPF
CASTS	ABSENT	ABSENT	
CRYSTALS	ABSENT	ABSENT	


Consulting Pathologist

DR. UMESH KUMAR
MBBS (MD) (PATHOLOGIST)
MCI Reg. No. 41413

Lab Technician

Timing : 24/7 hrs

This Report is not valid for medico legal purpose

Note: These tests have technical limitations. Clinico-pathological interpretation is necessary. In case of any disparity test may be repeated immediately.

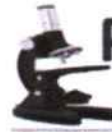Address : 36/44 FK Kabir Nagar, Durgakund, Varanasi – 221005

Email: dramishra@gmail.com, drpallaviojha@gmail.com Website: panaceahospital.org

Facilities:

All clinical Biomedical & Hematology Investigations including Bone Marrow Examination
VPT, Podiascan & Complete Foot Care (First Time in Purvanchal)
All Hormonal Investigation by Chemiluminescent Method
Visceral Fat by (AB-140) Ambulatory BP Monitoring
CGMS & Insulin Pump Available
PFT, 2D-ECHO (Color Doppler), Holter, TMT, Cardiac-3 available
VIA, VILI, Colposcopy available
Special Endocrinological Investigation Protocols.

ISO 9001:2008 Certified
Mobile: 9389994334, 9554572190, 9453837595



Panacea Pathology

Clinical Reference Lab

Persistence, Preparedness and Precision
EQAS (CMC Vellore Attached) & IQAS System
पूर्वांचल की सर्वोत्तम गुणवत्ता वाली पैथोलॉजी

UHID No	:- UD-23240006917	Booking No/Date	:- 48 / 18-Mar-2024 12:53 PM
Patient Name	:- Mr ROHIT KUMAR	Age/Sex	:- 39 Y/M
Father	:- GAURI SHANKAR THAKUR	OP No	:- OP-23240021225
Address	:- THANA TAJPUR MORWA BAZAR BAZAR MORWA SAMASTIPUR - 848121 , BIHAR	Mobile No	:- 7355463929
Consultant	:- Dr Santosh Verma (MBBS)		

Investigations	Observations	Biological Ref. Interval	Unit
----------------	--------------	--------------------------	------

HAEMATOLOGY

ESR	10.0	0.00 - 15.00	mm at 1 hr
BLOOD GROUP ABO & RH FACTOR			
BLOOD GROUP	"O"		
RH FACTOR	POSITIVE		
HBA1C -(BY GOLD STANDARD METHOD :HPLC)	6.2	Normal: 4.0 - 5.4 Prediabetic : 5.5 -6.3 Diabetes mellitus := 6.4	%

BIOCHEMISTRY

LIPID PROFILE

TOTAL CHOLESTROL	156.0	Desirable : - < 200 mg/dL Borderline: - 200 - 239 mg/dL High : - > 240mg/dL	mg/dl
TRIGLYCERIDES	148.0	35.00 - 160.00	mg/dl
HDL CHOLESTROL	41.0	35.30 - 79.50	mg/dl
LDL CHOLESTROL	85.4	<130	mg/dl
VLDL	29.60	<40	mg/dl
CHOLESTROL/ HDL RATIO	3.80	<3.0 LOW RISK, 3.0-5.0 AVG RISK, >5.0 HIGH RISK	ratio
LDL/HDL RATIO	2.08	<3	ratio

LFT (LIVER FUNCTION TESTS)

Lab Technician

Consulting Pathologist

DR. UMESH KUMAR
MBBS, M.D. (PATHOLOGY)
MCI Reg. No. 41413

Timing : 24/7 hrs

This Report is not valid for medico legal purpose

Note: These tests have technical limitations. Clinico-pathological interpretation is necessary. In case of any disparity test may be repeated immediately.

Address : 36/44 FK Kabir Nagar, Durgakund, Varanasi - 221005

Email: dramishra@gmail.com, drpallaviojha@gmail.com Website: panaceahospital.org

Facilities:

All clinical Biomedical & Hematology Investigations including Bone Marrow Examination
VPT, Podiascan & Complete Foot Care (First Time in Purvanchal)
All Hormonal Investigation by Chemiluminescent Method
Visceral Fat by (AB-140) Ambulatory BP Monitoring
CGMS & Insulin Pump Available
PFT, 2D-ECHO (Color Doppler), Holter, TMT, Cardiac-3 available
VIA, VILI, Colposcopy available
Special Endocrinological Investigation Protocols.

ISO 9001:2008 Certified
Mobile: 9389994334, 9554572190, 9453837595



Panacea Pathology

Clinical Reference Lab

Persistence, Preparedness and Precision
EQAS (CMC Vellore Attached) & IQAS System
पूर्वांचल की सर्वोत्तम गुणवत्ता वाली पैथोलॉजी

UHID No :- UD-23240006917 **Booking No/Date** :- 48 / 18-Mar-2024 12:53 PM
Patient Name :- Mr ROHIT KUMAR **Age/Sex** :- 39 Y/M
Father :- GAURI SHANKAR THAKUR **OP No** :- OP-23240021225
Address :- THANA TAJPUR MORWA BAZAR BAZAR MORWA SAMASTIPUR - 848121 , BIHAR **Mobile No** :- 7355463929
Consultant :- Dr Santosh Verma (MBBS)

Investigations	Observations	Biological Ref. Interval	Unit
TOTAL BILIRUBIN	0.63	0.00 - 1.20	mg/dl
DIRECT BILIRUBIN	0.24	0.00 - 0.30	
INDIRECT BILIRUBIN	0.39	0.20 - 0.70	mg/dl
SGOT	26.0	2.00 - 31.00	U/L
SGPT	29.0	10.00 - 45.00	U/L
ALKALINE PHOSPHATASE	68.0	25.00 - 140.00	U/L
TOTAL PROTIENS	7.32	6.60 - 8.70	g/dl
ALBUMIN	4.10	3.50 - 5.20	gm%
GLOBULIN	3.22	1.50 - 3.60	gms/dl
A/G RATIO	1.27	2:1	RATIO
RFT (RENAL FUNCTION TESTS)			
SERUM CREATININE	0.99	0.60 - 1.60	mg/dl
URIC ACID	3.92	3.60 - 7.70	mg/dl

IMMUNOLOGY

PSA, TOTAL	0.52	0.00 - 4.00	ng/ml
THYROID PROFILE (T3,T4,TSH)			
T3	0.92	0.60 - 1.81	ng/ml

Lab Technician

Timing : 24/7 hrs

This Report is not valid for medico legal purpose

Consulting Pathologist
DR. UMESH KUMAR
MBBS, MD (PATHOLOGY)
MCI Reg. No. 41413

Note: These tests have technical limitations. Clinico-pathological interpretation is necessary. In case of any disparity test may be repeated immediately.

Address : 36/44 FK Kabir Nagar, Durgakund, Varanasi – 221005

Email: dramishra@gmail.com, drpallaviojha@gmail.com Website: panaceahospital.org

Facilities:

All clinical Biomedical & Hematology Investigations including Bone Marrow Examination
VPT, Podiascan & Complete Foot Care (First Time in Purvanchal)
All Hormonal Investigation by Chemiluminescent Method
Visceral Fat by (AB-140) Ambulatory BP Monitoring
CGMS & Insulin Pump Available
PFT, 2D-ECHO (Color Doppler), Holter, TMT, Cardiac-3 available
VIA, VILI, Colposcopy available
Special Endocrinological Investigation Protocols.

ISO 9001:2008 Certified
Mobile: 9389994334, 9554572190, 9453837595



Panacea Pathology

Clinical Reference Lab

Persistence, Preparedness and Precision
EQAS (CMC Vellore Attached) & IQAS System
पूर्वाचल की सर्वोत्तम गुणवत्ता वाली पैथोलॉजी

UHID No :- UD-23240006917 **Booking No/Date** :- 48 / 18-Mar-2024 12:53 PM
Patient Name :- Mr ROHIT KUMAR **Age/Sex** :- 39 Y/M
Father :- GAURI SHANKAR THAKUR **OP No** :- OP-23240021225
Address :- THANA TAJPUR MORWA BAZAR BAZAR MORWA SAMASTIPUR - 848121 , BIHAR **Mobile No** :- 7355463929
Consultant :- Dr Santosh Verma (MBBS)

Investigations	Observations	Biological Ref. Interval	Unit
T4	6.2	4.50 - 10.90	ug/dl
TSH	1.05	0.39 - 6.10	uIU/mL

BIOCHEMISTRY

PPBS(POST PRANDIAL BLOOD SUGAR)

POST PRANDIAL BLOOD GLUCOSE(2 HR AFTER MEAL)	124.0	110.00 - 150.00	mg/dl
IGT(2 HR 75GM GLUCOSE)	-	140.00 - 199.00	mg/dl
DIABETES	-	upto200	mg/dl
TARGET IN DM	-	80.00 - 130.00	mg/dl

PARASITOLOGY

STOOL ROUTINE

GROSS EXAMINATON

COLOR <i>Methology</i>	YELLOW	CLEAR YELLOW
CONSISTANCY	NORMAL	
BLOOD	ABSENT	
MUCUS	ABSENT	

MICROSCOPIC EXAMINATON

OVA OR EGGS OF HELMINTHS	ABSENT
--------------------------	--------

Consulting Pathologist

DR. UMESH KUMAR
MBBS, MD, (PATHOLOGIST)
MC Reg No. 41413

Lab Technician

Timing : 24/7 hrs

This Report is not valid for medico legal purpose

Note: These tests have technical limitations. Clinico-pathological interpretation is necessary. In case of any disparity test may be repeated immediately.

Address : 36/44 FK Kabir Nagar, Durgakund, Varanasi – 221005

Email: dramishra@gmail.com, drpallaviojha@gmail.com Website: panaceahospital.org

Facilities:

All clinical Biomedical & Hematology Investigations including Bone Marrow Examination
 VPT, Podiascan & Complete Foot Care (First Time in Purvanchal)
 All Hormonal Investigation by Chemiluminescent Method
 Visceral Fat by (AB-140) Ambulatory BP Monitoring
 CGMS & Insulin Pump Available
 PFT, 2D-ECHO (Color Doppler), Holter, TMT, Cardiac-3 available
 VIA, VILI, Colposcopy available
 Special Endocrinological Investigation Protocols.

ISO 9001:2008 Certified
 Mobile: 9389994334, 9554572190, 9453837595



Panacea Pathology

Clinical Reference Lab

Persistence, Preparedness and Precision
 EQAS (CMC Vellore Attached) & IQAS System
 पूर्वांचल की सर्वोत्तम गुणवत्ता वाली पैथोलॉजी

UHID No :- UD-23240006917 **Booking No/Date** :- 48 / 18-Mar-2024 12:53 PM
Patient Name :- Mr ROHIT KUMAR **Age/Sex** :- 39 Y/M
Father :- GAURI SHANKAR THAKUR **OP No** :- OP-23240021225
Address :- THANA TAJPUR MORWA BAZAR BAZAR MORWA SAMASTIPUR - 848121 , BIHAR **Mobile No** :- 7355463929
Consultant :- Dr Santosh Verma (MBBS)

Investigations	Observations	Biological Ref. Interval	Unit
CYST OF PROTOZOA	ABSENT		
VEG. FORMS OF PROTOZOA	ABSENT		
PUS CELLS	02-03	2.00 - 3.00	/HPF
RBC <i>Methology / Carm</i>	NIL	4.50 - 5.50	million/cumm

* END OF REPORT *

Consulting Pathologist

Dr. Umesh Kumar
 DR. UMESH KUMAR
 MBBS MD (PATHOLOGY)
 MCL Reg. No. 41473

Lab Technician

Timing : 24/7 hrs

This Report is not valid for medico legal purpose

Note: These tests have technical limitations. Clinico-pathological interpretation is necessary. In case of any disparity test may be repeated immediately.

Address : 36/44 FK Kabir Nagar, Durgakund, Varanasi – 221005

Email: dramishra@gmail.com, drpallaviojha@gmail.com Website: panaceahospital.org



Call Now - 1800-123-3070

PANACEA HOSPITAL



A shelter for many hearts A Home for many lives

(An ISO 9001:2008 Certified Organisation)

Lab Attached with CMC Under EQAS Scheme

Dept. of Radiodiagnosis - 32 Slice CT Scan, 3D/4D USG, 2D ECHO, Colour Doppler, Intervention Procedures, Digital X-Ray

NAME: ROHIT KUMAR
REF.DR. DR.ASHUTOSH MISHRA(MD)

AGE/SEX: 39 YRS/MALE
DATE: 18/03/2024

ULTRA SOUND WHOLE ABDOMEN REPORT

- Liver:** Normal in size(143mm), shape & echogenicity. Intra & extra hepatic biliary Radicals & Vascular structures are normal. Margins are smooth and regular.
- Gall bladder:** Normally distended with echo free lumen.
- Portal vein:** Normal in course and caliber.
- CBD diameter:** Visualized part normal in course & caliber.
- Pancreas:** Normal in size, shape & echogenicity. Margins are smooth & regular. No diffuse/ focal lesion seen. Pancreatic duct not visualized.
- Spleen:** Normal in size, shape & echogenicity. Margins are smooth & regular.
No diffuse / focal lesion seen. Splenic vessels at hilum is normal.
- Kidney:** Both normal in size, shape echogenicity & position. Cortical-medullary differentiation is maintained. Pelvicalyceal system normal. No evidence of any calculus/mass lesion seen
No hydronephrosis/ hydroureter seen. No suprarenal mass lesion.
- Urinary bladder:** Normally distended with normal wall thickness. No echogenic foci lumen or diverticula seen.
Both VUJ appears normal. No evidence of calculus / mass lesion seen.
- Prostate:** Normal in size, shape & echogenicity.
- Others:** No free fluid in peritoneal cavity.
No free fluid in bilateral pleural cavity.
No evidence of significantly enlarged retroperitoneal/ mesenteric lymph nodes noted.
- IMPRESSION:** **NO OBVIOUS SONOLOGICAL ABNORMALITY SEEN.**

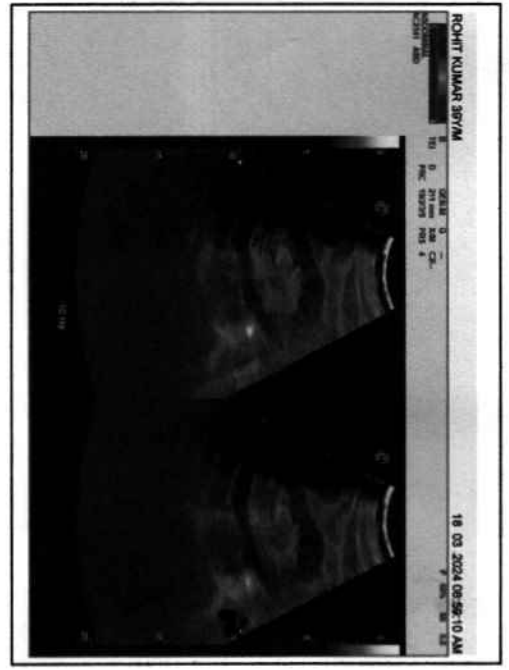
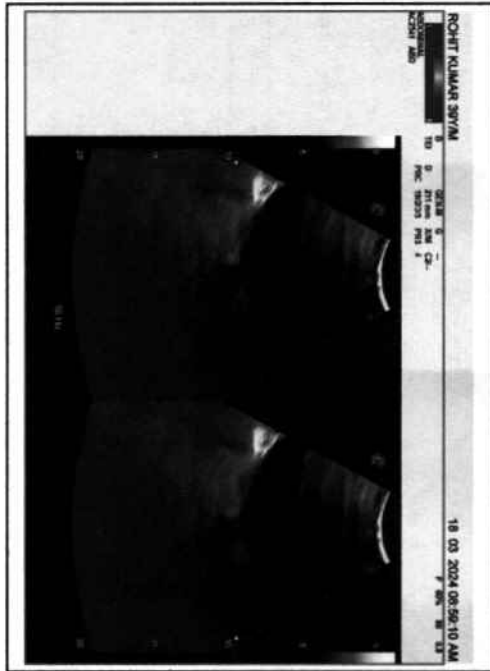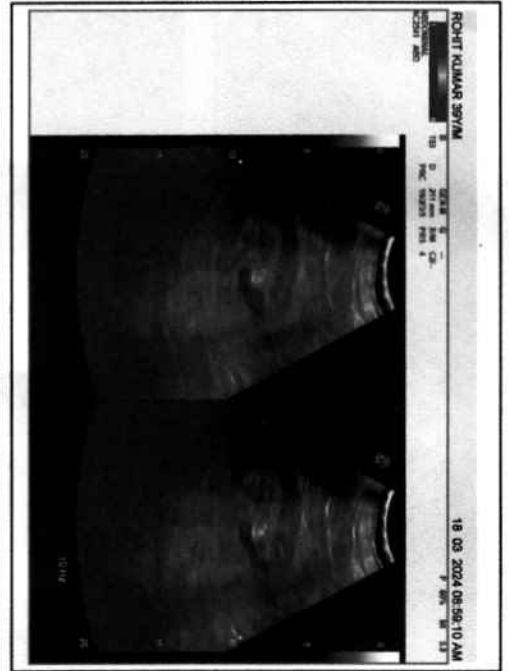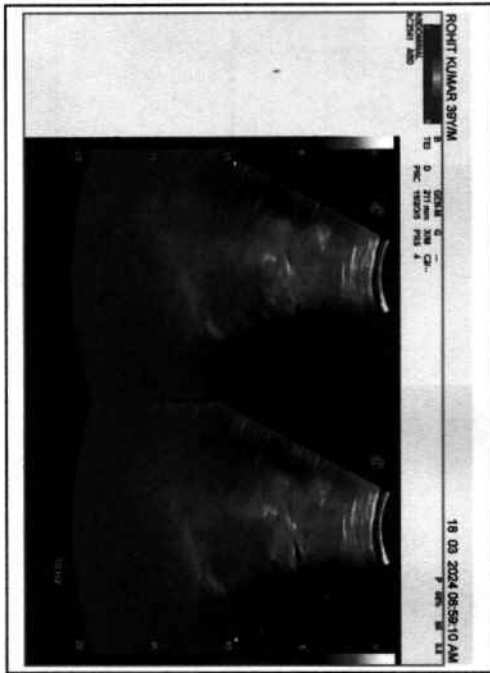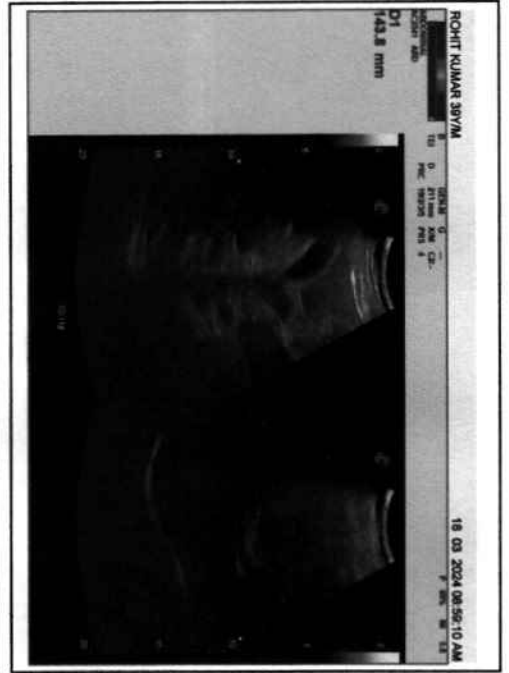Please correlate clinically and further investigations.

Sonologist

Dr. Rahul Kumar Tiwar
MBBS, MD (Radio Diagono...
Reg. No. 57557

Disclaimer: This report is not valid for Madicolegal or Judicial Purpose. Radiological diagnosis is solely interpretation of images produced by tissue & may not be always conclusive.

Address : B36/44 B4 Kabir Nagar (Near Sanjay Shiksha Niketan), Durgakund, Varanasi
Mobile : 9554572190 / 9453837595 / Recpn, 9389994334
Email : dramishra@gmail.com, drpallaviojha@gmail.com, Website : www.piire.org





PANACEA HOSPITAL



A shelter for many hearts A Home for many lives

(An ISO 9001:2008 Certified Organisation)

Lab Attached with CMC Under EQAS Scheme

Dept. of Radiodiagnosis - 32 Slice CT Scan, 3D/4D USG, 2D ECHO, Colour Doppler, Intervention Procedures, Digital X-Ray

NAME: MR ROHIT KUMAR

AGE/SEX:39Y/MYRS/MALE

REF BY: DR.ASHUTOSH MISHRA(MD)

DATE: 18/03/2024

Echo - Cardiography

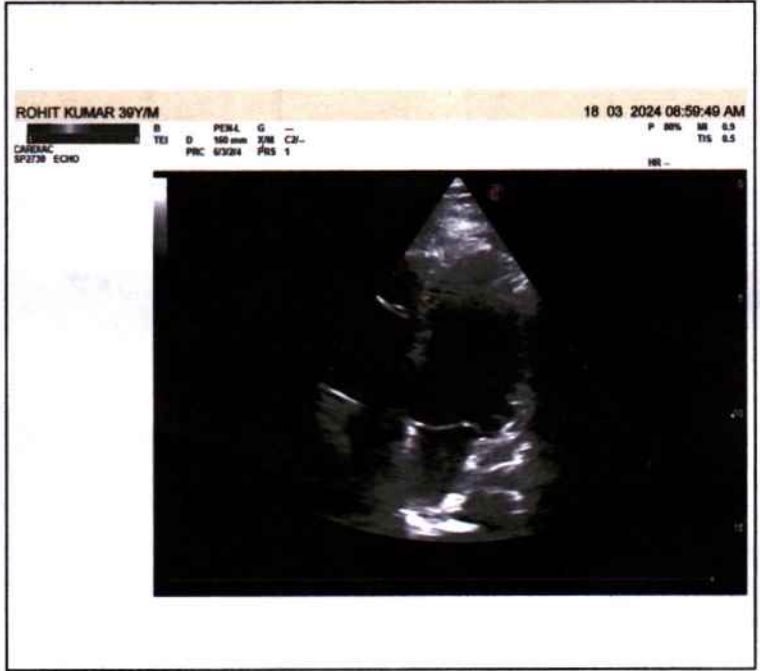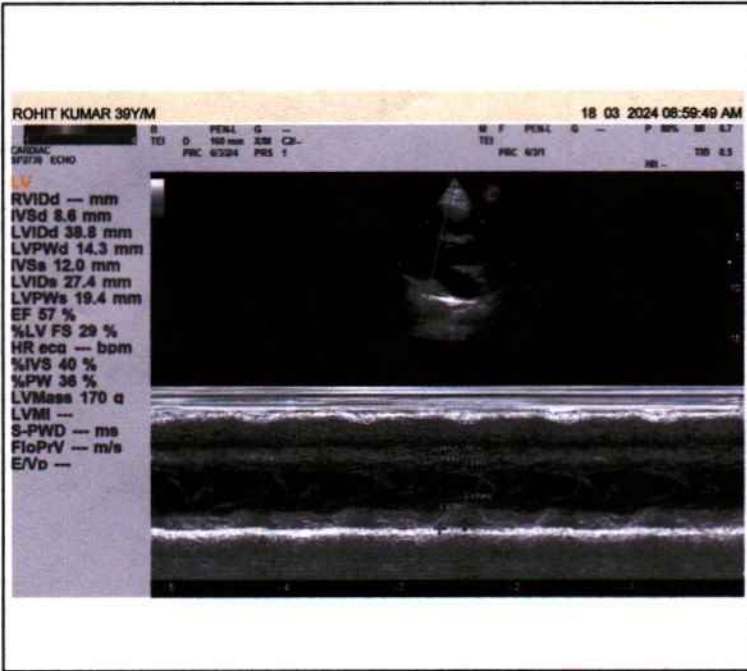
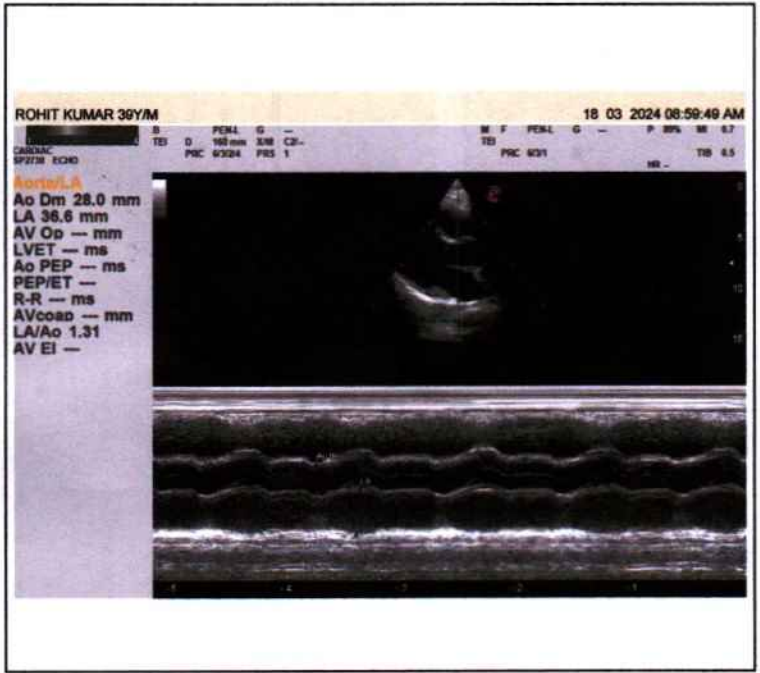
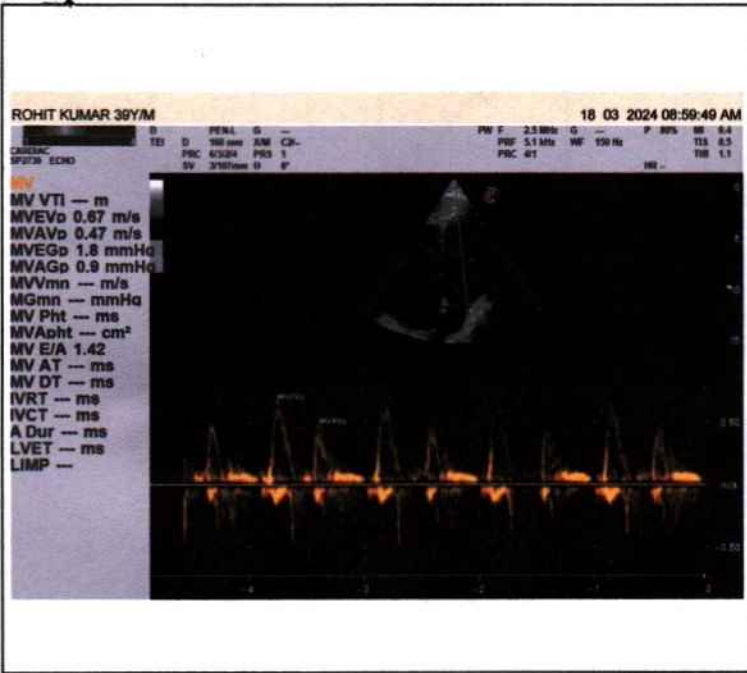
MITRAL VALVE Doppler	AML - Normal morphology MV Flow - E - 0.47 A-0.6 E/A=1.42	PML - Normal morphology MVA - 3.0 cm2 Mitral Regurgitation -No
TRICUSPID VALVE Doppler	Normal TV Flow -No	Tricuspid Regurgitation - No
PULMONARY VALVE Doppler	Normal PV Flow -No	Pulmonary Regurgitation - No
AORTIC VALVE Doppler	Trileaflet-No AV Flow - no	Aortic Regurgitation - No
MEASUREMENT	Aorta - 26.8 (20-38) mm IVS ed - 9.1 (6 - 12) mm LVID ed - 45.7 (35 - 55) mm LVPW ed - 9.7 (6 - 12) mm OA - 7 (> 5) mm	LA -31.4 (24-32) mm IVS es -12.1 (6 - 12) mm LVID es - 27.4 (24 - 40) mm LVPW es - 19.4 (6 -12) mm EPSS - 4 (< 9) mm

CONCLUSION All cardiac chamber dimensions are WNL
No valvular abnormalities
Good LV systolic function present Modified Simpson's method (4C, 2C) (LVEF-57%)
No diastolic dysfunction present (E/A = 1.42)
No RWMA
No pericardial effusion
Intact IAS / IV
No PAH
No intra cardiac mass /thrombus /vegetation

IMPRESSION Normal Echocardiogram


Niraj Mishra
Physician Assistant
(PIIRE)


Dr. Pallavi Mishra
MBBS, MD (GENERAL MEDICINE),
Echocardiography specialist, MHA
MBBS, MD (GENERAL MEDICINE),
MCI Reg. No. 52033
Diabetocardiologist





Call Now - 1800-123-3070

PANACEA HOSPITAL



A shelter for many hearts A Home for many lives
(An ISO 9001:2008 Certified Organisation)
Lab Attached with CMC Under EQAS Scheme

Dept. of Radiodiagnosis - 32 Slice CT Scan, 3D/4D USG, 2D ECHO, Colour Doppler, Intervention Procedures, Digital X-Ray

PATIENT'S NAME :	ROHIT KUMAR	AGE 39Y/ SEX :M
REF. BY :	Dr. ASHUTOSH MISHRA(MD)	DATE :18/03/2024

X-RAY CHEST (PA VIEW)

- Bilateral lung fields appear normal.
- Trachea and mediastinum appear normal in position.
- Both hila appear normal in size and are symmetrical.
- Transverse cardiac diameter is within normal limits.
- Great vessels appear normal
- Both CP angles appear clear. Normal position and contour diaphragms noted.
- Bony rib cage and soft tissue shadows appear normal.

IMPRESSION

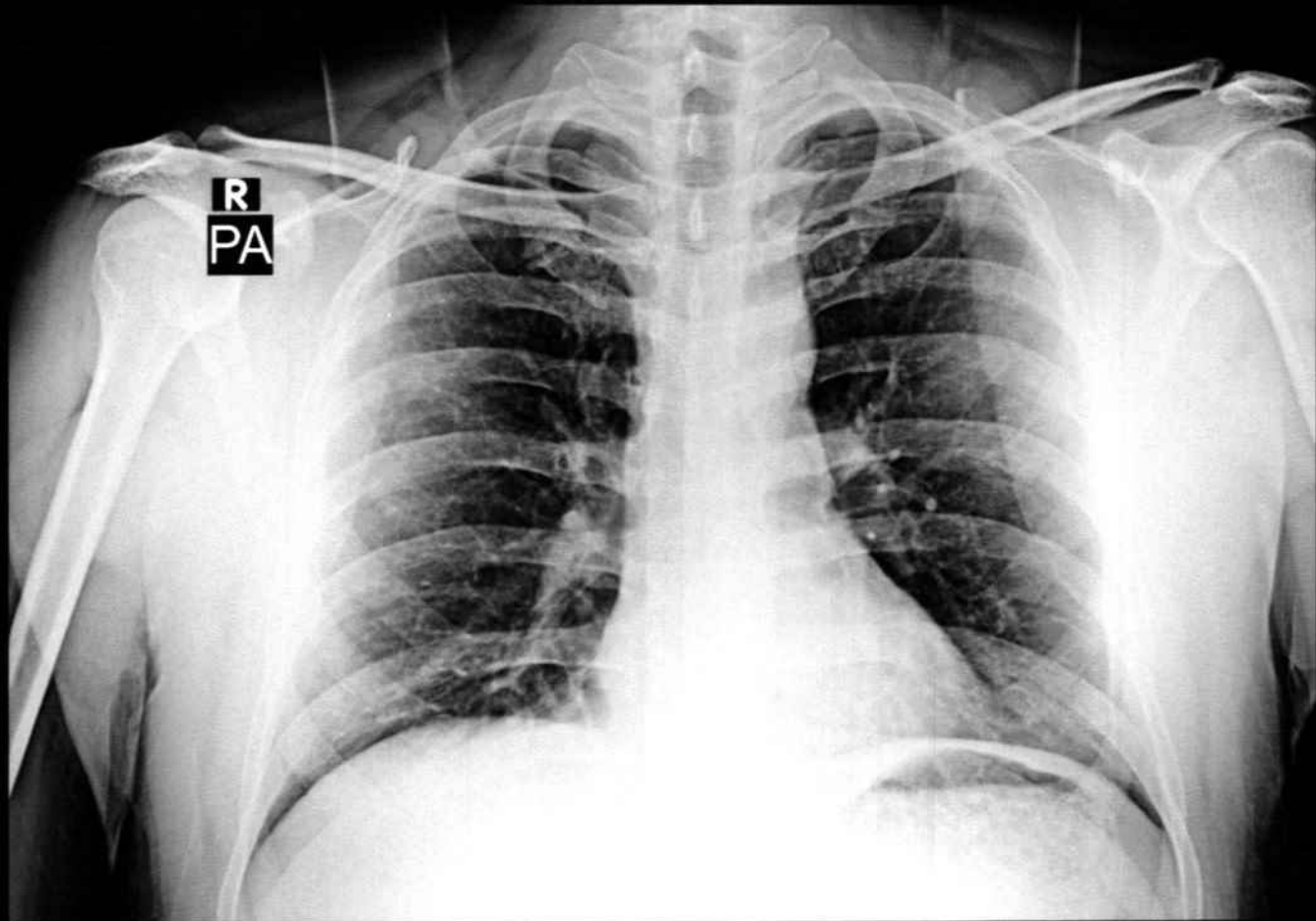
- **No obvious abnormality noted in the chest radiograph.**

Thanks for reference.

Radiologist
Dr. Rahul Kumar Tiwari
MBBS, MD (Radio Diagonosis),
Reg. No. 57557

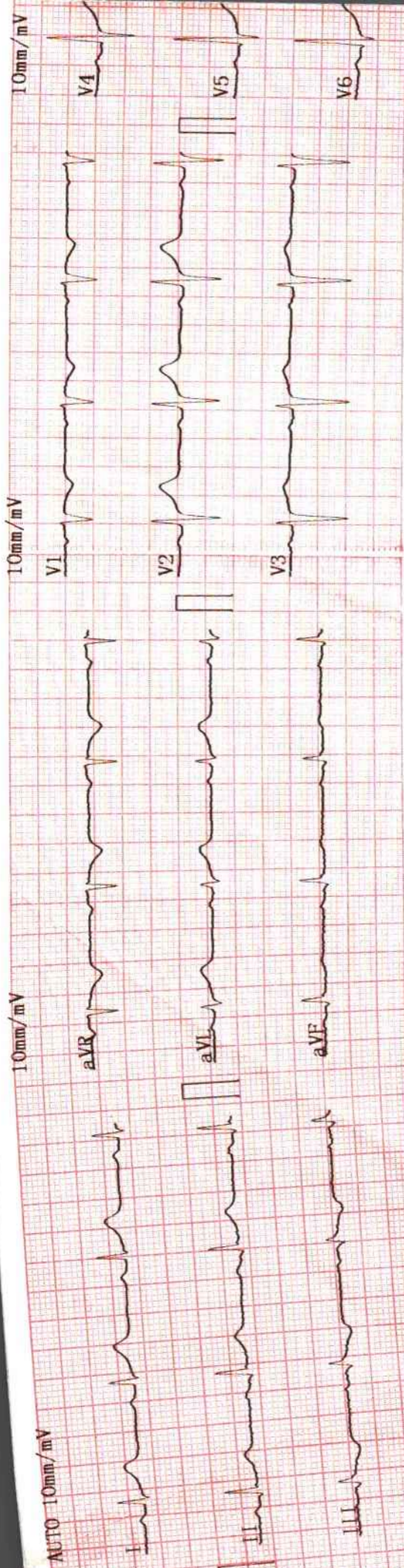
Disclaimer: This report is not valid for Madicolegal or Judicial Purpose. Radiological diagnosis is solely interpretation of images produced by tissue & may not be always conclusive.

Address : B36/44 B4 Kabir Nagar (Near Sanjay Shiksha Niketan), Durgakund, Varanasi
Mobile : 9554572190 / 9453837595 / Recpn, 9389994334
Email : dramishra@gmail.com, drpallaviojha@gmail.com, Website : www.piire.org



ROHIT KUMAR 39Y/M 6917 M CHEST P.A. 18-Mar-24 10:54 AM

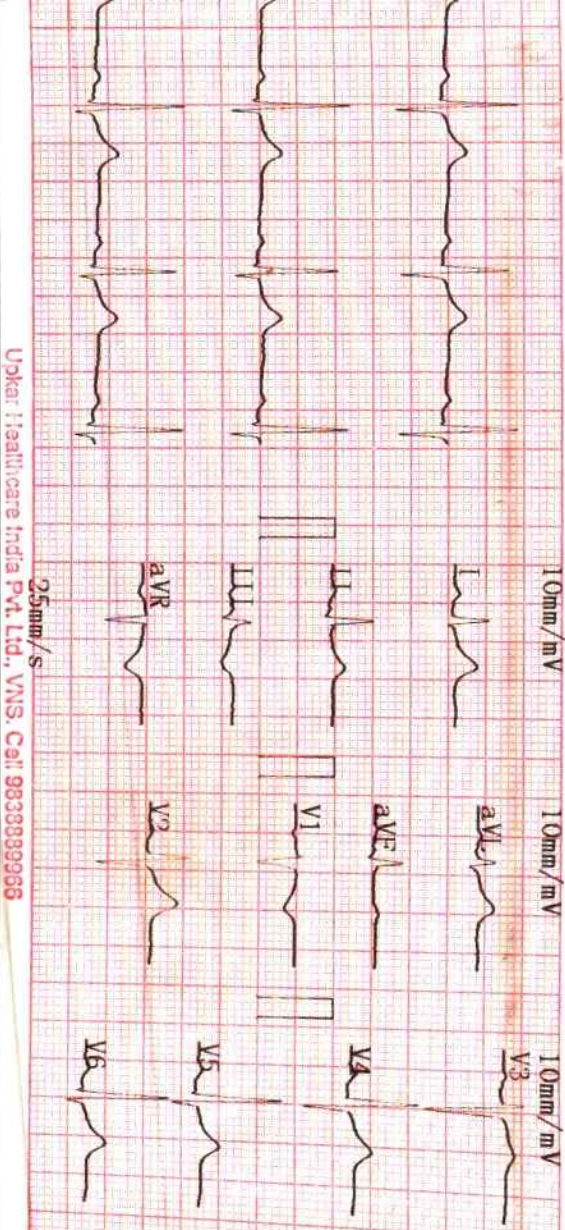
PANACEA HOSPITAL, KABIR NAGAR, DURGAKUND, VARANASI



AUTO 10mm/mV
 25mm/s AC50Hz+EMC35Hz+DFT

Upkar Healthcare India Pvt. Ltd., VNS. Cell: 9838889966

2024-03-18 09:48



ID : _____
 Name : **Rohit Kumar**
 Sex : **M**
 Height : **171**
 SYS : _____
 DIA : _____
 HR : **71**
 PR Interval : **174**
 P Duration : **104**
 QRS Duration : **69**
 T Duration : **187**
 QT/QTc : **351/381**
 P/QRS/T Axis : **47.0/49.5/16.3**
 R(V5)/S(V1) : **1.13/0.52**
 R(V5) : **1.65**
 S(V1) : _____

Age : **32**
 Weight : **73.8** kg

<< Conclusions >>

Normal Sinus Rhythm,
 Cardiac electric axis norma

**Report need physician conf

DR. Pallavi Misra

MBBS, MD(GENERAL MEDICINE)
 Physio

Reg. No.52033