

DAKSH HOSPITAL

396 - 397, Gandhi Nagar, Scheme No. 8, ALWAR -301001

Ref. No.

Date.....

MEDICAL EXAMINATION REPORT
Mediwheel (BOB)

Name: Mrs. Bhavana Meena

Age: 27 yrs Sex: Female

Date: 06/04/2024

General Physical ExaminationHeight : 163cm
Pulse : 90 /mt
Respiration : 18/mtWeight : 53 Kg
BP : 100/70 mm/hg
BMI : 19.9 kg/m²Systemic Exam:- NORMALDental Check up :- NORMALEye check-up :- NORMALSkin Check up:- NORMALENT Check up:- NORMALGynae Check up:- Mn - 3/30 d m on - NIL Pmt + pap's smear after
LMP - 3rd MLIYm clearj fun fluidImpression:- NORMALRecommendation:- - Increase Protein dietDr. Mukesh Kumar Gupta
MD Gen. Medicine
Reg. No 5423/16262डॉ० मुकेश गुप्ता
M.D.F.C.C.S.फिजिशियन एवं मधुमेह रोग विशेषज्ञ
दक्ष हॉस्पिटल, अलवर
रेजि० नं०-5423/16262

Results

Run Date 06/04/2024 09:24:55 AM

Operator DAKSH

Last Name

Sample ID 3

First Name MRS BHAVANA

Department

Gender Female

Age

Physician DR. MUKESH GUPTA M.D

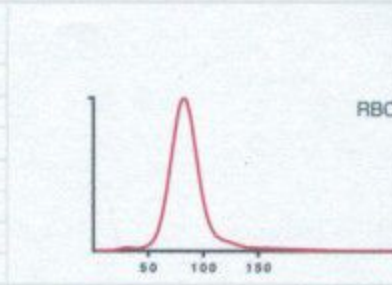
Patient ID AUTO_PID20739

Type Woman

Date of birth

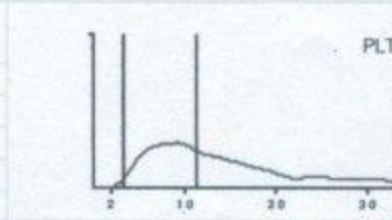
Sample comments

				Range
RBC	5.54	h*	10 ⁹ /μL	3.80 - 5.50
HGB	15.0		g/dL	11.5 - 15.2
HCT	47.8	h*	%	35.0 - 46.0
MCV	86.2	*	μm ³	77.0 - 97.0
MCH	27.1		pg	26.0 - 34.0
MCHC	31.4	L	g/dL	32.0 - 35.0
RDW-CV	14.9		%	11.0 - 17.0
RDW-SD	51.0	h	μm ³	37.0 - 49.0

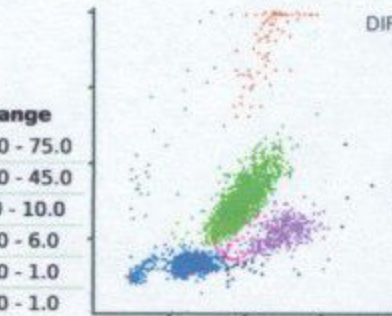


Susp. Pathologies
Macroplatelets

				Range
PLT	294	*	10 ³ /μL	150 - 450
PCT	0.39		%	0.15 - 0.40
MPV	13.2	H	μm ³	8.0 - 11.0
PDW	22.8	h	μm ³	11.0 - 22.0
P-LCC	152	h	10 ³ /μL	44 - 140
P-LCR	51.9	h	%	18.0 - 50.0



			Range		Range
WBC	6.51		10 ³ /μL	3.50 - 10.00	
	#		Range	%	Range
NEU	3.68		1.60 - 7.00	56.7	40.0 - 75.0
LYM	2.42		1.00 - 3.00	37.2	20.0 - 45.0
MON	0.19	l	0.20 - 0.80	2.9	2.0 - 10.0
EOS	0.13		0.00 - 0.50	2.0	1.0 - 6.0
BAS	0.08		0.00 - 0.15	1.2	0.0 - 1.0
LIC	0.01		0.00 - 0.10	0.1	0.0 - 1.0



Dr. R.S. Gupta
Dr. R.S. GUPTA
 MD (Pathology) (MAHE)
 RMC No. 7924/19778

Date :- 06/04/2024

Name :- MRS.BHAVNA

Age & Sex :- 27Yrs/ female

Refd. :- Dr Mukesh Gupta M.D.

	TEST NAME	RESULT	REFERENCE RANGE	
	ESR	13	00 -20 mm/hrs	
	Blood Group & Rh Factor	O ⁺ POSITIVE		
	HbA1C	4.7	4 - 5.6%	
	Blood Sugar (F)	80.8	< 70 - 100 mg/dl	
	Blood Sugar (PP)		< 140 mg/dl	
	Urine Sugar (F)		-	
	Urine Sugar (PP)		-	
LIVER	S.Bilirubin Total	0.90	0.30 - 1.20 mg/dl	
	S.Bilirubin Direct	0.20	0.10 - 0.30 mg/dl	
	S.Bilirubin Indirect	0.70	0.30 - 0.90 mg/dl	
	S.G.O.T.	27	> 40 u/l	
	S.G.P.T.	40	> 40 u/l	
	S.Alk. Phosp.	191	80 - 306 u/l	
	G.G.T.	25	5 -40 u/l	
	Total Protein	6.9	6.5 - 8.5 gm/dl	
	Albumin	3.8	3.8 - 5.4 gm/dl	
	Globulin	3.1	2.3 - 3.5 gm/dl	
	A/G Ratio	1.2	-	
	AST/ALT Ratio	0.6	-	
KIDNEY	Blood Urea	28.2	15 -45 mg/dl	
	S.Creatinine	0.94	0.60 - 1.30 mg/dl	
	BUN	19.0	6 -24 mg/dl	
	S.Uric Acid	5.0	M 3.1 - 7.0, F 2.5 - 5.6 mg/dl	
	BUN/Creatinine Ratio	20	-	
LIPID PROFILE	Total Cholesterol	160.1	Up to 200 mg/dl	
	S.HDL	44.1	30 - 70 mg/dl	
	S.LDL	86.1	Up to 170 mg/dl	
	S.VLDL	301	5.0 - 40 mg/dl	
	S. Triglycerides	150.1	Up to 170 mg/dl	
	LDL/HDL Ratio	1.9	-	
	Total Cholesterol/ HDL Ratio	3.6	-	
THYROID	T3	78	40 - 181 ng/dl	
	T4	6.0	4.6 - 10.5 µg/dl	
	TSH	1.43	0.30 - 5.0 mlu/l	
URINE EXAMINATION		Microscopic Examination :		
General/Chemical Examination:	Colour	Pale Yellow	RBC	Absent
	Reaction	Acidic	WBC	NIL
	Specific Gravity	QNS	Epithelial Cells	NIL
	Appearance	NIL	Cast	Absent
	Albumin	Nil	Crystal	Absent
	Sugar	Nil	Spermatozoa	Absent
			Amorphous Sediments	Absent
		Other	Absent	
X-RAY CHEST	NORMAL STUDY			
STOOL EXAMINATION		Microscopic Examination :		
General/ Chemical Examination:			RBC	-
	Colour	-	WBC	-
	Consistency	-	Ova & Parasites	-
	PH	-		
	Reducing Substances	-		

Dr. R.S. GUPTA
MD (Pathology) (MAHE)
Doctor
RMC No. 7924/19778

TECHNOLOGIST

All investigations have their own limitations regarding the sensitivity & specificity of individual assay procedures. Isolated laboratory investigations never confirm the final diagnosis of the disease. They only help in arriving at a diagnosis in conjunction with clinical presentation and other related investigations. Report is not valid for medico-legal purpose subject to ALWAR jurisdiction only.



दक्ष हॉस्पिटल

396, गाँधी नगर स्कीम नं.8, अलवर (राज०) ☎ 0144-2703340

Sonography / 2D Echo Cardiography / Doppler Report

2D/ ECHO REPORT

Name: - Mrs Bhavana

Age: - 27 Yrs

Date: - 6-Apr-24

Reg. No.: - Alw/2009/04
BOB health checkup

PROCEDURES: M-MODE/2D/DOPPLER/COLOR/CONTRAST B.A.S. M²

MEASUREMENT:		DOPPLER:	
AOD	22	NORMAL (20- 37mm)	MV 0.8 (0.8- 1.3) MR No
LA	20	(19- 40mm)	AV 1.4 (1.2- 1.8) AR No
AVO	15	(12- 25mm)	TV 0.6 (0.3- 0.8) TR No
RVDd.	12	(03- 09mm)	PV 0.8 (0.7- 1.1) PR No
LVDd	40.5	(37- 56mm)	MITRAL VALVE-
LVDs	21.6	(22- 40mm)	AML Normal
IVS d	6	(06- 12mm)	PML Normal
IVS s	10		
PWd	2.6	(05- 10mm)	AORTIC VALVE Normal
LV FUNCTION		TV & PV are normal.	
M- E- S Separation	<0.9cm		
Minor	24.42%		
LV Ejection Fraction	79%	65 +/- 12%	

LV WALL MOTION: NO RWMA
ALL CARDIAC CHAMBERS ARE NORMAL
ALL VALVES ARE NORMAL
NO CLOT, VEGETATION, PERICARDIAL EFFUSION

FINAL DIAGNOSIS: NORMAL STUDY

Adv: - Follow up/ review at higher center for confirmation

Note:- Please Correlate clinically. Due to technical limitations as well as inaccuracies inherent in the laboratory and statistical analysis of biological process. Diagnostic accuracy of ECHO is up to 95% only.
Report is not valid for medico-legal purpose.


DR. MUKESH GUPTA
PHYSICIAN
Dr. Mukesh Kumar Gupta
Physician & Sonologist
RM 5423/16262



"भ्रूण लिंग परीक्षण की शिकायत
104 टोल फ्री सेवा पर भी की
जा सकती है"
भ्रूण लिंग परीक्षण की शिकायत 104 टोल फ्री सेवा पर भी की जा सकती है।



दक्ष हॉस्पिटल

396, गाँधी नगर स्कीम नं.8, अलवर (राज०) ☎ 0144-2703340

Sonography / 2D Echo Cardiography / Doppler Report

NAME :- MRS BHAVANA/F/27 YRS

6-Apr-24

BOB HEALTH CHECKUP

U.S.G. OF ABDOMEN & PELVIS

LIVER

Liver is 13.5 cm with normal echo-texture. Intra hepatic biliary radicals Are not dilated. No evidence of focal or diffuse lesion.

GALL BLADDER

Operated. CBD normal.

PANCREAS

Pancreas is normal in size, shape & echo-texture. No evidence of focal or diffuse lesion. MPD not dilated.

SPLEEN

Spleen 7.4 cm in size with normal shape & echo- texture. Spleen vein is normal. No evidence of focal or diffuse lesion

KIDNEY

Both kidneys are normal size, shape & echo-texture.

URINARY BLADDER

UB is normally distended, visualized lumen appear clear. Wall thickness normal.

UTERUS:

Uterus is normal in size (7.6x2.4x4.5cm) with homogenous echo-texture. Endometrial 9 mm in thickness & echo genicity

OVARIES:

Right ovary measures 47x18 mm & have multiple small follicles, arrange at periphery.
Left ovary measures 42x17 mm & have multiple small follicles, arrange at periphery.

Advice- follow up/ hormonal study review at higher center for confirmation

Please correlate clinically. USG accuracy is 95 % due to technical limitations as well as inaccuracies inherent in the laboratory and statistical analysis biological process.
This report is not valid for medico-legal cases

DR. MUKESH GUPTA
SONOLOGIST
Dr. Mukesh Kumar Gupta
Physician & Sonologist
RM 5423/16262



“भ्रूण लिंग परीक्षण की शिकायत
104 टोल फ्री सेवा पर भी की
जा सकती है”
भ्रूण लिंग परीक्षण की शिकायत 104 टोल फ्री सेवा पर भी की जा सकती है।

11-02-2024 07:29:38 PM

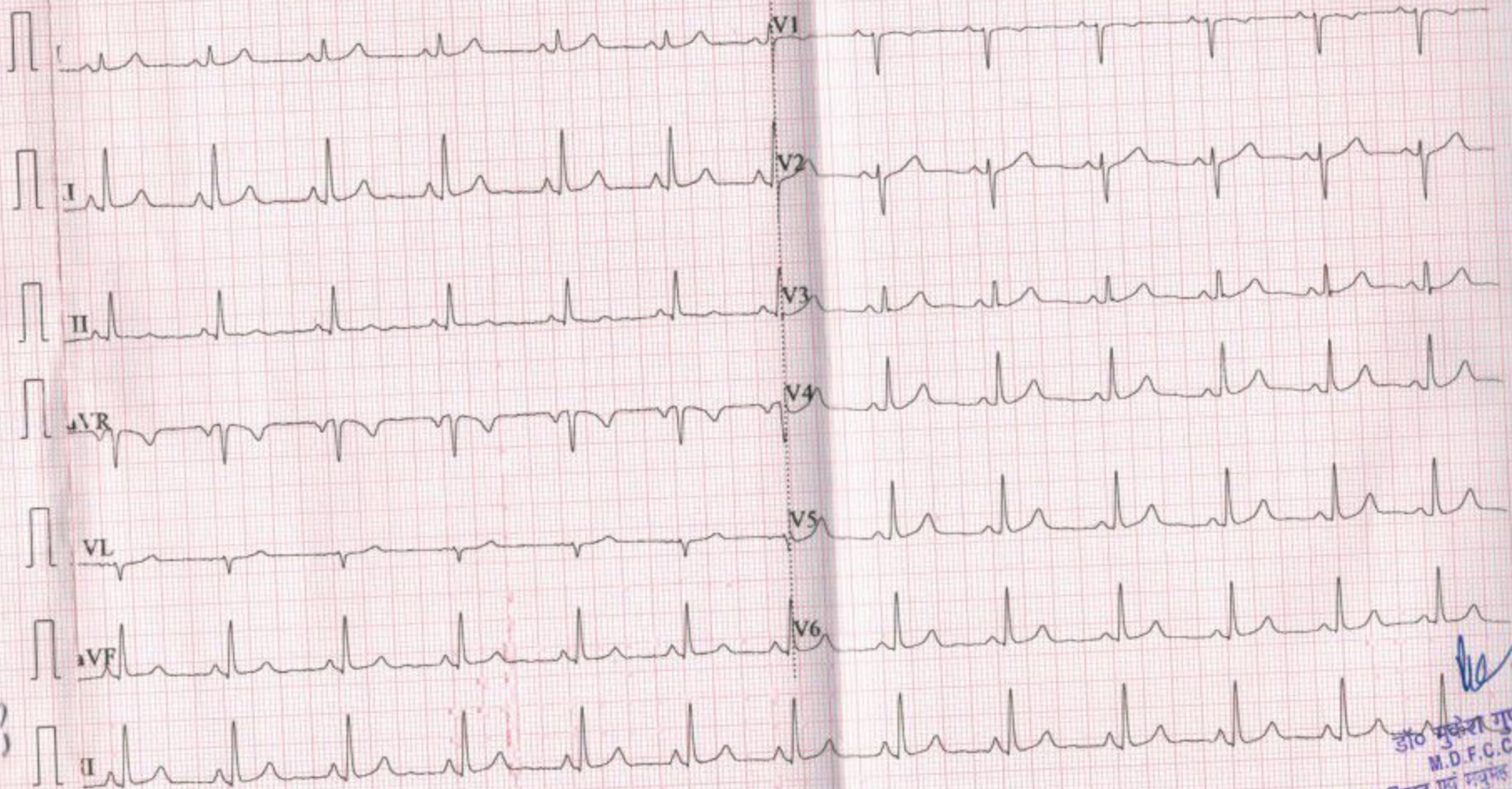
ID: 3

Female Years

HR	: 78	bpm
P	: 87	ms
PR	: 115	ms
QRS	: 79	ms
QT/QTc	: 360/411	ms
PQRST	: 54/71/32	°
RV5/SV1	: 0.987/0.655	mV

Diagnosis Information:
 Sinus Rhythm
 Short PR Interval
 Low Voltage(Chest Leads)

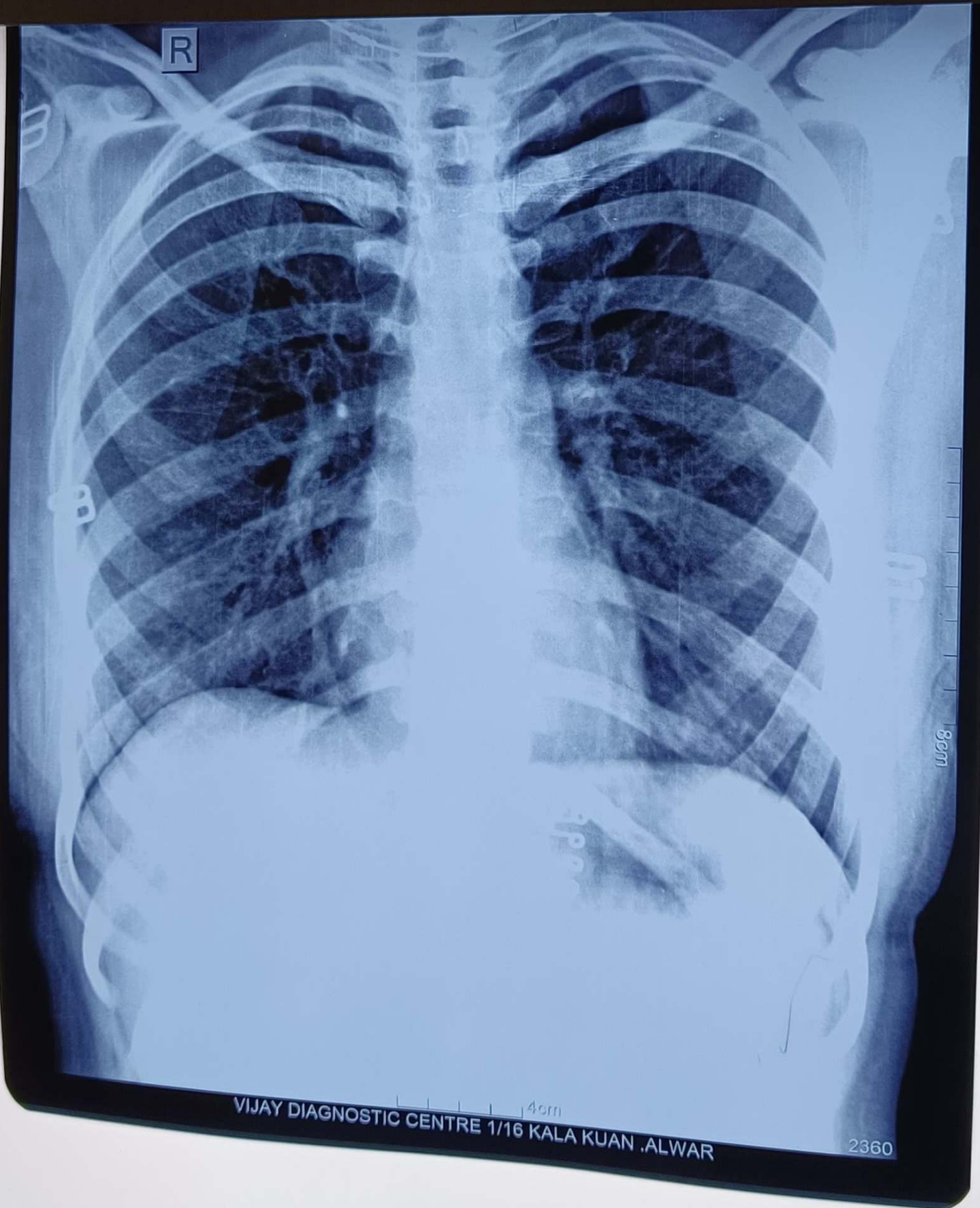
Report Confirmed by:



0.67~35Hz AC50 25mm/s 10mm/mV 2*5s+1r ♥78

V2.02 SEMIP V1.7 DAKSH HOSPITAL

डॉ० मुकुंदा गुप्ता
 M.D.F.C.C.S.
 फिजिशियन एवं मनुष्य रोग विशेषज्ञ
 दश हॉस्पिटल, जयपुर
 रजि० नं०-5423/192



R

B

11

8cm

ppn

4cm

VIJAY DIAGNOSTIC CENTRE 1/16 KALA KUAN .ALWAR

2360