

26/10/23

Respected sir/mam,

As I am not comfortable for getting done ECHO, with a male doctor, I am opting out for the same. I will get it done from somewhere else if & when my regular physician will prescribe the same,

~~At~~ -

Yours faithfully

Charvi son

Respected sir/mam,

As I am planning for family, my doctor has advised me for avoiding XRAY exposure for few days. So, I will take appointment later for XRAY report. Please allow.

~~At~~ -

Yours sincerely,
Charvi son



MER- MEDICAL EXAMINATION REPORT

Date of Examination	26-10-2024		
NAME	CHARVI SONI		
AGE	34	Gender	FEMALE
HEIGHT(cm)	168	WEIGHT (kg)	65
B.P.	122/76/78		
X RAY	NORMAL		
ECG	NORMAL		
EYE CHECKUP	COLOUR VISION: NORMAL NEAR: 6/6 WITHOUT GLASSES FAR: 6/6 WITHOUT GLASSES		
Present Ailments	N/A		
Details of Past ailments (If Any)	N/A		
Comments / Advice : She /He is Physically Fit	PHYSICALLY FIT		

Dr. Vipul Chaudhary
 MD (Internal Medicine)
 Reg.No. G-18004

Signature with Stamp of Medical Examiner



NAME :	CHARVI SONI	AGE/SEX:	34 Y/F
REF. BY:	HEALTH CHECK UP	DATE :	26-Oct-24

USG ABDOMEN & PELVIS

LIVER: normal in size & shows normal echotexture. No evidence of dilated IHBR. No evidence of focal or diffuse lesion. CBD & Portal vein normal.

GALL-BLADDER: normal, No evidence of Gall Bladder calculi.

PANCREAS: normal in size & echotexture, No e/o peri-pancreatic fluid collection.

SPLEEN: normal in size & shows normal echogenicity.

KIDNEYS: Both kidneys appear normal in size & echotexture. Right kidney measures 114 x 40mm. Left kidney measures 118 x 49mm. No evidence of calculus or hydronephrosis on either side.

URINARY BLADDER: appears normal and shows minimal distension & normal wall thickness. No evidence of calculus or mass lesion.

UTERUS: grossly normal in size and echopattern. No e/o adnexal mass seen on either side.

USG WITH HIGH FREQUENCY SOFT TISSUE PROBE:

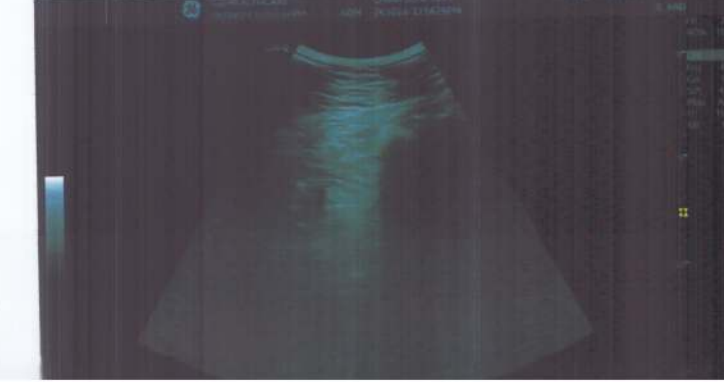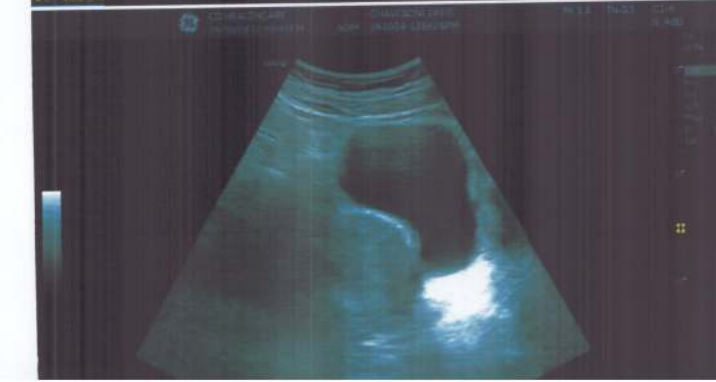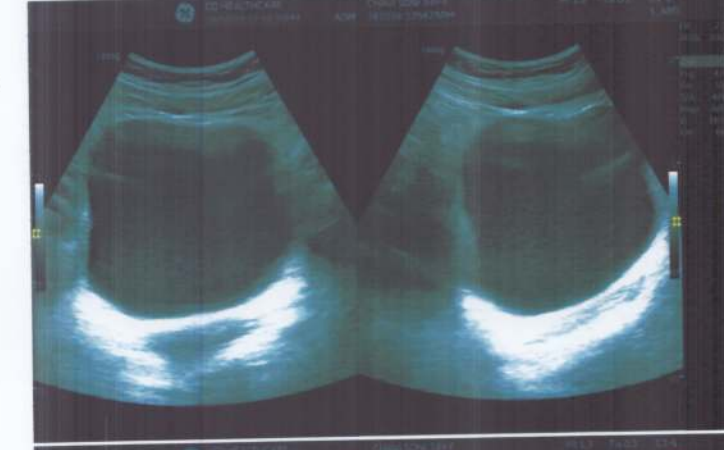
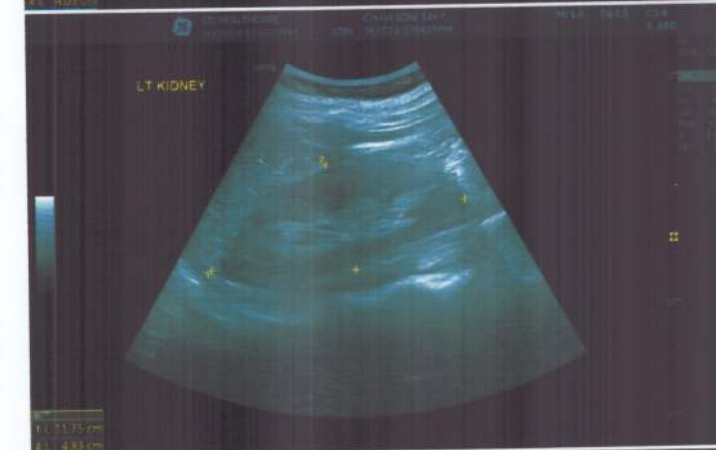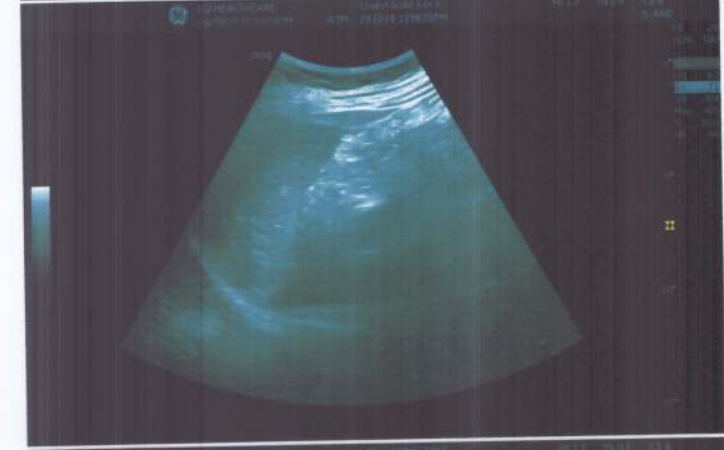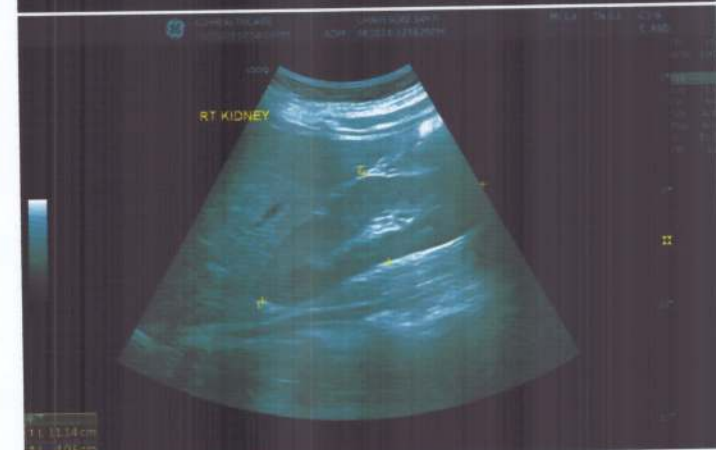
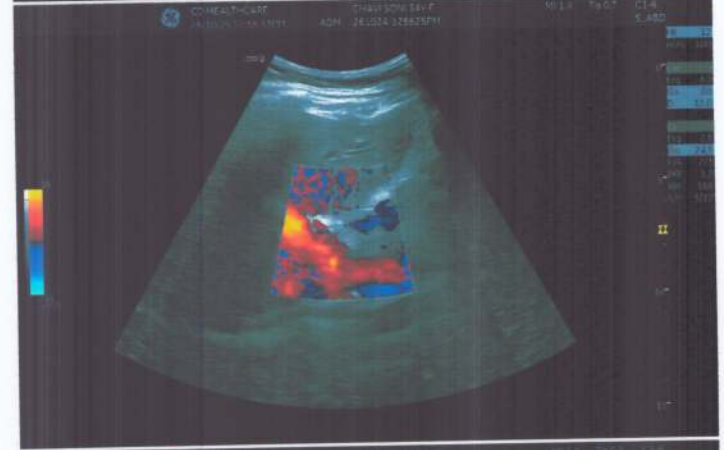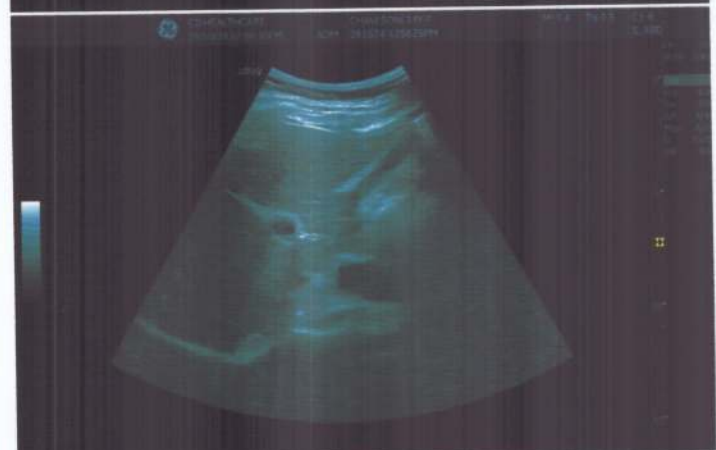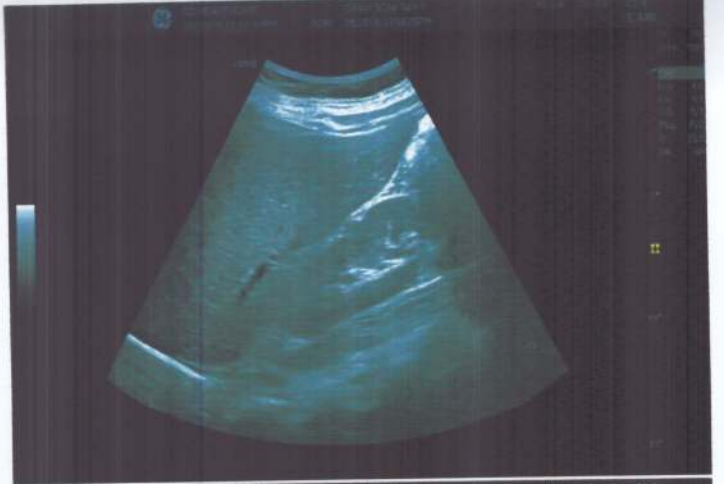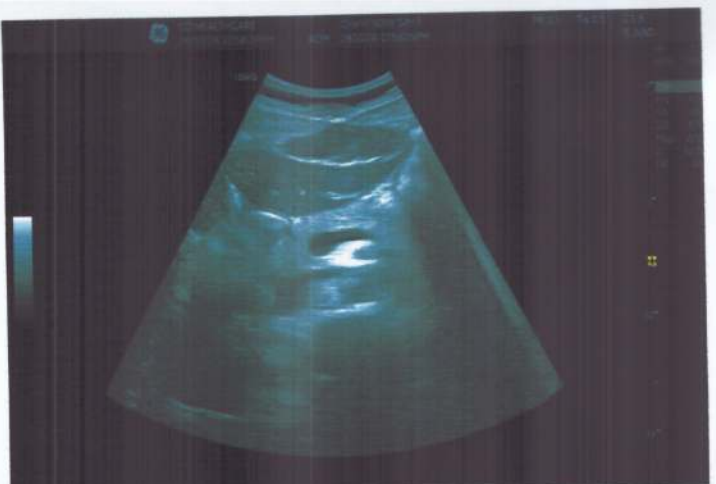Visualized bowel loops appears normal in caliber. No evidence of focal or diffuse wall thickening. No collection in RIF. No e/o Ascites. No e/o significant lymphadenopathy.

IMPRESSION:

- **NORMAL STUDY.**

Dr. TEJAS PATEL
DNB RADIODIAGNOSIS

Dr. Tejas Patel
Diplomate N. B.
G-33659



SIB
 gynae

Chavi soni

26/12/2024

34yrs

- Married
- Nulligravida
- LMP: 25/19/2024
- Rmn: Regular
- Father + Mother has Ca Breast
- Father + Mother has CA

PIA - Son

MS - Ca healthy
 Pa taken

Adx

USG Breast

Pa Pa

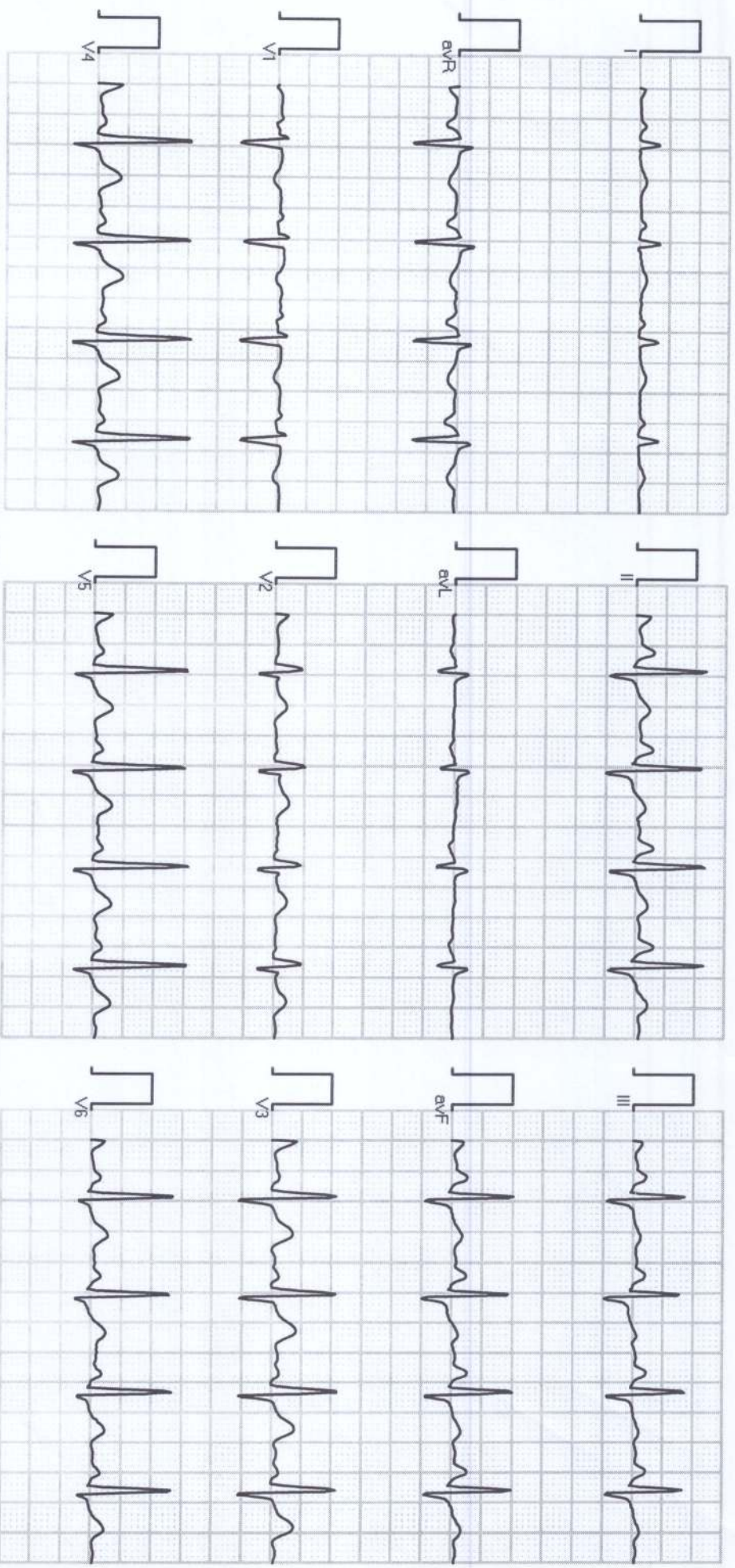
- FU & report

[Signature]

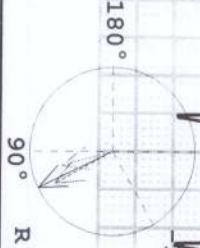
CONCEPT DIAGNOSTIC

3056 / CHARVI SONI / 34 Yrs / F / 168Cms. / 65Kgs. / Non Smoker
Heart Rate : 90 bpm / Tested On : 26-Oct-24 12:52:09 / HF 0.05 Hz - LF 35 Hz / Notch 50 Hz / Sn 1.00 Cm/mV / Sw 25 mm/s

ECG



Vent Rate : 90 bpm
PR Interval : 134 ms
QRS Duration : 108 ms
QT/QTc Int : 378/431 ms
P-Q-T axis : 74.00° 64.00° 61.00°



Axis
R 64.00° T 61.00° P 74.00°

NSR/WMZ

G - 32946

DR PARTH THAKKAR
MD (Med.) DFNB (Cardiology)
Interventional cardiologist

Reported By: DR PARTH THAKKAR