

Name:	HINGOLE PRAVINKUMAR BHIMRAO	Exam Date:	14-Sep-2024
Age & Sex:	041 Year /M	Accession:	143056133429
Exam:	ABDOMEN AND PELVIS	PID:	P00000526566
Physician:	HOSPITAL CASE	OP/IP:	OP /«extrafield1»

ULTRASOUND OF ABDOMEN AND PELVIS

DEXTROCARDIA NOTED.

Liver appears normal in size, shape and echotexture. No focal lesion is seen. No intrahepatic biliary radicle dilatation seen. The portal vein and CBD appear normal.

Gall bladder is collapsed.

Pancreas appears normal in size and echotexture. No focal lesion is seen.
Spleen appears normal in size and echotexture. No focal lesion is seen.

Both kidneys appear normal in size, shape & echotexture. They show good cortico-medullary differentiation. There is no hydronephrosis, hydroureter or calculus seen on either side.

The urinary bladder is well distended. Wall thickness is normal. No mass lesion or calculus is seen.

Prostate is normal in size, shape and echotexture. No obvious focal lesion is seen on present transabdominal study.

Visualised bowel loops are non-dilated and show normal peristalsis.
There is no ascites or significant lymphadenopathy seen.

clinical correlation,



DR. YATIN R. VISAVE
CONSULTANT RADIOLOGIST
MBBS, DMRD
Regd. No. 090812

16-Sep-2024 09:16:48 AM



Grant Medical Foundation
Ruby Hall Clinic
Hinjawadi

Name: HINGOLE PRAVINKUMAR BHIMRAO	Study Date: 14-Sep-2024
Age & Sex: 041 Year /M	Accession: 143056133429
Exam: CHEST X RAY	PID: P00000526566
Physician: HOSPITAL CASE	OP OP /«extrafield1»

Health Check

Radiograph Chest PA View :

DEXTROCARDIA NOTED

Both lung fields normal.

Both costo-phrenic angles are clear.

Cardiac silhouette and aortic knuckle are normal.

Both hilar shadows and the diaphragmatic contours are normal.

Thoracic soft tissues and the rib cage normal.

CLINICAL CORRELATION.

DR. YATIN R. VISAVE
CONSULTANT RADIOLOGIST
MBBS, DMRD
Regd. No. 090812

15-Sep-2024 11:50:19 AM

Dextrocardia

1100 Sinus rhythm
9110 ** normal ECG **

years

Ref: PS010148- Reg. OP-S000004129
P00000526566 -

Medication:

Symptoms:

History:

Vent. rate

PR int

QRS dur

QT/QTc(E) int

P/ORS/T axis

RV5/SV1 amp

RV5+SV1 amp

70 bpm

172 ms

86 ms

372/ 393 ms

72/ 66/ 64

1.63/ 1.36 mV

3.00 mV

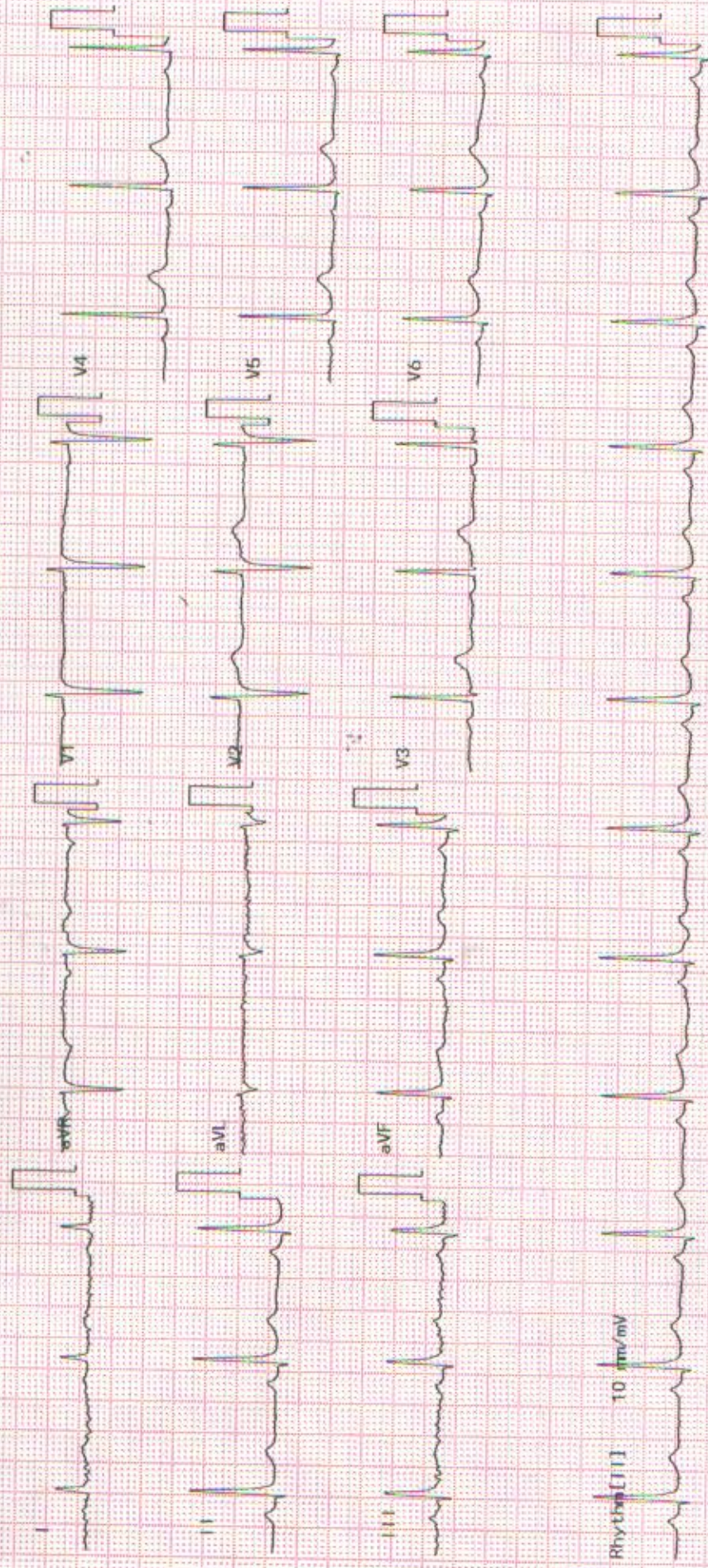
10 mm/mV 25 mm/s

Filter: H50 D 35 Hz 10 mm/mV

10 mm/mV

10 mm/mV

Unconfirmed Report
Reviewed by:





Grant Medical Foundation
Ruby Hall Clinic
 Pimple Saudagar

MR. HINGOLE PRAVINKUMAR BHIMRAO

Ref: PS010148- Reg: OPS00004129
 41.2.11/M - NH - 14/09/2024
 P00000526566 -

OPHTHALMOLOGY

NAME :

AGE :


R

L

- | | | |
|---------------------|-------------------------|---------------|
| 1) Vision | unaided _____ | _____ |
| | with glasses <u>6/6</u> | <u>6/6</u> |
| 2) Near Vision | unaided _____ | _____ |
| | with glasses <u>N-6</u> | <u>N-6</u> |
| 3) Binocular Vision | <u>Normal</u> | <u>Normal</u> |
| 4) Colour Vision | <u>Normal</u> | <u>Normal</u> |
| 5) Tension | <u>-</u> | <u>-</u> |
| 6) Anterior Segment | <u>Normal</u> | <u>Normal</u> |
| 7) Pupils | <u>PRRL</u> | <u>PRRL</u> |
| 8) Lens | <u>Clear</u> | <u>Clear</u> |
| 9) Media & Fundus | <u>-</u> | <u>-</u> |

10) Remarks Add - +1.00DS

Date :


 (Signature)

MR. HINGOLE PRAVINKUMAR BHIMRAO



Ref: PS010148- Reg: OPS0004129
41.2.11/M - NH - 14/09/2024
P00000526566 -

Dental

OT →

* Stones → +, Calculus +.

* Gen. atrophy.

* spacing in lower premolars & molars

Adis:-

Oral prophylosis

①

Dr. Aniket

