  
**आधार**

**भारत सरकार**  
 Government of India

**भारतीय विशिष्ट पहचान प्राधिकरण**  
 Unique Identification Authority of India


नामांकन क्रम/ Enrolment No.: 0812/10022/09520

To  
 सोनिया  
 Sonia  
 C/O: Rakesh Kumar  
 194  
 A Block  
 New Seemapuri  
 Jhilmil  
 East Delhi Delhi - 110095  
 9711225229

Download Date: 18/09/2020


Issue Date: 05/09/2020


Signature Not Verified



**आपका आधार क्रमांक / Your Aadhaar No. :**  
**7633 9985 7335**  
**VID : 9194 5800 9758 1963**  
**मेरा आधार, मेरी पहचान**


---



  
**आधार**

**भारत सरकार**  
 Government of India


**भारतीय विशिष्ट पहचान प्राधिकरण**  
 Unique Identification Authority of India



 सोनिया  
 Sonia  
 जन्म तिथि/DOB: 25/02/1971  
 महिला/ FEMALE

Download Date: 18/09/2020

Issue Date: 05/09/2020

**7633 9985 7335**  
**VID : 9194 5800 9758 1963**  
**मेरा आधार, मेरी पहचान**



  
**आधार**

**सूचना**

- आधार पहचान का प्रमाण है, नागरिकता का नहीं।
- सुरक्षित QR कोड / ऑफलाइन XML / ऑनलाइन ऑथेंटिकेशन से पहचान प्रमाणित करें।
- यह एक इलेक्ट्रॉनिक प्रक्रिया द्वारा बना हुआ पत्र है।

**INFORMATION**

- Aadhaar is a proof of identity, not of citizenship.
- Verify identity using Secure QR Code/ Offline XML/ Online Authentication.
- This is electronically generated letter.

- आधार देश भर में मान्य है।
- आधार कई सरकारी और गैर सरकारी सेवाओं को पाना आसान बनाता है।
- आधार में मोबाइल नंबर और ईमेल ID अपडेट रखें।
- आधार को अपने स्मार्ट फोन पर रखें, **mAadhaar App** के साथ।

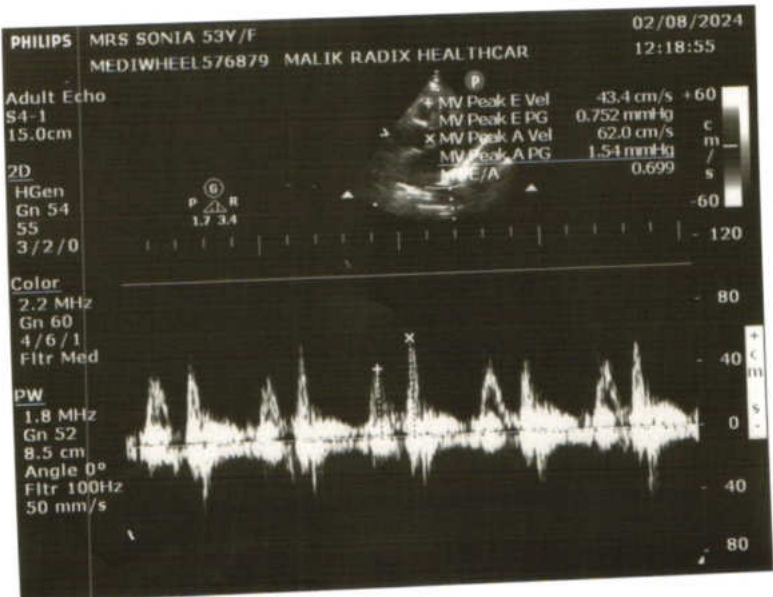
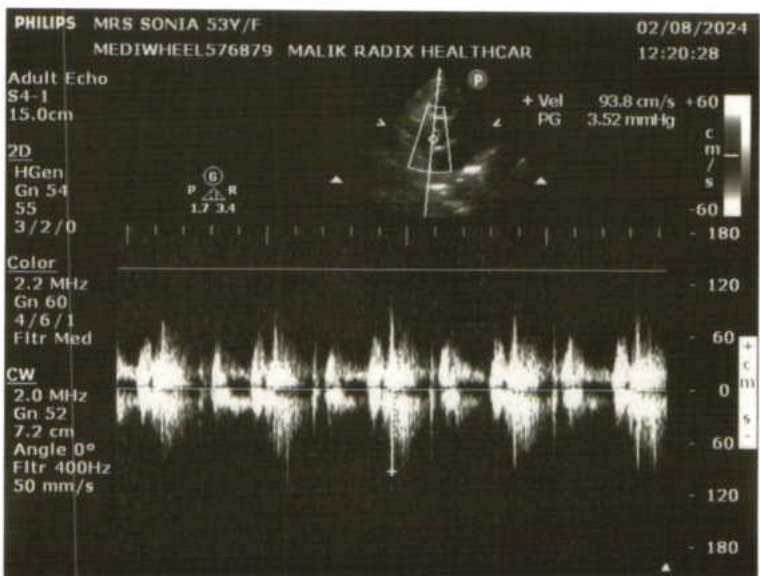
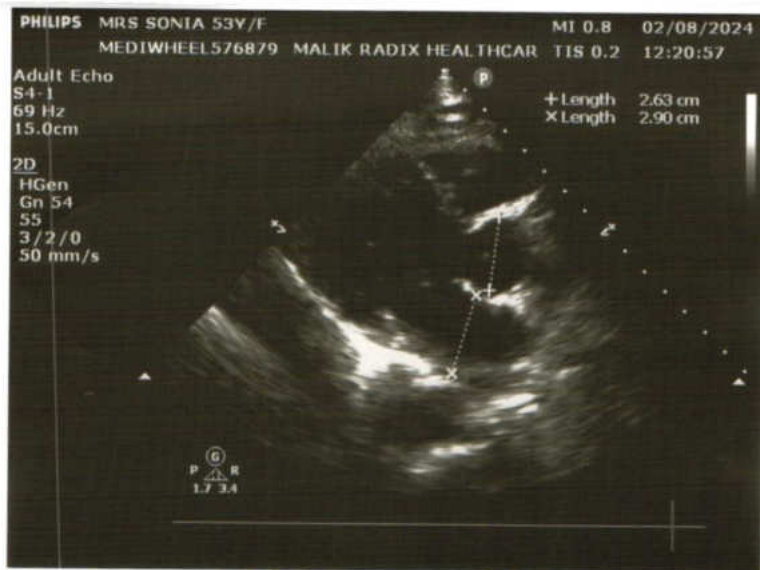
- Aadhaar is valid throughout the country.
- Aadhaar helps you avail various Government and non-Government services easily.
- Keep your mobile number & email ID updated in Aadhaar.
- Carry Aadhaar in your smart phone – use **mAadhaar App**.

**7633 9985 7335**  
**VID : 9194 5800 9758 1963**

1947 | help@uidai.gov.in | www.uidai.gov.in

**MALIK RADIX HEALTH CARE PVT. LTD.**  
 C-217, C-218, Nirman Vihar,  
 Delhi-110092  
 Ph.: 011-49287456, 011-61381379  
 607

सोनिया





## Echocardiogram Report

<b>Patient Name</b>	<b>MRS. SONIA</b>
<b>Date of Test</b>	<b>02/08/2024</b>
<b>Age</b>	<b>53 YRS/ FEMALE</b>
<b>Ref. by</b>	<b>MEDIWHEEL</b>

<b>Dimensions</b>	<b>Result</b>	<b>Normal Range</b>
AO (ed)	2.6 cm	( 2.1 -3.7cm)
LA (es)	2.9 cm	(2.1 -3.7cm)
RVID (ed)	2.2 cm	(1.1-3.0cm)
LVID (ed)	4.3 cm	(3.6 – 5.5 cm)
LVID (es)	3.0 cm	(2.3-3.9cm)
IVS (ed)	1.1 cm	(0.6 – 1.1 cm)
LVPW (ed)	1.1 cm	(0.6 – 1.1 cm)
EF	60 %	
FS	31 %	(28 % - 42 %)

### Impression:

- NO REGIONAL WALL MOTION ABNORMALITY SEEN.
- LVEF= 60 %
- NORMAL CHAMBER DIMENSIONS.
- STAGE I LV DIASTOLIC DYSFUNCTION.
- TRACE MITRAL REGURGITATION.
- MILD TRICUSPID REGURGITATION. NORMAL PA PRESSURE.
- NO INTRA CARDIAC CLOT/MASS/ VEGETATION/PERICARDIAL EFFUSION SEEN.

  
 Dr. Sheikh Nazir Ahmed  
 M.D. "Physician" PGDCC  
 (Consultant Non – Invasive Cardiologist)

### Facilities Available

- Multispeciality Hospital - 24 Hours Emergency - X-Ray/ ECG/ Ultrasound/ CT Scan - Dental- Fully Equipped Operation Theatre  
 - Fully Functional Lab - 24/7 Casualty/ ICU-Nursery 24/7 Pharmacy - Labour Room - All Speciality OPD - Laproscopic Surgery -  
 ECHO - Plastic Surgery



## EYE EXAMINATION (AHC)

Name: Mrs. Sonia.	Age & Gender: 53yr / Female
Ref.by: Medicwheel	Date: 02/08/24

Without Correction		With Correction	
Distance - Right	6/12	Distance - Right	6/6
Distance - Left	6/24	Distance - Left	6/18
Near - Right	ND	Near - Right	ND
Near - Left	ND	Near - Left	ND

Color Vision: Normal  Abnormal

Diagnosis: Ⓒ Early Cataract

Treatment Recommended: Evaluation & details

*Dr. Nidhi Gupta*  
 MBBS, MS, DNB  
 Casualty Ophthalmologist  
 Malik Radix Healthcare Pvt. Ltd.  
 DMC No. 121661

### Facilities Available

- Multispeciality Hospital - 24 Hours Emergency - X-Ray/ ECG/ Ultrasound/ CT Scan - Dental- Fully Equipped Operation Theatre
- Fully Functional Lab - 24/7 Casualty/ ICU-Nursery 24/7 Pharmacy - Labour Room - All Speciality OPD - Laproscopic Surgery - ECHO - Plastic Surgery



## CONSULTANTS ON PANEL

### PAEDIATRICS

Dr Ravi Malik (MBBS, MD)  
Dr Harit Prasad (MBBS, MD, Pdi)  
Dr Ritu Jain (MBBS, MD)

### GYNAECOLOGY

Dr Renu Malik (MBBS, MD)  
Dr Meena Malhotra (MBBS, MD)  
Dr Rajni (MBBS, MD)  
Dr Manju Gupta (MBBS, MS)  
Dr Vaishali Saini (MBBS, DGO)  
Dr Rupam Arora (MBBS, MD)

### DENTAL

Dr Shruti Malik (BDS, MDS)  
Dr Annu Saini (BDS, MDS)  
Dr Rachit Thukral (BDS, MDS)  
Dr Mohit Mangla (BDS, MDS)  
Dr Tarun Mittal (BDS, MDS)  
Dr Geetika Sharma (BDS)  
Dr Shilpa Verma (BDS)

### CHILD GASTROENTEROLOGY

Dr S. K Mittal (MBBS, MD)

### MEDICINE

Dr A S Talwar (MBBS, MD)  
Dr Sunny Uppal (MBBS, MD)  
Dr Surendra Rajpal (MBBS, MD)

### RESPIRATORY MEDICINE /PULMONOLOGY

Dr Abhinav Bhanot (MBBS, DNB)

### LAPAROSCOPY SURGERY

Dr Ajay Jain (MBBS, MS)  
Dr Deepak Saran (MBBS, MS)  
Dr Pradeep Saini (MBBS, MS)  
Dr G. S Garg (MBBS, MS)

### ORTHOPAEDICS

Dr Vikas Bhardwaj (MBBS, MS ORTHO, DNB)  
Dr Prabhakar Aggarwal (MBBS, MS ORTHO)  
Dr KB Tiwari (MBBS, MS ORTHO)  
Dr Deepak Kumar Arora (MBBS, MS ORTHO)

### EYE/OPTHALMOLOGY

Dr Nidhi Gupta (MBBS, MS, DNB, PGDM)  
Dr Himanshu Singh Pundir (MBBS, MS)

### ENT

Dr Sharad Kumar Singh (MBBS, MS)  
Dr Prateek Sharma (MBBS, MS)  
Dr Ashok Singh (MBBS, MS)  
Dr A K Lahiri (MBBS, MS)

### RADIOLOGY (ULTRASOUND)

Dr K K Sinha (MBBS DNRB)  
Dr T K Vohra (MBBS, MD)  
Dr Rajesh Malhotra (MBBS, MD)  
Dr Ashish Tomar (MBBS, MD)

### PATHOLOGY

Dr Reema Dahiya (MBBS, MD PATH)  
Dr Meenu Aggarwal (MBBS, MD PATH)

### ANAESTHESIA

Dr Rajesh Dhall (MBBS, MD)  
Dr Rakesh Atrey (MBBS, MD)  
Dr R K Arora (MBBS, MD)  
Dr Swaraj Garg (MBBS, MD)

### DERMATOLOGY

Dr Niharika Jha (MBBS, MD)

### PLASTIC & COSMETIC SURGERY

Dr Ayush Jain (MBBS, MS, MCh)

### PAEDIATRIC SURGERY

Dr Dharmendra Singh (MBBS, MS, M.Ch)

### PAEDIATRIC NEPHROLOGY

Dr A S Vasudev (MD, Dip.in. Paed.)

### NEPHROLOGY

Dr Javed (MBBS, MD, Nephro)

### CARDIOLOGY

Dr Nishant Tyagi (MBBS, MD)

### NEUROLOGY

Dr Amit Batra (MBBS, MD)

### GASTROENTEROLOGY

Dr Deepak Lahoti (MBBS, MD)

Dr Nareesh Aggarwal (MBBS, MD)

Dr Ashok Goyal (MBBS, MD)

Dr Ankur Singhal (MBBS, MD)

### UROLOGY

Dr Nikhil Sharma (MBBS, Mch)

Dr Ankur Singhal (MBBS, MD)

### PSYCHIATRY

Dr Mohit Sharma (MBBS, MD)

### PHYSIOTHERAPY

Dr Kirti Dwivedi

Dr Ravi Kumar

### NUTRITIONIST

Dr Deepika Kohli

Dr Sakshi Rana

### CLINICAL PSYCHOLOGIST

Dr. Sarika Singh

## Dr. Shruti Malik

BDS, MDS (Endodontics)

☎ +91-9899561092

**Timings : 10:00 am. to 2:00 pm.  
6:00 pm. to 8:30 pm.**

Name : Sonia

Age/Sex : 53y / F

Date : 02/08/2024

**For Appointment**

☎ 011-45152510  
+91-9999254639

### CLINICAL EXAMINATION:-

Health checkup - Preinsurance

#### 1. TMJ:-

M/H → Diabetes + Hypertension

#### 2. DENTAL STATUS:

##### a. Caries Teeth :

O/E → Stains + +

##### b. Fracture Teeth :

Calculus + +

##### c. Root Stumps :

##### d. Gingivitis :

##### e. Periodontitis :

Caries - 1/8

##### f. Impacted Teeth :

##### g. Malaligned Teeth :

Mandibular Anterior Crowding in

#### 3. ORAL LESIONS:-

#### 4. DIAGNOSIS:-

#### 5. TREATMENT PLANNING:

Adv OPG + Scaling

#### 6. FOLLOW UP:-

Referral To Other Consultant: Yes/ No

If Yes, please mention the Name: .....

Doctor's Signature ..... Sapna

02/08

## Facilities Available :

- ★ MULTI-SPECIALITY HOSPITAL ★ MODULAR FULLY EQUIPPED OT ★ NURSERY ★ LAPROSCOPIC SURGERY
- ★ 24X7 EMERGENCY ★ OPG ★ DENTAL ★ 24X7 DIAGNOSTICS ★ LABOUR ROOM ★ ECHO ★ EEG ★ DIGITAL X-RAY ★ CT SCAN
- ★ ECG ★ ULTRASOUND ★ RICU/ICU ★ ALL SPECIALITY OPD ★ PLASTIC & COSMETIC SURGERY ★ DIALYSIS ★ PHARMACY

GE

MAC600 I.02

ID: 0208202444

2-Aug-2024 11:43:39

V1

V2

V3

V4

V5

V6

aVR

aVL

aVF

I

II

III

II

50Hz

67 bpm

10.0||5.0 mm/mV

0.16-20Hz

Auto gain applied

25.0 mm/s

1

by 2.5s + 1 rhythm id

0

Soniq

ID: 0208202444

53years

Female

Vent. rate	67 bpm
QRS duration	74 ms
QT/QTc	394/416 ms
PR interval	124 ms
P duration	82 ms
RR interval	895 ms
P-R-T axes	-22 36 39

MAC600 I.02

12SL™ V239

HA GIZI

# Malik Radix HealthCare.

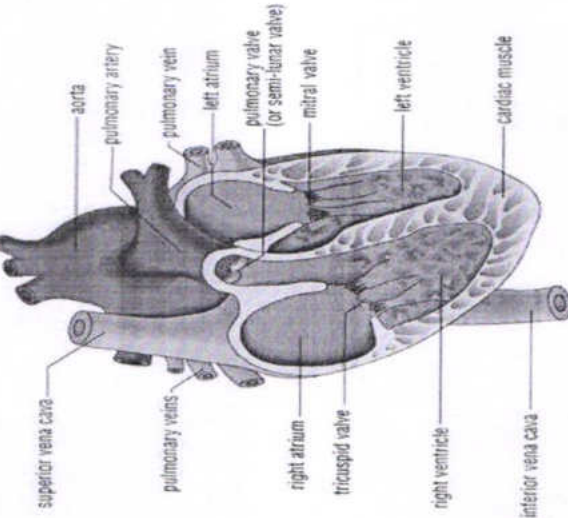
## ELECTROCARDIOGRAM

Name: MRS. SONIA

Age & Sex: 53 YR/FEMALE

Ref By: MEDIWHEEL

Date: 02/08/2024



### ECG FINDINGS:

Rate 67 bpm Rhythm Sinus Mechanism Normal

Axis Normal P Wave Normal PR Interval 0.12/Sec

QRS Complex Normal QT Interval Normal Q Wave Normal

ST Segment Normal T Wave Normal

Conclusion Sinus Rhythm, Normal Axis, WNL.

Doctors Signature AS  
**Dr. SHEIKH NAZIR AHMED**  
 M.D. "Physician"  
 PGDCC  
 DMC-46499

**LAB REPORT**

Reg. Date	02/08/2024	Patient Id	2408020009	DOB.	25/02/1971
Name	MRS. SONIA	Gender	F	Perm. ID	
Age	53 Yrs. 5 Mn. 7 Day	Panel	MEDIWHEEL	Reported	02/08/2024 17:39:57
Ref. By	MEDIWHEEL				

Test Name	Result	Units	Ref. Range
-----------	--------	-------	------------

MW FULL BODY ANNUAL PLUS CHECK AD. F

**HAEMATOLOGY****COMPLETE HAEMOGRAM**

HAEMOGLOBIN (HB%)	10.3	gm/dl	12 - 15
TOTAL LEUCOCYTE COUNT (TLC)	6,400	/cumm	4000 - 11000

**DIFFERENTIAL LEUCOCYTE COUNT (DLC)**

NEUTROPHIL	64	%	40 - 80
LYMPHOCYTE	26	%	28 - 55
MONOCYTE	05	%	02 - 10
EOSINOPHIL	05	%	01 - 06
BASOPHIL	00	%	0 - 0
ESR (WESTEGREN'S METHOD)	10	mm/1st hr.	0 - 15
R B C COUNT	3.68	Millions/cmm	4.247 - 5.4
P.C.V / HAEMATOCRIT	33.2	%	35 - 45
M C V	90.2	fl.	80 - 100
M C H	28.0	Picogram	27.0 - 31.0
M C H C	31.0	gm/dl	33 - 37
PLATELET COUNT	1.69	Lakh/cu mm	1.50 - 4.50

BLOOD GROUP ABO

" AB "

RH TYPING

Positive

BLOOD SUGAR FASTING

166.8 mg/dl 70 - 100

BLOOD SUGAR PP

296.29 mg/dl 90 - 140

**THYROID PROFILE**

Free T3 ELFA	2.31	ng/ml	02 - 04
Free T4 ELFA	1.45	ug/dl	0.8 - 2.7

Checked by : \_\_\_\_\_  
Page 1 Contd...2

If test results are alarming or unexpected, patient is advised to contact the laboratory immediately for possible remedial action.

**Facilities Available**

- Multispeciality Hospital - 24 Hours Emergency - X-Ray/ ECG/ Ultrasound/ CT Scan - Dental- Fully Equipped Operation Theatre  
- Fully Functional Lab - 24/7 Casualty/ ICU-Nursery 24/7 Pharmacy - Labour Room - All Speciality OPD - Laproscopic Surgery -  
ECHO - Plastic Surgery





**LAB REPORT**

Reg. Date	02/08/2024	Patient Id	2408020009	DOB.	25/02/1971
Name	MRS. SONIA			Perm. ID	
Age	53 Yrs. 5 Mn. 7 Day	Gender	F	Reported	02/08/2024 17:39:57
Ref. By	MEDIWHEEL	Panel	MEDIWHEEL		

Test Name	Result	Units	Ref. Range
TSH Serum/ELFA	1.970	uIU/ml	0.25 - 5.50 uIU/ml

**Interpretation**

**Clinical Use**

- Diagnose Hypothyroidism and Hyperthyroidism
- Monitor T4 replacement or T4 suppressive Therapy
- Quantify TSH levels in the subnormal range

Increased Levels : Primary Hypothyroidism Subclinical Hypothyroidism, TSH dependent, Thyroid Hormone Resistance.

Decreased Levels : Grave's Disease, Autonomous Thyroid Hormone Secretion, TSH Deficiency

**LIPID PROFILE**

TOTAL CHOLESTEROL	154.60	mg/dL	130.0 - 200.0 (<200)
TRIGLYCERIDES	172.70	mg/dL	80.5 - 150.0 (<150)
H D L CHOLESTEROL DIRECT	38.7	mg/dL	42.0 - 60.0 (<40->59)
V L D L	34.5	mg/dL	4.0 - 30. (23-45)
L D L CHOLESTEROL	81.4	mg/dL	50.0 - 150.0 (50-150)
TOTAL CHOLESTEROL / HDL RATIO	4.0		3.3 - 5.1
LDL / HDL CHOLESTEROL RATIO	2.1		1.5 - 3.5
SERUM URIC ACID	3.82	mg/dl	2.4 - 6.0
BLOOD UREA NITROGEN (BUN)	12.20	mg/dl	6.0 - 21.0

Checked by : \_\_\_\_\_  
 Page 2 Contd...3

If test results are alarming or unexpected, patient is advised to contact the laboratory immediately for possible remedial action.

**Facilities Available**

Multispeciality Hospital - 24 Hours Emergency - X-Ray/ ECG/ Ultrasound/ CT Scan - Dental- Fully Equipped Operation Theatre  
 Fully Functional Lab - 24/7 Casualty/ ICU-Nursery 24/7 Pharmacy - Labour Room - All Speciality OPD - Laproscopic Surgery -  
 ECHO - Plastic Surgery



**LAB REPORT**

Reg. Date	02/08/2024	Patient Id	2408020009	DOB.	25/02/1971
Name	MRS. SONIA	Gender	F	Perm. ID	
Age	53 Yrs. 5 Mn. 7 Day	Panel	MEDIWHEEL	Reported	02/08/2024 17:39:57
Ref. By	MEDIWHEEL				

Test Name	Result	Units	Ref. Range
SERUM CREATININE	0.70	mg/dl	0.6 - 1.2
BUN/CREAT RATIO	17.4	mg/dl	10 - 20
<b><u>LIVER FUNCTION TEST (LFT)</u></b>			
BILIRUBIN TOTAL	0.74	mg/dl	0.2 - 1.2
CONJUGATED (D. BILIRUBIN)	0.14	mg/dl	0.00 - 0.3
UNCONJUGATED (I.D.BILIRUBIN)	0.60	mg/dl	0.2 - 0.9
SGOT / AST	17.20	IU/L	0 - 35
SGPT / ALT	27.1	IU/L	0 - 35
ALKALINE PHOSPHATASE	96.20	U/L	64 - 306
TOTAL PROTEIN	7.14	gm/dl	6.0 - 8.3
ALBUMIN	4.74	gm/dl	3.2 - 5.0
GLOBULIN	4.74	gm/dl	2.5 - 5.6
A/G RATIO	1.00		0.9 - 2.0
GAMMA GT	20.10	IU/L	0.0 - 35.0

Pap Smear (Above 40 years)  
Urine Routine Examination

**PHYSICAL EXAMINATION**

QUANTITY	20	ml.	
COLOUR	Pale Yellow		Pale Yellow
TRANSPARENCY	Clear		
SPECIFIC GRAVITY	1.025		
PH	6.0		

**CHEMICAL EXAMINATION**

ALBUMIN	Trace
SUGAR	Nil

Checked by : \_\_\_\_\_  
Page 3 Contd...4

If test results are alarming or unexpected, patient is advised to contact the laboratory immediately for possible remedial action.

**Facilities Available**

- Multispeciality Hospital - 24 Hours Emergency - X-Ray/ ECG/ Ultrasound/ CT Scan - Dental- Fully Equipped Operation Theatre  
- Fully Functional Lab - 24/7 Casualty/ ICU-Nursery 24/7 Pharmacy - Labour Room - All Speciality OPD - Laproscopic Surgery -  
ECHO - Plastic Surgery



**LAB REPORT**

Reg. Date	02/08/2024	Patient Id	2408020009	DOB.	25/02/1971
Name	MRS. SONIA	Gender	F	Perm. ID	
Age	53 Yrs. 5 Mn. 7 Day	Panel	MEDIWHEEL	Reported	02/08/2024 17:39:57
Ref. By	MEDIWHEEL				

Test Name	Result	Units	Ref. Range
<b>MICROSCOPIC EXAMINATION</b>			
PUS CELLS	1-2	/HPF	
RBC'S	Nil	/HPF	
CASTS	Nil		
CRYSTALS	NIL		
EPITHELIAL CELLS	1-2	/HPF	
BACTERIA	Nil		
OTHERS	Nil		

**Dr. REEVA DAHIYA**  
 DR. REEVA DAHIYA  
 M.B.B.S, MD (Path)  
 Checked by : *[Signature]*  
 Malik Radix Healthcare Pvt. Ltd.  
 C-217, C-218, Vikas Marg, Nirman Vihar, New Delhi-110092

**DR. MEENU AGGARWAL**  
 M.B.B.S, MD (Path.)

If test results are alarming or unexpected, patient is advised to contact the laboratory immediately for possible remedial action.

**Facilities Available**

- Multispeciality Hospital - 24 Hours Emergency - X-Ray/ ECG/ Ultrasound/ CT Scan - Dental- Fully Equipped Operation Theatre
- Fully Functional Lab - 24/7 Casualty/ ICU-Nursery 24/7 Pharmacy - Labour Room - All Speciality OPD - Laproscopic Surgery - ECHO - Plastic Surgery

R

SONIA ... CHEST PA 02-08-2024 ...  
RADIX HEALTH CARE ... NIRMAN VIHAR PH. 22011198



UHID	PT218683	LAB No.	XRY2315087
Name	Mrs. SONIA	Regn. No.	GEN2416116
Age / Sex	53 Yrs / F	Receiving Dt/Time	02-Aug-2024 11:37
		Reporting Dt/Time	02-Aug-2024 04:47 PM



**XRAY**

CHEST (PA)

**B/L Prominent bronchovascular marking seen.**

Cp angles are clear.

Hila are normal...

Heart size appears within normal limits.

Soft tissue shadows and bony thorax are normal.

Advised....please correlate clinically.

\*\*\*\*\* END OF REPORT \*\*\*\*\*

Approved By :

DR. K. K. SINHA  
 M.B.B.S. D.M.R.D.  
 SENIOR CONSULTANT  
 Reg. No. 26437 (DMC)

DR. RAJESH MALHOTRA  
 MBBS, MD (RADIOLOGY)  
 CONSULTANT RADIOLOGY  
 Reg.No.DMC9299

DR. T. K VOHRA  
 MD (RADIODIAGNOSIS)  
 SENIOR CONSULTANT  
 Reg. No. 3272 (DMC)

Approval Date :

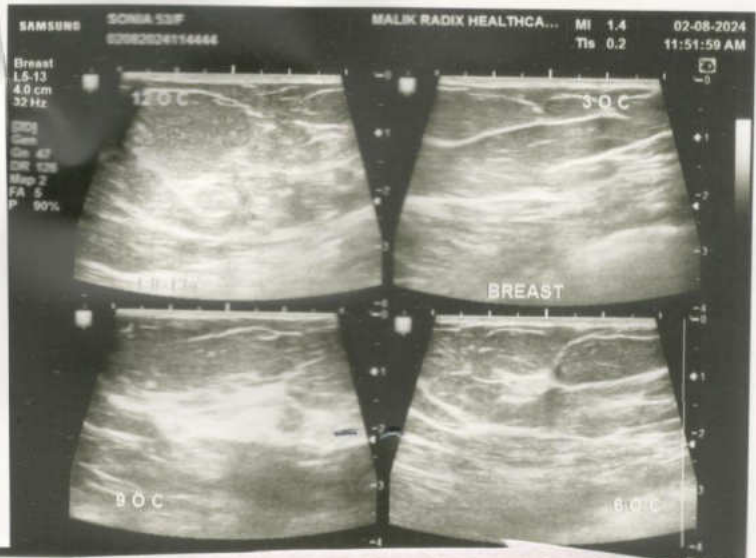
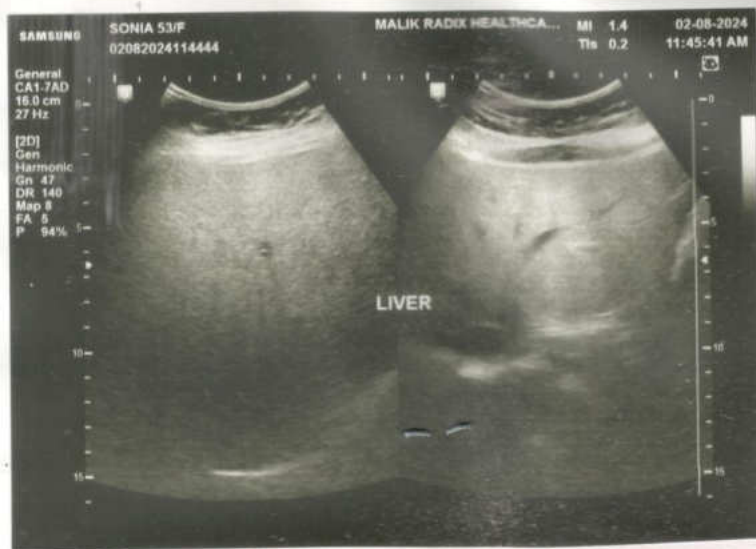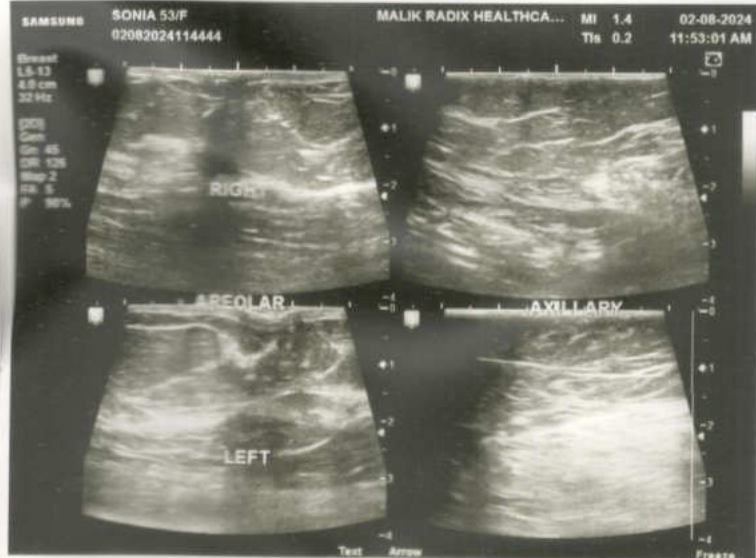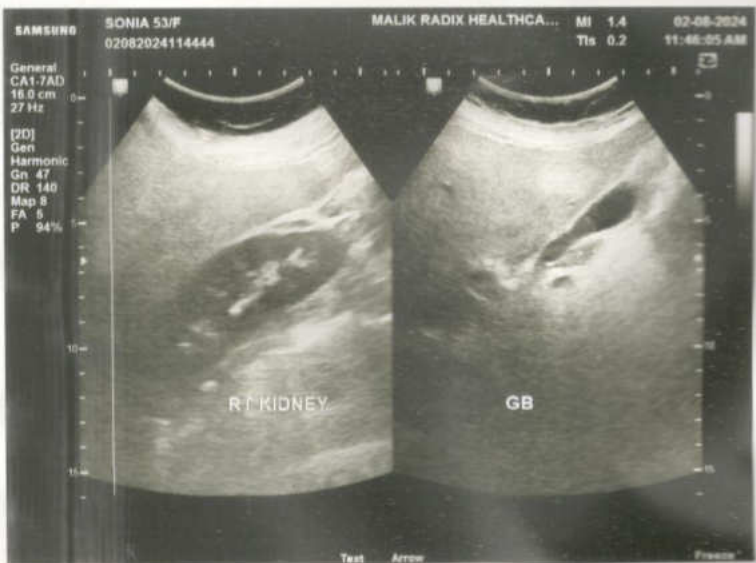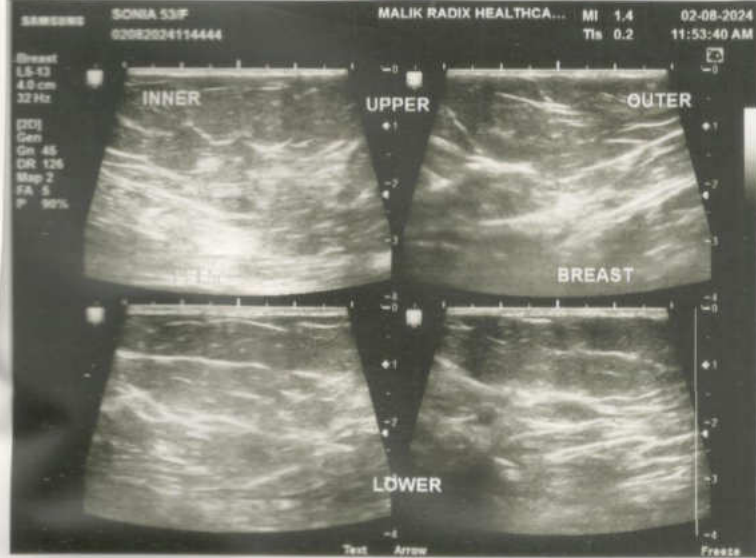
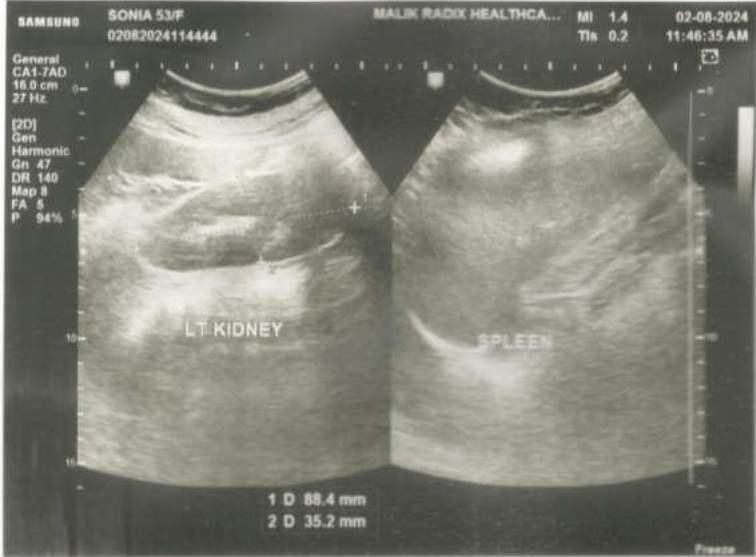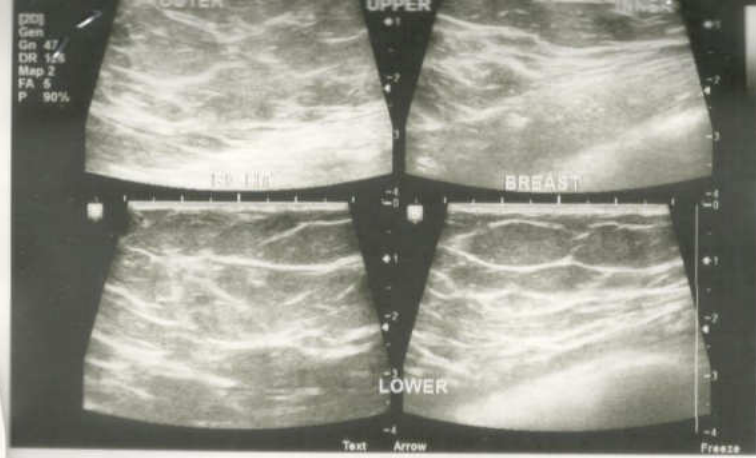
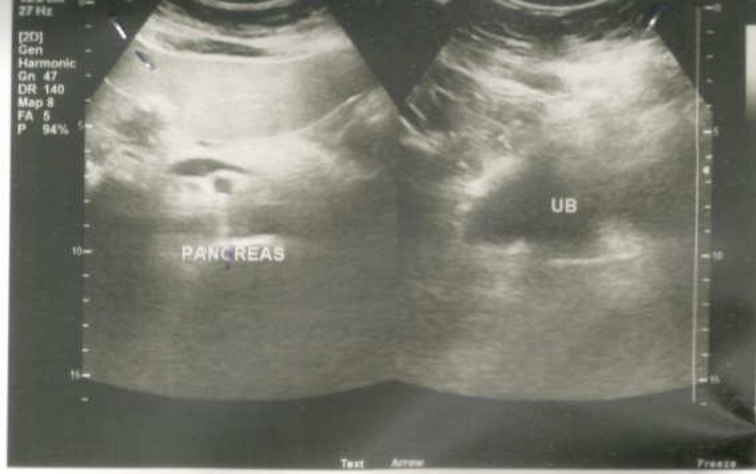00:00:00

DR. MUKESH KOSHAL  
 MBBS, MD (RADIOLOGY)  
 CONSULTANT RADIOLOGY  
 Reg.No.DMC10407

DR. SHREYASH TIWARY  
 MBBS, MD (RADIOLOGY)  
 CONSULTANT RADIOLOGY  
 Reg.No.DMC85802

**Facilities Available**

- Multispeciality Hospital - 24 Hours Emergency - X-Ray/ ECG/ Ultrasound/ CT Scan - Dental - Fully Equipped Operation Theatre
- Fully Functional Lab - 24/7 Casualty/ ICU-Nursery 24/7 Pharmacy - Labour Room - All Speciality OPD - Laproscopic Surgery - ECHO - Plastic Surgery





<b>NAME</b>	<b>MRS SONIA</b>	<b>AGE</b>	<b>53 Y/F</b>
<b>REFD. BY.</b>	<b>HEALTH CHECK UP</b>	<b>DATE</b>	<b>02.08.24</b>

**Ultrasound Examination of Whole Abdomen & Pelvis :**

**Liver:** Liver shows grade I fatty changes . No focal SOL is seen in liver. IHBR & portal radicles are normal.

**Gallbladder:** Gallbladder shows normal anechoic pattern. No evidence of cholecystitis or cholelithiasis seen. Common bile duct is normal in course & caliber.

**Pancreas:** Pancreas shows normal size & echotexture.

**Spleen:** Spleen shows normal size, outline & echotexture.

**Kidneys:** Kidneys show normal size, shape, position & echotexture. No calculus, hydronephrosis or SOL is seen in kidneys. Cortico- medullary differentiation and cortical thickness is normal on both sides.

No supra- renal mass seen.

Great abdominal vessels are normal.

Domes of diaphragm are seen to move normally & synchronously in respiration. No supra- or infra diaphragmatic collection is seen.

No ascites or pericardial effusion seen.

No para aortic lymph nodes seen.

**Urinary bladder:** Urinary bladder shows normal anechoic pattern. No calculus, SOL or diverticulum seen.

**Uterus:** Uterus is not visualized (Posthysterectomy)

**IMP- GRADE I FATTY LIVER**

Regards.

**Dr Mukesh Koshal MD ( Rad- diag)**

Regn. No. DMC 10407

**RADIOLOGIST :**

**Facilities Available**