


Name : Mr. Anand Sugate	Age : 36 Y	UHID :SPUN.0000046107
Address : Belgaum	Sex : M	
Plan : ARCOFEMI MEDIWHEEL MALE AHC CREDIT PAN INDIA OP AGREEMENT		OP Number :SPUNOPV60811
		Bill No :SPUN-OCR-10175
		Date : 27.01.2024 12:46

Sno	Service Type/ServiceName	Department
1	ARCOFEMI - MEDIWHEEL - FULL BODY ANNUAL PLUS MALE - 2D ECHO - PAN INDIA - FY2324	
<input checked="" type="checkbox"/>	1 URINE GLUCOSE(FASTING)	
<input checked="" type="checkbox"/>	2 GAMMA GLUTAMYL TRANSFERASE (GGT)	
<input checked="" type="checkbox"/>	3 HbA1c, GLYCATED HEMOGLOBIN	
<input checked="" type="checkbox"/>	4 2 D ECHO	
<input checked="" type="checkbox"/>	5 LIVER FUNCTION TEST (LFT)	
<input checked="" type="checkbox"/>	6 X-RAY CHEST PA	
<input checked="" type="checkbox"/>	7 GLUCOSE, FASTING	
<input checked="" type="checkbox"/>	8 HEMOGRAM - PERIPHERAL SMEAR	
<input checked="" type="checkbox"/>	9 ENT CONSULTATION	
<input checked="" type="checkbox"/>	10 FITNESS BY GENERAL PHYSICIAN	
<input checked="" type="checkbox"/>	11 DIET CONSULTATION	
<input checked="" type="checkbox"/>	12 COMPLETE URINE EXAMINATION	
<input checked="" type="checkbox"/>	13 URINE GLUCOSE(POST PRANDIAL)	
<input checked="" type="checkbox"/>	14 PERIPHERAL SMEAR	
<input checked="" type="checkbox"/>	15 ECG	
<input checked="" type="checkbox"/>	16 BLOOD GROUP ABO AND RH FACTOR	
<input checked="" type="checkbox"/>	17 LIPID PROFILE	
<input checked="" type="checkbox"/>	18 BODY MASS INDEX (BMI)	
<input checked="" type="checkbox"/>	19 OPHTHAL BY GENERAL PHYSICIAN	
<input checked="" type="checkbox"/>	20 RENAL PROFILE/RENAL FUNCTION TEST (RFT/KFT)	
<input checked="" type="checkbox"/>	21 ULTRASOUND - WHOLE ABDOMEN	
<input checked="" type="checkbox"/>	22 THYROID PROFILE (TOTAL T3, TOTAL T4, TSH)	
<input checked="" type="checkbox"/>	23 DENTAL CONSULTATION	
<input checked="" type="checkbox"/>	24 GLUCOSE, POST PRANDIAL (PP), 2 HOURS (POST MEAL)	

CERTIFICATE OF MEDICAL FITNESS

This is to certify that I have conducted the clinical examination

of Anand Sugate on 27/01/24

After reviewing the medical history and on clinical examination it has been found that he/she is

	Tick
<ul style="list-style-type: none">• Medically Fit	<input checked="" type="checkbox"/>
<ul style="list-style-type: none">• Fit with restrictions/recommendations <p>Though following restrictions have been revealed, in my opinion, these are not impediments to the job.</p> <p>1.....</p> <p>2.....</p> <p>3.....</p> <p>However the employee should follow the advice/medication that has been communicated to him/her.</p> <p>Review after _____</p>	<input type="checkbox"/>
<ul style="list-style-type: none">• Currently Unfit. <p>Review after _____ recommended</p>	<input type="checkbox"/>
<ul style="list-style-type: none">• Unfit	<input type="checkbox"/>

Dr. Samrat Shah 
General Physician
Apollo Spectra Hospital Pune

This certificate is not meant for medico-legal purposes

Dr. Samrat Shah
MBBS MD
Reg No. 2021097302
Consultant Internal Medicine
Apollo Speciality Hospital

Date : 27/01/24
MRNO :
Name : Anand Sugate
Age/Gender :
Mobile No : 3617

Department : Gen Physician
Consultant :
Reg. No : Dr. Samrat Shah
Qualification :
Consultation Timing :

SPO2 100%

Pulse : 64/min	B.P : 110/70	Resp : 16/min	Temp : 98.6
Weight : 70.7 kg	Height : 170 cm	BMI : 24.4	Waist Circum : -

General Examination / Allergies
History

Clinical Diagnosis & Management Plan

Renal calculi ⊕

found fit to join duty

Follow up date:

Dr. Samrat Shah
MBBS MD
Reg No. 2021097302
Consultant Internal Medicine
Apollo Speciality Hospital
Doctor Signature

2D ECHO / COLOUR DOPPLER

Name : Mr. Anand Sugate
Ref by : HEALTH CHECKUP

Age : 36YRS / M
Date : 27/01/2024

LA – 32 AO – 26 IVS – 10 PW – 10
LVIDD – 37 LVIDS - 25
EF 60 %

Normal LV size and systolic function.
No diastolic dysfunction
Normal LV systolic function, LVEF 60 %
No regional wall motion abnormality
Normal sized other cardiac chambers.
Mitral valve has thin leaflets with normal flow.
Aortic valve has three thin leaflets with normal structure and function. No aortic regurgitation.No LVOT gradient
Normal Tricuspid & pulmonary valves.
No tricuspid regurgitation.
PA pressures Normal
Intact IAS and IVS.
No clots, vegetations, pericardial effusion noted.

IMPRESSION :
NORMAL LV SYSTOLIC AND DIASTOLIC FUNCTION.
NO RWMA. NO PULMONARY HTN
NO CLOTS/VEGETATIONS



DR.SAMRAT SHAH
MD, CONSULTANT PHYSICIAN

MR. ANAND SUGATE
36 Years.

MR No:
Location:

SPUN.0000046707
Apollo Spectra Hospital, Pune
(Swargate) **DIAGNOSTICS**
Expertise. Empowering you.

Gender: M
Image Count: 1
Arrival Time: 27-Jan-2024 13:10

Physician: SELF
Date of Exam: 27-Jan-2024
Date of Report: 27-Jan-2024 14:24

X-RAY CHEST PA VIEW

FINDINGS

Normal heart and mediastinum.
There is no focal pulmonary mass lesion is seen.
No collapse or consolidation is evident.
The apices, costo and cardiophrenic angles are free.
No hilar or mediastinal lymphadenopathy is demonstrated.
There is no pleural or pericardial effusion.
No destructive osseous pathology is evident.

IMPRESSION:

No significant abnormality is seen.



Dr. Santhosh Kumar DMRD, DNB
Consultant Radiologist
Reg.No: 59248

CONFIDENTIALITY:

This transmission is confidential. If you are not the intended recipient, please notify us immediately. Any disclosure, distribution or other action based on the contents of this report may be unlawful.

PLEASE NOTE:

This radiological report is the professional opinion of the reporting radiologist based on the interpretation of the images and information provided at the time of reporting. It is meant to be used in correlation with other relevant clinical findings.



Name	Mr Anand Mahadev Sugate	Age	36 Years
Patient ID	DD/271/2023-2024/1246	Gender	MALE
Ref By	Dr. Apollo Spectra Hospital	Date	27/01/2024

SONOGRAPHY OF ABDOMEN AND PELVIS

The liver appears normal in size, shape and echotexture. No focal lesion is seen. The hepatic venous radicals and intrahepatic biliary tree appear normal. The portal vein and CBD appears normal.

The gall bladder is normal in size with a normal wall thickness and there are no calculi seen in it. No pericholecystic collection seen.

The pancreas appear normal in size and echotexture.

The spleen appears normal in size and echotexture.

The right kidney measures 9.9x4.5 cms and shows a 4 mm calculus in the lower pole.

The left kidney measures 9.1x4.5cms. Both kidneys appear normal in size, shape & echotexture. There is no hydronephrosis or calculus seen on either side.

The urinary bladder distends well and is normal in shape and contour. No intrinsic lesion or calculus is seen in it. The bladder wall is of normal thickness.

The prostate is normal in size, shape and echotexture. No focal lesion is seen.

There is no free fluid or paraaortic lymphadenopathy seen.

IMPRESSION:

**A 4 mm calculus in the lower pole of right kidney.
No other significant abnormality is noted.**

Dr. Lalitkumar S Deore
MD(Radiology) (2001/04/1871)

Powered By Omniview

EYE REPORT

Name: Mr. Anand Sugale

Age / Sex: 36 y / M

Ref No.:

Complaint: No complaints

Examination

NO DM

NO HTN

Unaided Vision
R 6/6 N6
L 6/6 N6

Spectacle Rx

	Right Eye				Left Eye			
	Vision	Sphere	Cyl.	Axis	Vision	Sphere	Cyl.	Axis
Distance	6/6	Plano	—	—	6/6	Plano	—	—
Read	—	—	—	N6	—	—	—	N6
	Sphere	CYL	Axis	Vision	Sphere	CYL	Axis	Vision

Remarks:

PGP
 R
 L

Medications: ∴ BE colour Blindness (Abnormal)

Trade Name	Frequency	Duration

Follow up: 1 yr

Consultant: 

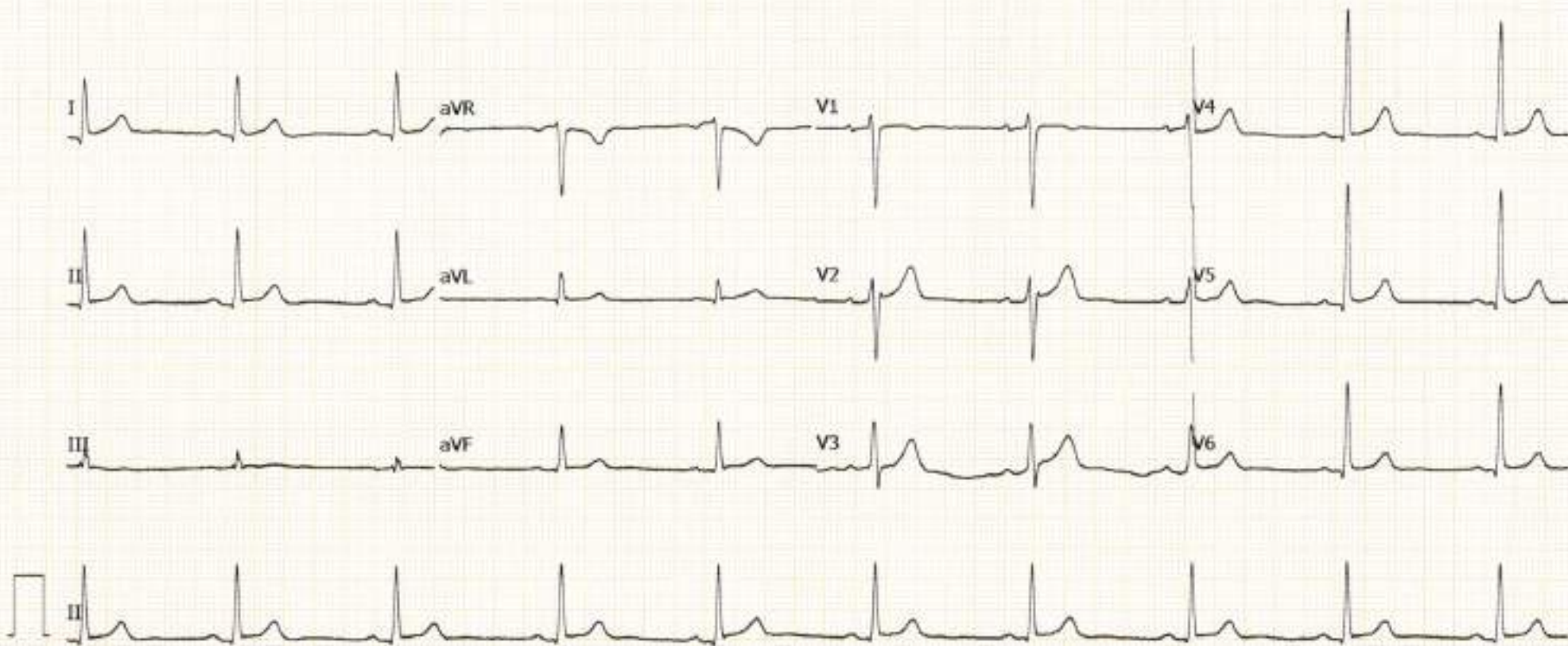
Apollo Spectra Hospitals

170 cm Male
70.0 kg

Technician:
Ordering Ph:
Referring Ph:
Attending Ph:

QRS : 90 ms
QT / QTcBaz : 388 / 377 ms
PR : 158 ms
P : 96 ms
RR / PP : 1046 / 1052 ms
P / QRS / T : 40 / 42 / 35 degrees

Sinus bradycardia
Minimal voltage criteria for LVH, may be normal variant
Borderline ECG



Appointment Id	Corporate Name	Name	Email id	Mobile
CORPAHC1001242594	BETACURA HEALTH SOLUTIONS PRIV	DINESH RAMKISAN DHUT	care@betacura.com Aishwarya.jha@betacura.com	9619394272 BETACU
CORPAHC1001242602	BETACURA HEALTH SOLUTIONS PRIV	MADHURI DINESH DHUT	care@betacura.com Aishwarya.jha@betacura.com	9619394272 BETACU
59568	VISIT HEALTH PRIVATE LIMITED	Mr Amit Dudhane	ariko.sarkar@getvisitapp.com	9960567567 VISIT HE
59567	VISIT HEALTH PRIVATE LIMITED	Mrs. Snehal Dudhane	ariko.sarkar@getvisitapp.com	9960567567 VISIT HE
59572	ARCOFEMI HEALTHCARE LIMITED	MR. SUGATE ANAND	sukteanant@gmail.com	9080641909 ARCOFEM
APTL4MZY5INB	AAYUV TECHNOLOGIES PRIVATE LIM	Susan kanitkar	customercareservice@ekincare.com	9081095645 AAYUV TE
57453	INDUS HEALTH PLUS PRIVATE LIM	SHARAD SABALE	info@indushealthplus.com	9049904526 INDUS +
55075	PROGNOCHEALTH SOLUTIONS INDIA P	Rachana Shah	prognochealth.com@app.prognochealth.com	5822118371 PROGNO
907C05B1BF23C	CONNECT AND HEAL PRIMARY CARE	Pawan Kumar Singh	reports@connectandheal.com	8910117061 CONNECT

DL No: KA22 20110012906 DOI: 03/11/2011 FORM: 7
NAME: ANAND SUGATE (See Rule 163B)
D.O.B: 12/09/1987 S.O.
VALID TILL: 02/11/2031(NT)




VALID THROUGHOUT INDIA

COV: MCWG 03/11/2011
LMV 03/11/2011

DOI: 03/11/2011

S/O: MAHADEV
ADDRESS: C/O BHATHKANDI COMPOUND, HINDU
NAGAR, TILAKWADI, TG DIST BELGAUM


Sign. Of Holder


Sign. Licensing Authority
BELGAUM (KA22)

Customer Pending Tests- All Blood and Urine Test not done because client is not willing to do blood test also he is not in fasting.
ENT and Dental service not available in Apollo