



Patient Name : Mrs.DEVIKA T D	Collected : 09/Nov/2024 08:53AM
Age/Gender : 32 Y 3 M 2 D/F	Received : 09/Nov/2024 11:57AM
UHID/MR No : CIND.0000173134	Reported : 09/Nov/2024 01:09PM
Visit ID : CINDOPV244815	Status : Final Report
Ref Doctor : Self	Sponsor Name : ARCOFEMI HEALTHCARE LIMITED
Emp/Auth/TPA ID : 22E37885	

**DEPARTMENT OF HAEMATOLOGY**

**ARCOFEMI - MEDIWHEEL - FULL BODY HEALTH ANNUAL PLUS CHECK - FEMALE - 2D ECHO - PAN INDIA - FY2324**


PLATELETS: appear adequate in number.

HEMOPARASITES: negative

**IMPRESSION: NORMOCYTIC NORMOCHROMIC BLOOD PICTURE WITH MILD EOSINOPHILIA.**



Dr. Vidya Aniket Gore  
M.B.B.S,M.D(Pathology)  
Consultant Pathologist



Dr Priya Murthy  
M.B.B.S,M.D(Pathology)  
Consultant Pathologist





Patient Name : Mrs.DEVIKA T D	Collected : 09/Nov/2024 08:53AM
Age/Gender : 32 Y 3 M 2 D/F	Received : 09/Nov/2024 12:32PM
UHID/MR No : CIND.0000173134	Reported : 09/Nov/2024 12:48PM
Visit ID : CINDOPV244815	Status : Final Report
Ref Doctor : Self	Sponsor Name : ARCOFEMI HEALTHCARE LIMITED
Emp/Auth/TPA ID : 22E37885	

**DEPARTMENT OF BIOCHEMISTRY**

**ARCOFEMI - MEDIWHEEL - FULL BODY HEALTH ANNUAL PLUS CHECK - FEMALE - 2D ECHO - PAN INDIA - FY2324**

Test Name	Result	Unit	Bio. Ref. Interval	Method
GLUCOSE, FASTING , NAF PLASMA	109	mg/dL	70-100	HEXOKINASE


**Comment:**

As per American Diabetes Guidelines, 2023

Fasting Glucose Values in mg/dL	Interpretation
70-100 mg/dL	Normal
100-125 mg/dL	Prediabetes
≥126 mg/dL	Diabetes
<70 mg/dL	Hypoglycemia

**Note:**

- 1.The diagnosis of Diabetes requires a fasting plasma glucose of > or = 126 mg/dL and/or a random / 2 hr post glucose value of > or = 200 mg/dL on at least 2 occasions.
2. Very high glucose levels (>450 mg/dL in adults) may result in Diabetic Ketoacidosis & is considered critical.

  
 Dr Priya Murthy  
 M.B.B.S.,M.D(Pathology)  
 Consultant Pathologist















Patient Name : Mrs.DEVIKA T D	Collected : 09/Nov/2024 08:53AM
Age/Gender : 32 Y 3 M 2 D/F	Received : 09/Nov/2024 11:24AM
UHID/MR No : CIND.0000173134	Reported : 09/Nov/2024 12:11PM
Visit ID : CINDOPV244815	Status : Final Report
Ref Doctor : Self	Sponsor Name : ARCOFEMI HEALTHCARE LIMITED
Emp/Auth/TPA ID : 22E37885	

**DEPARTMENT OF BIOCHEMISTRY**

**ARCOFEMI - MEDIWHEEL - FULL BODY HEALTH ANNUAL PLUS CHECK - FEMALE - 2D ECHO - PAN INDIA - FY2324**

Test Name	Result	Unit	Bio. Ref. Interval	Method
<b>RENAL PROFILE/KIDNEY FUNCTION TEST (RFT/KFT) , SERUM</b>				
CREATININE	0.84	mg/dL	0.66 - 1.09	Modified Jaffe, Kinetic
UREA	21.90	mg/dL	17-43	GLDH, Kinetic Assay
BLOOD UREA NITROGEN	10.2	mg/dL	8.0 - 23.0	Calculated
URIC ACID	4.13	mg/dL	2.6-6.0	Uricase PAP
CALCIUM	9.90	mg/dL	8.8-10.6	Arsenazo III
PHOSPHORUS, INORGANIC	<b>4.57</b>	mg/dL	2.5-4.5	Phosphomolybdate Complex
SODIUM	<b>135</b>	mmol/L	136-146	ISE (Indirect)
POTASSIUM	4.2	mmol/L	3.5-5.1	ISE (Indirect)
CHLORIDE	103	mmol/L	101-109	ISE (Indirect)
PROTEIN, TOTAL	7.58	g/dL	6.6-8.3	Biuret
ALBUMIN	4.49	g/dL	3.5-5.2	BROMO CRESOL GREEN
GLOBULIN	3.09	g/dL	2.0-3.5	Calculated
A/G RATIO	1.45		0.9-2.0	Calculated

Dr.Govinda Raju N L  
MSc,PhD(Biochemistry)  
Consultant Biochemistry

Dr Priya Murthy  
M.B.B.S,M.D(Pathology)  
Consultant Pathologist



SIN No:IRA241100854

This test has been performed at Apollo Health & Lifestyle Ltd, RRL BANGALORE Laboratory

APOLLO HEALTH AND LIFESTYLE LIMITED - RRL BANGALORE  
Apollo Health and Lifestyle Limited  
Regd. Office: 10, 82nd, Anand Nagar, 4th Cross, 4th Stage, Mysore Road, Bangalore, Karnataka, India. | 560029  
www.apolloclinic.com | Email: info@apolloclinic.com, Ph: No: 080-4664 7777, Fax: No: 4664 7766

APOLLO CLINIC  
Apollo Clinic, 2nd Stage, 4th Cross, Anand Nagar, Bangalore, Karnataka, India. | 560029  
www.apolloclinic.com | Email: info@apolloclinic.com, Ph: No: 080-4664 7777, Fax: No: 4664 7766









Patient Name : Mrs.DEVIKA T D	Collected : 09/Nov/2024 08:53AM
Age/Gender : 32 Y 3 M 2 D/F	Received : 09/Nov/2024 11:23AM
UHID/MR No : CIND.0000173134	Reported : 09/Nov/2024 01:30PM
Visit ID : CINDOPV244815	Status : Final Report
Ref Doctor : Self	Sponsor Name : ARCOFEMI HEALTHCARE LIMITED
Emp/Auth/TPA ID : 22E37885	

**DEPARTMENT OF IMMUNOLOGY**

**ARCOFEMI - MEDIWHEEL - FULL BODY HEALTH ANNUAL PLUS CHECK - FEMALE - 2D ECHO - PAN INDIA - FY2324**

High	High	High	High	Pituitary Adenoma; TSHoma/Thyrotropinoma
------	------	------	------	--

  
**Dr.Govinda Raju N L**  
 MSc,PhD(Biochemistry)  
 Consultant Biochemistry

  
**Dr Priya Murthy**  
 M.B.B.S,M.D(Pathology)  
 Consultant Pathologist



SIN No:IRA241100857

This test has been performed at Apollo Health & Lifestyle Ltd, RRL BANGALORE Laboratory

APOLLO HEALTH AND LIFESTYLE LIMITED - RRL BANGALORE  
 Apollo Health and Lifestyle Limited  
 Regd. Office: 10/22/20, Anand Nagar, 4th Cross, 4th Stage, 4th Cross, Anand Nagar, 4th Stage, 4th Cross, Anand Nagar, Bangalore - 560016  
 www.apolloclinic.com | Email ID: rrl@apolloclinic.com, Ph No: 080-4664 7777, Fax No: 4664 7766

APOLLO HEALTH AND LIFESTYLE LIMITED - RRL BANGALORE  
 Apollo Health and Lifestyle Limited  
 Regd. Office: 10/22/20, Anand Nagar, 4th Cross, 4th Stage, 4th Cross, Anand Nagar, Bangalore - 560016  
 www.apolloclinic.com | Email ID: rrl@apolloclinic.com, Ph No: 080-4664 7777, Fax No: 4664 7766















---

Patient Name	: Mrs. Devika T D	Age	: 32Yrs 3Mths 3Days
UHID	: CIND.0000173134	OP Visit No.	: CINDOPV244815
Printed On	: 09-11-2024 07:00 AM	Advised/Pres Doctor	: --
Department	: Radiology	Qualification	: --
Referred By	: Self	Registration No.	: --
Employer Id	: 22E37885		

---

## DEPARTMENT OF RADIOLOGY

---

### ULTRASOUND ABDOMEN AND PELVIS

**LIVER:** Appears normal in size, shape and echopattern. No focal parenchymal lesions identified. No evidence of intra/extrahepatic biliary tree dilatation noted. Portal vein appears to be of normal size.

**GALLBLADDER:** Moderately distended. No definite calculi identified. No evidence of abnormal wall thickening noted.

**SPLEEN:** Appears normal in size, shape and echopattern. No focal parenchymal lesions identified.

**PANCREAS:** Obscured by bowel gas. However, the visualized portion appear normal.

**KIDNEYS:** Both kidneys appear normal in size, shape and echopattern. Corticomedullary differentiation appears maintained. No evidence of calculi or hydronephrosis on either side.

**URINARY BLADDER:** Distended and appears normal. No evidence of abnormal wall thickening noted.

**UTERUS:** Anteverted and appears normal in size. Myometrial echoes appear normal. The endometrial lining appears intact. Endometrium measures 7 mm.

**OVARIES:** Both ovaries appearing normal in size and echopattern.

No free fluid is seen.

---

**IMPRESSION:**

**NO SIGNIFICANT SONOGRAPHIC ABNORMALITY DETECTED.**

---End Of The Report---



Dr.DHANALAKSHMI B  
MBBS, DMRD  
29543  
Radiology

Patient Name	: Mrs. Devika T D	Age	: 32Yrs 3Mths 6Days
UHID	: CIND.0000173134	OP Visit No.	: CINDOPV244815
Printed On	: 12-11-2024 07:06 AM	Advised/Pres Doctor	: --
Department	: Cardiology	Qualification	: --
Referred By	: Self	Registration No.	: --
Employer Id	: 22E37885		

## DEPARTMENT OF CARDIOLOGY

### ECG

#### Observation :-

1. Normal Sinus Rhythm.
2. Heart rate is Normal
3. No pathological Q wave or ST-T changes seen.
4. Normal P,QRS,T waves and axis.
5. No evidence of chamber, hypertrophy or enlargement seen.

#### Impression:-

NORMAL RESTING ECG.

**NOTE:-**KINDLY TAKE A PHOTOCOPY OF THE GRAPH FOR FUTURE REFERENCE IF NEEDED

---End Of The Report---



Dr.M SUDHAKAR RAO  
MBBS, MD, DM (Cardio)  
0000018  
Cardiology



---

Patient Name	: Mrs. Devika T D	Age	: 32Yrs 3Mths 5Days
UHID	: CIND.0000173134	OP Visit No.	: CINDOPV244815
Printed On	: 11-11-2024 11:52 AM	Advised/Pres Doctor	: --
Department	: Cardiology	Qualification	: --
Referred By	: Self	Registration No.	: --
Employer Id	: 22E37885		

---

**DEPARTMENT OF CARDIOLOGY**

---

**M mode and doppler measurements:**

**CM    CM            M/sec**

**AO: 2.3 IVS(D): 0.9    MV: E Vel: 0.7 A Vel : 0.4**

**LA: 2.5 LVIDD(D): 3.5 AV Peak: 0.6**

**LVPW(D): 0.8 PV peak: 0.6**

**IVS(S): 1.0**

**LVID(S): 2.2**

**LVPW(S): 1.1**

**LVEF: 60%**

**Descriptive findings:**

**Left Ventricle    Normal**

**Right Ventricle: Normal**

**Left Atrium:     Normal**

**Right Atrium:    Normal**

**Mitral Valve:    Normal**

**Aortic Valve:    Normal**

**Tricuspid Valve: Normal**

**IAS:                Normal**

---

---

IVS:	Normal
Pericardium:	Normal
IVC:	Normal
Others	---

**IMPRESSION :**

Normal cardiac chamber and valves  
No Regional wall motion abnormality  
Normal PA pressure  
No clot/vegetation/pericardial effusion  
Normal LV systolic function - LVEF= 60%

**DR JAGADEESH H V MD,DM**  
**CONSULTANT CARDIOLOGIST**

---End Of The Report---



Dr.JAGADEESH H V

---

---

MBBS, MD, DM  
86848  
Cardiology

Patient Name	: Mrs. Devika T D	Age	: 32Yrs 3Mths 3Days
UHID	: CIND.0000173134	OP Visit No.	: CINDOPV244815
Printed On	: 09-11-2024 12:09 PM	Advised/Pres Doctor	: --
Department	: Radiology	Qualification	: --
Referred By	: Self	Registration No.	: --
Employer Id	: 22E37885		

---

**DEPARTMENT OF RADIOLOGY**

---

**X-RAY CHEST PA VIEW**

Both lung fields and hila are normal .

No obvious active pleuro-parenchymal lesion seen .

Both costophrenic and cardiophrenic angles are clear .

Both diaphragms are normal in position and contour .

Thoracic wall and soft tissues appear normal.

**CONCLUSION :**

**No obvious abnormality seen**

For clinical correlation.

---End Of The Report---



Dr.DHANALAKSHMI B  
MBBS, DMRD  
29543  
Radiology

Name : Mrs. Devika T D

Age : 32Y 3M 2D

UHID : CIND.0000173134

Address : Hulsur Bazaar Bangalore Karnataka INDIA 560008

sex : Female



CIND.0000173134

Plan : ARCOFEMI MEDIWHEEL FEMALE AHC  
CREDIT PAN INDIA OP AGREEMENT

OP No: CINDOPV244815

Bill No: CIND-OCR-103587

Date: Nov 9th, 2024, 8:37 AM

Sno.	Service Type/Service Name	Department	
1	ARCOFEMI - MEDIWHEEL - FULL BODY HEALTH ANNUAL PLUS CHECK - FEMALE - 2D ECHO - PAN INDIA - FY2324		
1	ULTRASOUND - WHOLE ABDOMEN - 9	Ultrasound Radiology	<input type="checkbox"/>
2	OPHTHAL BY GENERAL PHYSICIAN - 5 after 10 am	Consultation	<input type="checkbox"/>
3	URINE GLUCOSE(POST PRANDIAL)	Clinical Pathology	<input type="checkbox"/>
4	GAMMA GLUTAMYL TRANSFERASE (GGT)	Biochemistry	<input type="checkbox"/>
5	HbA1c, GLYCATED HEMOGLOBIN	Biochemistry	<input type="checkbox"/>
6	GYNAECOLOGY CONSULTATION - 3 after 11 am	Consultation	<input type="checkbox"/>
7	DIET CONSULTATION	General	<input type="checkbox"/>
8	BODY MASS INDEX (BMI) - 6	General	<input type="checkbox"/>
9	ECG - 6	Cardiology	<input type="checkbox"/>
10	THYROID PROFILE (TOTAL T3, TOTAL T4, TSH)	Biochemistry	<input type="checkbox"/>
11	2 D ECHO - 9 after 9:30 am	Cardiology	<input type="checkbox"/>
12	BLOOD GROUP ABO AND RH FACTOR	Blood Bank	<input type="checkbox"/>
13	X-RAY CHEST PA - 10	X Ray Radiology	<input type="checkbox"/>
14	URINE GLUCOSE(FASTING)	Clinical Pathology	<input type="checkbox"/>
15	LBC PAP TEST- PAPSURE - 3 after 11 am	Histopathology	<input type="checkbox"/>
16	FITNESS BY GENERAL PHYSICIAN	Consultation	<input type="checkbox"/>
17	GLUCOSE, POST PRANDIAL (PP), 2 HOURS (POST MEAL)	Biochemistry	<input type="checkbox"/>
18	GLUCOSE, FASTING	Biochemistry	<input type="checkbox"/>
19	ENT CONSULTATION	Consultation	<input type="checkbox"/>
20	LIPID PROFILE	Biochemistry	<input type="checkbox"/>
21	DENTAL CONSULTATION - 1 after 10 am	Consultation	<input type="checkbox"/>
22	HEMOGRAM + PERIPHERAL SMEAR	Haematology	<input type="checkbox"/>
23	PERIPHERAL SMEAR	Haematology	<input type="checkbox"/>
24	COMPLETE URINE EXAMINATION	Clinical Pathology	<input type="checkbox"/>
25	RENAL PROFILE/RENAL FUNCTION TEST (RFT/KFT)	Biochemistry	<input type="checkbox"/>
26	LIVER FUNCTION TEST (LFT)	Biochemistry	<input type="checkbox"/>



09.11.2024

173134  
Mrs. Devita T D

Height :	Weight :	BMI :	Waist Circum :
Temp :	Pulse :	Resp :	B.P :

General Examination / Allergies  
History

Clinical Diagnosis & Management Plan

Acropiani - AHe

Ears: NTD

Nose: NTD

Throat: NTD

Follow up date:

Dr. RAVINDRANATH Doctor Signature

M.B.B.S., D.L.O.

E.N.T. SURGEON

KMC REG. NO: 18554

BOOK YOUR APPOINTMENT TODAY!

Whatsapp Number : 970 100 3333

Toll Number : 1860 500 7788

Website : www.apolloclinic.com

Ms. Devika. T.D.  
17/134/ 32 yrs.

Gynecologist

Height : 160cm	Weight : 62-kg	BMI : 23.9 kg/m <sup>2</sup>	Waist Circum : 89cm
Temp : 97°F	Pulse : 73	Resp : 18/min	B.P : 112/78

General Examination / Allergies  
History

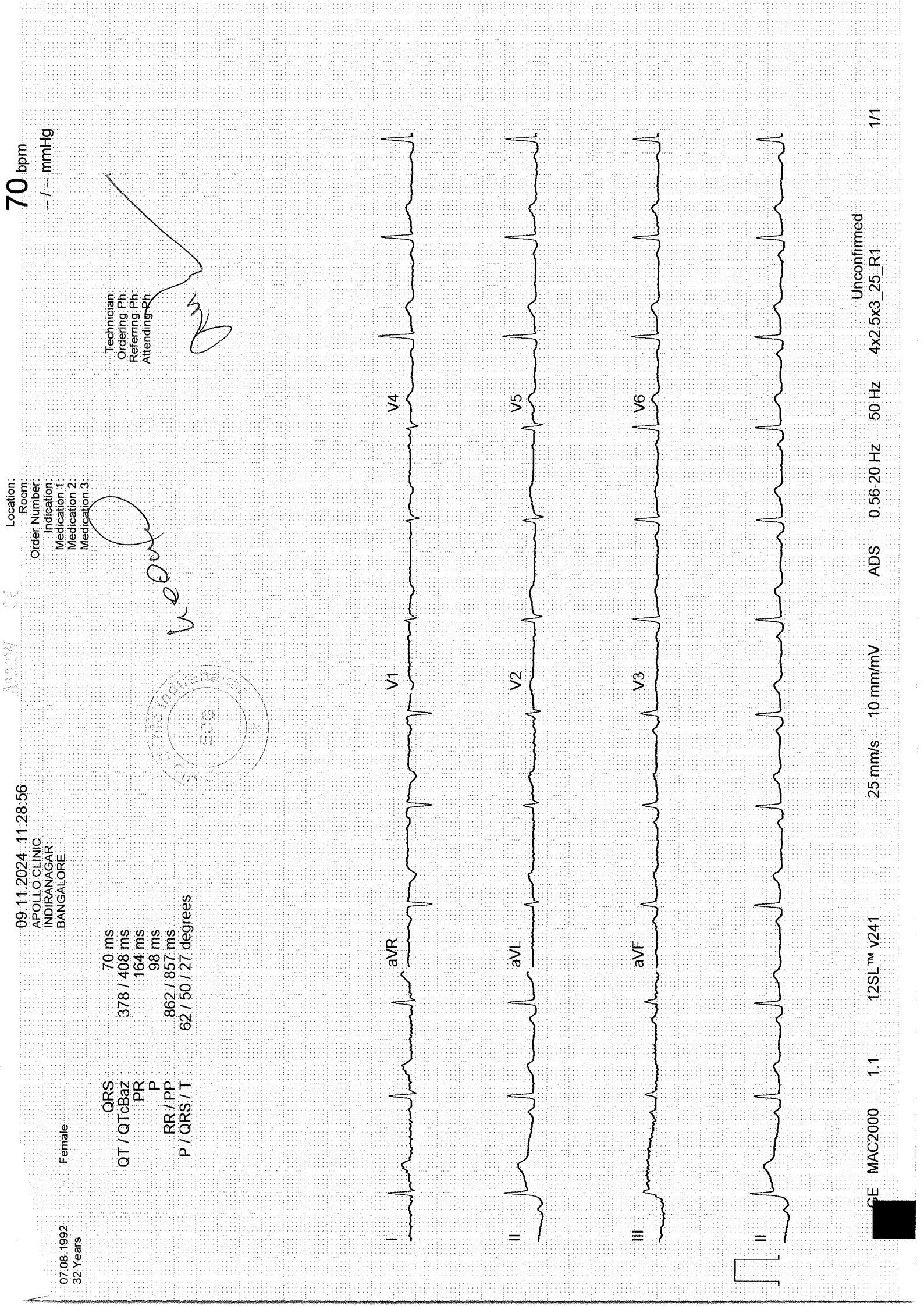
Nov 9/2024

Clinical Diagnosis & Management Plan

32 yrs, cycles regular 21-4  
LMP - 26<sup>th</sup> Oct  
LBR Pap Test  
Adv  
HAV vaccine  
Niramani  
Hygiene kit  
CCB - 3 yrs  
MVD  
P E  
PACON  
PS  
a health  
m n  
Bottle

Follow up date:

Doctor Signature



07.08.1992  
32 Years

Female

09.11.2024 11:28:56  
APOLLO CLINIC  
INDIRANAGAR  
BANGALORE

Location:  
Room:  
Order Number:  
Indication:  
Medication 1:  
Medication 2:  
Medication 3:

70 bpm  
- / - mmHg

Technician:  
Ordering Ph:  
Referring Ph:  
Attending Ph:

QRS : 70 ms  
QT / QTcBaz : 378 / 408 ms  
PR : 164 ms  
P : 98 ms  
RR / PP : 862 / 857 ms  
P / QRS / T : 62 / 50 / 27 degrees

Unconfirmed

ADS 0.56-20 Hz 50 Hz 4x2.5x3.25\_R1

25 mm/s 10 mm/mV 12SL™ V241 1/1

GE MAC2000 1.1

# Apollo Clinic

## CONSENT FORM

Patient Name: Devika. T. D Age: 32

UHID Number: ..... Company Name: Bank of Baroda.


I  Mr/Mrs/Ms Devika. T. D Employee of Bank of Baroda.

(Company) Want to inform you that I am ~~not~~ interested in getting the consultation on

Tests done which is a part of my routine health check package.

Opthal pending

And I claim the above statement in my full consciousness.

Patient Signature:  Date: 09/11/2021.

### Apollo Health and Lifestyle Limited

(CIN - U85110TG2000PLC115819)

Regd. Office: 1-10-60/62, Ashoka Raghupathi Chambers, 5th Floor, Begumpet, Hyderabad, Telangana - 500 016.

Ph No: 040-4904 7777, Fax No: 4904 7744 | Email ID: enquiry@apollohl.com | www.apollohl.com

APOLLO CLINICS NETWORK KARNATAKA

Bangalore (Basavanagudi | Bellandur | Electronic City | Fraser Town | HSR Layout | Indira Nagar | JP Nagar | Kundalahalli | Koramangala | Sarjapur Road) Mysore (VV Mohalla)

TO BOOK AN APPOINTMENT



NAME: Mrs. Devika T D	AGE/SEX: 32Y/F	OP NUMBER: 173134
Ref By : SELF	DATE: 09-11-2024	

**M mode and doppler measurements:**

CM	CM	M/sec	
AO: 2.3	IVS(D): 0.9	MV: E Vel: 0.7	A Vel : 0.4
LA: 2.5	LVIDD(D): 3.5	AV Peak: 0.6	
	LVPW(D): 0.8	PV peak: 0.6	
	IVS(S): 1.0		
	LVID(S): 2.2		
	LVPW(S): 1.1		
	LVEF: 60%		

**Descriptive findings:**

Left Ventricle	Normal
Right Ventricle:	Normal
Left Atrium:	Normal
Right Atrium:	Normal
Mitral Valve:	Normal
Aortic Valve:	Normal
Tricuspid Valve:	Normal
IAS:	Normal
IVS:	Normal
Pericardium:	Normal
IVC:	Normal
Others	---



**From:** Wellness : Mediwheel : New Delhi <wellness@mediwheel.in>

**Sent:** Tuesday, October 22, 2024 12:23 PM

**To:** Corporate Apollo Clinic <corporate@apolloclinic.com>

**Cc:** Customer Care :Mediwheel : New Delhi <customercare@mediwheel.in>; Network : Mediwheel : New Delhi <network@mediwheel.in>

**Subject:** Health checkup booking No. 101

Dear Team

Please find the health checkup booking file and confirm the same.


Thanks & Regards

Lav Gupta



नाम टी डी देवा  
Name T D DEWA

E.C. NO. 126256

  
भारिकर्ता प्राधिकार  
Issuing Authority

भारिकर्ता प्राधिकार  
Signature of holder